



Preoperative prostate biopsy and multiparametric magnetic resonance imaging: reliability in detecting prostate cancer

Francesco Porpiglia¹, Filippo Russo², Matteo Manfredi¹, Fabrizio Mele¹, Cristian Fiori¹, Daniele Regge²

¹Division of Urology, University of Turin, San Luigi Gonzaga Hospital, Orbassano, Turin, Italy; ²Radiology Unit Institute for Cancer Research and Treatment, Candiolo, Turin, Italy

ABSTRACT

Purpose: The aim of the study was to analyse and compare the ability of multiparametric magnetic resonance imaging (mp-MRI) and prostate biopsy (PB) to correctly identify tumor foci in patients undergoing radical prostatectomy (RP) for prostate cancer (PCa).

Materials and Methods: 157 patients with clinically localised PCa with a PSA <10 ng/mL and a negative DRE diagnosed on the first (12 samples, Group A) or second (18 samples, Group B) PB were enrolled at our institution. All patients underwent mp-MRI with T2-weighted images, diffusion-weighted imaging, dynamic contrast enhanced-MRI prior to RP. A map of comparison describing each positive biopsy sample was created for each patient, with each tumor focus shown on the MRI and each lesion present on the definitive histological examination in order to compare tumor detection and location. The sensitivity of mp-MRI and PB for diagnosis was compared using Student's t-test. The ability of the two exams to detect the prevalence of Gleason pattern 4 in the identified lesions was compared using a chi-square test.

Results: Overall sensitivity of PB and mp-MRI to identify tumor lesion was 59.4% and 78.9%, respectively ($p < 0.0001$). PB missed 144/355 lesions, 59 of which (16.6%) were significant. mp-MRI missed 75/355 lesions, 12 of which (3.4%) were significant. No lesions with a GS ≥ 8 were missed. Sensitivity of PB and mp-MRI to detect the prevalence of Gleason pattern 4 was 88.2% and 97.4%, respectively.

Conclusions: mp-MRI seems to identify more tumor lesions than PB and to provide more information concerning tumor characteristics.

ARTICLE INFO

Key words:

Prostatic Neoplasms; Prostate; Magnetic Resonance Imaging; Prostatectomy; Biopsy

Int Braz J Urol. 2015; 41: 124-33

Submitted for publication:
January 11, 2014

Accepted after revision:
September 09, 2014

INTRODUCTION

In recent decades, an increase in prostate cancer (PCa) diagnosis occurred because of the introduction of PSA into clinical practice and an increase in the number of biopsy samples, leading to an increase in cases with low-grade disease on prostate biopsy (PB) and a pathological migration towards earlier stage tumors (1).

After the diagnosis of PCa, some factors have a negative prognostic value, such as tumor volume (TV) and Gleason Score (GS). The current definition of clinically significant disease is PCa with a TV ≥ 0.5 mL and/or a pathologic GS > 6 (2, 3). To predict a significant PCa prior to surgery, urologists use parameters such as the PSA value, digital rectal examination (DRE), and PB results (bioptic GS, number of positive samples

and percentage of biopsy cores positive for PCa), separately or in combination in nomograms (4). Despite the use of these tools, tumor size and aggressiveness are often underestimated (5). Recently, some authors have emphasised the role of multiparametric magnetic resonance imaging (mp-MRI) in PCa diagnosis, taking advantage of the anatomical, morphological and functional information that it provides (6-8).

The aim of this prospective study was to analyse the ability of mp-MRI to correctly identify tumor foci in patients undergoing radical prostatectomy (RP) for PCa with a PSA <10 ng/mL and a negative DRE and to compare it with the results of PB. The secondary aims were to identify significant or insignificant lesions and to compare the ability of these results dividing our population in terms of diagnosis at first or second PB.

MATERIALS AND METHODS

Population

The study lasted between September 2010 and November 2012, and it was approved by the ethical committee of our institution, San Luigi Hospital in Orbassano (Turin), Italy. During this period, 178 consecutive patients with PCa diag-

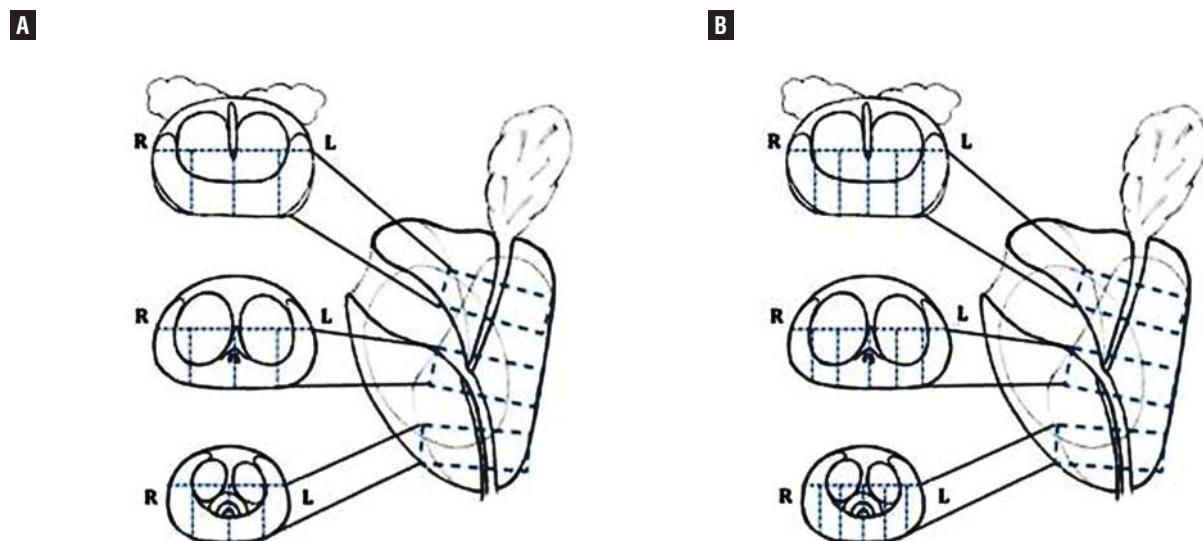
nosed on the first or second PB who underwent mp-MRI prior to RP, as a part of preoperative evaluation, were enrolled at our institution.

For the purposes of the study, only patients with clinically localised PCa with a PSA <10 ng/mL and a negative DRE were included. The exclusion criteria involved: any previous prostate treatment (TURP, 12 patients; hormonal therapy, 4 patients); contraindications for mp-MRI (i.e., claustrophobia, presence of magnetically activated implanted devices, metallic implants in sensitive areas; 5 patients). The patients were divided into two groups: Group A, patients diagnosed at the first biopsy; and Group B, patients diagnosed at the second biopsy.

Prostate biopsy

All biopsies were performed at our institution with a transrectal approach under TRUS guidance. First biopsies consisted of 12 samples (Group A) while second biopsies consisted of 18 samples (Group B). Second biopsies were performed in cases of an initial negative PB and persistently elevated PSA, according to a systematic template. A modification of the European Consensus Meeting on the prostate MRI template (9) was used for this purpose (Figure-1).

Figure 1 - Prostate reporting scheme for first (A) and second (B) prostate biopsy with transrectal approach. Prostate gland is divided into 12 (A) or 18 (B) sectors.



mp-MRI

All patients underwent preoperative mp-MRI in the Department of Radiology of I.R.C.C. in Candiolo, using a 1.5 Tesla unit (Signa HDX, General Electric, Milwaukee, USA), with a 4-channel phased-array body coil and an endorectal coil filled with 50 mL of air for signal reception, after intramuscular injection of 20 mg butylscopolamine bromide. All patients underwent mp-MRI at least 6 weeks after PB, to reduce artefacts due to bleeding or inflammation. All mp-MRI examinations were performed according to the same protocol, using the following sequences: a panoramic T1-weighted sequence from the aortic bifurcation to the symphysis pubis for the evaluation of iliac and obturator lymphadenopathies; T2-weighted images (slice-thickness 3 mm, FOV 16 x 16 cm, NEX 2) and T1 fast spin-echo axial images (slice-thickness 3 mm, TR/TE 580/min, FOV 16 x 16 cm, matrix 320 x 256, NEX 2) were used to study prostate and seminal vesicles in axial (TR/TE 3020/85), coronal (TR/TE 3620/90) and sagittal (TR/TE 3960/110) planes. Three sequences were obtained on Diffusion-Weighted Imaging (DWI), with axial EPI sequences (slice-thickness 3 mm, TR/TE 7000/min., FOV 16x16 cm, matrix 128x128, NEX 6) with b-values of 0.600 s/mm², 0.1000 s/mm² and 0.1400 s/mm². Dynamic Contrast Enhanced MRI (DCE-MRI) was performed using axial FSPGR sequences with a temporal resolution of 13s, repeated for 26 times (TR/TE ~3.5/min., FOV 20x20 cm, matrix 224x192, NEX 0.5). The contrast agent (gadobutrol, Gadovist, Bayer Pharma AG, Berlin) was administered intravenously at an injection rate of 2 mL/s, followed by saline solution flush at the same rate using a power injector (Spectris, Medrad). The entire prostate was sectioned to achieve 3 mm-thick parasagittal sections. All MRI images were interpreted by the same expert urologist. Positivity for neoplastic tissue was defined by the following: hypointensity in T2-weighted (T2w) images; an Apparent Diffusion Coefficient (ADC) value ≤ 1.05 mm²/s with a b-value of 1000 s/mm² in DWI examination; an enhancing area with early intense contrast uptake followed by washout in DCE-MRI. Overall, the mp-MRI finding was considered positive if at least two of the three MRI sequences (T2w, DWI and DCE-MRI) produced

suspicious findings. The presence, side and location of PCa were analysed, and for every lesion, the radiological stage, ADC and pharmacokinetic parameters were analysed using DCE-MRI. For the purpose of the study, very low ADC values were considered as an index of Gleason pattern 4 prevalence, based on the previously reported correlation between ADC and GS (10).

RP

All patients underwent robot-assisted RP at our institution.

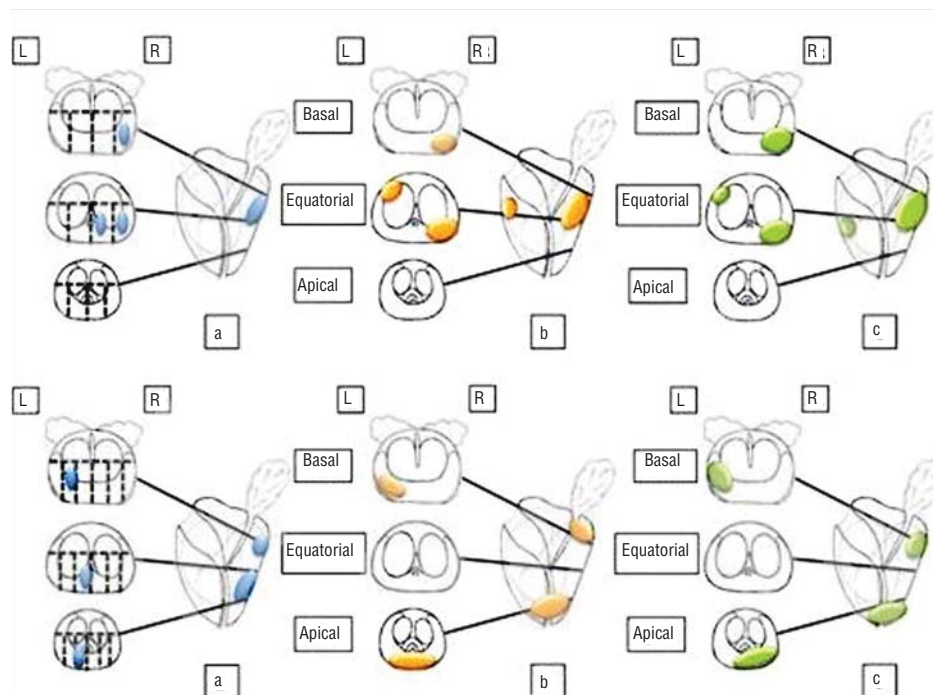
Pathologic analysis

All RP specimens were uniformly processed and submitted in their entirety for histological investigation according to the protocol of Montironi et al. (11). The entire prostate surface was treated with black ink, and the seminal vesicles and the apical and basal portions of the gland were removed to create two 4 mm sections. From the remaining gland, 4 mm-thick parasagittal sections were obtained and were further sectioned to achieve 3 mm slices (analogous to slices obtained with MRI), which were then stained with haematoxylin-eosin. Tumors were staged according to the TNM classification system, and the grading was evaluated according to the Gleason Score (12). The volume of each tumor was measured using the ellipsoid formula (length x width x height x 0.52) in mL. The pathologic analysis was conducted by the same uropathologist who was blinded to the MRI results. The following variables were analysed: tumor location, TV, and pathologic GS (pGS).

Map of comparison

A dedicated operator, blinded to patient names, noted the location of positive biopsy samples according to the European Consensus Meeting on prostate MRI (9) on a specific form. The same procedure was performed by the radiologist for the MRI report and by the pathologist for the pathology report. A map describing each positive biopsy sample was created for each patient, with each tumor focus shown on the MRI and each lesion present on the definitive histological examination (Figure-2).

Figure 2 - Example of two comparison maps between biopsy (a, a'), mp-MRI (b, b') and pathological examination (c, c'). The first case (1) was a naive patient with 12 PB samples (a), with a diagnosis of PCa in 3/12 samples on the right lobe (equatorial, equatorial lateral, basal lateral); mp-MRI (b) highlighted two areas that were suspicious for cancer: the posterolateral equatorial right with extension to the base (diameter 8x5 mm) and the anterolateral equatorial left (diameter 4x5 mm); a histological examination of the surgical specimen (c) demonstrated two tumor foci: a right posterolateral lesion on the basal plane extending to the equatorial plane (vol. 0.75 mL) and a left anterolateral lesion on the equatorial plane (vol. 0.3 mL). The second case (2) was a patient with persistently elevated PSA from whom 18 samples were collected during a second PB (a'). A diagnosis of PCa was made in 3/12 samples from the left lobe (equatorial lateral, basal median, apical median); mp-MRI (b') highlighted two suspicious areas: the posterolateral left on the basal plane (diameter 6x4 mm) and the apical posterior (diameter 14x6 mm); a histological examination of the specimens (c') demonstrated two tumor foci: a left posterolateral lesion on the basal plane (vol. 0.45 mL) and a right posterolateral apical lesion extending to the contralateral lobe (vol. 1.25 mL).



Statistical analysis

Using the tumor map obtained by the pathologic analysis as the standard reference, the overlap of the biopsy samples and mp-MRI was evaluated. Lesions were divided into groups according to the TV (<0.5 and ≥ 0.5 mL), the tumor location (basal, equatorial and apical) and the pGS (≤ 6 , 7a - 3+4, 7b - 4+3, ≥ 8). The sensitivity of mp-MRI and PB for diagnosis was compared using Student's t-test in the overall population and in Groups A and B. Finally, the ability of the two

exams to detect the prevalence of Gleason pattern 4 in the identified lesions was recorded and compared using a chi-square test. All statistical tests were performed using Statistic 7 software (Statsoft, Tulsa, Oklahoma) and p-values <0.05 were considered as statistically significant.

RESULTS

The overall population consisted of 157 patients: group A consisted of 113 patients diagnosed at the first prostate mapping, while group B

consisted of 44 patients diagnosed at the second prostate mapping. The baseline characteristics are detailed in Table-1.

The pathologic analysis identified 355 neoplastic lesions, 140 (39.4%) with a TV <0.5 mL and 215 (60.6%) with a TV ≥0.5 mL. The mean TV was 2.21±2.5 mL (median 1.55 mL; range 0.04-15.3 mL). According to the pGS, 150 (42.3%) lesions had a GS ≤6, 148 (41.7%) GS=7a (3+4), 31 (9%) GS=7b (4+3) and 26 (7%) a GS≥8. Tumor location was also analysed; 118 (33.2%) lesions were basal, 121 (34.1%) were equatorial, and 116 (32.7%) were apical.

Overall, MRI identified tumor lesions thanks to three sequences that produced suspicious findings (T2w, DWI and DCE-MRI) in 69 cases and thanks to two sequences in 211. In 36 cases, only one sequence (T2w or DWI or DCE-MRI) produced suspicious finding, so the lesion was not classified as tumour (see Materials and Methods section - mp MRI).

The sensitivities of PB and mp-MRI for identifying tumor foci, stratified by TV, tumor location and pGS, in the overall population and in the two subgroups are presented in Tables 2 and 3.

PB missed 144/355 lesions, 59 of which (40.9%) were significant: 11 with a TV ≥0.5 mL, 25 with a pGS=7 and 23 with both a TV ≥0.5 mL and a pGS=7. No statistically significant differences in

the number of missed significant lesions were recorded between Groups A and B.

mp-MRI missed 75/355 lesions, 12 of which (16%) were significant: four with a TV ≥0.5 mL, six with a pGS=7 and two with both a TV ≥0.5 mL and a pGS=7. No lesions with a GS ≥8 were missed by both mp-MRI and PB.

Compared to PB, in the overall population and in Groups A and B, mp-MRI demonstrated a higher sensitivity, reaching statistical significance in most of stratifications. The results are detailed in Table-4.

The abilities of mp-MRI and PB to detect the prevalence of Gleason pattern 4 are shown in Table-5.

PB showed an accuracy, sensitivity, specificity, positive predictive value, and negative predictive value of 87.2%, 88.2%, 81.8%, 96.3%, and 56.3%, respectively, while mp-MRI showed values of 97.5%, 97.4%, 98.0%, 99.6%, and 89.3%, respectively. Pearson's correlation coefficients were 0.6067 and 0.9207 for PB and mp-MRI, respectively.

DISCUSSION

After a diagnosis of localised PCa eligible for RP, the current standard of pre-operative evaluation is based on data from biopsies of the entire

Table 1 - Baseline characteristics. Group A= first biopsy (12 samples); Group B= second biopsy (18 samples); SD= standard deviation.

	Overall population	Group A	Group B	p-value
Number of patients	157	113	44	/
Age, mean (SD), years	63.1±6.2	63.2±6	63.1±6.8	NS
PSA, mean (SD), ng/mL	5.87±2.1	5.91±2	5.73±2.2	NS
Number of positive biopsy samples, median (range)	3 (1-12)	3 (1-8)	3 (1-12)	NS
% pathological tissue, median (range)	13.5 (0.1-87)	12.5 (0.1-80)	14 (0.5-87)	NS
Bioptic Gleason Score, rate (number of patients)				
≤6	51.6%(81)	54.9%(62)	43.2%(19)	NS
7a	37.6%(59)	36.3%(41)	40.9%(18)	NS
7b	5.1%(8)	2.6%(3)	11.4%(5)	NS
≥8	5.8%(9)	6.2%(7)	4.5%(2)	NS

Table 2 - Neoplastic lesions identified by prostate biopsy. Group A= first biopsy (12 samples); Group B= second biopsy (18 samples).

		Prostate Biopsy			
		Identified overall	Identified Group A	Identified Group B	p-value
Pathologic Tumor Volume	<0.5 mL	21.4% (30/140)	20.8% (21/101)	23.1% (9/39)	NS
	≥0.5 mL	84.2% (181/215)	81.5% (123/151)	90.6% (58/64)	NS
Pathologic Tumor Location	Basal	54.2% (64/118)	51.2% (43/84)	61.8% (21/34)	NS
	Equatorial	61.2% (74/121)	58.8% (50/85)	66.7% (24/36)	NS
	Apical	62.9% (73/116)	61.4% (51/83)	66.7% (22/33)	NS
Pathologic Gleason Score	≤6	36.0% (54/150)	33.7% (36/107)	41.9% (18/43)	NS
	7a	73.0% (108/148)	71.7% (76/106)	76.2% (32/42)	NS
	7b	74.2% (23/31)	70.8% (17/24)	85.7% (6/7)	NS
	≥8	100% (26/26)	100% (15/15)	100% (11/11)	NS
Total		59.4% (211/355)	57.1% (144/252)	65% (67/103)	NS

Table 3 - Neoplastic lesions identified by mp-MRI. Group A= first biopsy (12 samples); Group B= second biopsy (18 samples).

		mp-MRI			
		Identified overall	Identified Group A	Identified Group B	p-value
Pathologic Tumor Volume	<0.5 mL	50.7% (71/140)	49.5% (50/101)	53.9% (21/39)	NS
	≥0.5 mL	97.2% (209/215)	96.7%(146/151)	98.4% (63/64)	NS
Pathologic Tumor Location	Basal	71.2% (84/118)	71.4%(60/84)	70.6% (24/34)	NS
	Equatorial	84.3% (102/121)	83.5% (71/85)	86.1% (31/36)	NS
	Apical	81.0% (94/116)	77.4% (65/83)	87.9% (29/33)	NS
Pathologic Gleason Score	≤6	55.3% (83/150)	53.3% (57/107)	60.5% (26/43)	NS
	7a	95.2% (141/148)	95.3%(101/106)	95.2%(40/42)	NS
	7b	96.8% (30/31)	95.8%(23/24)	100%(7/7)	NS
	≥8	100% (26/26)	100% (15/15)	100% (11/11)	NS
Total		78.9% (280/355)	77.8% (196/252)	81.6% (84/103)	NS

prostate gland under TRUS guidance. Thus, in men diagnosed with low-risk PCa, we observed an underestimation of the tumor grade in up to 30% of cases and the tumor burden in up to 50% of cases that was related to the biopsy technique, and

it affected both the first and repeat biopsies (5). mp-MRI is the imaging technique that provides the best results for the diagnosis of significant PCa with high sensitivity and specificity values (7). Moreover, the use of an endorectal coil may

Table 4 - Comparison between sensitivity of prostate biopsy and mp-MRI in identifying tumor lesions. Results are reported by studied variables in the overall population and in Group A (first prostate biopsy) and B (second prostate biopsy).

		Sensitivity	PB	mp-MRI	p-value
Total		Overall	59.4%	78.9%	<0.0001
		Group A	57.1%	77.8%	<0.0001
		Group B	65.0%	81.6%	0.0112
Pathologic Tumor Volume	<0.5 mL	Overall	21.4%	50.7%	<0.0001
		Group A	20.8%	49.5%	<0.0001
		Group B	23.1%	53.9%	<0.0001
	>0.5 mL	Overall	84.2%	97.2%	<0.0001
		Group A	81.5%	96.7%	<0.0001
		Group B	90.6%	98.4%	0.0316
Pathologic Tumor Location	Basal	Overall	54.2%	71.2%	0.01
		Group A	51.2%	71.4%	0.0114
		Group B	61.8%	70.6%	NS
	Equatorial	Overall	61.2%	84.3%	0.0001
		Group A	58.8%	83.5%	0.0007
		Group B	66.7%	86.1%	NS
	Apical	Overall	62.9%	81.0%	0.0035
		Group A	61.4%	77.4%	0.0386
		Group B	66.7%	87.9%	NS
Pathologic Gleason Score	≤6	Overall	36.0%	55.3%	0.0012
		Group A	33.7%	53.3%	0.0059
		Group B	41.9%	60.5%	NS
	7a	Overall	73.0%	95.2%	< 0.0001
		Group A	71.7%	95.3%	< 0.0001
		Group B	76.2%	95.2%	0.0296
	7b	Overall	74.2%	96.8%	0.0291
		Group A	70.8%	95.8%	NS
		Group B	85.7%	100%	NS
	≥8	Overall	100%	100%	NS
		Group A	100%	100%	NS
		Group B	100%	100%	NS

Table 5 - Comparison among PB and mp-MRI in predicting the prevalence of Gleason pattern 4 on histopathological analysis. The prevalence of pattern 4 is evaluated on histology and biopsy with the Gleason Score $\geq 7b$ (pGS and bGS, respectively) while is predicted in mp-MRI by a very low value of the ADC on DWI. Gleason pattern 4 not prevalent is defined by Gleason Score $\leq 7a$. The rate (number) of identified patients are shown. In the lower part of the table the Pearson correlation coefficient, both for biopsy and mp-MRI, is indicated.

		PB		mp-MRI	
		Pattern 4 prevalent	Pattern 4 not prevalent	Pattern 4 prevalent	Pattern 4 not prevalent
Histology (standard reference)	Pattern 4 prevalent	56.2% (27/48)	43.8% (21/48)	89.3% (50/56)	10.7% (6/56)
	Pattern 4 not prevalent	3.7% (6/163)	96.3% (157/163)	0.4% (1/224)	99.6% (223/224)
Pearson's correlation coefficient		0.6067		0.9207	

allow a more accurate detection rate by improving the spatial characterisation of the prostate zonal anatomy and molecular changes (13). Actually, mp-MRI is also gaining an important role because of the possibility that it offers in performing cognitive (14) or visually guided targeted PB (15-17). In this study, compared to transrectal biopsy, mp-MRI demonstrated a significantly greater sensitivity in the entire study population (78.9% vs. 59.4%, $p < 0.001$) and in each subgroup (TV, tumor location and pGS). Moreover, mp-MRI diagnosed the vast majority of significant lesions regarding TV (97.2% in PCa with TV ≥ 0.5 mL) and pGS ($>95\%$ in PCa with pGS ≥ 7). Although mp-MRI had a sensitivity that was statistically higher than biopsy, both had low sensitivity for detecting small lesions (TV < 0.5 mL). The same results were observed when the population was divided into patients diagnosed at the first PB (Group A) or the second PB (Group B). Despite these differences between mp-MRI and PB, it is extremely important to identify the characteristics of the missed lesions and determine whether these characteristics are actually significant.

In our study, only 12 of the 75 lesions (16%) missed by mp-MRI were significant PCas (with a TV ≥ 0.5 mL and/or a GS ≥ 7), representing 3.4% (12/355) of all identified lesions. Conversely, PB missed 144 lesions of which 40% (59/144) were significant (16.6% of all identified lesions). Interestingly, all lesions with a GS ≥ 8 were diagnosed by both mp-MRI and PB.

A change in GS from the PB to the resected specimen was recently reported in approximately 23-35% of cases (18). Functional imaging techniques provide information not just about tumor location and volume but also about cancer behaviour (8): less differentiated and dense cancers are associated with lower ADC values, better contrast and a higher detection rate using DWI (19, 20). Additionally, cancer foci show lower ADC values than normal prostate tissue, and these values correlate with GS (10, 21). Nevertheless, ADC values may vary depending on the technical parameters used (10). In our study, we analysed the ability of mp-MRI to identify the prevalence of the pathologic Gleason pattern 4 and observed a strong correlation (Pearson 0.9207) between Gleason pattern 4 and very low ADC values on DWI, while a good correlation was obtained using the biopsy GS (Pearson 0.6067).

Focusing on clinically not significant disease, mp-MRI correctly identified 50% of tumor lesions with a TV < 0.5 mL and 55% of PCa with a GS ≤ 6 . In our opinion, on the basis of these results, mp-MRI may be a valid diagnostic tool not only before the surgery but also in the follow up of patients included in active surveillance protocols for PCa.

The technical parameters of mp-MRI used in this study correspond to the minimal imaging requirements outlined in the recommendations of the European Consensus Meeting on prostate MRI

(9), particularly concerning the use of an endorectal coil (considered an optimal requirement).

This study was limited by the inclusion of only a single expert urologist who interpreted all the mp-MRI images, which may affect the reproducibility of our results in centres without a radiologic team specialised in prostate mp-MRI. On the other hand, including only one urologist minimises sources of potential bias because patients were treated and followed at the same department.

CONCLUSIONS

Our study suggested that mp-MRI allows for higher identification rate of tumor lesions than PB. Moreover, compared to significant PCa diagnosed at either the first or second biopsy, mp-MRI provides more information concerning tumor anatomy (tumor volume and location) and aggressiveness (prevalence of Gleason pattern 4). In patients with PCa with PSA <10 ng/mL and negative DRE, the data provided by mp-MRI may be useful for better therapeutic planning.

ABBREVIATIONS

PCa = prostate cancer

PB = prostate biopsy

TV = tumor volume

GS = Gleason Score

DRE = digital rectal examination

mp-MRI = multiparametric Magnetic Resonance Imaging

RP = radical prostatectomy

DWI = Diffusion-Weighted Imaging

DCE = Dynamic Contrast Enhancement

ADC = Apparent Diffusion Coefficient

CONFLICT OF INTEREST

None declared.

REFERENCES

1. Mouraviev V, Villers A, Bostwick DG, Wheeler TM, Montironi R, Polascik TJ. Understanding the pathological features of focality, grade and tumour volume of early-stage prostate cancer as a foundation for parenchyma-sparing prostate cancer therapies: active surveillance and focal targeted therapy. *BJU Int.* 2011;108:1074-85.
2. Stamey TA, McNeal JE, Yemoto CM, Sigal BM, Johnstone IM. Biological determinants of cancer progression in men with prostate cancer. *JAMA.* 1999 281:1395-400.
3. Ploussard G, Epstein JI, Montironi R, Carroll PR, Wirth M, Grimm MO, et al. The contemporary concept of significant versus insignificant prostate cancer. *Eur Urol.* 2011;60:291-303.
4. Shukla-Dave A, Hricak H, Akin O, Yu C, Zakian KL, Udo K, et al. Preoperative nomograms incorporating magnetic resonance imaging and spectroscopy for prediction of insignificant prostate cancer. *BJU Int.* 2012;109:1315-22.
5. Crawford ED, Wilson SS, Torkko KC, Hirano D, Stewart JS, Brammell C, et al. Clinical staging of prostate cancer: a computer-simulated study of transperineal prostate biopsy. *BJU Int.* 2005;96:999-1004.
6. Sciarra A, Barentsz J, Bjartell A, Eastham J, Hricak H, Panebianco V, et al. Advances in magnetic resonance imaging: how they are changing the management of prostate cancer. *Eur Urol.* 2011;59:962-77.
7. Puech P, Potiron E, Lemaitre L, Leroy X, Haber GP, Crouzet S, et al. Dynamic contrast-enhanced-magnetic resonance imaging evaluation of intraprostatic prostate cancer: correlation with radical prostatectomy specimens. *Urology.* 2009 ;74:1094-9.
8. Hoeks CM, Barentsz JO, Hambrock T, Yakar D, Somford DM, Heijmink SW, et al. Prostate cancer: multiparametric MR imaging for detection, localization, and staging. *Radiology.* 2011;261:46-66.
9. Dickinson L, Ahmed HU, Allen C, Barentsz JO, Carey B, Futterer JJ, et al. Magnetic resonance imaging for the detection, localisation, and characterisation of prostate cancer: recommendations from a European consensus meeting. *Eur Urol.* 2011;59:477-94.
10. Barentsz JO, Richenberg J, Clements R, Choyke P, Verma S, Villeirs G, et al. European Society of Urogenital Radiology. ESUR prostate MR guidelines 2012. *Eur Radiol.* 2012;22:746-57.
11. Montironi R, Mazzucchelli R, Kwast T. Morphological assessment of radical prostatectomy specimens. A protocol with clinical relevance. *Virchows Arch.* 2003 ;442:211-7.

12. Epstein JI, Allsbrook WC Jr, Amin MB, Egevad LL; ISUP Grading Committee. The 2005 International Society of Urological Pathology (ISUP). Consensus Conference on Gleason Grading of Prostatic Carcinoma. *Am J Surg Pathol.* 2005;29:1228-42.
13. Masterson TA, Touijer K. The role of endorectal coil MRI in preoperative staging and decision-making for the treatment of clinically localized prostate cancer. *MAGMA.* 2008;21:371-7.
14. Puech P, Rouvière O, Renard-Penna R, Villers A, Devos P, Colombel M, et al. Prostate cancer diagnosis: multiparametric MR-targeted biopsy with cognitive and transrectal US-MR fusion guidance versus systematic biopsy—prospective multicenter study. *Radiology.* 2013;268:461-9.
15. Pinto PA, Chung PH, Rastinehad AR, Baccala AA Jr, Kruecker J, Benjamin CJ, et al. Magnetic resonance imaging/ultrasound fusion guided prostate biopsy improves cancer detection following transrectal ultrasound biopsy and correlates with multiparametric magnetic resonance imaging. *J Urol.* 2011;186:1281-5.
16. Moore CM, Robertson NL, Arsanious N, Middleton T, Villers A, Klotz L, et al. Image-guided prostate biopsy using magnetic resonance imaging-derived targets: a systematic review. *Eur Urol.* 2013;63:125-40.
17. Siddiqui MM, Rais-Bahrami S, Truong H, Stamatakis L, Vourganti S, Nix J, et al. Magnetic resonance imaging/ultrasound-fusion biopsy significantly upgrades prostate cancer versus systematic 12-core transrectal ultrasound biopsy. *Eur Urol.* 2013;64:713-9.
18. Cooperberg MR, Carroll PR, Klotz L. Active surveillance for prostate cancer: progress and promise. *J Clin Oncol.* 2011;29:3669-76.
19. deSouza NM, Riches SF, Vanas NJ, Morgan VA, Ashley SA, Fisher C, et al. Diffusion-weighted magnetic resonance imaging: a potential non-invasive marker of tumour aggressiveness in localized prostate cancer. *Clin Radiol.* 2008;63:774-82.
20. Yoshimitsu K, Kiyoshima K, Irie H, Tajima T, Asayama Y, Hirakawa M, et al. Usefulness of apparent diffusion coefficient map in diagnosing prostate carcinoma: correlation with stepwise histopathology. *J Magn Reson Imaging.* 2008;27:132-9.
21. Hambroek T, Somford DM, Huisman HJ, van Oort IM, Witjes JA, Hulsbergen-van de Kaa CA, et al. Relationship between apparent diffusion coefficients at 3.0-T MR imaging and Gleason grade in peripheral zone prostate cancer. *Radiology.* 2011;259:453-61.

Correspondence address:

Francesco Porpiglia, MD, PhD
San Luigi Gonzaga Hospital - Urology
Regione Gonzole 10 Orbassano
Turin, 10043, Italy
E-mail: porpiglia@libero.it