

Rise in total IgE as an indicator of allergic bronchopulmonary aspergillosis in cystic fibrosis

J L Marchant, J O Warner, A Bush

Abstract

Background – Allergic bronchopulmonary aspergillosis is a serious complication of cystic fibrosis and may be difficult to diagnose. The aim of this study was to define the usefulness of measuring total IgE compared with other major criteria in the diagnosis of allergic bronchopulmonary aspergillosis in children with cystic fibrosis.

Methods – A retrospective analysis was carried out of the case records of 160 children attending a tertiary referral paediatric cystic fibrosis clinic.

Results – Sixteen children had a total IgE level above 500 IU/ml. Eleven children had six or more other major criteria and were considered to have allergic bronchopulmonary aspergillosis. These 11 children had a fourfold rise in IgE in association with clinical deterioration. A further child had a fourfold rise in IgE to 341 IU/l, and was also thought to have allergic bronchopulmonary aspergillosis. Eleven had a fall in IgE with successful treatment; one patient died with uncontrolled disease. Only one of these 12 children had negative precipitins to *Aspergillus fumigatus*. The five children with a raised IgE not thought to have bronchopulmonary aspergillosis had four or fewer major criteria and were not treated; none had positive precipitins.

Conclusions – A fourfold rise in total IgE, particularly to above 500 IU/ml, is strongly suggestive of the diagnosis of allergic bronchopulmonary aspergillosis in children with cystic fibrosis. The measurement of total IgE has the merit of being simple to perform and objective. Positive aspergillus precipitins provide useful confirmatory evidence. These two criteria, taken in conjunction with clinical deterioration and new radiological shadowing, allow simplification of the diagnosis of allergic bronchopulmonary aspergillosis in cystic fibrosis.

(Thorax 1994;49:1002-1005)

Allergic bronchopulmonary aspergillosis (ABPA) is a serious complication of cystic fibrosis but its prevalence is disputed, ranging from 0% to 11% in the published literature.¹⁻⁴ Major and minor diagnostic criteria (table 1) have been proposed,^{5,6} but have the disadvantage of being relatively non-specific in

this setting.⁶ For example, chest radiographic shadows are common and there are many other reasons for a deterioration in respiratory symptoms in such children.^{3,6} In our clinic⁷ the prevalence of a positive culture for *Aspergillus fumigatus* in sputum is 30%, a positive skin prick test is 30%, a positive specific IgE to *Aspergillus fumigatus* (RAST) is 27%, and positive IgG precipitin lines is 12% in children with stable cystic fibrosis and nothing to suggest ABPA, underscoring the lack of specificity of these criteria. One group even discarded these criteria and proposed that the diagnosis of ABPA should be considered in children with new radiographic shadows which have not responded to intravenous antibiotics.³ The importance of detecting a high level of IgE has become apparent since ABPA was first described in 1965.^{8,9} On the other hand, atopy and a high level of IgE are common findings in cystic fibrosis.^{7,9-11} Making the diagnosis of ABPA is important because of the risk of deterioration if it is not treated; conversely, unnecessary treatment with oral corticosteroids should be avoided. We have therefore carried out a study to determine the significance of a high level of IgE in cystic fibrosis and to ascertain its use (if any) as an aid to the diagnosis of ABPA.

Methods

A total of 160 children attended our paediatric cystic fibrosis clinic for their annual assessments (80 boys and 80 girls, age range four months to 17 years). In all cases the diagnosis had been established by duplicate measurements of sodium levels in sweat of more than 70 mmol/l on more than 100 mg of sweat¹² together with a compatible clinical history.

Routine investigations performed annually include chest radiography; ventilation lung scans or (in older children) pulmonary function tests; routine haematology and biochemistry;

Table 1 Diagnostic criteria for allergic bronchopulmonary aspergillosis

Major criteria	Pulmonary infiltrates Increased serum total IgE +ve skin prick tests to <i>Aspergillus fumigatus</i> +ve RAST to <i>Aspergillus fumigatus</i> Presence of precipitins to <i>Aspergillus fumigatus</i> Reversible bronchoconstriction Blood eosinophils Central bronchiectasis
Minor criteria	Positive sputum culture to <i>Aspergillus fumigatus</i> Brown plugs in sputum Late skin test reaction

Department of
Paediatric Respiratory
Medicine, Royal
Brompton National
Heart and Lung
Hospital, London
SW3 6NP
J L Marchant
A Bush

Department of Child
Health, University of
Southampton, UK
J O Warner

Reprint requests to:
Dr A Bush.

Received 28 February 1994
Returned to authors
6 May 1994
Revised version received
13 June 1994
Accepted for publication
16 June 1994

Table 2 Details of the patients studied. Those in group 1 were thought to have ABPA and those in group 2 had a raised IgE titre but were thought not to have ABPA

Patient no.	Sex	Age	IgE before diagnosis	IgE before treatment	IgE after treatment	RAST	Serum precipitins to <i>A. fumigatus</i>	Skin prick test	Eosinophils >0.4	Chest radiograph*
Group 1:										
1	M	9	ND	2117	1279	+ve	-ve	+ve	+ve	+ve
2	F	10	13	560	66	+ve	+ve	+ve	+ve	+ve
3	F	8	37	341	74	+ve	+ve	+ve	+ve	+ve
4	M	12	83	1660	677	+ve	+ve	+ve	+ve	+ve
5	F	8	970	2456	Died	+ve	+ve	ND	-ve	+ve
6	M	12	237	1498	129	+ve	+ve	+ve	+ve	+ve
7	F	9	1360	7756	ND	+ve	+ve	+ve	-ve	+ve
8	M	10	502	5736	2678	+ve	+ve	+ve	+ve	+ve
9	F	13	806	3780	936	+ve	+ve	+ve	+ve	+ve
10	M	17	990	5330	737	+ve	+ve	+ve	+ve	+ve
11	M	11	219	2905	97	+ve	+ve	+ve	+ve	+ve
12	F	14	1050	3108	2152	+ve	+ve	+ve	+ve	+ve
Group 2:										
			IgE (1)†	IgE (2)†						
13	M	7	248	699		+ve	-ve	+ve	-ve	-ve
14	M	12	259	3993		+ve	ND	+ve	+ve	-ve
15	M	13	39	1287		+ve	-ve	+ve	+ve	+ve
16	M	12	206	784		+ve	-ve	+ve	-ve	-ve
17	M	4	182	919		+ve	-ve	+ve	+ve	-ve

ND = not done; IgE = total IgE (normal <150 IU/l); RAST = radioallergosorbent test for specific IgE antibodies.

* Typical wedge shadows on chest radiograph.

† IgE(1) and (2) are measurements made one year apart on annual review.

immunoglobulins A, M, G and E; *Aspergillus fumigatus* RAST using the standard scoring system from 0 to 4; serum precipitins to *Aspergillus fumigatus* using double immunodiffusion of unconcentrated serum with Bencard standard antigens 1 and 2. Sputum (when available) is cultured on every visit. Full reassessment is performed at the time of any respiratory deterioration.

Results

Sixteen children with a total IgE of more than 500 IU/ml on at least one occasion were identified, together with a further child who had a fourfold rise in IgE to 341 IU/ml. The results of testing for *Aspergillus fumigatus* RAST and precipitins, skin prick tests (immediate sensitivity), and sputum culture for *Aspergillus fumigatus* in these 17 children are shown in table 2. These children could be divided into two groups.

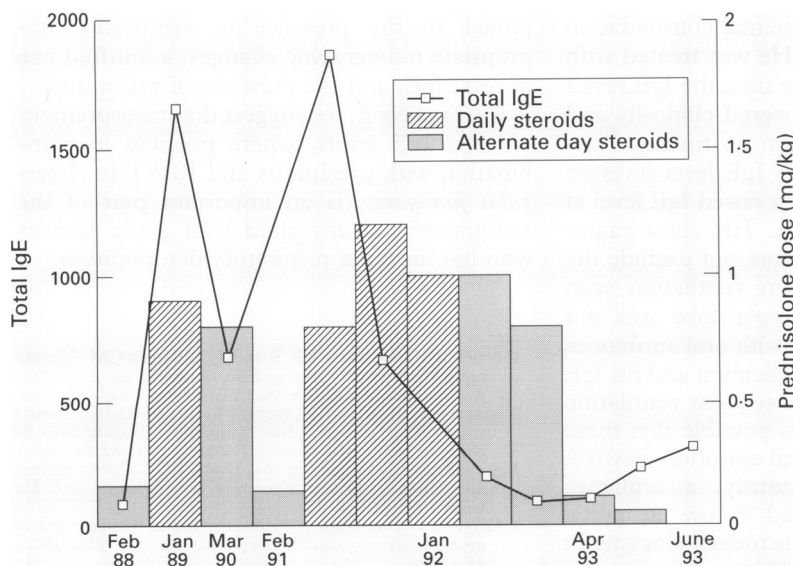
Twelve (7.5%) were considered to have ABPA, having evidence of clinical deterioration and meeting at least six of the major criteria listed in table 1 (group 1 in table 2). Additionally, the total IgE levels showed at least a fourfold rise from their baseline level to above 500 IU/ml. One child (patient 3) who was considered on other standard grounds to have ABPA had a rise in IgE to only 341 IU/ml, but this constituted a greater than fourfold rise. In 11 children IgE results were available after treatment with oral prednisolone, 1 mg/kg. There was a fall in IgE which tracked the clinical and radiological response to treatment. The exception was patient 8 who continued to deteriorate despite administration of high dose steroids, oral itraconazole, and nebulised amphotericin. She died of respiratory failure and her total IgE was >10 000 IU/ml just before her death.

Five other patients (group 2 in table 2) had a total IgE >500 IU/ml. All had four or fewer other major criteria for ABPA. Two failed to show a fourfold rise in total IgE. None of them had positive precipitins to *Aspergillus fumigatus*. The significance of these results is discussed below.

Discussion

The prevalence of ABPA is uncertain,¹⁻⁴ partly because of the lack of specificity of the diagnostic criteria.⁶ Of the major criteria (table 1) parenchymal shadowing on the chest radiograph, central bronchiectasis, and reversible bronchoconstriction may be manifestations of uncomplicated cystic fibrosis or an infective exacerbation, and hence we have reviewed our experience to try to refine the diagnosis.

We found that children with cystic fibrosis who had a total IgE level >500 IU/ml could be divided into two groups. Group 1 (n = 11) had a more than fourfold rise in IgE in association with at least six major criteria for ABPA and symptomatic deterioration. A further child had



Serial measurements of total IgE in patient 4. His initial episode of ABPA was treated with prednisolone, 1 mg/kg, but relapsed on reduction of the steroid dosage (second peak of IgE). This second episode responded to a higher dose of prednisolone.

a fourfold rise in IgE to 341 IU/ml with seven major criteria for the diagnosis, and was also considered to have ABPA. While accepting that there is no definitive diagnostic test, we felt that ABPA was the cause of deterioration and treated these children with oral prednisolone, 1 mg/kg. Others³ have used doses as high as 2 mg/kg. It is preferable to use the non-enteric coated preparation.¹³ The children improved clinically with a fall in total IgE concomitant with radiological improvement. This provided further evidence to support the diagnosis but, since some of our patients had also been given intravenous antibiotics, some diagnostic uncertainty remained. Using our diagnostic criteria, however, the prevalence of ABPA in our clinic population (12/160, 7.5%) was similar to other published series.¹⁻³

Supporting evidence for the diagnosis may come from measurements of RAST and precipitins to *Aspergillus fumigatus*. All the patients in group 1 had a positive RAST, implying that a negative RAST excludes or casts strong doubts on the diagnosis. However, all the patients in group 2 also had a positive RAST, reducing its predictive value. Precipitins were positive in 11 out of 12 of the children in group 1, but in none of the patients in group 2 in whom it was sought. Thus positive precipitins, particularly if they were previously negative, may be a stronger pointer to the diagnosis of ABPA in combination with a high or rapidly rising IgE.

The children in group 2 with a raised IgE level had four or fewer of the criteria for ABPA; none was treated with prednisolone. Patients 13 and 16 were completely stable between the two measurements of IgE, and the increases were attributed to known atopic status. Of note was the absence of a fourfold rise in IgE level. Patient 14 had a steep rise in IgE with no clinical or radiological features of ABPA. He received no treatment and a year later his IgE level had reverted to below 500 IU/ml with no change in clinical status. We have no explanation for this result. Patient 15 came to the clinic with minimally increased respiratory symptoms and had a segmental consolidation on the chest radiograph. He was treated with oral antibiotics and, by the time the IgE result was to hand, he had recovered clinically and radiologically. He was given no further treatment and subsequently his IgE level reverted to normal. Patient 17 had a raised IgE level at routine annual assessment. His chest radiograph was normal which does not exclude the diagnosis¹⁴ but his krypton ventilation scan revealed that the right upper lobe was not ventilated. He was treated with oral antibiotics but no other additional medication and his IgE levels fell to normal. A subsequent ventilation scan was also normal. It is possible that these two patients had subclinical episodes of ABPA which resolved spontaneously, a sequence which has been described before in cystic fibrosis.^{3,15} However, simple mucus plugging or infection cannot be excluded.

Aspergillus fumigatus has the capacity to cause numerous pulmonary problems including asthma, ABPA, mycetoma, and invasive dis-

ease. It has the capacity to grow at body temperature, and hence within the airways of patients.⁹ The consequence may be the exposure of patients to a heavy antigen load, generating an intense humoral immune response.¹⁶⁻¹⁸ Additionally *Aspergillus fumigatus* produces at least one proteinase which may damage bronchial epithelium.¹⁹ This intense response may set up cycles of further obstruction, inflammation, and lung damage. In common with others we found that ABPA is not rare in the cystic fibrosis population,¹⁻³ often requires high doses of prednisolone for control, and frequently relapses. Relapse of ABPA was associated in group 1 with a further abrupt rise in IgE level (figure), confirming the diagnostic utility of this measurement. These findings accord with the results of others,^{15,20} although less stringent criteria have been proposed. Greenberger²⁰ suggested that a doubling of total IgE was sufficient to signal the onset of ABPA, rather than the fourfold rise we propose. Presumably the timing of the blood samples will determine the extent of the rise, and further work is needed to delineate the minimum criteria for a truly significant rise in IgE levels.

Clearly there is no one diagnostic test that will be 100% sensitive and specific for ABPA. We would not advocate treating all patients with a raised level of IgE with prednisolone, since this would appear to have been unnecessary in five of the 17 children in this study. However, taken in context with the clinical picture, the presence of other major criteria and, in particular, if there is a fourfold or greater rise in titre, we believe that measurement of total IgE is an important diagnostic pointer towards ABPA. This measurement has the further merit of being easily and rapidly available. Many of the more sophisticated tests are bedevilled by differences in the quality of the *Aspergillus fumigatus* antigens used for testing in different laboratories.²¹ The presence of precipitins to *Aspergillus fumigatus*, at least as measured with Bencard standard antigens 1 and 2, is a further useful pointer to the diagnosis. Indeed, the diagnostic criteria could be simplified to the presence of symptoms, appropriate radiographic changes, a fourfold rise in total IgE, and the presence of precipitins.

In conclusion, we suggest that measurement of total IgE levels, where possible in combination with precipitins and RAST to *Aspergillus fumigatus*, is an important part of the examination of any child with cystic fibrosis who has an acute respiratory deterioration.

- 1 Brueton MJ, Ormerod LP, Shah KJ, Anderson CM. Allergic bronchopulmonary aspergillosis complicating cystic fibrosis in childhood. *Arch Dis Child* 1980;55:348-53.
- 2 Maguire S, Moriarty P, Tempary E, Fitzgerald M. Unusual clustering of allergic bronchopulmonary aspergillosis in children with cystic fibrosis. *Pediatrics* 1988;82:835-9.
- 3 Simmonds EJ, Littlewood JM, Evans EGV. Cystic fibrosis and allergic bronchopulmonary aspergillosis. *Arch Dis Child* 1990;65:507-11.
- 4 Carswell F, Hamilton A. Pathogenesis and management of aspergillosis in cystic fibrosis [letter]. *Arch Dis Child* 1990; 65:1288.
- 5 Rosenberg M, Patterson R, Mintzer R, et al. Clinical and immunologic criteria for the diagnosis of allergic bronchopulmonary aspergillosis. *Ann Intern Med* 1977;86:405-14.
- 6 Hiller EJ. Pathogenesis and management of aspergillosis in cystic fibrosis. *Arch Dis Child* 1990;65:397-8.

- 7 Nikolaizik WH, Brueton MJ, Warner JO. Aspergillus allergy and allergic bronchopulmonary aspergillosis in cystic fibrosis. *Pediatr Allergy Immunol* 1991;2:83-6.
- 8 Longbottom JL. Allergic bronchopulmonary aspergillosis: reactivity of IgE and IgG antibodies with antigenic components of *Aspergillus fumigatus* (IgE/IgG antigen complexes). *J Allergy Clin Immunol* 1983; 72:668-75.
- 9 Wardlaw A, Geddes DM. Allergic bronchopulmonary aspergillosis: a review. *J R Soc Med* 1992;85:747-51.
- 10 Warner JO, Taylor BW, Norman AP, Soothill JF. Association of cystic fibrosis with allergy. *Arch Dis Child* 1976;51:507-11.
- 11 Tobin MJ, Maguire O, Reen D, Tempany E, Fitzgerald MX. Atopy and bronchial reactivity in older patients with cystic fibrosis. *Thorax* 1980;35:807-13.
- 12 Gibson LF, Cooke RE. A test for concentration of electrolytes in sweat in cystic fibrosis of the pancreas utilising pilocarpine iontophoresis. *Pediatrics* 1959;23:545-9.
- 13 Gilbert J, Littlewood JM. Enteric coated prednisolone in cystic fibrosis. *Lancet* 1986;ii:1167-8.
- 14 Rosenberg M, Mintzer R, Aarouson DW, Patterson R. Allergic bronchopulmonary aspergillosis in three patients with normal chest X-ray. *Chest* 1977;72:597-600.
- 15 Bernstein JA, Zeiss CR, Greenberger PA, Patterson R, Marhoul JF, Smith LL. Immunoblot analysis of sera from patients with allergic bronchopulmonary aspergillosis: correlation with disease activity. *J Allergy Clin Immunol* 1990; 86:532-9.
- 16 Safirstein BH, D'Souza MF, Simon G, Tai EH-C, Pepys J. Five year follow up of allergic bronchopulmonary aspergillosis. *Am Rev Respir Dis* 1973;108:450-9.
- 17 Greenberger PA, Smith LJ, Hsu CCS, Roberts M, Liotta JL. Analysis of bronchoalveolar lavage in allergic bronchopulmonary aspergillosis: divergent responses of antigen specific antibodies and total IgE. *J Allergy Clin Immunol* 1988;82:164-70.
- 18 Longbottom JL, Harvey C, Taylor ML, Austwick PKC, Fitzharris P, Walker CA. Characterisation of immunologically important antigens and allergens of aspergillus fumigatus. *Int Arch Allergy Appl Immunol* 1989;88:185-6.
- 19 Robinson BWS, Venaille TJ, Mendis AHW, McAleer R. Allergens as proteases: an aspergillus fumigatus proteinase directly induces human epithelial cell detachment. *J Allergy Clin Immunol* 1990;86:726-31.
- 20 Greenberger PA. Allergic bronchopulmonary aspergillosis and fungoses. *Clin Chest Med* 1988;9:599-608.
- 21 Little SA, Price JA, Longbottom JL, Warner JO. Release of allergens/antigens from *Aspergillus fumigatus* cultures. *J Allergy Clin Immunol* 1990;85:277.