

Spontaneous infarction of the breast

J. J. LUCEY

From the Department of Histopathology, St. Bartholomew's Hospital, London

SYNOPSIS Five cases of infarction of physiological hyperplastic breast tissue associated with pregnancy or lactation are reported. These presented clinically as lumps in the breast, two of which were painful. Similar cases in the literature are briefly reviewed. The demonstration of an underlying lobular pattern in the present cases and the distribution of the infarcts support the view that the so-called 'adenoma' of pregnancy or lactation is a myth. Organizing vascular thrombi, previously unrecorded in this context, were seen in three of the five cases, and it is postulated that these lesions are the primary cause of the infarction rather than relative vascular insufficiency, as proposed by previous authors.

Spontaneous infarction of physiologically hyperplastic breast tissue associated with pregnancy or lactation is a recognized but rare clinical entity. Only 13 cases are recorded in the American and British literature (table) (Hasson and Pope, 1961;

Wilkinson and Green, 1964; Pambakian and Tighe, 1971; Rickert and Rajan, 1974). Vascular lesions were not demonstrated in these cases and so the pathogenesis of the infarction remains speculative. In this report, the clinical and pathological features of five cases are described, and evidence on the underlying mechanism of the infarction is presented.

Received for publication 9 June 1975.

<i>Author</i>	<i>Case</i>	<i>Race</i>	<i>Age</i>	<i>Breast</i>	<i>No of Lumps</i>	<i>Size (cm)</i>	<i>Pain</i>	<i>Status at Operation</i>	<i>Duration (weeks)</i>
Hasson and Pope (1961)	1	N	33	Right	1	3.5	No	17 d pp	7
	2	C	23	Right	1	3.0	No	7 d pp	4
	3	C	26	Right	1	1.0	No	3 wk pp	2
Wilkinson and Green (1964)	1 ¹	N	21	—	1	2.0	—	26 wk pp	40
	2 ¹	LA	18	Left	3	5.5	—	2 wk pp	52
				Right	1	1.5	—		
	5 ¹	N	26	—	1	7.0	—	5 wk pp	8
	6 ¹	N	21	—	1	4.0	—	1-2 wk pregnant	—
	7 ¹	N	20	—	1	2.0	—	6 wk pp	40
	10 ¹	N	20	—	1	3.5	—	6 wk pp	26
4	C	24	—	1	4.0	—	8 d pp	6	
Pambakian and Tighe (1971)	3	N	27	Left	2	5.0 each	Tender	1 wk pp	1
Rickert and Rajan (1974)	1 ¹	N	19	Left	2	2.0	No	8 wk pp	26
	2 ¹	N	17	Right	2	1.5 1.0 1.0	No No No	8 wk pp	12
Present series	1	C	23	Right	1	2.0	Tender	4 wk pp	2
	2	C	21	Left	1	2.5	No	3 wk pp	19
				Right	Many	0.5 each	No	3 wk pp	11
	3	N	18	Right	1	2.0	No	26 wk pp	34
	4	N	26	Left	1	2.0	Tender	36 wk pregnant	3
5	N	28	Right	1	0.5	No	26 wk pp	32	

Table Summary of cases

N = Negro; C = Caucasian; LA = Latin American

¹Reported as an adenoma

Case Reports

CASE 1

Eleven days after the normal delivery of her second child a 23-year-old woman, gravida 2 para 2, complained of a tender lump in the right breast. She was not breast feeding and breast binders were used to suppress lactation. There was no history of trauma or previous breast disease. Her first pregnancy three years previously had been normal, and shortly afterwards she was given oral contraceptives, Minovular for four months and Gynovular for a further six months. The mass was situated in the upper and outer quadrant of the breast, and a variety of clinical opinions were expressed regarding its nature, but infarction was not considered. The lump was excised four weeks after delivery and her postoperative progress was uneventful.

The excised breast tissue (St B H SH 1478/74) contained a well-circumscribed area measuring 2.0 cm in diameter with a uniform grey-yellow cut surface. Microscopically this was an area of coagulative necrosis of hyperplastic breast lobules (fig 1). In the necrosis the original reticulin architecture of lobules and acini was preserved (fig 2). The margin of the necrotic area was formed by a narrow rim of viable breast tissue associated with areas of haemorrhage and a moderate inflammatory cellular infiltration comprising lymphocytes, plasma cells, and many

eosinophils. Many haemosiderin-laden macrophages were also seen at the edge of the infarct. At least three smaller but similar discrete areas of necrosis were observed in adjacent mammary lobules. The residual breast tissue was normal, exhibiting variable secretory activity. In the interlobular collagenous tissue adjoining the infarcts, some medium-sized arteries and veins showed cellular intimal fibrous thickening which partly occluded the lumen of the vessels (fig 3). Many other vessels in the same region showed no evidence of thrombo-occlusive or inflammatory disease.

CASE 2

A 21-year-old primigravida noticed a painless lump in the left breast at 24 weeks' gestation. A similar lump appeared in the right breast at 32 weeks' gestation. There was no history of trauma or previous breast disease. She was admitted to hospital at 25 weeks' and 32 weeks' gestation with persistent vomiting which improved with bed rest. Four years previously she had been treated with Duphaston for three months and with Norlestrin for 18 months for dysmenorrhoea.

On examination a solitary mass was palpable in the left breast and at least two nodules in the right breast. The masses, thought to be multiple fibroadenomata, were situated in the lower and inner quadrants. At term she was delivered of a normal

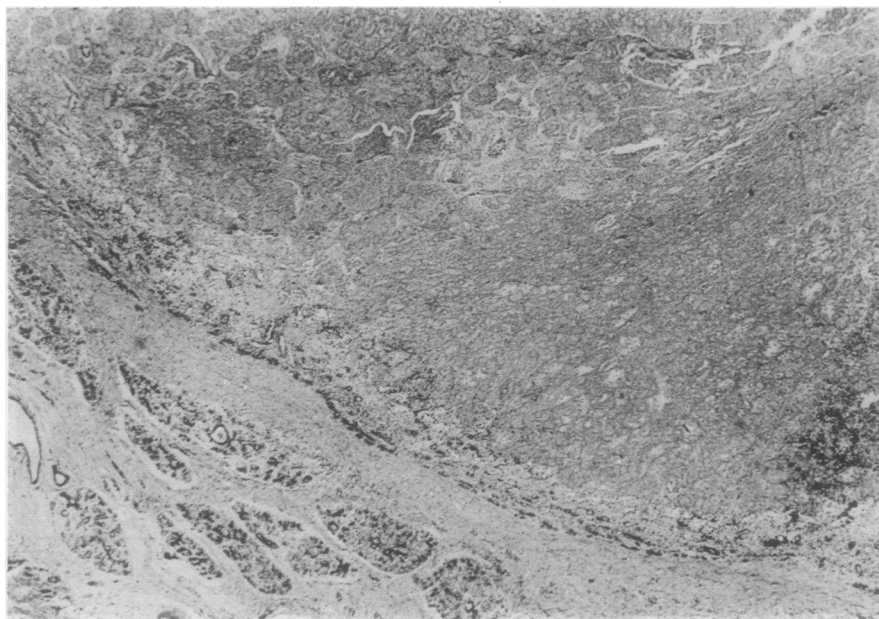


Fig 1 (Case 1)
The sharply circumscribed border of the infarct may give an initial impression of adenoma
(Haematoxylin and eosin $\times 25$).

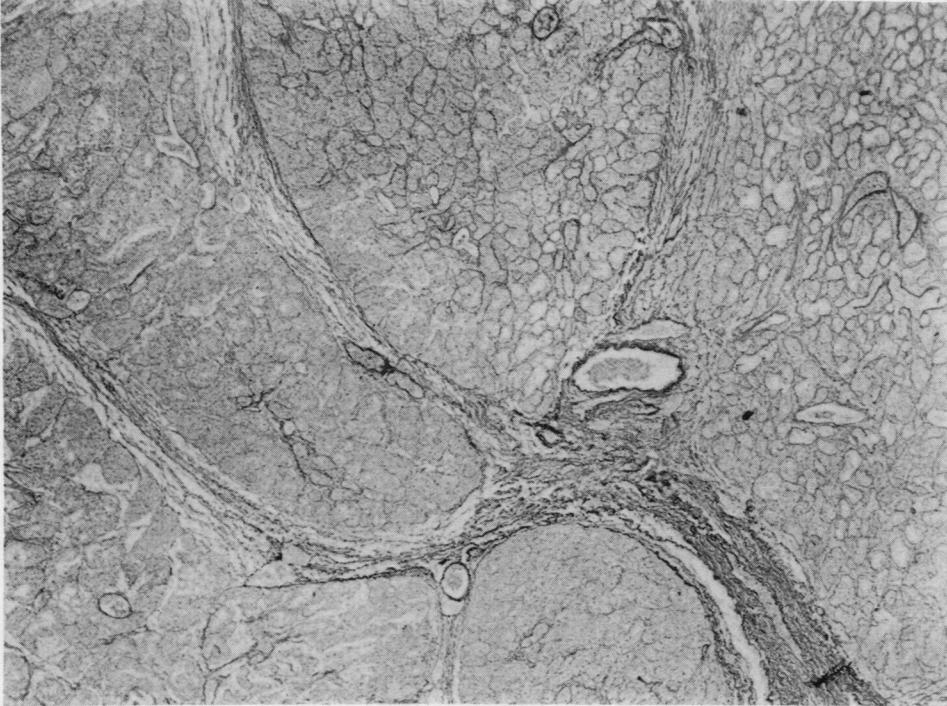


Fig 2 (Case 1)
Several hyperplastic lobules composed of closely packed acini (Gordon and Sweet's reticulin \times 150).

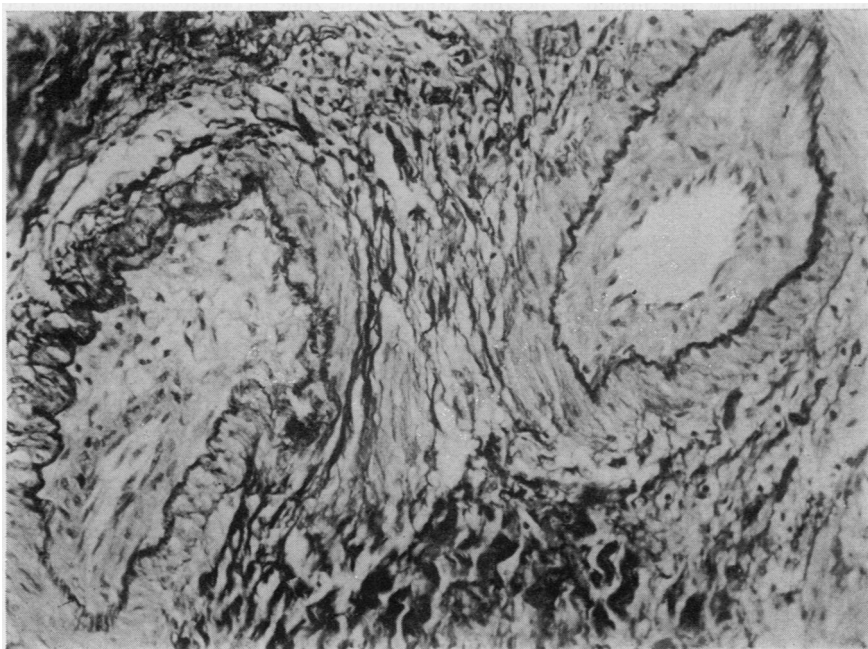


Fig 3 (Case 1)
Partial luminal obliteration of two medium-sized arteries by intimal fibrous tissue (Weigert's elastic van Gieson \times 215).

female infant which was not breast fed, lactation being suppressed with breast binders. Three weeks after delivery the masses were excised.

The mass from the left breast (St B H SH 2157/74) contained a central well-circumscribed soft area measuring 2.5 cm in diameter. Pale grey and reddish-brown areas were mixed with smaller yellow areas on the cut surface (fig 4). The tissue from the right breast measured 6.0 × 4.0 × 3.0 cm and contained several grey-white nodules which, on slicing, revealed central yellow areas, each approximately 0.5 cm in diameter.

Microscopic examination of the left breast mass revealed an almost confluent area of coagulative necrosis of hyperplastic breast lobules. Despite the extensive necrosis the original reticulin architecture of the lobules and acini was retained. An incomplete rim of viable breast acini and granulation tissue formed the margin of the infarct associated with many haemosiderin-laden macrophages, lymphocytes, and plasma cells. Broad trabeculae of dense fibrous tissue containing a sparse mononuclear infiltration and areas of finely granular calcification extended into the necrotic area from the marginal zone. Several nearby hyperplastic mammary lobules showed similar areas of coagulative necrosis which frequently involved only part of a lobule. The residual breast lobules were normal, exhibiting variable secretory activity. Several small veins and a few arteries in the interlobular collagenous tissue adjacent to the infarcts contained eccentric areas of intimal fibrosis which partly occluded the lumen. Definite organizing venous thrombi were seen in one area (fig 5). Many other vessels showed no evidence of thrombo-occlusive or inflammatory disease.

The right breast mass was composed of hyperplastic lobules, several of which showed partial

infarction (fig 6). Many foamy macrophages were seen in the infarcted areas, and there was a slight lymphocytic infiltration in the residual lobules. A few small veins in the interlobular collagenous tissue showed cellular fibrous thickening of the intima which partly occluded the lumen. Several other vessels appeared normal.

CASE 3

At 32 weeks' gestation of an otherwise normal pregnancy an 18-year-old negro primigravida noticed a painless lump in the right breast. There was no history of trauma, oral contraceptives or previous breast disease. On examination the mass, thought to be a fibroadenoma, was situated in the outer and lower quadrant. At term the delivery was normal and the infant was breast fed. The mass was excised six months later and postoperative progress was uneventful.

The excised breast tissue (St B H SH 2312/74) contained a sharply circumscribed nodule 2.0 cm in diameter with grey and yellow areas on the cut surface. Microscopically, as in the two preceding cases, there was extensive necrosis of hyperplastic breast lobules with ghost-like acini clearly seen in a reticulin preparation. The necrotic area was demarcated from the surrounding breast tissue by an irregular zone of dense collagenous tissue containing occasional ducts. Some ducts nearest the necrosis showed squamous metaplasia, and an incomplete layer of squamous epithelium lined a cleft-like space between the necrotic area and the zone of collagenous tissue. The boundary zone also contained many haemosiderin-laden macrophages, lymphocytes, and plasma cells. The surrounding breast tissue exhibited advanced post-lactational involution. The lumina of a few veins in the interlobular collagenous tissue near the

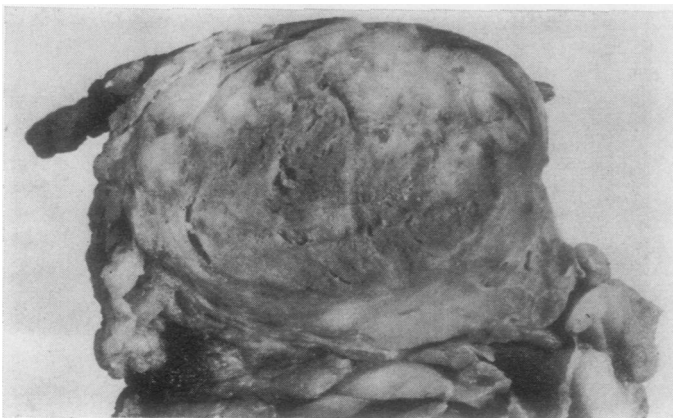


Fig 4 (Case 2) Cut surface of the well-circumscribed infarct from the left breast (× 2).

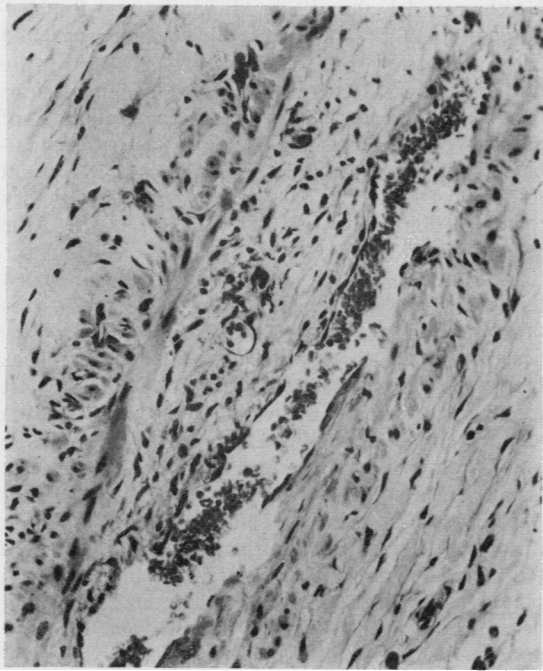


Fig 5 (Case 2) Organizing thrombus partly occluding the lumen of the vein (H and E \times 175).

infarct were partly obliterated by cellular fibrous thickening of the intima. Several other vessels were normal.

CASE 4

At 33 weeks' gestation of an otherwise normal pregnancy a 26-year-old negro primigravida complained of a tender lump in the left breast. There was no history of trauma or previous breast disease. As she had been a known case of homozygous sickle cell disease for 18 years, the recurrent pain in the muscles, bones, and abdomen, of which she had previously complained, were attributed to episodes of infarction, and the spleen which had been removed when she was 10 years old contained several infarcts. On examination the mass was situated in the upper and inner quadrant and an infarct was suspected. In view of the underlying blood disorder, a lower segment Caesarian section was performed at 36 weeks' gestation and a healthy female infant was delivered. The breast mass was also excised and postoperative recovery was satisfactory.

The excised breast tissue (St B H SH 2450/60) contained a sharply circumscribed area 2.0 cm in diameter with a yellow cut surface. Microscopically extensive necrosis of the lobules, sparing only an irregular rim of hyperplastic breast tissue with its

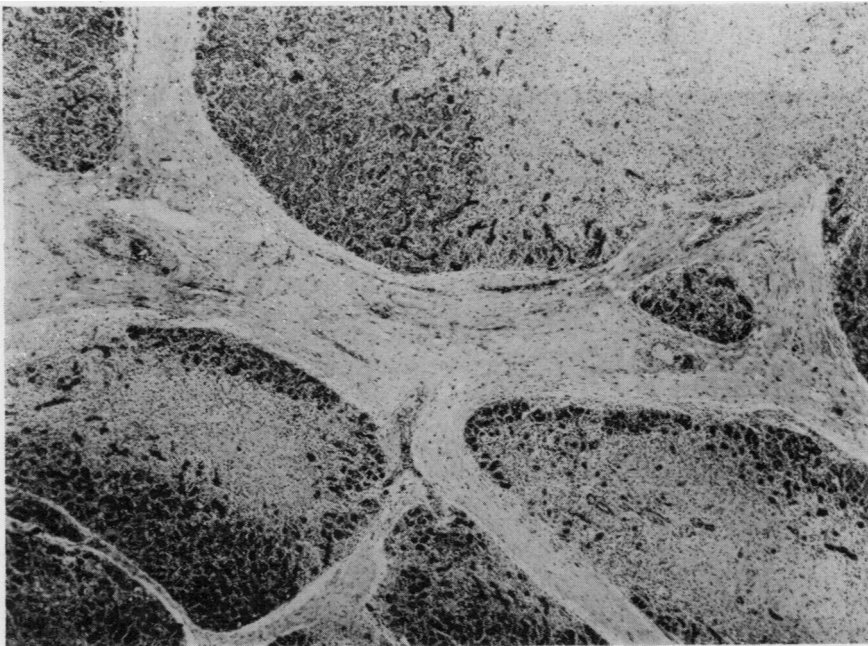


Fig 6 (Case 2) Partial infarction of hyperplastic breast lobules (H and E \times 37).

infiltrate of lymphocytes, plasma cells, and haemosiderin-laden macrophages, was as described in the preceding cases. In addition, the ducts at the edge of the necrotic area showed patches of squamous metaplasia. The surrounding breast lobules were normal, exhibiting variable secretory activity. The vessels in the interlobular collagenous tissue were normal.

CASE 5

At 34 weeks' gestation of an otherwise normal fifth pregnancy, a 28-year-old negro, gravida 5 para 2, 3 abortions, noticed a painless lump in the right breast. There was no history of trauma or previous breast disease. On examination the mass, thought to be a fibroadenoma, was situated in the upper and outer quadrant. At term she was delivered of a healthy male infant which was breast fed. The mass was excised six months after delivery.

The excised breast tissue (St B H SH 3401/69) measured 4.0 × 2.5 × 2.0 cm and contained a peripherally situated, stippled yellow area, 0.5 cm in diameter. Microscopically this area was composed of dense collagenous tissue in which several small ducts were embedded but the outline of the hyperplastic mammary lobules was still discernible. A narrow rim of viable breast tissue including many haemosiderin-laden macrophages and lymphocytes formed the boundary zone. The adjacent breast tissue showed advanced post-lactational involution. The vessels in the interlobular collagenous tissue were normal.

Discussion

Spontaneous infarction of physiologically hyperplastic breast tissue associated with pregnancy and lactation is rare. However, it may be commoner than is generally appreciated as three of the five cases in the present series were detected in the surgical material received in one department in a two-month period. The true incidence is difficult to assess since some cases are reported under the title of adenoma associated with pregnancy (Rickert and Rajan, 1974) or lactation adenoma (Wilkinson and Green, 1964). Study of the present cases leads one to believe that they are not true adenomata. The sharply circumscribed infarcted masses composed of enlarged, closely packed acini give an initial impression of an adenoma when compared with the adjacent involuting breast tissue. However, on closer inspection, especially with the aid of reticulin preparations, the true hyperplastic nature of the infarcted breast tissue is revealed. Infarction has also been reported in fibroadenomata of the breast (Wilkinson and Green, 1964; Haagensen, 191; Pambakian and Tighe, 1971;

Newman and Kahn, 1973; Majinudar and Rosales-Quintana, 1975) some of which were associated with pregnancy, but these neoplasms can readily be distinguished from the hyperplastic lesions mentioned above. The sporadic case reports of necrosis of the breast from various causes, particularly oral anticoagulant drugs (Davis *et al*, 1972), and the case of ischaemic fat necrosis in the mammary region (Robitaille *et al*, 1974) are irrelevant to the present study.

Infarction of physiologically hyperplastic breast tissue associated with pregnancy or lactation was first reported by Hasson and Pope in 1961. They described three cases which presented clinically as breast neoplasms. These were detected in the last month of pregnancy in two cases and on the sixth postpartum day in the third case. In 1964, Wilkinson and Green described 10 cases of infarction of breast lesions during pregnancy and lactation. They felt that the background lesion was an adenoma of lactation in six cases (table) and a fibroadenoma in two. In the remaining two cases, the underlying lesion was interpreted as lobular hyperplasia identical with that described by Hasson and Pope. In one of these patients, the mass had been present for six weeks and was removed on the eighth postpartum day. The other case was unusual as the patient had juvenile hypertrophy of both breasts. Bilateral reduction mammoplasty was performed at 13 years and again at 15 years of age. The infarcts were found in breast tissue removed during the third mammoplasty at three months' gestation when she was 16 years old. In view of the history of trauma, it is debatable whether this case is comparable. In 1971, Pambakian and Tighe described three examples of mammary infarction. In two, the underlying lesion was interpreted as a fibroadenoma. The third patient noticed two masses in the left breast on the first postpartum day. Microscopy of the resected masses revealed infarcted hyperplastic lactating breast tissue. Two cases of localized breast infarcts in pregnancy were recorded by Rickert and Rajan in 1974. Each patient had two nodules in the affected breast which were interpreted as adenomata. In case 4 of the present series, the patient suffered from homozygous sickle cell disease, which may have been responsible for the infarction, but there was no clinical evidence of pre-existing disease in the other four cases.

The salient features of the reported cases, together with those of the present series, are summarized in the table. The infarcts usually appeared in the third trimester of pregnancy or early in the puerperium. Clinically, they presented as palpable breast lumps which were sometimes painful. Transient tenderness was noted by two patients in this study, and the absence of pain may explain the long interval be-

tween the appearance and removal of the masses in the other three. Multiple nodules are often present, but bilateral lesions, as seen in case 2, are rare. As emphasized by previous writers, the importance of the lesions lies in their possible confusion with carcinoma, especially in rapid frozen sections. However, confusion is less likely if the possibility of infarction is considered and the diagnosis of malignancy is made only when viable tumour is identified.

The pathogenesis of infarction has not been established by previous authors. As vascular lesions were not demonstrated, it was proposed that infarction occurred because of relative vascular insufficiency resulting from increased metabolic demands of the breast tissue imposed by pregnancy and lactation. However, in the collagenous tissue close to the infarcts, obvious vascular lesions were detected in three of the five cases of the present series. In cases 1, 2, and 3, several veins showed striking intimal fibrosis, and in cases 1 and 2 some medium-sized arteries contained similar intimal thickening. These intimal thickenings were attributed to previous vascular thrombosis. This supposition was supported by the finding of definite organizing venous thrombi in case 2 (fig 5). The presence of apparently normal vessels in the vicinity of those affected suggested that the thrombosis was primary rather than secondary to the infarction. The most likely predisposing cause is pregnancy itself as there was no evidence of other vascular disease, and a history of trauma was not elicited. The role of the oral contraceptives in cases 1 and 2 remains speculative. It is proposed that the infarction is due to ischaemia that resulted from the

thrombosis, rather than relative vascular insufficiency which was postulated by Hasson and Pope (1961) and later reiterated by others.

I wish to thank Dr. A. G. Stansfeld for helpful advice in the preparation of this paper and Mr. P. Crocker for the photomicrography. I am also grateful to surgical colleagues for access to the clinical records of the patients under their care.

References

- Davis, C. E., Jr., Wiley, W. B., and Faulconer, R. J. (1972). Necrosis of the female breast complicating oral anticoagulant treatment. *Ann. Surg.*, **175**, 647-656.
- Haagensen, C. D. (Ed) (1971). *Diseases of the Breast*, 2nd ed., pp. 212-226. Saunders, Philadelphia.
- Hasson, J. and Pope, C. H. (1961). Mammary infarcts associated with pregnancy presenting as breast tumors. *Surgery*, **49**, 313-316.
- Majinudar, B. and Rosales-Quintana, S. (1975). Infarction of breast fibroadenomas during pregnancy. *J. Amer. med. Ass.*, **231**, 963-964.
- Newman, J. and Kahn, L. B. (1973). Infarction of fibroadenoma of the breast. *Brit. J. Surg.*, **60**, 738-740.
- Pambakian, H. and Tighe, J. R. (1971). Mammary infarction. *Brit. J. Surg.*, **58**, 601-602.
- Rickert, R. R. and Rajan, S. (1974). Localised breast infarcts associated with pregnancy. *Arch. Path.*, **97**, 159-161.
- Robitaille, Y., Seemayer, T. A., Thelmo, W. L., and Cumberland, M. C. (1974). Infarction of the mammary region mimicking carcinoma of the breast. *Cancer (Philad.)*, **33**, 1183-1189.
- Wilkinson, L. and Green, W. O., Jr. (1964). Infarction of breast lesions during pregnancy and lactation. *Cancer (Philad.)*, **17**, 1567-1572.