

# Clinical outcomes of osteonecrosis of the femoral head after autologous bone marrow stem cell implantation: a meta-analysis of seven case-control studies

Heng-feng Yuan,<sup>#</sup> Jing Zhang,<sup>#</sup> Chang-an Guo, Zuo-qin Yan\*

Fudan University, Zhongshan Hospital, Department of Orthopedics, Shanghai, China.

The purpose of this study was to evaluate the clinical outcomes of osteonecrosis of the femoral head after autologous bone marrow stem cell implantation. We searched the PubMed, Embase and Web of Science databases and included all case-control trials that reported on the clinical outcomes of osteonecrosis progression, incidence of total hip arthroplasty and improvement in Harris hip scores. Overall, seven case-control trials were included. Compared with the controls, patients treated with the bone marrow stem cells implantation treatment showed improved clinical outcomes with delayed osteonecrosis progression (odds ratio = 0.17, 95% CI: 0.09 – 0.32;  $p < 0.001$ ), a lower total hip arthroplasty incidence (odds ratio = 0.30, 95% CI: 0.12 - 0.72;  $p < 0.01$ ) and increased Harris hip scores (mean difference = 4.76, 95% CI: 1.24 – 8.28;  $p < 0.01$ ). The heterogeneity, publication bias, and sensitivity analyses showed no statistical difference significant differences between studies. Thus, our study suggests that autologous bone marrow stem cells implantation has a good therapeutic effect on osteonecrosis of the femoral, resulting in beneficial clinical outcomes. However, trials with larger sample sizes are needed to confirm these findings.

**KEYWORDS:** Osteonecrosis; Femoral Head; Bone Marrow; Meta-Analysis.

Yuan H, Zhang J, Guo C, Yan Z. Clinical outcomes of osteonecrosis of the femoral head after autologous bone marrow stem cell implantation: a meta-analysis of seven case-control studies. *Clinics*. 2016;71(2):110-113

Received for publication on August 19, 2015; First review completed on September 16, 2015; Accepted for publication on November 30, 2015

E-mail: zuoqin\_yan@163.com

\*Corresponding author

<sup>#</sup>contributed equally to the study.

## INTRODUCTION

Osteonecrosis of the femoral head (ONFH) is a debilitating and painful disease associated with multiple risk factors, such as trauma, corticosteroid administration, alcohol abuse, organ transplantation, and some inflammatory or autoimmune diseases (1,2). Without effective early treatment, this type of osteonecrosis can develop into femoral head collapse with subsequent hip joint destruction and patients may eventually require total hip arthroplasty (THA) to restore joint function (3). As ONFH mainly affects young and middle-aged adults and THA cannot be expected to last the patient's lifetime, hip-preserving treatments are especially important for these patients (4,5).

Recent reports (6,7) have shown that bone marrow stem cell (BMSC) implantation into the necrotic lesion of the femoral head is a promising cellular-based therapy. The pathogenesis of ONFH involves both vascular and bone pathology with

altered bone remodeling (8-10). BMSC function to promote angiogenesis and osteogenesis, although the number and activity of these cells are decreased in the femoral head of patients with ONFH (11,12). Hence, autologous BMSC implantation could be useful for the treatment of ONFH.

To date, several original trials (13-15) have reported the use of BMSC for ONFH treatment. However, the clinical outcomes were not conclusive. These inconclusive results could be attributed to the small sample size in each of the reported trials and the low statistical power of the individual studies. Therefore, in this study, we performed a meta-analysis to investigate the clinical outcomes of ONFH after BMSC implantation.

## METHODS

### Search strategy

This meta-analysis was performed in accordance with the PRISMA guidelines (16). A systematic literature search of PubMed, Embase and Web of Science databases through March 10, 2015 was conducted. Combinations of the terms "bone marrow stem cell" or "bone marrow mononuclear cell" or "bone marrow-derived cell"; "osteonecrosis" or "avascular necrosis"; and "femoral head" or "femur" were used without restricting the language or publication date. Relevant studies were retrieved accordingly. In addition, we

**Copyright** © 2016 CLINICS – This is an Open Access article distributed under the terms of the Creative Commons License (<http://creativecommons.org/licenses/by/4.0/>) which permits unrestricted use, distribution, and reproduction in any medium or format, provided the original work is properly cited.

No potential conflict of interest was reported.

**DOI:** 10.6061/clinics/2016(02)10



also checked the references of the articles to identify other relevant publications.

### Selection criteria

Two authors independently reviewed the titles and abstracts of potentially relevant studies. The inclusion criteria consisted of the following: (a) BMSC (including bone marrow cells or bone marrow mononuclear cells) implantation used to treat ONFH patients; (b) trials including a control group without BMSC implantation; (c) no less than one year of follow-up time; and (d) studies reporting at least one of the following clinical outcomes: ONFH progression, THA incidence and improvement of Harris hip scores (HHS). If the clinical outcomes were reported more than once by the same research group, we included the report with the longest follow-up time and the largest number of patients.

### Data extraction and quality assessment

For each trial, we extracted the following items: (a) the surname of the first author; (b) the year of publication; (c) the BMSC treatment method; (d) the number of patients; (e) the age of the patients; (f) the follow-up time; (g) the radiological ONFH progression at the last follow-up; (h) the THA incidence at the last follow-up; and (i) the changes in HHS at the last follow-up.

Quality assessments were performed independently by two authors, and any disagreements between authors were resolved by discussion. In addition, the evidence level of each study was determined according to the Cochrane handbook for systematic reviews of interventions (17).

### Statistical analysis

Analyses were performed using the software Review Manager, version 5.0 (RevMan, The Cochrane Collaboration, Oxford,

UK) and STATA package v.11.0 (Stata Corporation, College Station, TX, USA). Differences between patients receiving BMSC treatment and controls were expressed with the pooled odds ratio (OR) or mean difference (MD) and 95% confidence interval (CI). The fixed effect model was used for analysis. However, if significant heterogeneity existed between trials (a  $p$ -value of  $Q$  test  $<0.10$  or/and  $I^2 > 50\%$ ), the random effect model was used instead. Publication bias was evaluated with funnel plots using Egger's regression model. Sensitivity analyses were performed based on the "1-study removed" analyses. A  $p$ -value  $<0.05$  was considered statistically significant.

## RESULTS

### Trials included in the meta-analysis

A total of 3,320 articles were retrieved from the PubMed, Embase and Web of Science databases, of which 12 studies potentially met the identified criteria (Figure 1). Subsequently, 4 studies were excluded because they reported on early/pilot follow-up results; another study was excluded because the results were published twice in the same year in two different languages. In the end, 7 trials (13-15, 18-21) were included in the meta-analysis and their detailed characteristics are displayed in Table 1.

### Clinical outcomes after BMSC implantation

Among the 7 trials, 216 hips were treated with BMSC implantation, compared with 141 controls. No heterogeneities were observed between the two groups (ONFH progression:  $I^2 = 0\%$ ,  $p=0.69$ ; THA incidence:  $I^2 = 3\%$ ,  $p=0.39$ ; HHS:  $I^2=0\%$ ,  $p=0.79$ , respectively); hence, the fixed effect models were used. The overall meta-analysis including the 6 trials indicated that the pooled OR for ONFH progression was 0.17 (95% CI: 0.09 - 0.32;  $p < 0.001$ ) (Figure 2). The pooled OR for THA incidence was 0.30 (95% CI: 0.12 - 0.72;  $p < 0.01$ ) (Figure 3). The analysis of the improvement of HHS revealed

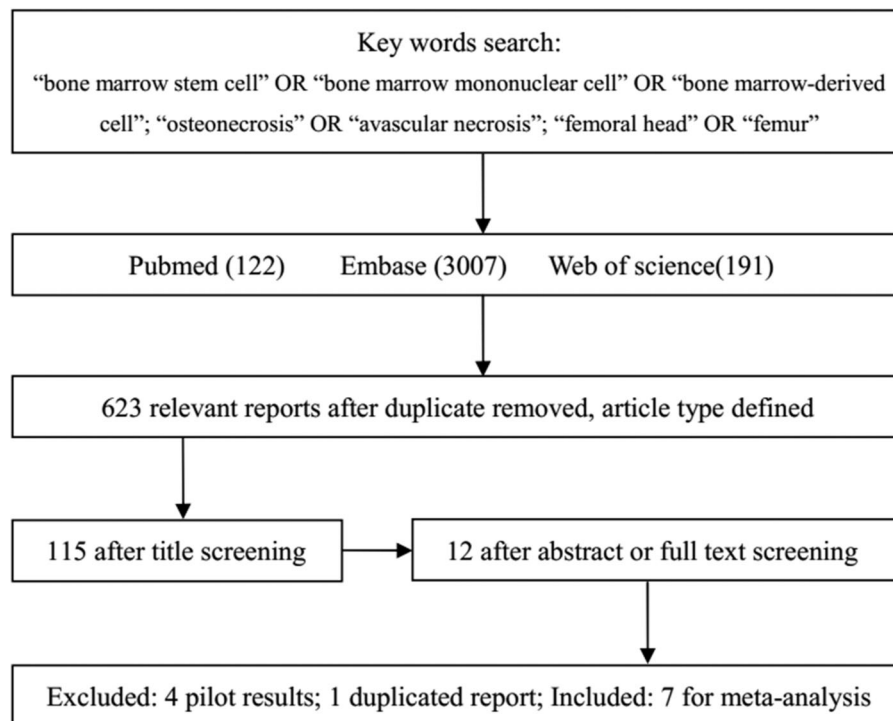


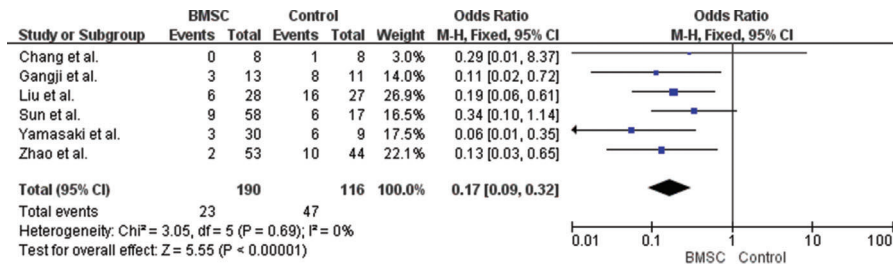
Figure 1 - Flowchart of the selection process for the meta-analysis.



**Table 1** - Characteristics of the 357 hips identified from the literature.

Authors	Year	Treatment	No. of patients (hips)	Age (mean)	Follow-up (months)
Sun et al.	2008	BMSC	Case/Control 45(58)/13(17)	Case/Control 37.5/37.3	Case/Control 12/12
Yamasaki et al	2010	BMMC + IP-CHA	22(30)/8(9)	41/49	29/31
Chang et al	2010	BMSC	4(8)/4(8)	-/-	23.5/23.5
Gangji et al.	2011	BMSC	13/11	42.2/45.7	60/60
Zhao et al.	2012	BMSC	50(53)/43(44)	32.7/33.8	60/60
Sen et al.	2012	BMMC	20(26)/20(25)	-/-	24/24
Liu et al.	2013	BMMC + NH/PA	17(28)/17(27)	38.0/38.1	26.7/24.9

**Note:** BMSC: bone marrow stem cells, BMMC: bone marrow mononuclear stem cells, IP-CHA, NH/PA: both are implant materials.



**Figure 2** - Forest plot for the progression of osteonecrosis of the femoral head after bone marrow stem cell implantation.

that the pooled MD was 4.76 (95% CI: 1.24 – 8.28;  $p < 0.01$ ) (Figure 4). These results indicated that patients who underwent BMSC implantation showed significantly better clinical outcomes than the control group.

**Publication bias and sensitivity analysis**

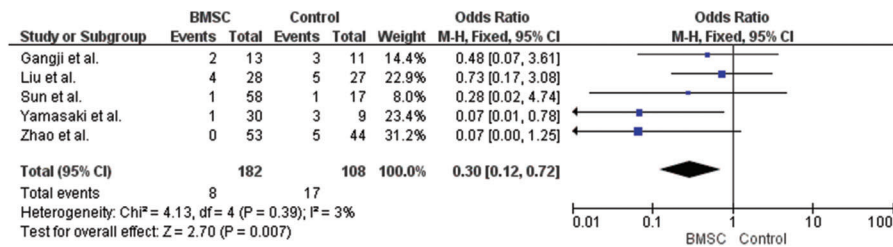
No significant publication bias ( $p > 0.05$ ) was found in any of the pooled comparisons based on Egger’s test for funnel plot asymmetry (Figure 5 for detection of THA incidence comparison). In addition, the sensitivity analysis showed no changes in the results when any trial was excluded.

**DISCUSSION**

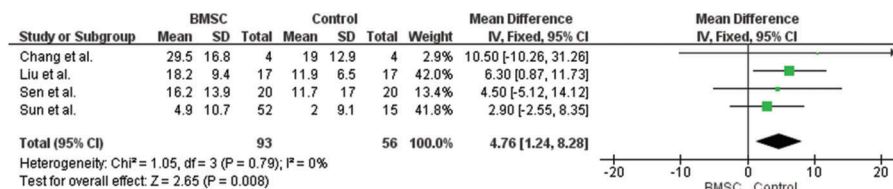
BMSC implantation is an effective method for the treatment of ONFH. These cells can be isolated from individual patients

without heterologous hazards or ethical questions (22) and no direct complications have ever been reported following this type of therapy (6). BMSC show multi-potential capacities to differentiate into osteoblasts, endothelial cell progenitors and hemangioblasts, which function to repair the necrosis region of the femoral head (22,23). In addition, reports (24,25) have shown that BMSC also release a variety of growth factors, such as VEGF-A, to facilitate bone regeneration. Our previous research (25) demonstrated that BMSC can not only survive but also expand in the necrotic area for up to 12 weeks after implantation.

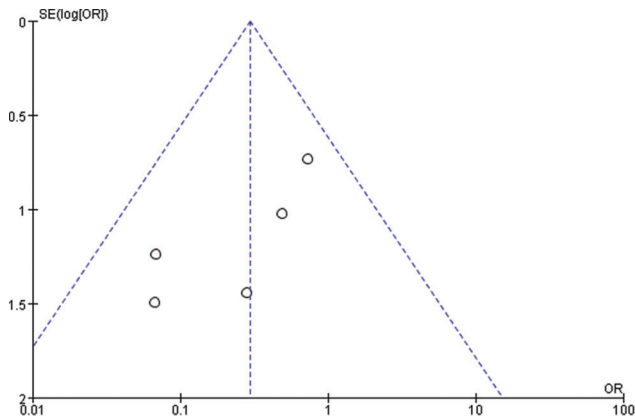
Although randomized, controlled trials would provide the strongest evidence, few randomized trials have reported on the application of BMSC implantation for the treatment of ONFH. The next-best alternative is comparative case-control trials; however, these reports have shown conflicting clinical



**Figure 3** - Forest plot for the arthroplasty incidence after bone marrow stem cell implantation.



**Figure 4** - Forest plot for the HHS improvement after bone marrow stem cell implantation.



**Figure 5** - Funnel plot for the detection of publication bias (comparison of arthroplasty incidence).

outcomes, which may be due to the small sample sizes and low statistical power of the studies. Hence, in this study, we performed a comprehensive and systematic analysis of the data from 6 independent case-control trials. The results showed that BMSC implantation delayed the progression of ONFH and decreased the need for THA. In addition, BMSC implantation may also improve hip function, as demonstrated by the increased HHS in treated patients.

There are some limitations in our study that should be considered. First, although seven independent studies were included, the total number of cases and controls in the meta-analysis was relatively small. Second, the methods of BMSC implantation reported in these trials were not completely uniform, which could have influenced the validity of our analysis. Third, we failed to analyze the changes in the volume of the necrotic lesion as insufficient data were reported in the included studies.

In summary, our study found that BMSC implantation resulted in better clinical outcomes of ONFH, delayed ONFH progression, decreased THA incidence and improved HHS. However, further studies with larger sample sizes are needed to confirm these results.

## ACKNOWLEDGMENTS

This work was supported by the National Natural Science Foundation of China (No. 81371966) and the Major Program for the Fundamental Research of Shanghai (No. 2014ZYJB0302).

## AUTHOR CONTRIBUTIONS

Yan Z developed the idea for the study and drafted the manuscript. Yuan H and Zhang J were responsible for conducting the literature search, data collection and study quality assessment. Yuan H and Guo C analyzed and interpreted the data. All the authors read and approved the final version of the manuscript.

## REFERENCES

- Chang CC, Greenspan A, Gershwin ME. Osteonecrosis: current perspectives on pathogenesis and treatment. *Semin Arthritis Rheum.* 1993;23(1):47-69, [http://dx.doi.org/10.1016/S0049-0172\(05\)80026-5](http://dx.doi.org/10.1016/S0049-0172(05)80026-5).
- Herndon JH, Aufranc OE. Avascular necrosis of the femoral head in the adult. A review of its incidence in a variety of conditions. *Clin Orthop Relat Res.* 1972; 86:43-62.
- Hernigou P, Poignard A, Nogier A, Manicom O. Fate of very small asymptomatic stage-I osteonecrotic lesions of the hip. *J Bone Joint Surg Am.* 2004; 86-A(12):2589-93.
- Mankin HJ. Nontraumatic necrosis of bone (osteonecrosis). *N Engl J Med.* 1992; 326(22):1473-9, <http://dx.doi.org/10.1056/NEJM199205283262206>.
- Mont MA, Hungerford DS. Non-traumatic avascular necrosis of the femoral head. *J Bone Joint Surg Am.* 1995;77(3):459-74.
- Hernigou P, Flouzat-Lachaniette CH, Delambre J, Poignard A, Allain J, Chevallier N, et al. Osteonecrosis repair with bone marrow cell therapies: state of the clinical art. *Bone.* 2015;70:102-9, <http://dx.doi.org/10.1016/j.bone.2014.04.034>.
- Lau RL, Perruccio AV, Evans HM, Mahomed SR, Mahomed NN, Gandhi R. Stem cell therapy for the treatment of early stage avascular necrosis of the femoral head: a systematic review. *BMC Musculoskelet Disord.* 2014;15:156, <http://dx.doi.org/10.1186/1471-2474-15-156>.
- Bejar J, Peled E, Boss JH. Vasculature deprivation-induced osteonecrosis of the rat femoral head as a model for therapeutic trials. *Theor Biol Med Model.* 2005;2:24, <http://dx.doi.org/10.1186/1742-4682-2-24>.
- Johnson EO, Soultanis K, Soucacos PN. Vascular anatomy and micro-circulation of skeletal zones vulnerable to osteonecrosis: vascularization of the femoral head. *Orthop Clin North Am.* 2004;35(3):285-91,viii, <http://dx.doi.org/10.1016/j.jocl.2004.03.002>.
- Yamamoto T, Irisa T, Sugioka Y, Sueishi K. Effects of pulse methylprednisolone on bone and marrow tissues: corticosteroid-induced osteonecrosis in rabbits. *Arthritis Rheum.* 1997;40(11):2055-64, <http://dx.doi.org/10.1002/art.1780401119>.
- Gangji V, Hauzeur JP, Schoutens A, Hinsenkamp M, Appelboom T, Egrise D. Abnormalities in the replicative capacity of osteoblastic cells in the proximal femur of patients with osteonecrosis of the femoral head. *J Rheumatol.* 2003; 30(2):348-51.
- Hernigou P, Beaujean F. Abnormalities in the bone marrow of the iliac crest in patients who have osteonecrosis secondary to corticosteroid therapy or alcohol abuse. *J Bone Joint Surg Am.* 1997;79(7):1047-53.
- Gangji V, De Maertelaer V, Hauzeur JP. Autologous bone marrow cell implantation in the treatment of non-traumatic osteonecrosis of the femoral head: Five year follow-up of a prospective controlled study. *Bone.* 2011; 49(5):1005-9, <http://dx.doi.org/10.1016/j.bone.2011.07.032>.
- Yamasaki T, Yasunaga Y, Ishikawa M, Hamaki T, Ochi M. Bone-marrow-derived mononuclear cells with a porous hydroxyapatite scaffold for the treatment of osteonecrosis of the femoral head: a preliminary study. *J Bone Joint Surg Br.* 2010;92(3):337-41, <http://dx.doi.org/10.1302/0301-620X.92B3.22483>.
- Sun W, Li Z, Wang B, Shi Z, Shi S. Core decompression plus implantation of autologous bone marrow stem cells for early stage osteonecrosis of the femoral head: A follow-up evaluation. *J Clin Rehab Tis Eng Res.* 2008;12(12):2231-4.
- Moher D, Liberati A, Tetzlaff J, Altman DG, PRISMA Group. Preferred reporting items for systematic reviews and meta-analyses: the PRISMA statement. *PLoS Med.* 2009;6(7):e1000097.
- Higgins JPT, Altman DG. Assessing risk of bias in included studies. In: Higgins JPT, Green S, editors. *Cochrane handbook for systematic reviews of interventions* version 5.01. ChichesterUK: Wiley; 2008, <http://dx.doi.org/10.1002/9780470712184.fmatter>.
- Zhao D, Cui D, Wang B, Tian F, Guo L, Yang L, et al. Treatment of early stage osteonecrosis of the femoral head with autologous implantation of bone marrow-derived and cultured mesenchymal stem cells. *Bone.* 2012; 50(1):325-30, <http://dx.doi.org/10.1016/j.bone.2011.11.002>.
- Sen RK, Tripathy SK, Aggarwal S, Marwaha N, Sharma RR, Khandelwal N. Early results of core decompression and autologous bone marrow mononuclear cells instillation in femoral head osteonecrosis: a randomized control study. *J Arthroplasty.* 2012;27(5):679-86, <http://dx.doi.org/10.1016/j.arth.2011.08.008>.
- Liu Y, Liu S, Su X. Core decompression and implantation of bone marrow mononuclear cells with porous hydroxylapatite composite filler for the treatment of osteonecrosis of the femoral head. *Arch Orthop Trauma Surg.* 2013;133(1):125-33, <http://dx.doi.org/10.1007/s00402-012-1623-3>.
- Chang T, Tang K, Tao X, Cao H, Li H, Chen Q, et al. Treatment of early avascular necrosis of femoral head by core decompression combined with autologous bone marrow mesenchymal stem cells transplantation. *Zhongguo Xiu Fu Chong Jian Wai Ke Za Zhi.* 2010;24(6):739-43.
- Bianco P, Riminucci M, Gronthos S, Robey PG. Bone marrow stromal stem cells: nature, biology, and potential applications. *Stem Cells.* 2001; 19(3):180-92.
- Conway EM, Collen D, Carmeliet P. Molecular mechanisms of blood vessel growth. *Cardiovasc Res.* 2001;49(3):507-21, [http://dx.doi.org/10.1016/S0008-6363\(00\)00281-9](http://dx.doi.org/10.1016/S0008-6363(00)00281-9).
- Murphy MB, Moncivais K, Caplan AI. Mesenchymal stem cells: environmentally responsive therapeutics for regenerative medicine. *Exp Mol Med.* 2013;45:e54, <http://dx.doi.org/10.1038/emm.2013.94>.
- Yan Z, Hang D, Guo C, Chen Z. Fate of mesenchymal stem cells transplanted to osteonecrosis of femoral head. *J Orthop Res.* 2009; 27(4):442-6, <http://dx.doi.org/10.1002/jor.20759>.