

# Malignant lymphoma of the cervix uteri: histology and ultrastructure

I. CARR<sup>1</sup>, A. S. HILL, B. HANCOCK, AND F. E. NEAL

*From Weston Park Hospital and Jessop Hospital, Sheffield*

**SYNOPSIS** Two cases of primary lymphoma of the cervix uteri are described. Both responded to radiotherapy; both were composed at the ultrastructural level of mature macrophages and immature, apparently neoplastic lymphoreticular cells and are classified as reticulum cell lymphoma.

Primary extranodal malignant lymphoma is not uncommon and a wide variety of organs may be involved. Primary lymphoma of the uterus is however extremely rare. Chorlton *et al* (1974), in an extensive review of the world literature, found only 23 reports and added nine cases of their own. Of these 32 cases, the corpus uteri was the site of involvement in seven cases and the cervix in 25. We report clinical and ultrastructural details of two patients presenting with apparently localized cervical lymphoma. Ultrastructural findings have not been reported previously.

## Case Reports

### CASE 1

This 44-year-old patient presented with a five-month history of watery vaginal discharge, heavy menstrual periods, and two episodes of intermenstrual bleeding, one post-coital. General examination was normal and a cervical smear was negative. Gynaecological examination under general anaesthesia showed an endocervical mass about 8 cm in diameter with subepithelial infiltration around the vaginal fornices. Initial investigations including haemoglobin, differential white blood cell count, ESR (Westergren), chest x-ray, lymphogram, bone marrow examination, intravenous pyelogram, and liver function tests were all normal. Treatment was given by a standard radiation technique as used in Sheffield for the treatment of carcinoma of the cervix. A single insertion of intrauterine and intravaginal <sup>137</sup>Cs was followed by megavoltage irradiation to the pelvic and para-aortic lymph nodes. The cervix received 11 200 rads over 30 days; the

<sup>1</sup>Present address: Department of Pathology, University of Saskatchewan, Canada S7N 0W0

Received for publication 13 January 1976

para-aortic region received the standard lymphoma dose of 3500 rads. This was tolerated extremely well, though blood counts showed temporary pancytopenia. Before therapy was completed the cervix had returned to normal dimensions. She has now been followed up for three years and there has been no evidence of local recurrence or of lymphoma dissemination.

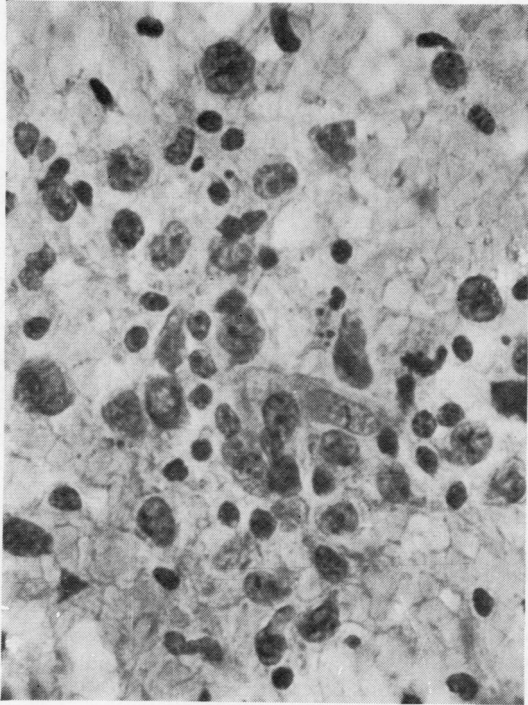
### CASE 2

This 60-year-old patient presented with a two-month history of postmenopausal vaginal blood loss. She had no systemic symptoms and general examination was normal. The cervical smear was positive (see below). Gynaecological examination showed an ulcerated cervical tumour with some parametrial extension. On investigation the haemoglobin, differential white blood count, chest x-ray, lymphogram, intravenous pyelogram, bone marrow examination, liver function tests, serum immunoglobulins, and T lymphocyte function (*in vivo* and *in vitro*) were normal. The ESR (Westergren) was raised to 77 mm/hour.

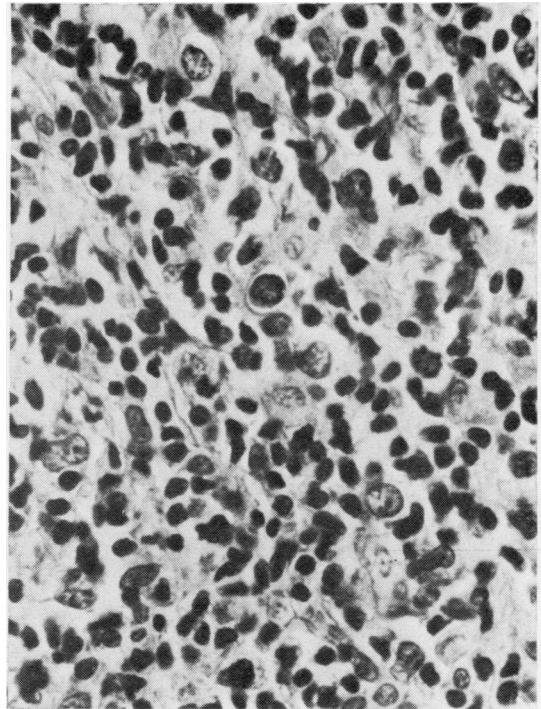
Treatment was essentially the same as in case 1, although she had two insertions of intracavitary <sup>137</sup>Cs. The cervix received a total of 13 500 rads and the para-aortic region 4500 rads. This was well tolerated, though temporary pancytopenia resulted. Six months after radiotherapy she is asymptomatic, and gynaecological examination is normal but the ESR is still raised.

## Cytology and Histology

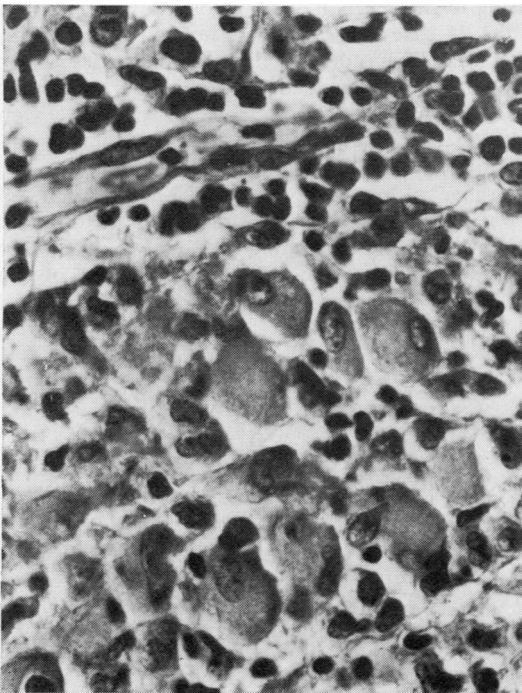
The cervical smear in case 1 was negative; in case 2 the smear showed malignant cells smaller than the usual carcinoma cells, lying singly. Many had bilobed nuclei with large nucleoli (fig 1).



**Fig 1**



**Fig 2**



**Fig 3**

**Fig 1** Cervical cytology smear showing tumour cells with lobulated nuclei and prominent nucleoli (Papanicolaou  $\times 612$ ).

**Fig 2** A typical area of the tumour showing lymphocytic cells and larger malignant reticulum cells (Haematoxylin and eosin  $\times 612$ ).

**Fig 3** Large malignant cells with abundant eosinophilic cytoplasm resembling histiocytes (H and E  $\times 612$ ).

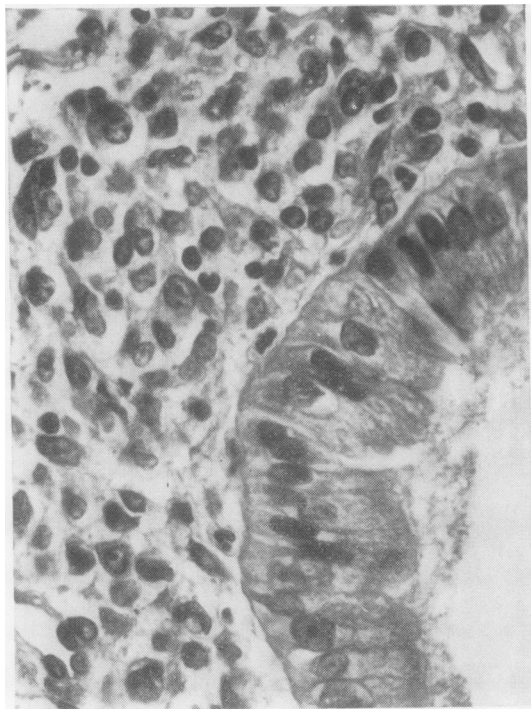

Fig 4 Tumour cells beneath intact columnar epithelium of the endocervix (H and E  $\times$  612).

Both cases at light microscopic level showed diffuse infiltration of cervical connective tissue by mixed cells, some clearly lymphocytes and some larger with eosinophilic cytoplasm (fig 2). Some of the eosinophilic cells, presumably neoplastic, were very large indeed and can be described as malignant reticulum cells (fig 3). In many areas the cervical epithelium was normal and intact over the tumour (fig 4). Both tumours showed a heavy reticulin network (fig 5).

The ultrastructure was studied with a transmission electron microscope after routine glutaraldehyde-osmium-Araldite-processing. At EM level both cases showed many large macrophages, with the characteristic irregular shape, numerous lysosomes, and granular endoplasmic reticulum of this cell type (fig 6). Many of these cells showed large vacuoles (fig 7). There was no evidence that these cells were neoplastic.

The other cell type present had pale cytoplasm with long channels of endoplasmic reticulum, prominent ribonucleoprotein particles, and a widely variable lysosome content. Some of these cells had strikingly large mitochondria (fig 7). The lysosome content of these cells was more marked in case 2 than in case 1. These cells had large nucleoli and were probably neoplastic; it is not certain to which cell line they belong. Some of them contained moderate numbers of lysosomal bodies and bore a general resemblance to macrophages (fig 8).

#### Discussion

Although the uterus was found to be involved at necropsy in 9-16% of cases of disseminated lymphoma of various types (Richmond *et al*, 1962) and Lathrop (1967) found the cervix to be involved in 6% of such cases, primary malignant lymphoma arising in the cervix is very uncommon. In addition to the 25 cases reviewed by Chorlton *et al* (1974), Wright (1973) has described two similar cases; if our two patients are included, the total reported, to our knowledge, is now 29. In Sheffield, we have seen only the two cases reported here in a total of approximately 25 000 primary cervical tumours. The age range of reported cases is 23-88 (median 43) years and the commonest presenting features are abnormal vaginal bleeding and pelvic mass. To merit the diagnosis of primary lymphoma of the cervix the lesion must be confined to the cervical

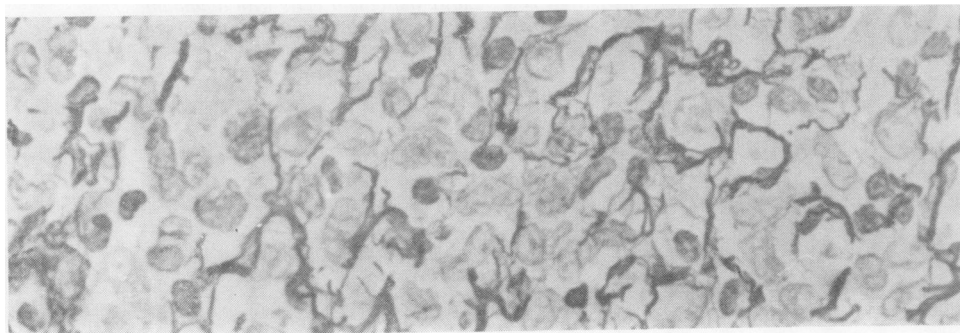


Fig 5 Area of tumour showing reticulin network (Silver reticulin  $\times$  665).

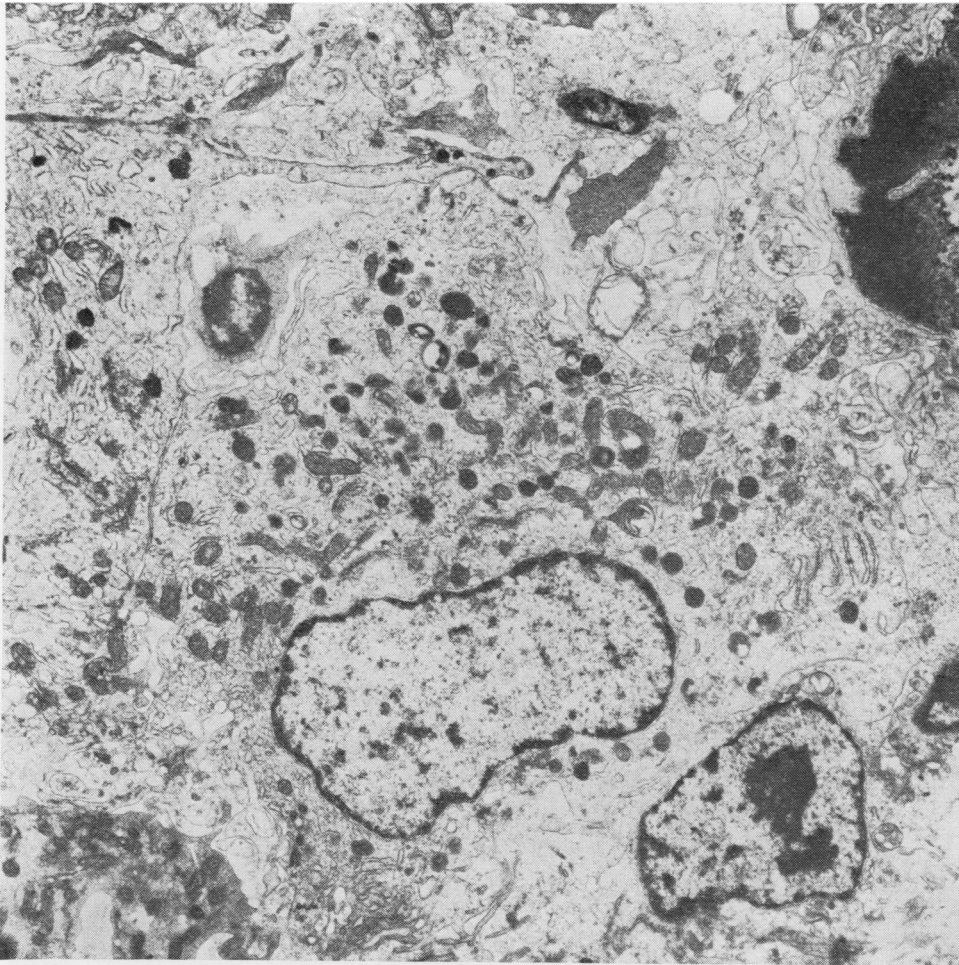


Fig 6  
*Large mature  
macrophage  
irregular in  
shape with  
peripheral  
pseudopodia  
and  
numerous  
lysosomes  
(EM ×  
6650).*

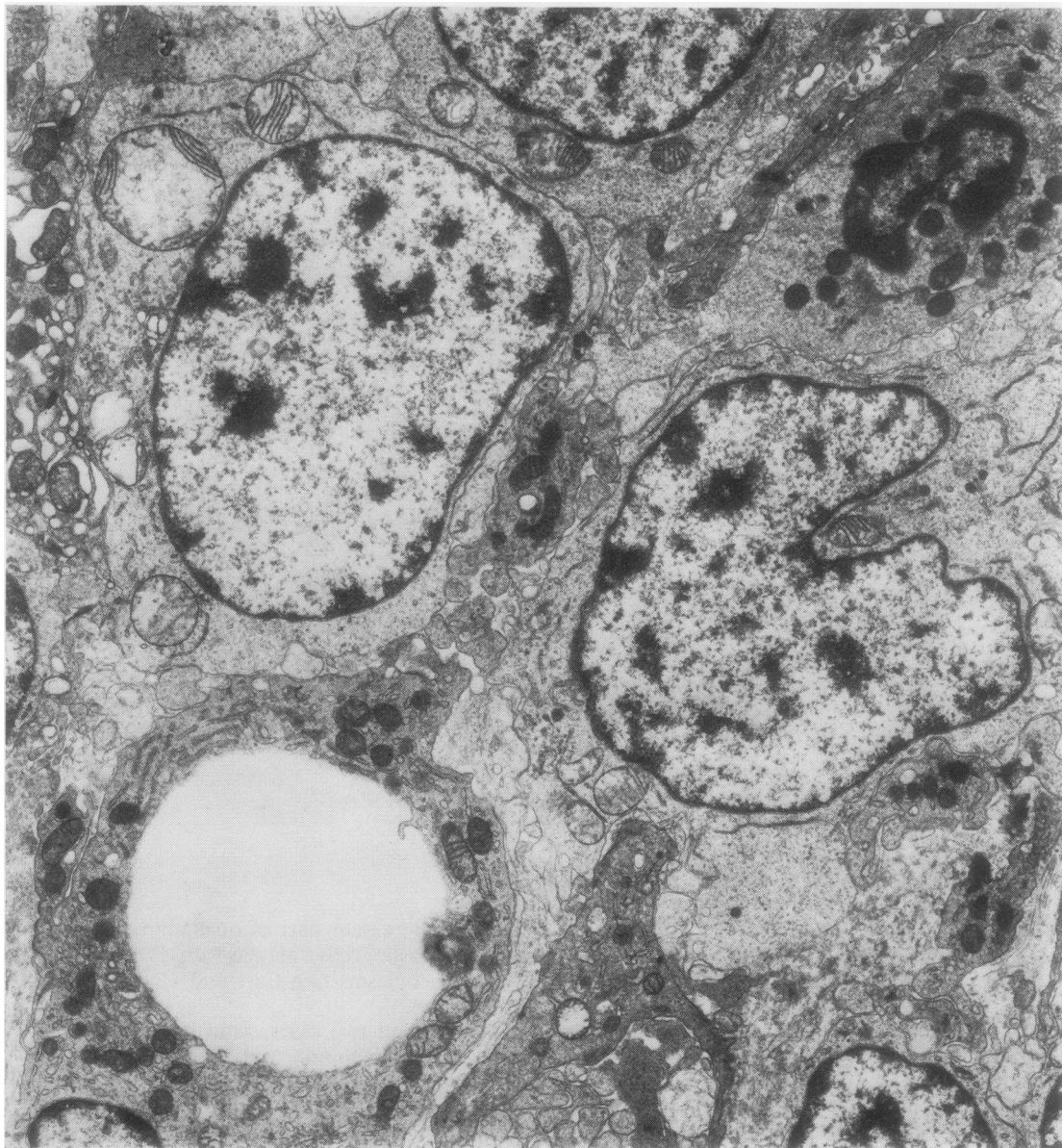
region at the time of diagnosis and there should be no evidence of lymphoma developing elsewhere for at least several months (Fox and More, 1965). Our patients meet both these criteria.

The histological diagnosis does not differ from that of lymphoma elsewhere. Preservation of the overlying cervical epithelium and glands is often a feature, as in our case 1 where there was no ulceration and consequently cervical cytology was normal. In case 2, ulceration had occurred and abnormal cells were seen in the smear.

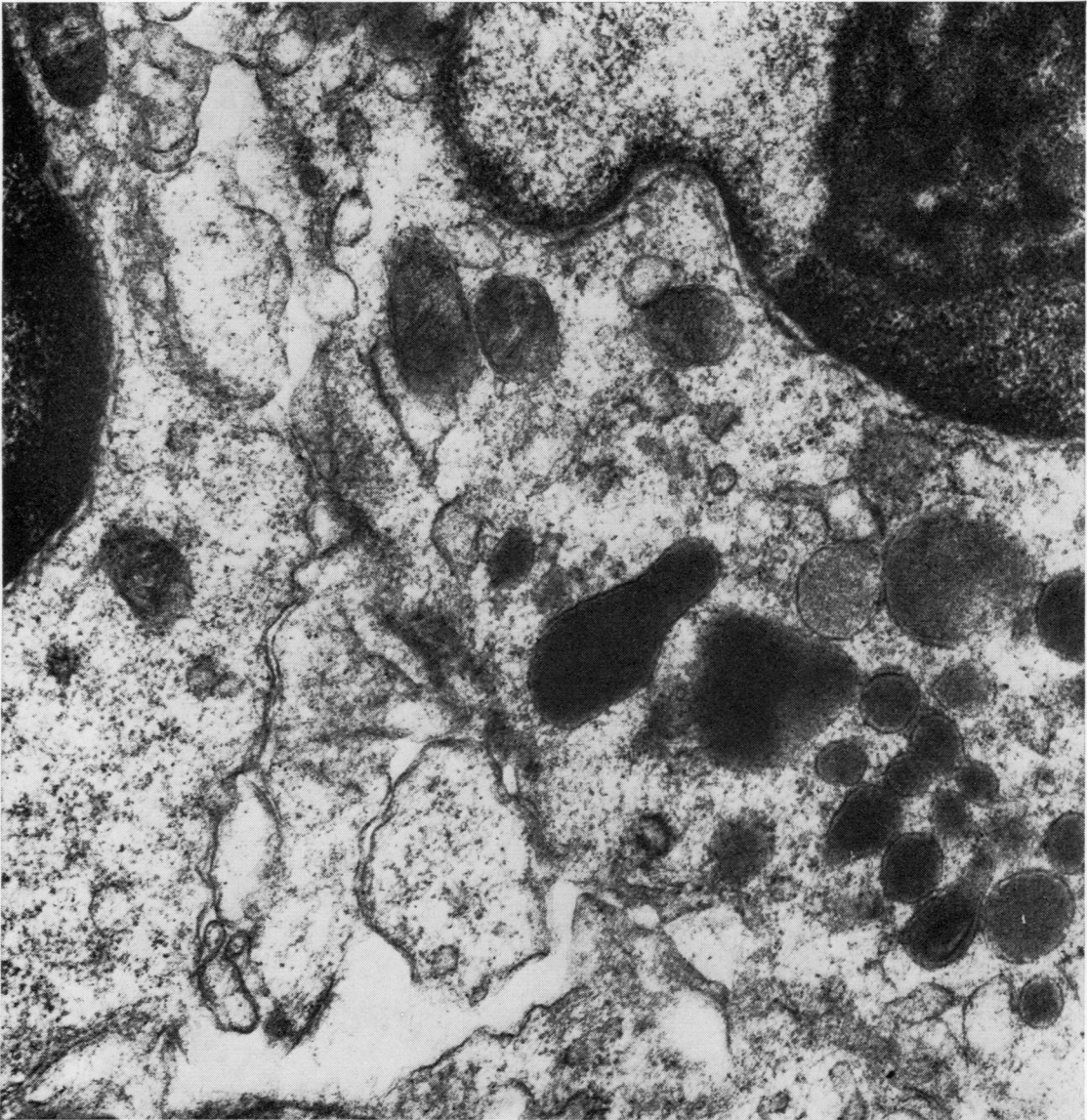
The ultrastructural changes of cervical lymphoma have not previously been described. As in so many lymphoreticular neoplasms, there are at least two components present. The mature macrophages seen resemble those encountered elsewhere in the body

and may represent part of an immune response to the neoplastic cells, as they do in some experimental neoplasms (see Carr and Underwood, 1974 for review).

The present two cases could best be regarded as malignant lymphoma, reticulum-cell type, until more general agreement is reached on classification. This group of tumours would be agreed by most to include many B-cell lymphomas and some lymphomas of genuinely histiocytic (or macrophage) type. The number of lysosomes present in what are clearly neoplastic cells suggests that the present lesions are in part, at any rate, genuinely histiocytic. A full discussion of the conflicting views on the classification of non-Hodgkins lymphoma is found in a recent symposium (Lukes and Collins, 1975).



**Fig 7** *Two neoplastic cells with large nuclei and prominent mitochondria and a macrophage with a large intracytoplasmic vacuole ( $\times 7665$ ).*



**Fig 8** *Detail of neoplastic cell with prominent nucleolus showing numerous lysosomes of homogeneous finely granular structure. Such lysosomes are similar to those found in macrophages ( $\times 30\ 665$ ).*

We thank Mr T. Smith and Mr D. R. Millar, under whose care the patients were originally admitted.

We are grateful to Mr Peter Norris for technical help and to the Cancer Research Campaign (Yorkshire Branch) for financial assistance.

#### References

- Carr, I. and Underwood, J. C. E. (1974). The ultrastructure of the local cellular response to neoplasia. *Int. Rev. Cytol.*, **37**, 329-347.
- Chorlton, I., Karnei, R. F., Jr., King, F. M., and Norris, H. J. (1974). Primary malignant reticuloendothelial disease involving the vagina, cervix, and corpus uteri. *Obstet. and Gynec.*, **44**, 735-748.
- Fox, H. and More, J. R. S. (1965). Primary malignant lymphoma of the uterus. *J. clin. Path.*, **18**, 723-728.
- Lathrop, J. C. (1967). Malignant pelvic lymphomas. *Obstet. and Gynec.*, **30**, 137-145.
- Lukes, R. J. and Collins, R. D. (1975). New approaches to the classification of the lymphomata. *Brit. J. Cancer*, **31**, Supplement II, 1-28.
- Richmond, J., Sherman, R. S., Diamond, H. D., and Craver, L. F. (1962). Renal lesions associated with malignant lymphomas. *Amer. J. Med.*, **32**, 184-207.
- Wright, C. J. E. (1973). Solitary malignant lymphoma of the uterus. *Amer. J. Obst. Gynec.*, **117**, 114-120.