

# Pathology of 'non-healing (midline) granuloma'<sup>1</sup>

L. MICHAELS AND MONICA M. GREGORY

*From the Department of Pathology, Institute of Laryngology and Otology, University of London*

**SUMMARY** In a histological study of biopsy and postmortem material from 30 cases of nasal disease in which a clinical diagnosis of 'midline granuloma' or Wegener's granuloma had been given, we selected 10 cases on the basis of the presence of widespread coagulative necrosis and atypical cells. Evidence is provided that such changes represent a malignant neoplasm of histiocytic lymphoma type. Local invasion and spread to cervical and more distant lymph nodes, spleen, liver, and kidney were seen in some of the cases. Erythrophagocytic activity was marked in the spleen in three cases and histiocytic infiltration of the bone marrow in two cases, indicating a more generalised activity of histiocytic cells. Terms such as 'malignant granuloma' should be abandoned. In obstructive and ulcerating conditions of the nose efforts should be concentrated on making an accurate histological diagnosis.

A condition variously referred to as non-healing granuloma, midline granuloma, malignant granuloma, granuloma gangrenescens or Stewart's granuloma is characterised by a relentlessly progressive ulceration of the nose and adjacent structures.

Stewart (1933) described 10 such cases in detail, and his paper has been regarded as a classic source on the subject. While credit must be given to Stewart for drawing attention to a clinical condition of relentless ulceration of the nose, his acceptance of it as a granulomatous one does not seem to have been based on adequate pathological criteria. In at least two of the cases the histology was thought to bear some resemblance to the 'very atypical spheroidal carcinomas seen in this region'. In one of the latter cases it is stated that multiple metastases to the lungs were probably present.

Friedmann (1955, 1963) was impressed by the similarity of 'non-healing granuloma' to Wegener's granuloma. He suggested that 'non-healing granuloma' had two forms: (1) Stewart's type, without vasculitis, and (2) Wegener's type showing vasculitis. Intermediate forms existed between the two types. This concept and indeed the whole existence of 'midline granuloma' as a specific entity has not been universally accepted. Burston (1959) showed that more specific entities could often be diagnosed by persistent investigation in cases initially given the

<sup>1</sup>Paper presented to the Pathological Society of Great Britain and Ireland, Dublin, July 1975, and as a demonstration to the same Society, London, January 1976

designation of midline granuloma. Eichel and Mabery (1968) felt that this condition did not actually exist as a specific disease process. Harrison (1974) found that by consideration only of the clinical aspects of the case he was able to decide on a mode of therapy which produced satisfactory results. He treated patients with progressive local ulceration of the nose as neoplastic by irradiation, while those showing less local but more systemic manifestations were more likely to be in the Wegener's group and were managed with corticosteroids and azathioprine.

The histological findings were not considered by Harrison to be helpful. The failure of histopathological examination to identify a lesion which in its behaviour is neoplastic is rare in modern medical practice. In fact, because of the close correlation between histology and clinical behaviour, identification by histological examination has become of fundamental importance in the diagnosis and treatment of most patients with suspected neoplasms. Because of this discrepancy between the cancerous behaviour of some of the lesions and the apparently inflammatory histological appearance of biopsies from them, we investigated histological material from 30 cases, most of them used in the clinical study of Harrison (1974), with the object of seeking a histological basis for the lesions which had been identified clinically as locally invasive.

## Material and methods

Histological sections were examined from 30 cases

with destructive lesions of the nasal passages, in 19 of whom a clinical diagnosis of 'malignant (non-healing) granuloma' had been made. In seven cases tissue from some internal organs was also available for histological study; in six cases these were obtained at necropsy and in one case (case 10, Table 1) spleen, liver, and abdominal lymph nodes had been removed surgically and were available for study.

Sections from all blocks of tissue were stained with haematoxylin and eosin (H and E). In addition, sections of all nasal tissues, lymph nodes, and selected other organs were stained by the periodic acid Schiff method, Gordon and Sweet's stain for reticulin, and the Unna-Pappenheim (methyl green-pyronin) methods. A preliminary survey of H and E stained sections from all biopsies of the nasal passages in these cases was carried out without recourse to the clinical history.

Nasal biopsy material from four cases (cases 1, 4, 5, and 6) was examined electron microscopically. Difficulty was experienced in each case in obtaining areas in which cells were sufficiently well preserved for adequate ultrastructural observation to be made, but a few suitable areas were obtained. Nasal biopsy material was fixed in 3% glutaraldehyde for electron microscopy, washed in Sørensen's buffer, and embedded in Araldite. The sections were examined with a Siemens Elmiskop II microscope.

## Results

### PRELIMINARY OBSERVATIONS

In the preliminary examination of H and E stained sections from biopsies of the nasal passages of all 30 cases, 17 cases were found to show inflammatory changes only. These changes included tuberculoid granulomatous inflammation as well as non-specific chronic inflammation. Vasculitis was present in some. All 11 cases of clinical Wegener's granuloma were found in this group. Since a study of the histological aspects of Wegener's granuloma was not an aim of this work, these cases will not be further referred to.

In three nasal biopsies the histological appearances were in the category of lymphoma. In these cases an initial clinical diagnosis of 'midline granuloma' had been made, and earlier biopsies had shown no neoplasm, but subsequent biopsies had revealed definite lymphoma classified as histiocytic lymphoma, well-differentiated lymphocytic lymphosarcoma, and plasmacytoma respectively. These three cases will not be further referred to. The remaining 10 cases all showed in one or more of the nasal biopsies a combination of widespread necrosis and groups of atypical cells, the cytological appearances of which suggested a malignant origin (Figs. 1 and 2). We

believe that this combination of histological changes, which we will refer to as NACE (necrosis with atypical cellular exudate) represents the microscopical counterpart of the 'lethal' form of the clinical condition described as 'malignant granuloma', and the rest of this report will deal with the features of the 10 cases showing this change.


### PATHOLOGICAL FEATURES OF CASES WITH NACE

The atypical cells in cases showing NACE were a little larger than mononuclear inflammatory cells (approximately 15–20 microns) with nuclei that varied from round to irregularly elongated and bent, often with irregular protuberances and an irregularly staining nuclear membrane. The chromatin material was rather scanty and irregularly distributed. Nucleoli were often prominent. Binucleate forms were present and occasional mitotic figures were seen in each case. Cytoplasm varied from scanty to abundant and the cytoplasmic membrane was indefinite. Phagocytised basophilic debris was frequently present in the cytoplasm of the cells (Figs. 2 and 3). A fine reticular framework honeycombed the cells individually (Figs. 4 and 5). Zones composed of such cells varied from very small areas to prominent portions of the available biopsy material. A variable amount of chronic inflammatory cellular infiltration, mainly lymphocytes and plasma cells, was also present. Histiocytes of normal appearance were seen in most cases and in several cases formed unbroken groups which occupied several low-power fields. The atypical cells described above formed homogeneous groups in about half the cases but in the other cases were interspersed as varying numbers of isolated cells among plasma cells, lymphocytes, and histiocytes.

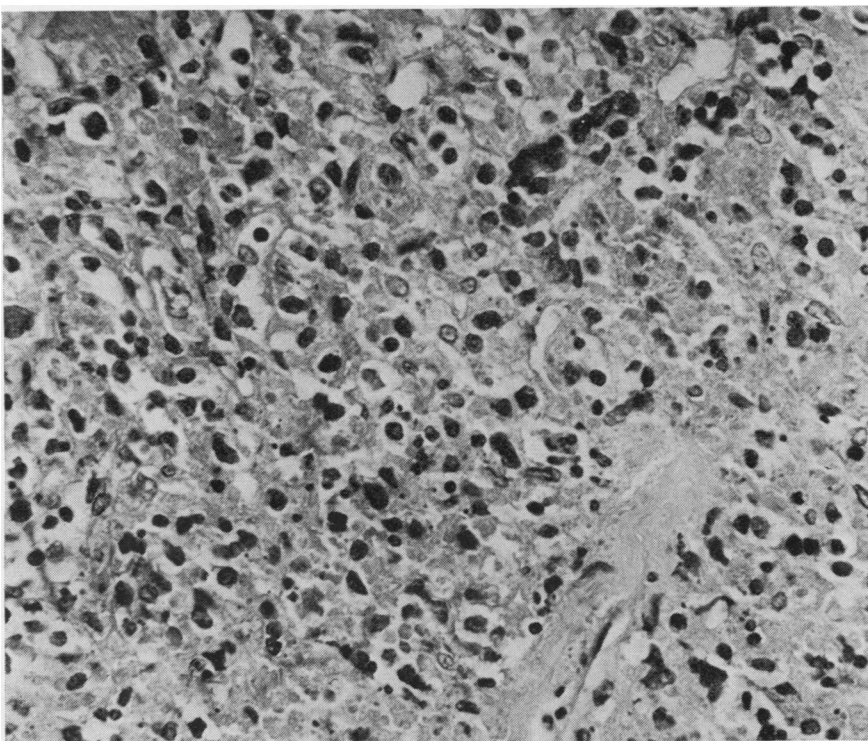
Necrosis was always prominent and was usually of the coagulative type. It was seen as a spotty change between the tumour cells and also forming large, eosinophilic, acellular areas which often comprised a prominent feature of the biopsy material. In the latter areas a fine honeycomb of reticulin was present which was identical in appearance with that of the atypical cellular areas (Figs. 4 and 5).

NACE was seen in some biopsy material to be occupying a mucosal position beneath epithelium and in the vicinity of seromucinous glands, but more often it was without such anatomical localisation, there being no epithelial tissue in the biopsy.

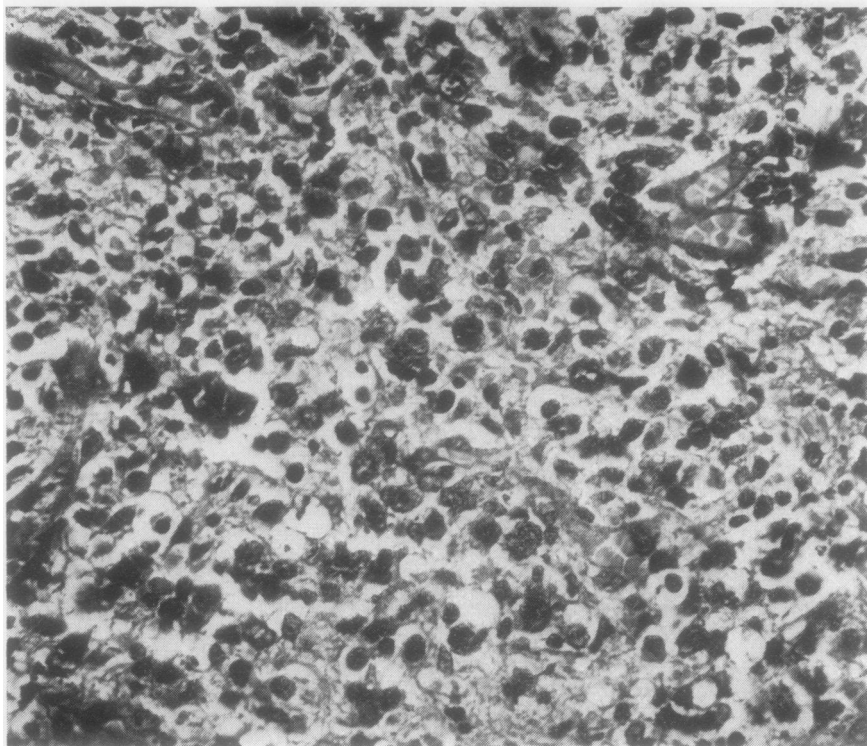
There was evidence of invasion of adjacent structures by the NACE tissue. In four cases it had invaded nerve sheaths (Fig. 6). In two cases invasion of skeletal muscle was present, and in one of these (case 5) the masseter muscle was infiltrated by pale grey tissue with the appearance of NACE histo-



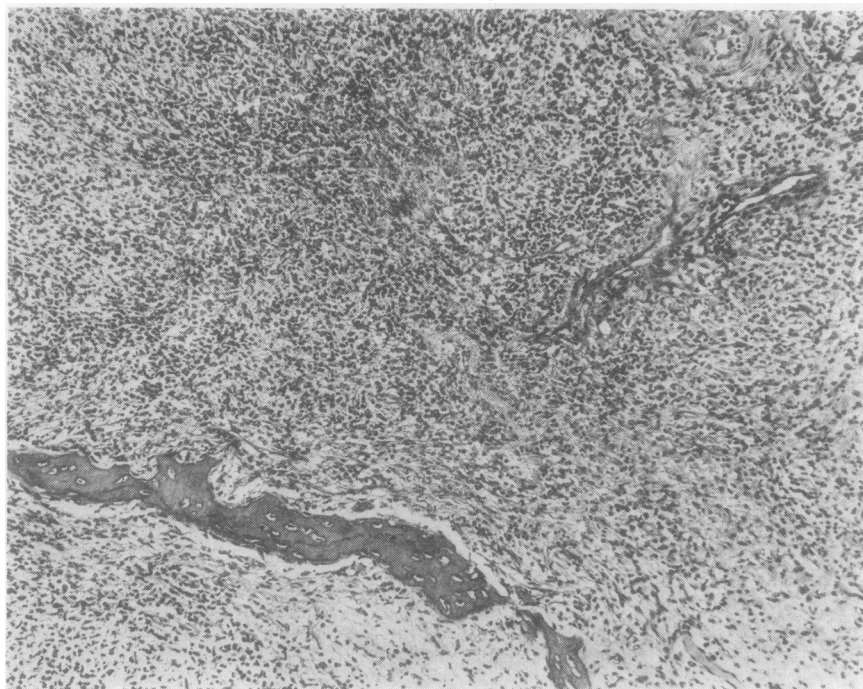
**Fig. 1** Nasal biopsy from a case of 'midline granuloma'. On the left is a cellular area. Towards the right this gives way to a zone composed largely of coagulation necrosis. Haematoxylin and eosin (H and E)  $\times 110$



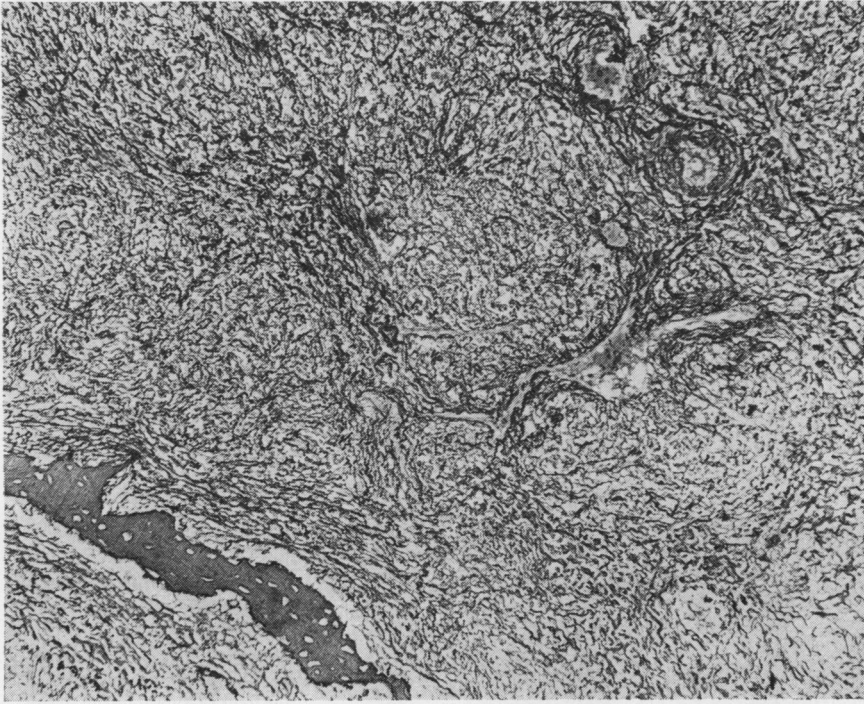
**Fig. 2** High-power view of square marked in Fig. 1. Note irregularity of many of the cell nuclei ('atypical cells'). Some typical lymphocytes and plasma cells are also present. Towards the right there is coagulation necrosis. H and E  $\times 355$



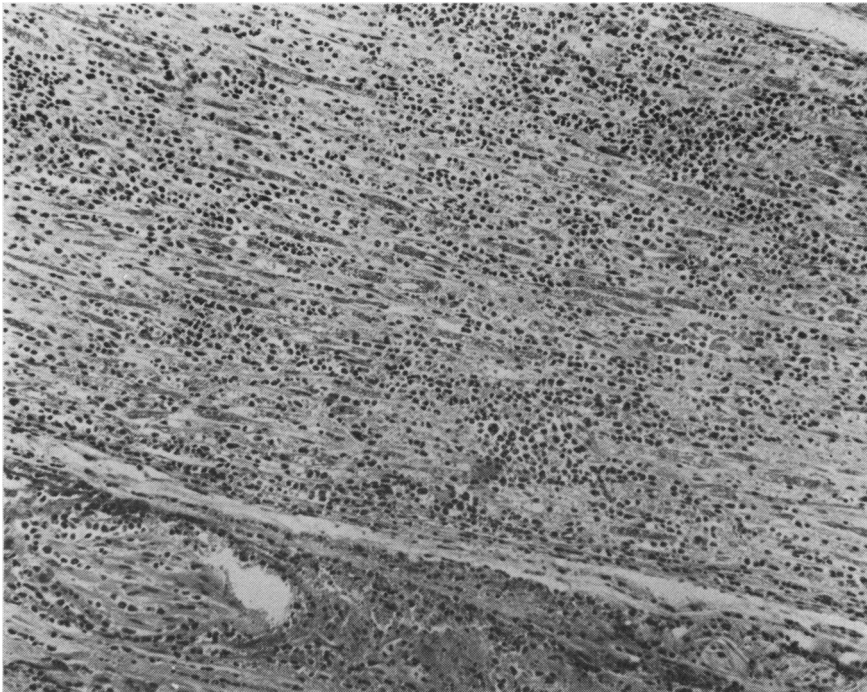**Fig. 3** 'Atypical cells' in nasal biopsy from another case of 'midline granuloma'. H and E  $\times 355$



**Fig. 4** Nasal biopsy from case of 'midline granuloma'. Area of NACE. Note patchy necrosis at bottom right and lamina of bone at bottom left. H and E  $\times 110$



*Fig. 5 Section from paraffin block adjacent to that of Fig. 4. There is a fine reticulin pattern including the zone of necrosis. Gordon and Sweet's reticulin stain  $\times 185$*



*Fig. 6 Nerve bundle in biopsy of nasal region in case of 'midline granuloma'. There is intense infiltration with 'atypical cells'. H and E  $\times 110$*



logically (Fig. 7). In a further two cases histological evidence of invasion of nasal bone by NACE was present (Fig. 8).

Vascular changes were evident in some of the cases. Two of these changes—fibrous thickening and foam-cell infiltration of the intima of small arteries—were found only in previously irradiated cases. In two cases there was involvement of the walls of small vessels by ACE (Fig. 9), and in five cases, two of them not irradiated, fibrin thrombi were found in small vessels within areas of NACE. In no case with NACE was there seen the necrotising vasculitis characteristic of polyarteritis nodosa or Wegener's granuloma.

#### ELECTRON MICROSCOPICAL OBSERVATIONS

Electron microscopical observation of the 'atypical

cells' in the cases with NACE showed peripherally arranged masses of chromatin and prominent nucleoli in nuclei. Cytoplasm contained rough endoplasmic reticulum, occasional mitochondria, and frequently prominent phagosomal bodies (Fig. 10).

#### CLINICAL FEATURES OF CASES WITH NACE

On review of the clinical features of the 10 patients selected by the presence of NACE without prior knowledge of the clinical history, it was found that nine of the 10 were males and the ages of presentation ranged from 23 to 72 years with a median age of 52. In all patients there had been a history of unilateral nasal obstruction, often for many years; in five patients submucous resection of the nasal septum had been carried out on one or two occasions with

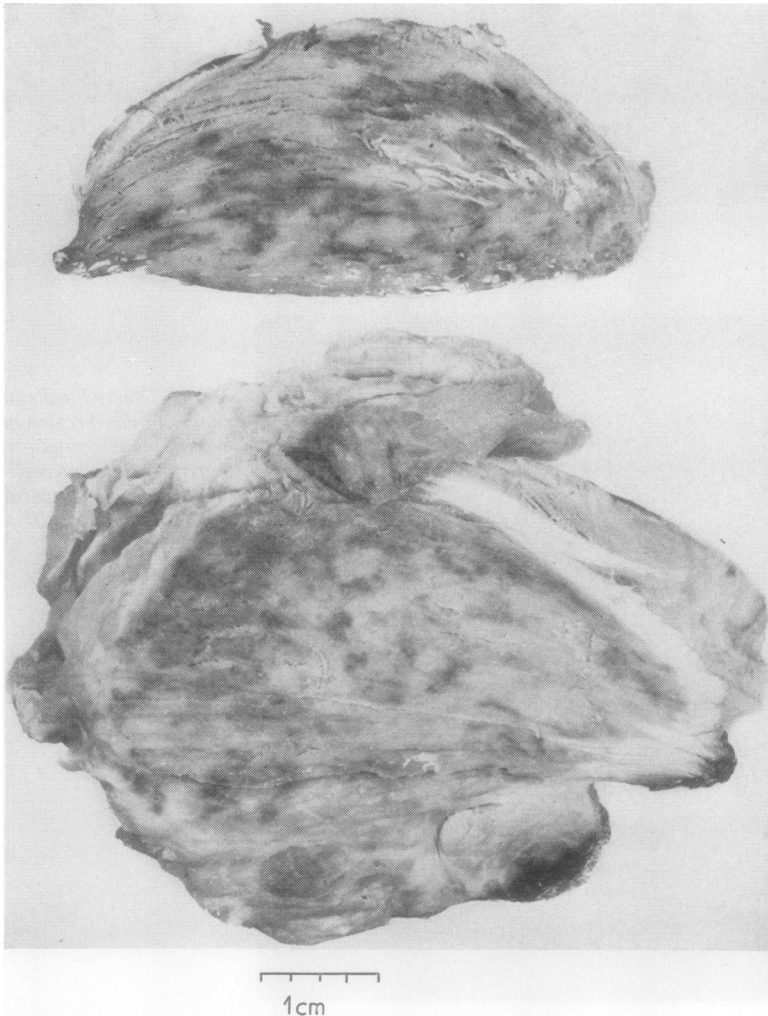
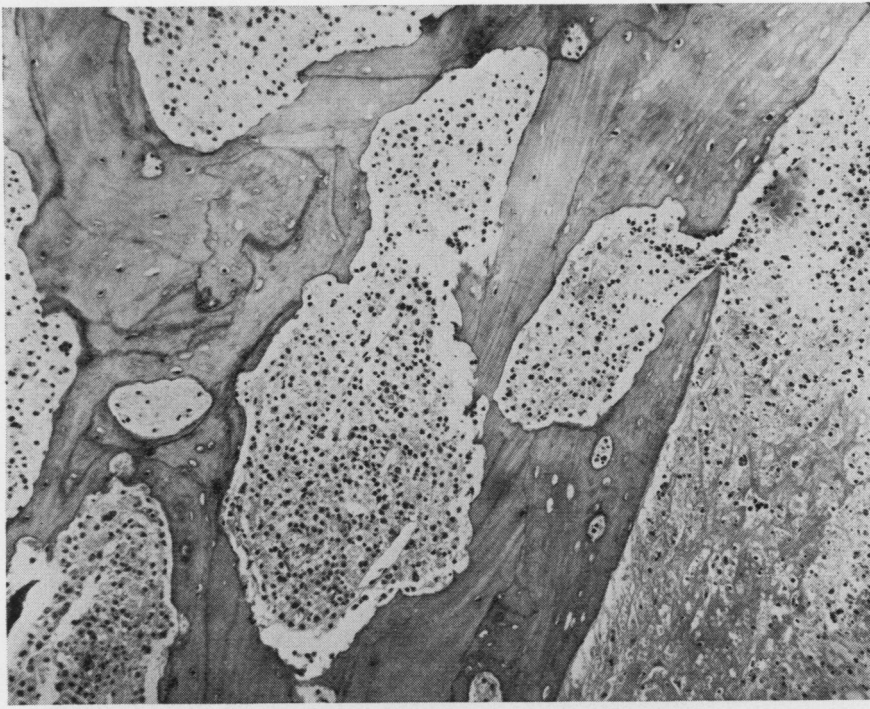
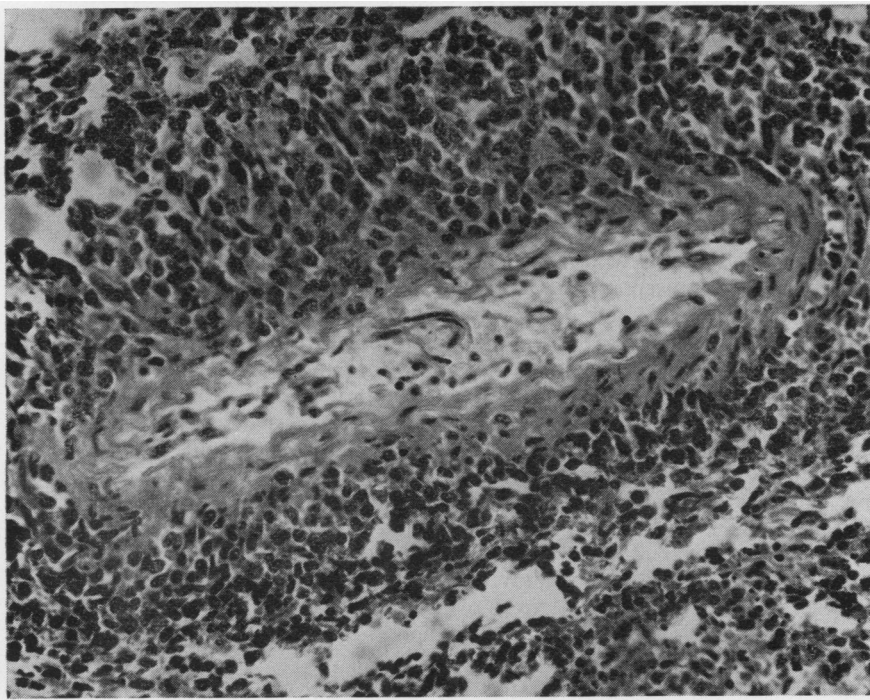


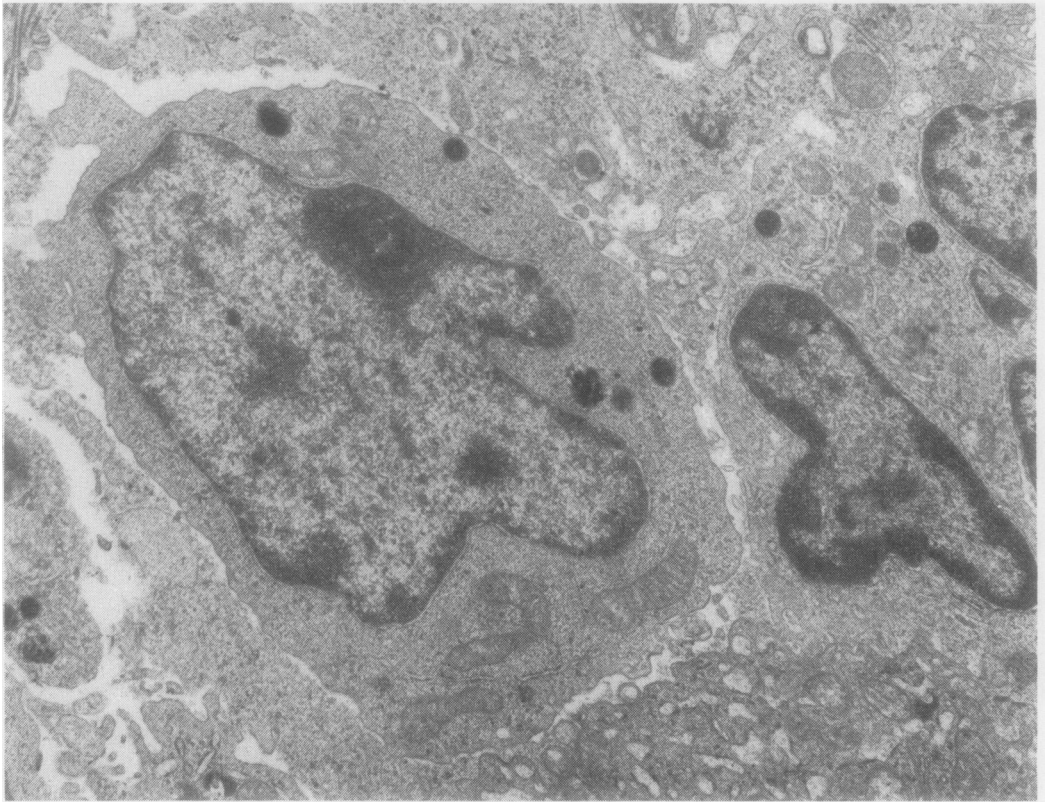
Fig. 7 Slices of left masseter muscle at necropsy from case of 'midline granuloma' showing extensive facial ulceration (case 6). The muscle is severely infiltrated by pale grey tissue, which was histologically characteristic of NACE.



**Fig. 8** Nasal biopsy from case of 'midline granuloma'. There is infiltration of bone by NACE tissue. Note atypical cells in central marrow cavity and coagulative necrosis outside bone to right. *H and E*  $\times 110$



**Fig. 9** Nasal biopsy from case of 'midline granuloma'. There is infiltration of the wall of a small artery with 'atypical cells'. *H and E*  $\times 335$



**Fig. 10** Electron micrograph of 'atypical cell' from nasal biopsy in a case of 'midline granuloma' showing NACE. Note low chromatin content of nucleus and phagosomes in cytoplasm. Uranyl acetate and lead citrate  $\times 10\ 000$

little or no relief of the obstruction. In most of the patients there was an accompanying unilateral or bilateral maxillary sinusitis for which, in two patients, a Caldwell-Luc operation had been performed. In each case the nasal obstruction had eventually given way to ulceration of parts of the nasal cavity with varying degrees of involvement of the nasal septum, turbinate bones, ethmoid sinuses, hard palate, and lateral wall of the nose. In case 1 there was extension of the disease process to the orbit, with proptosis, and to the base of the skull. In another patient the ulcerative process massively involved the anterior walls of the maxillary antra, the whole of the nose, the palate, and front of the mouth. Each patient was treated with radiotherapy, but it is not possible adequately to assess the effects of this treatment on the course of the disease as the treatment was administered in different centres in different dosages and at different stages of the disease. Four patients died five years, four years, three years, and six months respectively after the onset of the disease. Death was related to infection in three cases and massive

haemorrhage from iatrogenic duodenal ulceration in one case (Table 1).

**SYSTEMIC INVOLVEMENT IN CASES WITH NACE**  
Histological evidence of involvement by a similar or related pathological process outside the nasal area was seen in some of the cases. Such changes took the following forms: (a) lymphomatous change in spleen and/or lymph nodes; (b) tumour-like deposits; (c) infiltration of the liver; (d) erythrophagocytosis; (e) histiocytic infiltration of bone marrow.

(a) Cervical lymph nodes at necropsy in cases 1, 2, and 3 and abdominal lymph nodes and spleen at laparotomy in case 10 were enlarged on gross inspection. Histologically there was loss of normal architecture and replacement by atypical lymphoid cells similar in appearance to the cells described above in NACE. Multinucleate cells were common. Areas of necrosis were frequent. The changes were those of lymphomatous involvement of lymph nodes and spleen.

(b) In one kidney in case 2, a 1.5 cm deposit was



Table 1 Features of 10 cases with involvement of nasal passages by NACE

Case	Age	Sex	Course of disease	Length of history	Involvement		
					Nasal passage	Cervical lymph node	Systemic
1	23	M	Erosion of skull base. Meningitis	6 mth Died	Ethmoid, sphenoid	++	Necropsy: Sinusoids of liver
2	51	M	Progressive destruction of nasal tissues. Terminal <i>Strep. pyogenes</i> sinusitis	5 yr Died	Septum, nasopharynx, maxillary sinus	+	Necropsy: Kidney deposit
3	55	F	Progressive destruction of nasal tissues. Radical removal R. maxilla one month before death. Septicaemia	5 yr Died	Septum, maxillary sinus, nasopharynx	+	Necropsy —
4	48	M	No further progression after irradiation	3 yr A & W	Septum, turbinates	—	—
5	58	M	No further progression after irradiation	3 yr A & W	Maxillary sinus, ethmoids	—	—
6	53	M	Massive progressive involvement of nose and front skull. Death from massive haemorrhage from duodenal ulceration due to steroid therapy	3 yr Died	Whole nose and palate	—	Necropsy —
7	65	M	No further progression after radiotherapy	2 yr A & W	Septum, maxillary sinus	—	—
8	50	M	No further progression after radiotherapy	2 yr A & W	Roof of nose	—	—
9	72	M	No further progression after radiotherapy	1 yr A & W	Palate, maxillary sinus	—	—
10	41	M	Pancytopenia and hepatosplenomegaly during irradiation treatment of nasal lesion	9 mth A	Palate, lateral wall	—	Laparotomy: Spleen, abdominal lymph nodes, bone marrow

A &amp; W = alive and well

found in the cortex. Histologically this was composed of small cells similar to those of the NACE areas in the nasal lesion. Large areas of necrosis were present. At the edges of this deposit there was infiltration between the renal tubules by the abnormal cells.

As mentioned above, the left masseter muscle in case 6 showed grey infiltration which was composed histologically of tissue with NACE appearance. This muscle was at the edge of the advancing zone of massive facial ulceration in this patient so that it is possible that the tissue reached it by direct invasion from the nasal area rather than by some form of systemic spread.

(c) The sinusoids of the liver showed in case 1 infiltration by 'atypical' lymphoid cells, some of them multinucleate. In case 10 there was infiltration of portal areas and parenchyma by groups of cells similar to those causing lymphomatous enlargement of abdominal lymph nodes and spleen.

(d) Case 10 presented with a destructive nasal lesion with histological changes of NACE. During the course of radiotherapy to the nose this patient developed pancytopenia, and hepatosplenomegaly was detected. The spleen was removed and biopsies of abdominal lymph nodes and liver were taken. These tissues *all* showed erythrophagocytosis as well as the changes of malignant lymphoma and the condition was classified as malignant histiocytosis

(histiocytic medullary reticulosis). This patient will be presented in greater detail in a separate report. A study was made for the presence of erythrophagocytosis in the other cases in which NACE had been detected in the nasal biopsy. Liver, spleen, and lymph node sections were available in four other cases, and the degree of erythrophagocytosis seen in these tissues is listed in Table 2. Two cases (1 and 3) showed what is listed as a 'moderate' degree of erythrophagocytosis, by which is meant to a lesser degree than was present in the spleen of case 10 but nevertheless sufficiently prominent to be observed in most high-power fields. Sections of liver and lymph nodes in case 1 showed what is listed in Table 2 as slight 'erythrophagocytosis', by which is meant that histiocytes containing erythrocytes in their cytoplasm were seen in occasional high-power fields.

Table 2 Erythrophagocytosis in liver, spleen, and lymph nodes in cases with NACE in nasal biopsy

Case	Liver	Spleen	Lymph node
1	Slight	Moderate	Slight
2	Absent	Absent	Absent
3	NA	Moderate	NA
4	Absent	Absent	NA
10	Slight	Marked	Marked

NA = not available for histological study

(e) In case 10, normal and abnormal histiocytic cells were seen in excessive numbers in the smears of bone marrow. Some of these cells contained phagocytised red cells. Similar changes were seen in the bone marrow of another case of 'midline granuloma' not included in this report, in which the nasal biopsy showed changes of NACE (Kay, 1976).

## Discussion

In a histological study of biopsies from 30 cases in which a clinical diagnosis of 'midline granuloma' or Wegener's granuloma had been given, we selected 10 cases on the basis of a common histological feature, the presence of widespread necrosis and atypical cells (NACE). The cytological features of these cells were such as to suggest a malignant nature by criteria usually used by pathologists. It must be admitted that such criteria are not always valid in histological sections, eg, fibroblasts can show 'malignant' features in organising granulation tissues where there is no neoplastic activity. The atypical cells seen in these nasal biopsies, however, were sometimes arranged in broad groups with a fine reticulin pattern surrounding individual cells. A similar reticulin pattern was present in the areas of necrosis which were also a feature of the biopsies in each case. 'Atypical' cells, often accompanied by areas of necrosis, were seen infiltrating nerve, bone, muscle, and arterial walls in some of these cases. There was, therefore, histological evidence of an invasive and destructive neoplasm composed of 'atypical cells', ie, a malignant neoplasm, in these 10 cases. The lesion not only appeared to be locally malignant, but in several cases also showed evidence of systemic dissemination. Cervical or abdominal lymph nodes in four cases and spleen in one case showed not only the presence of malignant cells but obliteration of the normal architecture by this malignant infiltration. In one case a deposit of the same cells was present in the renal cortex, and in two cases there was infiltration of the liver.

We believe that the malignant neoplasm in these cases is a form of lymphoma. This view is based on the appearance of the tumour cells, on the reticulin pattern, and on the mode of infiltration of lymph nodes, spleen, and liver. Classification of non-Hodgkin's lymphoma is at present in a state of change (Bennett *et al.*, 1974; Dorfman, 1974; Gerard-Marchant *et al.*, 1974). The appearances of the lymphoma cells as seen by light and electron microscopy would suggest that the neoplasm should be classified as histiocytic lymphoma by the newer terminology. The feeble chromatin production and evidence of phagocytic activity in the rather abundant cytoplasm indicate an origin from histiocytes.

The clinical behaviour of these neoplasms is in keeping with a malignant lymphoma of rather slow activity. The lesion would seem, in both histological features and clinical activity, to be identical with that described as 'polymorphic reticulosis' by Eichel *et al.* (1966).

Erythrophagocytosis is frequently seen in normal lymphoid tissue in small amounts and may be found in increased amounts in haemolytic conditions (Smith, 1958). The presence of relatively large degrees of erythrophagocytosis in three of five of the cases with NACE, in which the relevant tissues were available for histological examination, indicates that the lymphomatous tumour, which we believe to be the pathological basis of these cases, may be accompanied by a generalised enhanced phagocytic activity of histiocytes. In case 10 this was extreme enough to warrant a diagnosis of malignant histiocytosis. In this case normal and abnormal histiocytes were abundant in the bone marrow smears, and this finding has been noted in another case of 'midline granuloma' showing NACE (Kay, 1976). These observations would suggest that the neoplasms found in these cases have a functional similarity and a relationship to normal histiocytes. It is of interest that the cells in the cases of 'midline granuloma' described by de Faria *et al.* (1957) were induced to phagocytise saccharated iron oxide *in vivo*, as a result of which the authors described the lesion as a reticulohistiocytoma.

We wish to emphasise that none of the 10 cases showed classical lymphoma on nasal biopsy but that the conclusion that the histological change which we have designated as NACE represents a malignant lymphoma is based on an analysis of all the findings in these cases. Large areas of the nasal biopsy tissue showed inflammatory changes only, and in some cases NACE tissue was found in only one of three or more biopsies. The sparsity of malignant tissue together with the large amount of necrosis in these cases accounts for the designation 'granuloma' that has been given to this lesion from the time of its first description, in spite of its behaviour as a malignant neoplasm. A further similarity to an inflammatory lesion is the small size of the tumour cells and their resemblance to inflammatory histiocytes. It is noteworthy that although some necrosis was present in the cervical lymph nodes and systemic deposits of neoplasm, neither this nor inflammation was ever as extensive as in the nasal biopsy material. Nasal tumours are particularly prone to secondary infection. Biopsies which have to be relatively small in this situation are usually taken from superficial mucosa where secondary changes are likely to be most marked. In some of our cases in whom the designation midline or malignant 'granuloma' had

been given, small doses of radiotherapy had been used as treatment to the nose. This produced widespread necrosis in the tissue and also vascular changes which probably enhanced the necrosis.

It is possible that there *does* exist a disease in which there is a relentlessly progressive ulceration confined to the nose and surrounding area but in which repeated biopsies show inflammatory changes only. We have not, however, found such a case, in company with Burston (1959), Eichel and Mabery (1968), and McGuirt and Rose (1976). We would, therefore, suggest that the concept of 'midline granuloma' and its synonyms be abandoned. If biopsy of the nose in a patient with a destructive lesion shows non-specific inflammatory changes only, particularly if these changes are accompanied by considerable necrosis, further biopsies should be carried out. The pathologist may then be satisfied that there is either a specific inflammatory change (eg, tuberculosis or sarcoid) or a histological appearance indicating a neoplastic condition, but we do not feel that it is justified to diagnose a condition with malignant potential on the basis of non-specific chronic inflammatory changes only.

The use of terms such as 'malignant granuloma' for cases that are in the malignant neoplastic category and their classification together with Wegener's granuloma have been, we believe, detrimental to the treatment of the patient. On the mistaken assumption that the process is a near-inflammatory or an autoimmune one, large doses of steroids have been given and radiotherapy is used in doses that are not sufficient for a malignant lymphoma. We suggest that the mainstay of treatment for histiocytic lymphoma of the nose should be adequate tumour doses of x rays. The cervical area should probably be irradiated also. We would further suggest that consideration be given to the use of surgical methods to remove as much as possible of the neoplasm. Surgery is sometimes a very effective therapy for lymphoma, for example, in the gastrointestinal tract, and might be useful in this area where infiltration of bone by the tumour protects against some of the destructive effect of radiotherapy on the tumour cells. Cytotoxic drugs

might also play a useful part, particularly where there is systemic involvement by the growth.

We wish to thank Professor D. F. N. Harrison for help and encouragement in carrying out this histological study based mainly on his clinical material. Dr H. E. M. Kay kindly gave help and advice on the bone marrow changes of case 10 and provided information on another case at the Royal Marsden Hospital. Miss Eileen Buckle helped with the typescript and Mr D. Connolly with the photography.

## References

- Bennett, M. H., Farrer-Brown, G., Henry, K., and Jelliffe, A. M. (1974). Classification of non-Hodgkin's lymphomas (Letter). *Lancet*, **2**, 405-406.
- Burston, H. H. (1959). Lethal midline granuloma: is it a pathological entity? *Laryngoscope*, **69**, 1-43.
- de Faria, J. L., Cutin, M., Morgante, A. P., and Ferri, R. G. (1957). Malignant granuloma of the face: contributions to its nosology. *Arch. Otolaryng.*, **62**, 255-262.
- Dorfman, R. F. (1974). Classification of non-Hodgkin's lymphomas. *Lancet*, **1**, 1295-1296.
- Eichel, B. S., Harrison, E. G., Jr., Devine, K. D., Scanlon, P. W., and Brown, H. A. (1966). Primary lymphoma of the nose including a relationship to lethal midline granuloma. *Amer. J. Surg.*, **112**, 597-605.
- Eichel, B. S. and Mabery, T. E. (1968). The enigma of the lethal midline granuloma. *Laryngoscope*, **78**, 1367-1386.
- Friedmann, I. (1955). The pathology of malignant granuloma of the nose. *J. Laryng.*, **69**, 331-341.
- Friedmann, I. (1963). The pathology of midline granuloma. *Proc. roy. Soc. Med.*, **57**, 289-297.
- Gerard-Marchant, R., Hamlin, I., Lennert, K., Rilke, F., Stansfeld, A. G., and van Unnik, J. A. M. (1974). Classification of non-Hodgkin's lymphomas (Letter) *Lancet*, **2**, 406-408.
- Harrison, D. F. N. (1974). Non-healing granulomata of the upper respiratory tract. *Brit. med. J.*, **4**, 205-209.
- Kay, H. E. (1976). Personal communication.
- McGuirt, W. F. and Rose, E. F. (1976). Lethal midline granuloma: a pathological spectrum. *J. Laryng.*, **90**, 459-466.
- Smith, F. (1958). Erythrophagocytosis in human lymph-glands. *J. Path. Bact.*, **76**, 383-392.
- Stewart, J. P. (1933). Progressive lethal granulomatous ulceration of the nose. *J. Laryng.*, **48**, 657-701.