

HB_sAg and HB_cAg in the livers of asymptomatic hepatitis B antigen carriers

E. TAPP¹ AND D. M. JONES

From the Department of Pathology, Withington Hospital, Manchester

SUMMARY Asymptomatic blood donors with persistent HB_s antigenaemia have a variety of histological lesions in the liver, and serial biopsies indicate that, in some, these lesions may progress. The immunoperoxidase technique was found to be a sensitive method for the histological demonstration of HB_sAg and HB_cAg. Livers showing minor histological changes contained more HB_sAg than those with active lesions and there appears to be an inverse relationship between the amount of HB_sAg in the liver and the severity of the histological damage. In the carriers who had more than one biopsy, the presence of stainable HB_sAg, irrespective of the initial histological diagnosis, was associated with a greater likelihood of progression of the histological lesion. HB_cAg was found only in the hepatocyte nuclei of carriers with chronic aggressive and chronic persistent hepatitis.

Hepatitis B antigen (HB Ag) was first identified in the liver by immunofluorescence (Millman *et al.*, 1969; Nowoslawski *et al.*, 1970). More recently, similar techniques have been used to demonstrate the surface antigen (HB_sAg) in the cytoplasm of hepatocytes and core antigen (HB_cAg) in the nuclei of hepatocytes (Gudat *et al.*, 1975; Ray *et al.*, 1976; Trepo *et al.*, 1976). A disadvantage of immunofluorescence is that the level of sensitivity is such that the most intense fluorescence is produced in sections of fresh frozen tissue (Portmann *et al.*, 1976). Moreover, the fluorescent stains are themselves only transitory, and these sections must be examined soon after staining. Consequently, the use of orcein-stained paraffin sections of liver (Shikata *et al.*, 1974; Deodhar *et al.*, 1975) has some potential advantages over immunofluorescence. A further advance in the identification and localisation of the hepatitis virus antigens was made when it was shown by Burns (1975) and by Nayak and Sachdeva (1975) that they could be stained in paraffin sections using the immunoperoxidase technique. This technique combines the specificity of immunological methods with all the advantages inherent in the use of paraffin sections for the study of the antigen.

In this study of the liver biopsies from asymptomatic blood donors with persistent HB_sAg anti-

genaemia, the immunoperoxidase, orcein, and electron optical methods have been compared and used to identify HB_sAg. HB_cAg was demonstrated in sections by both immunoperoxidase and electron microscopy.

Material and methods

Liver biopsies from a group of 33 asymptomatic blood donors, 22 of whom had had at least two biopsies over periods of two to four years, were reviewed. In most of these biopsies (48/55) there was sufficient material for immunoperoxidase and orcein staining. The investigation of the blood donors has been described previously (Woolf *et al.*, 1974; Tapp *et al.*, 1976).

IMMUNOPEROXIDASE

Paraffin sections were stained using the type of sandwich technique described by Mason *et al.* (1975). The following sera were applied to the sections in turn:

(a) for HB_sAg—normal porcine serum—specific anti HB_sAg raised in rabbits (Hoechst)—antibody to rabbit serum raised in pigs (Mercia Diagnostics)—the peroxidase-anti-peroxidase complexes (Mercia Diagnostics);

(b) for HB_cAg—normal porcine serum—human serum containing high titre anti HB_cAg and devoid of anti HB_s and antibody to e antigen—anti human IgG serum raised in rabbits—antibody to rabbit

¹Present address: The Group Laboratory, Preston Royal Infirmary, Preston.

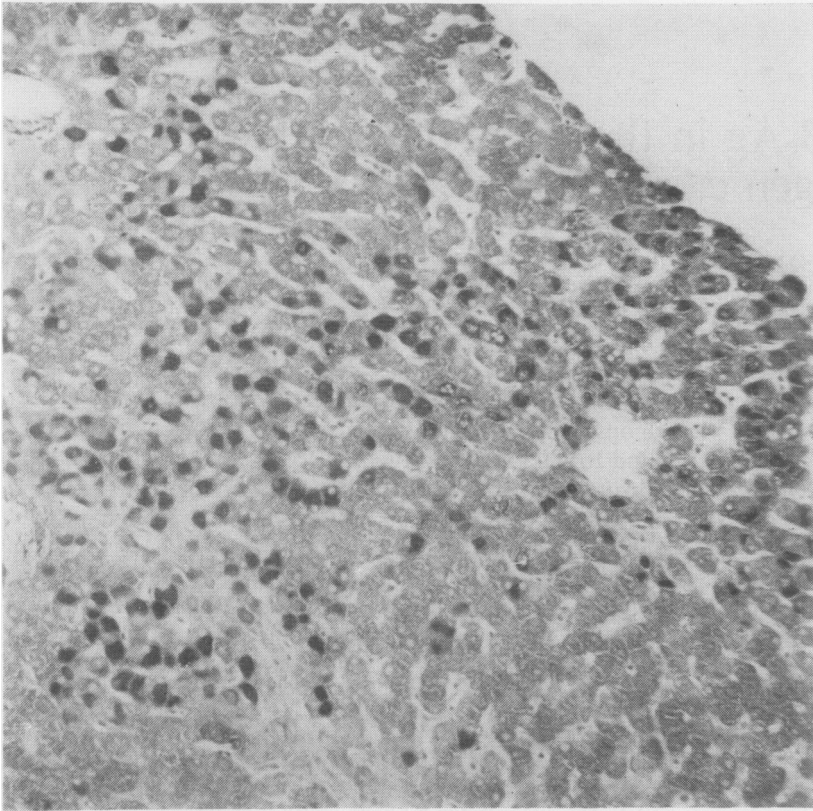


Fig. 1 *The cytoplasm of the majority of the cells in some lobules is stained. Immunoperoxidase $\times 145$.*

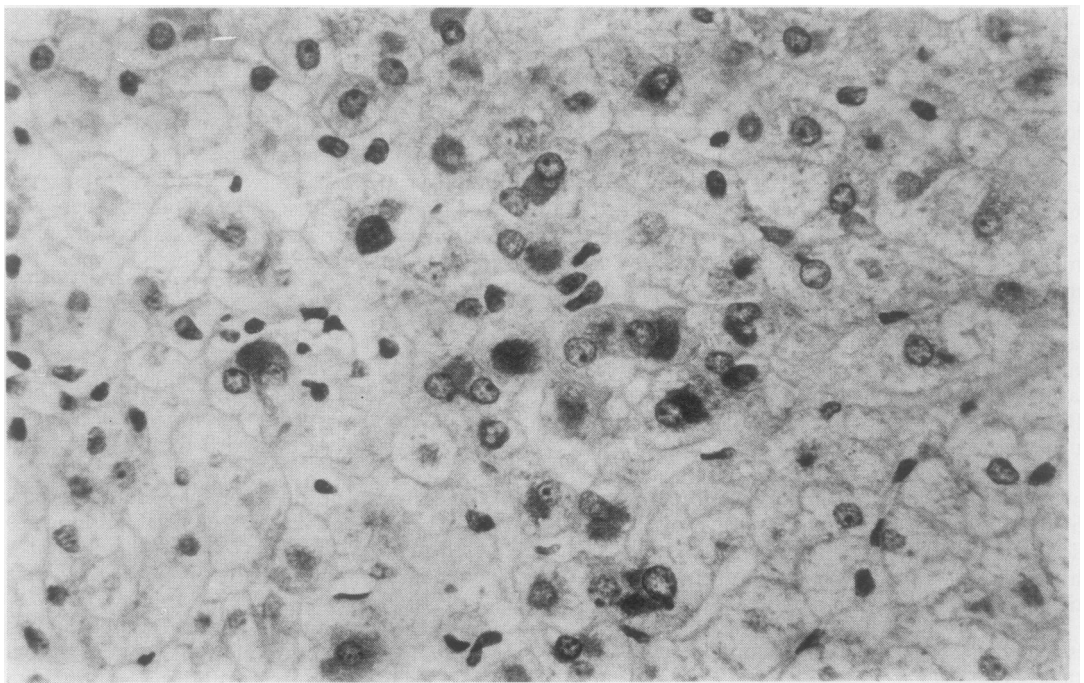


Fig. 2 *Small groups of cells show positive cytoplasmic staining. Immunoperoxidase $\times 400$.*

serum raised in pigs—the peroxidase-anti-peroxidase complexes.

The optimal dilutions for the anti HB_s and anti HB_c that produced least non-specific staining were found by titration. The specificity of the HB_sAg staining was confirmed in control sections where staining was abolished when anti-HB_s previously absorbed with HB_sAg was used. Specificity of the HB_cAg staining was demonstrated by treating control sections with normal human serum instead of anti HB_c. The anti HB_c serum was tested for anti HB_s by haemagglutination and for anti e antigen by immunodiffusion.

In both (a) and (b) the peroxidase and hence the antigen was visualised by the development of the antibody-bound peroxidase using diamino benzidine.

ORCEIN

Paraffin sections were stained by the method described by Deodhar *et al.* (1975).

ELECTRON MICROSCOPY

A part of each biopsy was processed separately for electron microscopy, and ultrathin sections were stained with uranylacetate and lead citrate.

Results

IMMUNOPEROXIDASE STAINING FOR HB_sAg

HB_sAg staining was seen in the cytoplasm of hepatocytes in 34 of the 48 biopsies which were examined. The biopsies from 12 of the 33 carriers did not have demonstrable HB_sAg in the first or subsequent biopsies. The amount of cytoplasm staining in the individual cells varied from almost the whole to only

Table HB_sAg staining and liver lesions

Liver lesion	No. of biopsies	HB _s Ag staining		
		Diffuse	Focal	Negative
Chronic aggressive hepatitis	7	1 (14%)	4 (56%)	2
Chronic persistent hepatitis	17	6 (35%)	7 (40%)	4
Focal parenchymal necrosis	17	9 (53%)	2 (12%)	6
Normal	4	2 (50%)	0 (0%)	2
Cirrhosis	3	2	1	0
Total	48	20 (42%)	14 (29%)	14

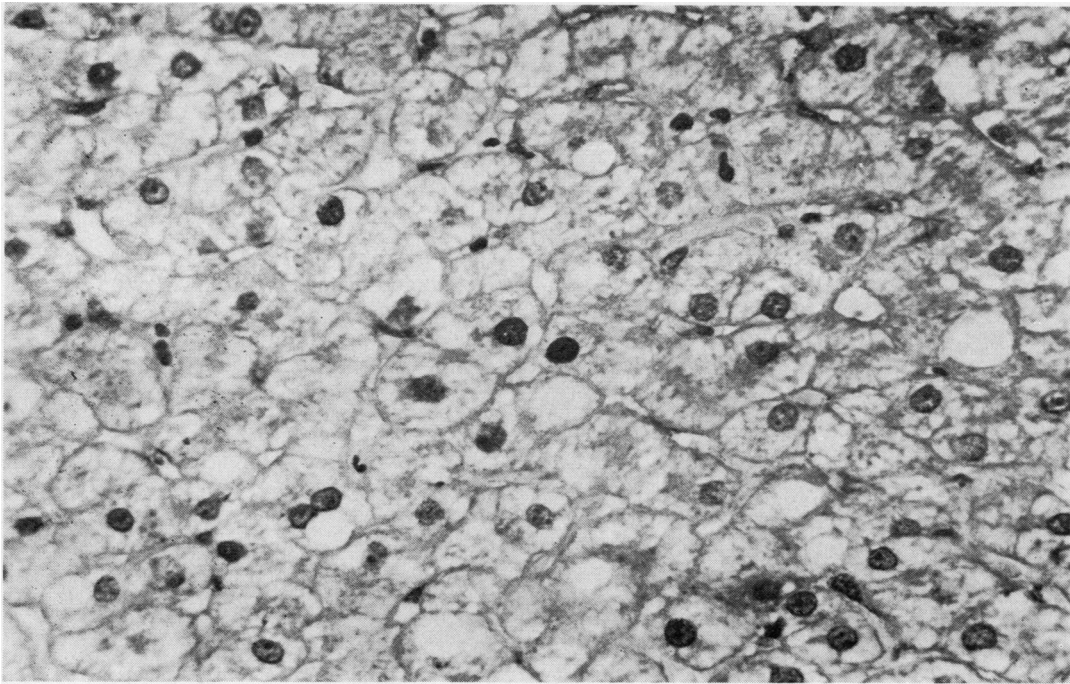


Fig. 3 The two nuclei in the centre of the field are stained heavily. Other nuclei show lighter staining. Immunoperoxidase $\times 400$.

small parts of the cell. The intensity of the staining varied from a dark brown to a pale yellow, and it is assumed that this is a reflection of the amount of HBsAg in the cytoplasm. Where there were lipid droplets in the cytoplasm these were unstained, giving rise to a foamy appearance of the cytoplasm. There was no evidence of HBsAg limited to the margins of the cells in these biopsies.

The number of cells which contained HBsAg varied in different biopsies, and two main groups

could be identified. In the first, there was diffuse staining of sheets of cells affecting up to two-thirds of the liver lobule, while in the second considerably fewer cells were affected (Figs. 1 and 2). There was no particular distribution of HBsAg staining within the lobule in either the diffuse or the focally stained sections.

HBsAg staining and liver lesions

The type of HBsAg staining in biopsies showing

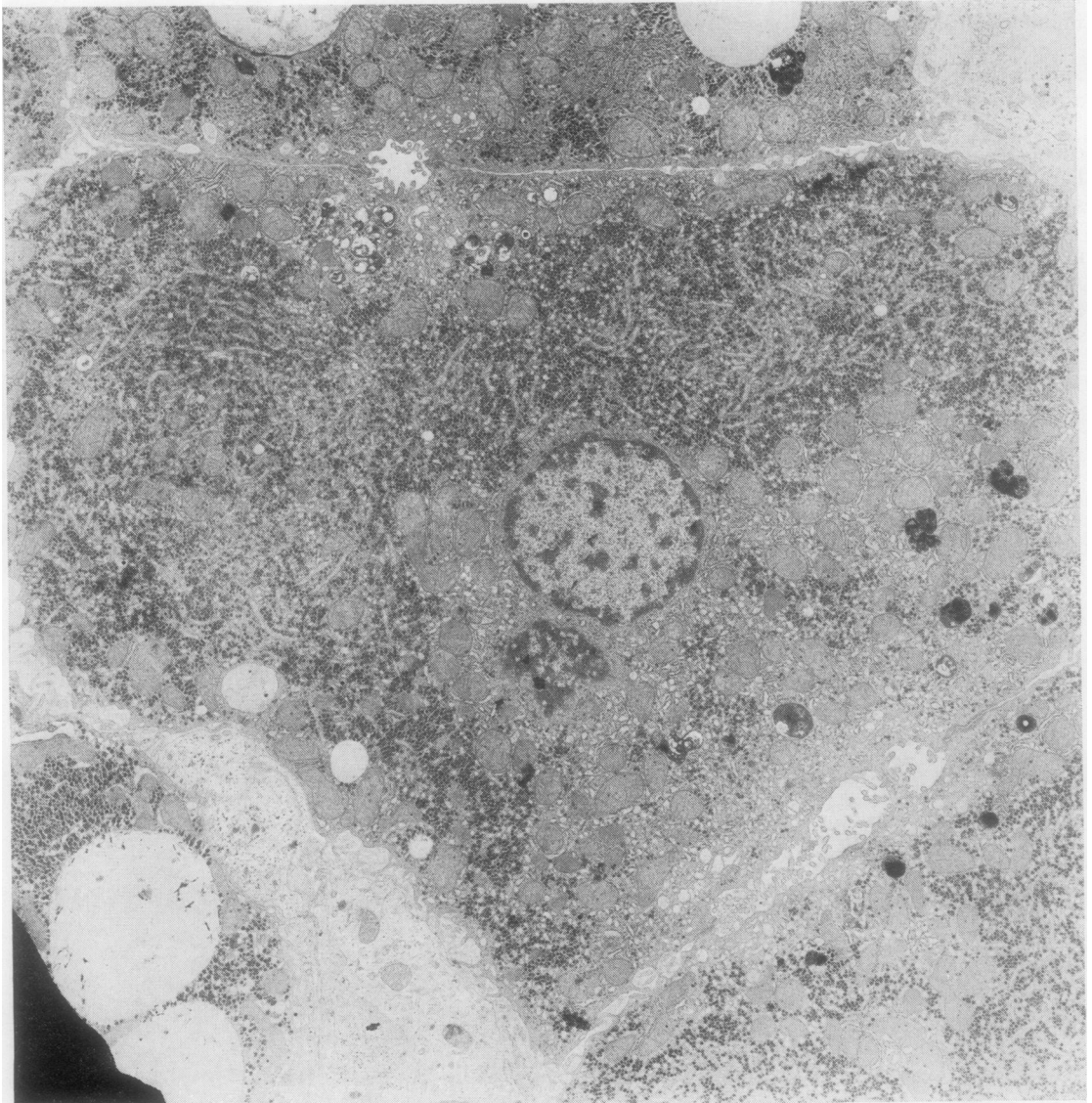


Fig. 4 There is marked dilatation of the endoplasmic reticulum and part of the cytoplasm contains very few mitochondria (upper part of photograph). EM \times 5400.

different histological lesions is given in the Table. Diffuse staining was more common in livers with focal parenchymal necrosis and was seen also in two of the three biopsies showing cirrhosis. Focal staining was seen more commonly in livers showing chronic aggressive hepatitis. Biopsies with the histological lesion of chronic persistent hepatitis showed both patterns of HBsAg staining with equal frequency.

HBsAg staining in sequential biopsies

There was little variation in the pattern of HBsAg staining in the first and subsequent biopsies from each individual.

In these carriers, 2/4 of those having a focal distribution and 5/8 of those having a diffuse distribution of HBsAg showed some deterioration of the histological appearances in the second biopsy; this occurred in only 1/10 carriers in whom HBsAg was not demonstrated in the liver.

IMMUNOPEROXIDASE STAINING FOR HBcAg

Staining was seen only in the nuclei of the hepatocytes. Of 48 biopsies that were stained for HBcAg, in only eight, from four donors, could positively stained nuclei be identified with certainty. In these biopsies only relatively few nuclei stained, and the

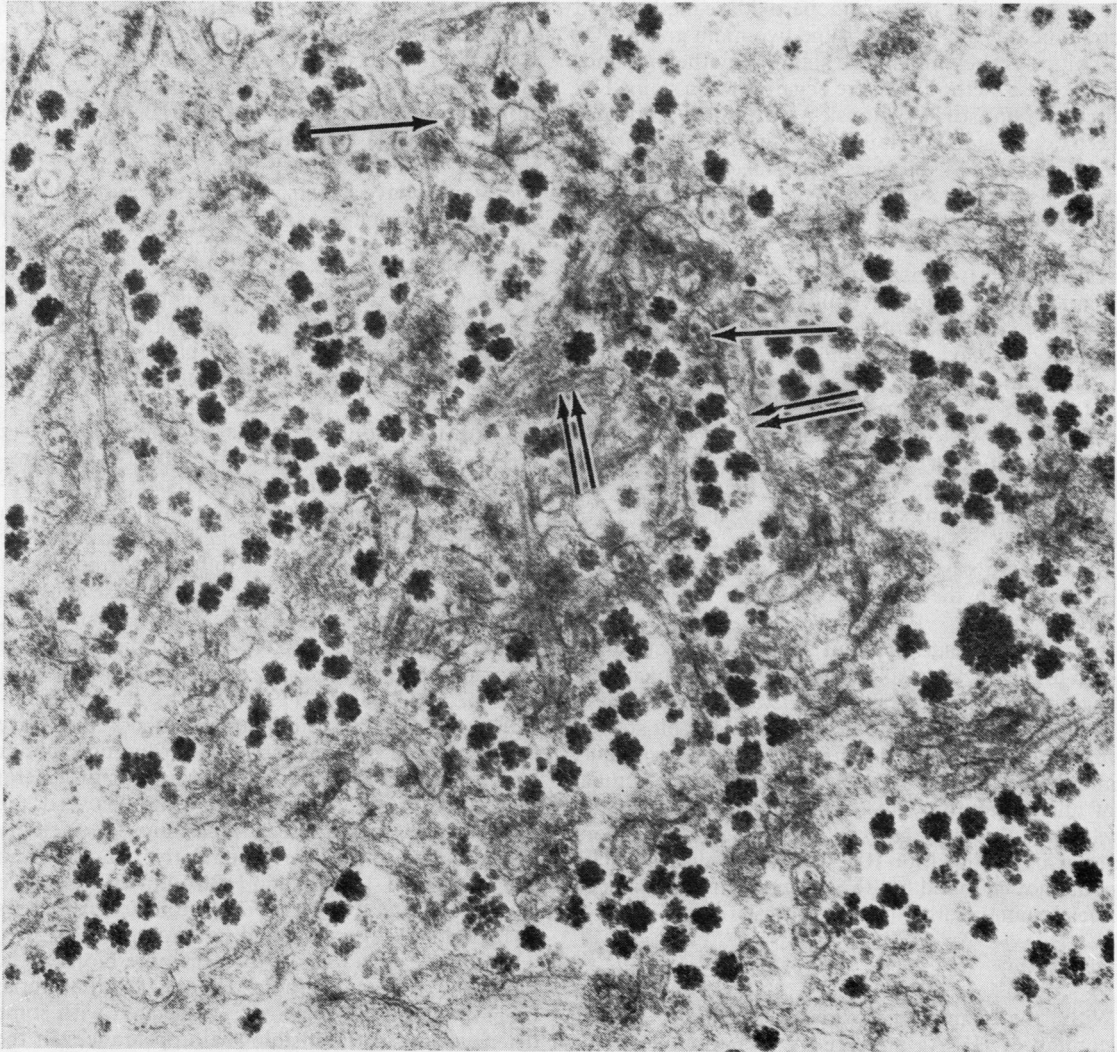


Fig. 5 Round particles (single arrow) and filaments (double arrow) are seen within the dilated endoplasmic reticulum. EM \times 53 250.

degree of HB_cAg staining in individual nuclei in each biopsy varied from brown to black (Fig. 3).

The biopsies from one donor showed chronic persistent hepatitis and, in three, chronic aggressive hepatitis; in two donors, the lesions had increased in severity during the period of study.

There were four other biopsies with occasional nuclei which stained faintly and were regarded as doubtful positives.

ORCEIN STAINING FOR HB_sAg

Biopsies stained with orcein showed the same variability in the extent and degree of cytoplasmic staining in hepatocytes as was seen in those stained for HB_sAg using the immunoperoxidase method and could be divided into the same two main groups. Of 20 biopsies showing diffuse staining by the immunoperoxidase method, 10 were negative when stained by orcein. Nine of 14 biopsies with focal immunoperoxidase staining failed to stain by the orcein method and 14 biopsies were negative by both methods. Orcein staining was clearly the less sensitive method.

ELECTRON MICROSCOPY

Filaments and tubules could be identified in the cytoplasm of hepatocytes in some biopsies. The areas containing these could be identified at low magnification by the presence of 'clear areas', the latter representing parts of the cytoplasm where the endoplasmic reticulum was dilated and there was a reduction of other cytoplasmic components especially mitochondria (Fig. 4). At higher magnification the filaments and tubules could be seen within the dilated endoplasmic reticulum (Fig. 5). These areas could be found more easily in biopsies which had stained diffusely with the immunoperoxidase technique for HB_sAg.

Particles measuring about 20 nm in diameter were seen in the nuclei in six of the 37 biopsies which were examined (three carriers each with two biopsies). The biopsies containing nuclear particles all stained for HB_cAg with the immunoperoxidase technique, and there was a good correlation between the number of nuclei staining with the latter and the ease with which 20 nm particles could be found. In two biopsies which stained for HB_cAg, intranuclear particles could not be found but these contained fewer stained nuclei than the other positive biopsies.

Discussion

With the immunoperoxidase technique specific staining of HB_sAg and HB_cAg was obtained. The morphological appearance of HB_sAg in sections stained by the immunoperoxidase technique is

similar to that described by other workers using this method (Burns, 1975; Nayak and Sachdeva, 1975) or immunofluorescent techniques (Akeyama *et al.*, 1974; Ray *et al.*, 1976). However, staining of the peripheral part of the cytoplasm or of the cell membrane described by the latter two groups of workers was not seen in the present formalin-fixed material.

The immunoperoxidase technique was more time-consuming than orcein staining but was more sensitive and gave clearer staining. Orcein staining was variable in quality because some commercial orcein preparations stain better than others. Afroudakis and his co-workers (1976) also found that immunoperoxidase staining for HB_sAg was more sensitive than orcein, although this was not the experience of Nayak and Sachdeva (1975).

In ultrathin sections, tubular and circular structures were seen in the cytoplasm of hepatocytes in biopsies which were positive for HB_sAg with the immunoperoxidase technique. Gerber and his co-workers (1974), using direct immuno-electron microscopy, have shown that these structures contain HB_sAg determinants, and there is little doubt that these bodies represent cytoplasmic HB_sAg. Examination of the sections by electron microscopy is laborious and only small areas of the liver can be examined by this method. In view of the focal nature of HB_sAg in some sections it is clearly a less satisfactory method for the quantitation of HB_sAg in the liver.

Using the immunoperoxidase technique, HB_sAg was found in the cytoplasm of 71% of biopsies. However, the type of distribution of HB_sAg in the biopsies varied, a focal distribution predominating in those showing the histological lesions of chronic aggressive hepatitis while a diffuse distribution of HB_sAg was seen more commonly in those showing none or only minor histological abnormalities. A similar distribution of HB_sAg in patients with chronic aggressive and persistent hepatitis has been described by Ray *et al.* (1976). Portmann and his co-workers (1976) also found large numbers of positive hepatocytes in chronic carriers showing only minor histological lesions, and it would appear in general that there is an inverse relationship between the amount of HB_sAg in the cytoplasm and the activity of the disease in the liver. The relative amounts and distribution of HB_sAg and HB_cAg in the liver have been related to the different immunological responses to hepatitis B virus infection (Gudat *et al.*, 1975).

In those carriers having two or more biopsies the presence of demonstrable HB_sAg in the initial biopsy was more likely to be associated with some deterioration in the histological appearances in the second biopsy. This appeared to be so irrespective of the amount of HB_sAg in the liver or the initial

histological diagnosis.

The immunoperoxidase technique was also used to demonstrate HB_cAg in the nuclei of hepatocytes. There was a good correlation between the incidence of positive staining and the presence of the 20 nm core particles. It is probable that the increased sensitivity of the immunoperoxidase technique is responsible for the finding of two biopsies positive for HB_cAg by the immunoperoxidase method in which core particles could not be found in the nuclei.

All the biopsies that were positive for HB_cAg showed either chronic aggressive or chronic persistent hepatitis. These HB_cAg positive biopsies came from four blood donors in whom significant numbers of Dane particles had been found repeatedly by electron microscopy of the serum and who are also persistently e antigen positive (Tapp *et al.*, 1974).

References

- Afroudakis, A. P., Liew, C-T., and Peters, R. L. (1976). An immunoperoxidase technic for the demonstration of the hepatitis B surface antigen in human livers. *American Journal of Clinical Pathology*, **65**, 533-539.
- Akeyama, T., Kamada, T., Koyama, M., and Abe, H. (1974). Distribution patterns of hepatitis B antigen in the liver. *Archives of Pathology*, **98**, 252-256.
- Burns, J. (1975). Immunoperoxidase localisation of hepatitis B antigen (HB) in formalin-paraffin processed liver tissue. *Histochemistry*, **44**, 133-135.
- Deodhar, K. P., Tapp, E., and Scheuer, P. J. (1975). Orcein staining of hepatitis B antigen in paraffin sections of liver biopsies. *Journal of Clinical Pathology*, **28**, 66-70.
- Gerber, M. A., Hadziyannis, S., Vissoulis, C., Schaffner, F., Paronetto, F., and Popper, H. (1974). Electron microscopy and immunoelectronmicroscopy of cytoplasmic hepatitis B antigen in hepatocytes. *American Journal of Pathology*, **75**, 489-496.
- Gudat, F., Bianchi, L., Sonnabend, W., Thiel, G., Aenishaenslin, W., and Stalder, G. A. (1975). Pattern of core and surface expression in liver tissue reflects state of specific immune response in hepatitis B. *Laboratory Investigation*, **32**, 1-9.
- Mason, D. Y., Farrell, C., and Taylor, C. R. (1975). The detection of intracellular antigens in human leucocytes by immunoperoxidase staining. *British Journal of Haematology*, **31**, 361-370.
- Millman, I., Zavatore, V., Gerstley, B. J. S., and Blumberg, B. S. (1969). Australia antigen detected in the nuclei of liver cells of patients with viral hepatitis by the fluorescent antibody technique. *Nature*, **222**, 181-184.
- Nayak, N. C. and Sachdeva, R. (1975). Localization of hepatitis B surface antigen in conventional paraffin sections of the liver. *American Journal of Pathology*, **81**, 479-490.
- Nowoslawski, A., Brzosko, W. J., Madalinski, K., and Krawczynski, K. (1970). Cellular localisation of Australia antigen in the liver of patients with lymphoproliferative disorders. *Lancet*, **1**, 494-498.
- Portmann, B., Galbraith, R. M., Eddleston, A. L. W. F., Zuckerman, A. J., and Williams, R. (1976). Detection of HB_sAg in fixed liver tissue—use of a modified immunofluorescent technique and comparison with histochemical methods. *Gut*, **17**, 1-9.
- Ray, M. B., Desmet, V. J., Fevery, J., De Groote, J., Bradburne, A. F., and Desmyter, J. (1976). Distribution patterns of hepatitis B surface antigen (HB_sAg) in the liver of hepatitis patients. *Journal of Clinical Pathology*, **29**, 94-100.
- Shikata, T., Uzawa, T., Yoshiwara, N., Akatsuka, T., and Yamazaki, S. (1974). Staining methods of Australia antigen in paraffin section—detection of cytoplasmic inclusion bodies. *Japanese Journal of Experimental Medicine*, **44**, 25-36.
- Tapp, E., Jones, D. M., Anfield, C., Whittaker, J. S., Woolf, I. L., and Dymock, I. W. (1974). Intranuclear particles in hepatocytes of HB_sAg-positive blood donors (Letter). *Lancet*, **1**, 934.
- Tapp, E., Jones, D. M., Hollanders, D., and Dymock, I. W. (1976). Serial liver biopsies in blood donors with persistent HB_s antigenaemia. *Journal of Clinical Pathology*, **29**, 884-886.
- Trepo, C., Vitvitski, L., Neurath, R., Hashimoto, N., Schaefer, R., Nemoz, G., and Prince, A. M. (1976). Detection of e antigen by immunofluorescence in cytoplasm of hepatocytes of HB_sAg carriers (Letter). *Lancet*, **1**, 486.
- Woolf, I. L., Boyes, B. E., Jones, D. M., Whittaker, J. S., Tapp, E., MacSween, R. N. M., Renton, P. H., Stratton, F., and Dymock, I. W. (1974). Asymptomatic liver disease in hepatitis B antigen carriers. *Journal of Clinical Pathology*, **27**, 348-352.