

Microangiopathic haemolytic anaemia associated with malignant haemangio-endothelioma

D. DONALD AND AUDREY A. DAWSON

From the Departments of Pathology and Medicine, University of Aberdeen

SYNOPSIS A case of microangiopathic haemolytic anaemia associated with malignant haemangio-endothelioma is described. It is suggested that haemolysis may have been due to mechanical trauma sustained by the red blood cells on passage through the tumour's abnormal vasculature.

The malignant haemangio-endothelioma consists of anastomosing networks of aberrant capillaries lined by malignant endothelial cells. These tumours develop frequently, and often multilocally, within the reticulo-endothelial system, especially in the spleen and liver. Some appear to have haemopoietic potential (Evans, 1966). The tumour is uncommon. Although a case had been reported by Langhans in 1879, the term 'haemangio-endothelioma' was not coined until 1908, by Mallory. In 1943, Stout could assemble only 18 cases, but by 1966 this number had risen to 155 (Stout and Lattes, 1966).

We report a further case, in which the presenting feature was a microangiopathic haemolytic anaemia.

Case Report

A 59-year-old man was referred to the surgical outpatient department in December 1967 after an episode of melaena five weeks previously. For 25 years he had had intermittent mild melaena, associated with periodic heartburn and midepigastic discomfort. He was intolerant of oral iron. The only major episode in his previous medical history was the drainage of a right perinephric abscess in 1948. There was no history of Thorotrast administration.

On examination, apart from mucosal pallor, and some flattening and softening of the finger nails, no significant abnormality was detected. The stool orthotolidine test was negative. The haemoglobin was 10 g per 100 ml (69%), the red blood cells were moderately microcytic and hypochromic, and the white blood cells were normal. A barium meal demonstrated a persistent deformity of the duodenal cap.

In view of the frequent episodes of minor haemor-

rhage, elective gastric surgery was advised. Pyloroplasty and vagotomy were performed by Mr J. Kyle on 22 March 1968, preoperative assessment having shown a high level of gastric acid after histamine. The patient had an uneventful postoperative course,

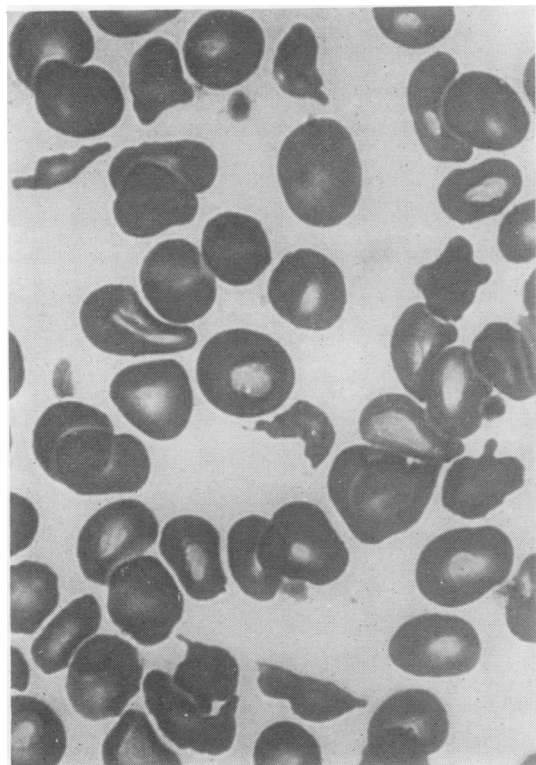


Fig. 1 Blood film showing fragmented red blood cells, $\times 1,000$.

Received for publication 3 September 1970.

and was advised to continue with oral iron after discharge from hospital.

On review in early May 1968, he complained of weight loss and tiredness. Blood count was: haemoglobin 8.8 g per 100 ml (60%), WBC count 13,900 per cmm, differential count 77% neutrophil polymorphs. Platelets were scanty on the blood film. The red blood cells showed marked anisocytosis, with many fragmented cells (schistocytes) and moderate polychromasia (Fig. 1). The patient was admitted to hospital for haematological diagnosis and management.

Physical examination revealed an ill man, febrile (temperature 100°F), with a striking number of de Morgan's spots on the trunk. The spleen was palpable two fingerbreadths and the liver one fingerbreadth below the costal margin. There were a few small lymph nodes palpable in both axillae.

INVESTIGATIONS

The urine contained a large excess of urobilinogen, but no bile. The stool orthotolidine test was persistently negative. The reticulocyte count was 7%, the platelet count 35,000 per cmm. The red blood cell fragility test was normal; a direct Coombs test negative; liver function tests normal, apart from a very high serum alkaline phosphatase (57 King-Armstrong units); serum proteins showed a non-

specific increase in alpha₂ and gamma globulin. Marrow, obtained from the iliac crest with a Gardner trephine needle, showed gross erythroid hyperplasia with some macronormoblasts, scanty, though platelet-producing megakaryocytes, and no other abnormality. The bone structure was normal. Percutaneous lymphography revealed no abnormality in the inguinal, pelvic, or para-aortic nodes.

During these investigations, the patient was deteriorating. The haemoglobin fell to 6.5 g per 100 ml (45%), macrocytes appeared, and the reticulocyte count rose to 19%. The polymorph leucocytosis persisted, but the platelet count fell to 14,000 per cmm. The normal plasma fibrinogen was taken to indicate that there was no definite evidence of diffuse intravascular coagulation. Further studies of the coagulation and fibrinolysis mechanisms were, unfortunately, not undertaken. The spleen enlarged to four fingerbreadths below the costal margin, without change in the size of the liver. Neither corticosteroids nor ACTH had any effect on the clinical or haematological state. Splenectomy with liver biopsy was performed by Mr J. Kyle on 5 June 1968 under cover of platelet-rich blood.

The immediate effect of splenectomy was to slow down the rate of haemolysis. The reticulocyte counts stabilized at 4-7%, and the platelet count rose to a plateau of about 50,000 per cmm for four weeks,

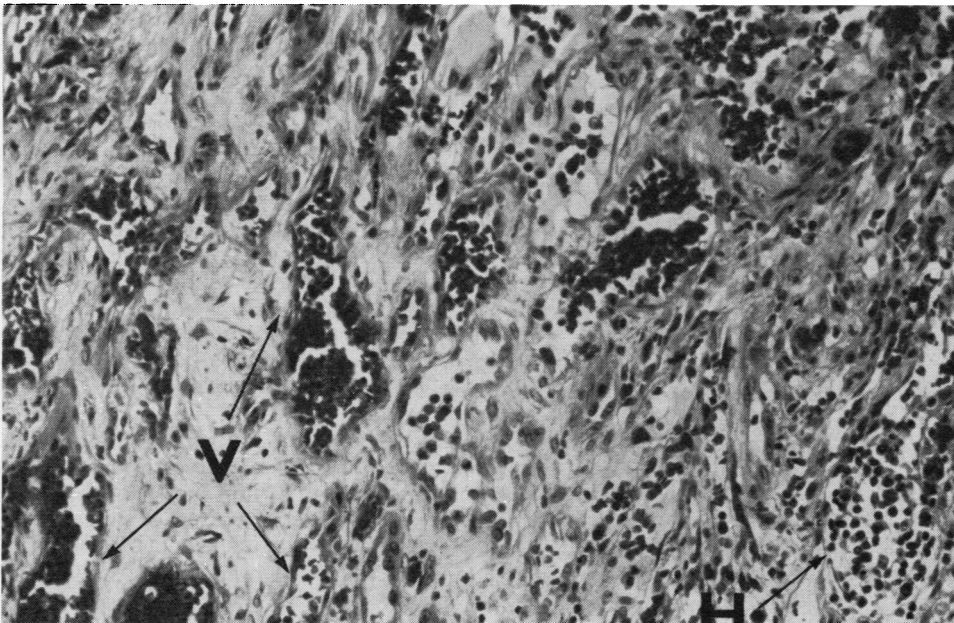


Fig. 2 Splenic tumour showing the vascular structure (V) and a focus of haemopoiesis (H). Haematoxylin and eosin, $\times 150$.

but during this time the liver had enlarged rapidly. Terminally the patient became severely anaemic and thrombocytopenic. He died with a massive generalized haemorrhage on 10 July 1968.

PATHOLOGY

The resected spleen (1.4 kg) was extensively infiltrated by haemorrhagic tumour nodules which were on average 3 cm in diameter, many showing central zones of necrosis. Histologically, the tumour deposits consisted largely of highly cellular compact sheets of fusiform cells, but also contained areas showing an obvious vascular structure: aberrant anastomosing blood-filled vascular channels were lined by pleomorphic endothelial cells (Fig. 2). Reticulin preparations confirmed the presence of a suspected underlying vasoformative pattern in the compact cellular areas (Fig. 3). Foci of extra-medullary haemopoiesis were widely distributed within the tumour nodules (Fig. 2), and groups of tumour cells containing haemosiderin were noted in

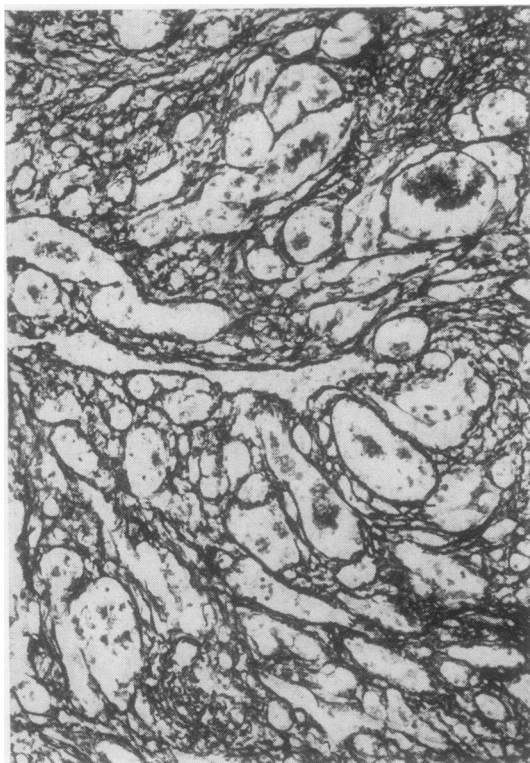


Fig. 3 Reticulin preparation demonstrates the underlying vascular structure in an area of compact cellular overgrowth. Gordon and Sweet's silver impregnation method, $\times 150$.

Perls' prussian blue preparations. A diagnosis of malignant haemangio-endothelioma was made. The tumour deposits in the biopsy specimen of liver showed similar features.

At necropsy the liver (4.1 kg) was widely infiltrated by a large number of haemorrhagic tumour nodules varying from a few millimetres to 3 cm in diameter. The lymph nodes in the porta hepatis were also extensively involved by similar tumours. Two further deposits were identified, one in a rib, the other in the fourth lumbar vertebral body. The histological appearances of these tumours were similar to those in the resected spleen.

An estimated 2.5 l of blood had accumulated in the alimentary tract as a result of a generalized ooze from numerous minute bleeding points on the gastric mucosa and along the entire length of the intestine. A diverticulum of the third part of the duodenum was an incidental finding. There were no other positive findings of note.

Discussion

Malignant haemangio-endothelioma is a diagnosis made only with great caution. Stout (1943) laid down strict criteria for the histological diagnosis: he stressed in particular the value of reticulin preparations in revealing the underlying vascular structure of areas of profuse endothelial overgrowth. In our case the reticulin pattern in the highly cellular areas was of considerable diagnostic value, although there were several conspicuous foci showing an obvious vasoformative structure. The tumour deposits in liver and spleen showed haemopoietic potentials which is a well recognized feature of the malignant haemangio-endothelioma. In addition, groups of tumour cells showed evidence of phagocytic activity by virtue of their haemosiderin content. This accords with the view that some malignant haemangio-endotheliomas may take origin from the phagocytic lining of sinusoids (Evans, 1966).

The association of haematological disorders with tumours of vasoformative tissue is well established: thrombocytopenia is found with extensive or multiple haemangiomas (Southard, Desanctis, and Waldron, 1951), and anaemia is a well recognized concomitant of malignant haemangio-endothelioma. Various workers (eg, Shennan, 1914; Wright, 1949) have commented that the appearances of the blood film in patients with malignant haemangio-endothelioma resemble those of pernicious anaemia. Bourne, Cook, and Williams (1965) have described two patients with a leuco-erythroblastic anaemia which they attributed to infiltration of the marrow by haemangio-endothelioma. None of these workers remarked on a haemolytic element of the anaemia.

In our patient, haemolysis was the prominent feature, and it was accompanied by the appearance of many schistocytes in the peripheral blood and by thrombocytopenia. These findings are very typical of a microangiopathic haemolytic anaemia.

The concept of haemolysis resulting from mechanical damage to red blood cells by abnormalities of the vessel walls is fairly recent (Brain, Dacie, and Hourihane, 1962). In many cases of microangiopathic haemolytic anaemia fibrin thrombi arising in abnormal blood vessels assist in producing haemolysis and are responsible for the rapid removal of circulating platelets. These thrombi were not identified histologically in our case. It may be that mechanical damage to the red blood cells caused solely by contact with the malignant endothelial lining of the tumour vessels accounted for the severe haemolysis.

A similar mechanism may contribute to the anaemia in many cases of malignant haemangio-endothelioma. Certainly Wright's description (1949) of the blood film, with anisocytosis, poikilocytosis, and polychromasia of the red blood cells, the presence of nucleated red cell precursors, and leucopenia and thrombocytopenia, is very suggestive of microangiopathic haemolytic anaemia. Fragmented red cells were not specifically mentioned.

The presence of a microangiopathic haemolytic anaemia and a rapidly enlarging spleen should suggest malignant haemangio-endothelioma as a

possible diagnosis, or should at least focus attention on the blood vessels as well as on the blood cells.

We wish to thank Mr J. Kyle, Woodend General Hospital, Aberdeen, for his help and cooperation in the management of the patient, and Professor A. R. Currie, Department of Pathology, University of Aberdeen, for his helpful criticism in the preparation of this paper.

References

- Bourne, M. S., Cook, T. A., and Williams, G. (1965). Haemangiosarcomatosis: two cases presenting as haematological problems. *Brit. med. J.*, 2, 275-276.
- Brain, M. C., Dacie, J. V., and Hourihane, D. O'B. (1962). Microangiopathic haemolytic anaemia: the possible role of vascular lesions in pathogenesis. *Brit. J. Haemat.*, 8, 358-374.
- Evans, R. W. (1966). *Histological Appearances of Tumours*, 2nd ed., p. 107. Livingstone, Edinburgh.
- Langhans, T. (1879). Pulsierende cavernöse Geschwulst der Milz mit metastatischen Knoten in der Leber. *Virchows Arch. path. Anat.*, 75, 273-291.
- Mallory, F. B. (1908). The results of the application of special histological methods to the study of tumours. *J. exp. Med.*, 10, 575-593.
- Shennan, T. (1914). Histologically non-malignant angioma, with numerous metastases. *J. Path. Bact.*, 19, 139-154.
- Southard, S. C., Desanctis, A. G., and Waldron, R. J. (1951). Hemangioma associated with thrombocytopenic purpura. *J. Pediat.*, 38, 732-737.
- Stout, A. P. (1943). Hemangio-endothelioma: a tumour of blood vessels featuring vascular endothelial cells. *Ann. Surg.*, 118, 445-464.
- Stout, A. P., and Lattes, R. (1966). *Tumors of Soft Tissues*. Atlas of Tumor Pathology, 2nd series, Fasc. 1, p. 145. Armed Forces Institute of Pathology, Washington, DC.
- Wright, M. (1949). Hemangiosarcoma of the spleen. *Arch. Path.*, 47, 180-190.