

Ultrastructure of a glomus tumour

M. HARRIS

From the Department of Pathology, University of the West Indies, Kingston, Jamaica

SYNOPSIS The ultrastructure of a glomus tumour is described, and the implications of the findings with regard to the histogenesis of this type of tumour are briefly discussed.

Floël, Hammersen, and Staubesand (1967) gave the first account of the fine structure of a glomus tumour. Their findings indicated that its 'epithelioid' cells were of smooth muscle type, and have been confirmed by other authors (Murad, von Haam, and Murthy, 1968; Rascol, Izard, and Rascol, 1968; Venkatachalam and Grealley, 1969; Tarnowski and Hashimoto, 1969; Kuhn and Rosai, 1969). The principal features indicating the relationship between the tumour cells and smooth muscle have been the presence of cytoplasmic myofibrils with characteristic zones of focal condensation, large numbers of pinocytic vesicles, and a conspicuous zone of electron-dense material between adjacent cells. In some of the reported examples mast cells have been a notable feature (Murad *et al.*, 1968; Rascol *et al.*, 1968; Tarnowski and Hashimoto, 1968; Goodman and Abele, 1971).

The ultrastructure of a further example is described here.

Materials and Methods

The patient was a 60-year-old man who complained of a small, painful nodule beneath the skin of the left wrist. The nodule, which was 0.6 cm diameter and brown in colour, was excised and sent for histological examination fixed in 10% formol saline. Half of the nodule was embedded in paraffin wax and 5 μ sections were stained with haematoxylin and eosin and by Gordon and Sweet's method for reticulin fibres.

After two weeks the remainder of the tumour was retrieved from the formol saline, cut into 1 mm cubes, and washed overnight in phosphate-buffered sucrose (pH 7.2) at 4°C. The tissue was then post-fixed in osmium tetroxide at 4°C for two hours and embedded in Epon. Sections were cut on a Reichert ultramicrotome, stained with uranyl acetate and lead citrate and examined in an Hitachi HS7S electron microscope.

Received for publication 27 October 1970.

The method of fixing in formol saline a specimen intended for routine histological examination has given rise to certain artefacts in the electron micrographs. These are coarse clumping of chromatin, a number of empty spaces in the cytoplasm, and swelling of some mitochondria. The changes are apparent in Figs. 2 and 3; however, in other respects preservation of cellular detail is adequate and emphasizes the fact that useful information may be obtained in selected cases by electron microscopic study of material submitted for routine histology.

Results

LIGHT MICROSCOPY

The lesion was a glomus tumour and consisted of close packed, uniform, round, or oval cells surrounding a number of inconspicuous vascular channels (Fig. 1). The cells had eosinophilic or clear cytoplasm and round, rather densely stained nuclei. The reticulin preparation emphasized the extravascular position of the tumour cells.

ELECTRON MICROSCOPY

In all the sections examined the tumour cells had a uniform appearance (Figs. 2 and 3). They varied between 9 μ and 12.2 μ in their greatest diameter, were oval or polygonal, and dovetailed closely with their neighbours, being separated from them by a fairly constant, narrow intercellular space. This space was filled with electron-dense material of similar appearance to basement membrane.

The nuclei were round or oval with slight irregularities of outline and nucleoli were often seen.

Mitochondria were numerous and often grouped in clusters. A Golgi apparatus was seen only infrequently but when present was well developed. Endoplasmic reticulum was scanty.

Large areas of cytoplasm, both near the nucleus and peripherally, had a finely fibrillar structure with scattered zones of electron density, appearances

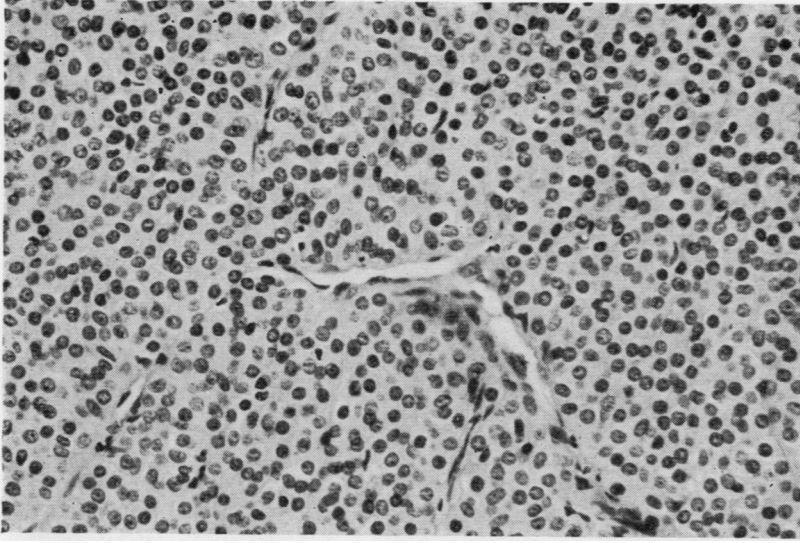


Fig. 1 *Light micrograph. Closely packed glomus cells surround small vascular channels. Haematoxylin and eosin $\times 325$.*

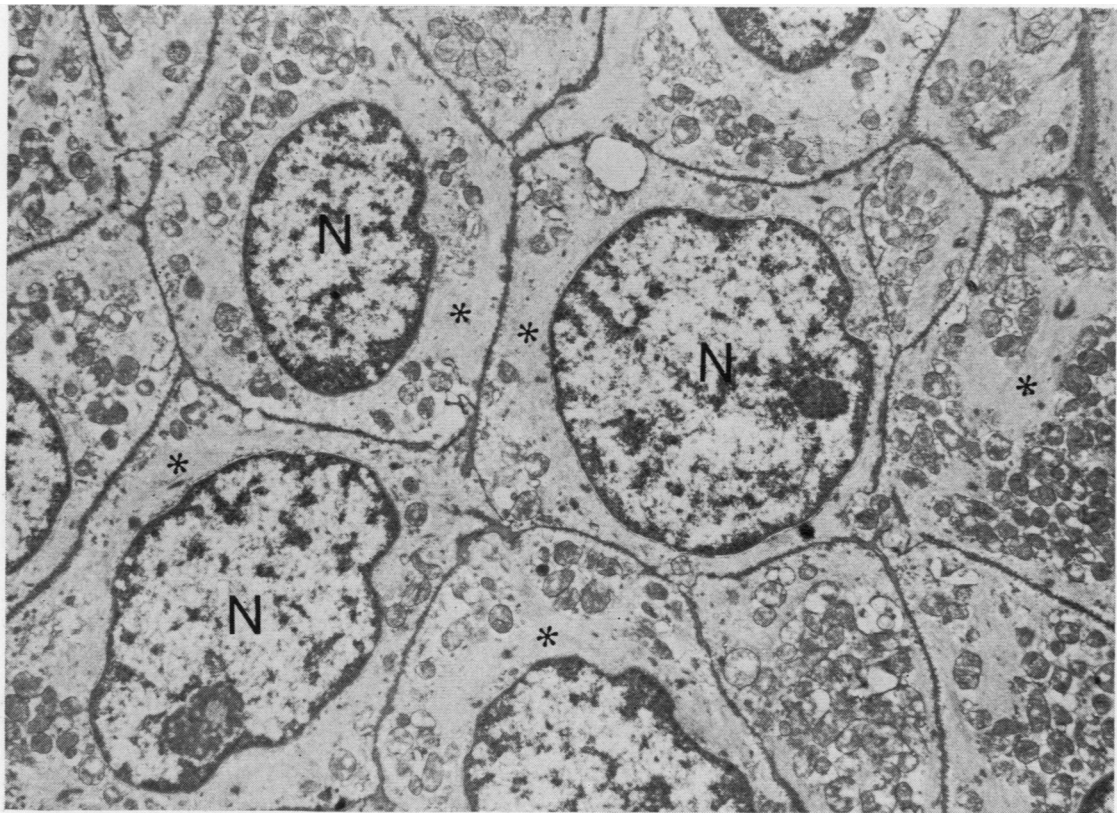


Fig. 2 *Low-power electron micrograph demonstrating the uniformity of the tumour cells and the regular intercellular space filled with electron-dense material. Myofibrils occupy the zones of cytoplasm indicated by asterisks. Uranyl acetate and lead citrate $\times 9,000$. N: nucleus.*

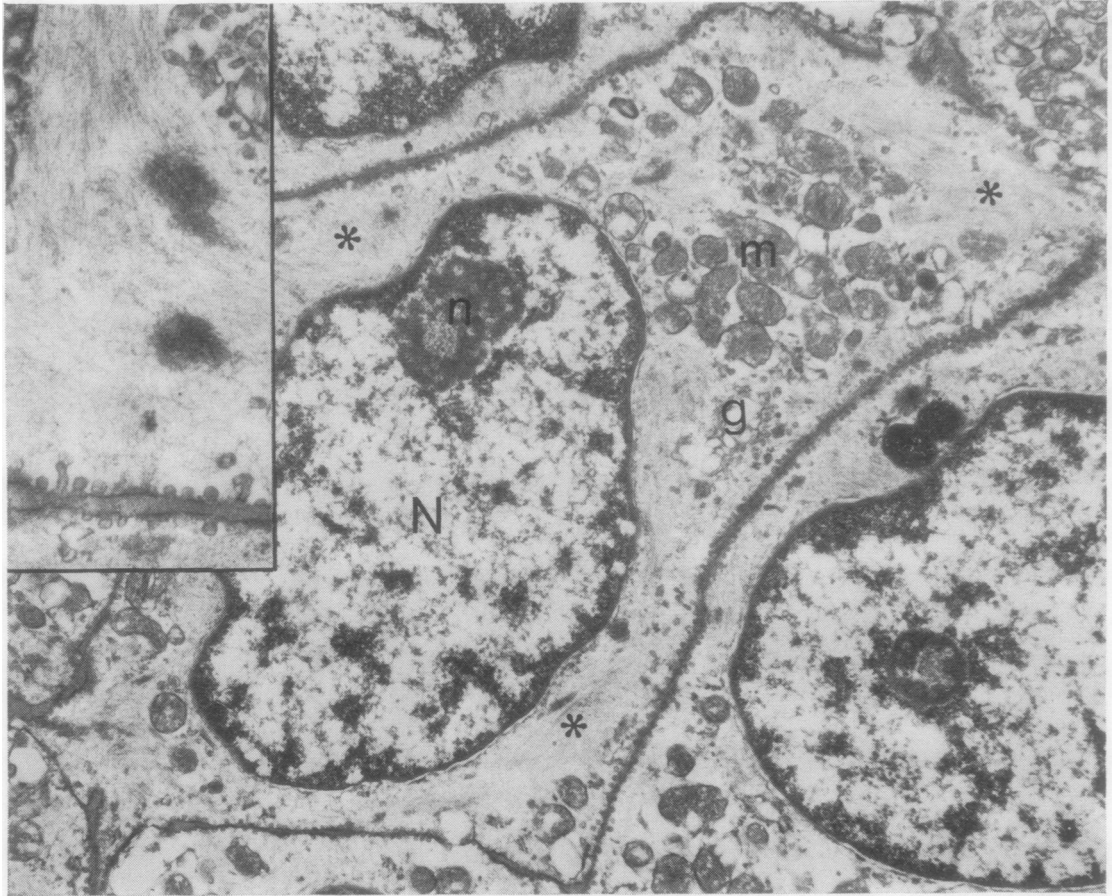


Fig. 3 Electron micrograph. Abundant pinocytotic vesicles are visible at this magnification. Asterisks indicate fibrillar zones of cytoplasm. The inset shows pinocytotic vesicles and cytoplasmic fibrils with zones of electron density in more detail. Uranyl acetate and lead citrate $\times 15,000$. Inset $\times 36,000$. N: nucleus; n: nucleolus; m: mitochondria; g: Golgi apparatus.

similar to those seen in smooth muscle cells. A further striking feature was the presence of abundant pinocytotic vesicles bordering all the cells examined.

In the few capillaries included in the sections there was a complete lining of non-fenestrated endothelial cells. Tumour cells extended up to the capillary basement membrane but did not come into contact with the lumen of the vessel as they did in the tumour reported by Toker (1969).

Mast cells were not seen although they have been a feature in some examples (Murad *et al*, 1968; Rascol *et al*, 1968; Tarnowski and Hashimoto, 1969).

Discussion

The ultrastructural features described above, notably

the presence of cytoplasmic fibrils with associated focal condensations and abundant pinocytotic vesicles, indicate that the cells of the glomus tumour are related to smooth muscle. These findings are in general agreement with other reports of the ultrastructure of glomus tumours (Flöel *et al*, 1967; Murad *et al*, 1968; Rascol *et al*, 1968; Venkatachalam and Greally, 1969; Tarnowski and Hashimoto, 1969; Kuhn and Rosai, 1969; Goodman and Abele, 1971).

The generally accepted concept of the histogenesis of the glomus tumour is based on the study of Murray and Stout (1942) in which, as a result of tissue culture experiments, they suggested that the epithelioid cells of glomus tumours were derived from vascular pericytes. It was suggested that the latter might be modified smooth muscle cells and, in a separate paper, that the haemangiopericytoma was

a related tumour (Stout and Murray, 1942). Subsequently, however, it has been shown that normal vascular pericytes resemble fibroblasts and do not have the ultrastructural features of smooth muscle (Fawcett, 1963; Rhodin, 1967) and neither do the cells of those haemangiopericytomas that have been studied by electron microscopy (Ramsey, 1966; Paullada, Lisci-Garmilla, Gonzales-Angulo, Jurado-Mendoza, Quizano-Narezo, Gomez-Peralto, and Doria-Medina, 1968; Murad *et al*, 1968).

Thus, although ultrastructural studies of glomus tumours support the view that their epitheloid cells are of smooth muscle type, there is no evidence from electron microscopy that they are derived from pericytes and the grounds for regarding glomus tumours and haemangiopericytomas as being histogenetically related therefore appear to be unsound.

References

- Fawcett, D. W. (1963). In *The Peripheral Blood Vessels*. International Academy of Pathology Monograph No. 4, edited by J. Lowell Orbison and David E. Smith, p. 23. Williams and Wilkins, Baltimore.
- Flöel, H., Hammersen, F., and Staubesand, J. (1967). Weitere elektronenmikroskopische Untersuchungen an den epitheloiden Gefäßwandzellen; Beobachtungen an Glomustumoren (Masson). *Verh. anat. Ges.*, 62, 295-300.
- Goodman, T. F., and Abele, D. C. (1971). Multiple glomus tumours. *Arch. Derm.*, 103, 11-23.
- Kuhn, C. III, and Rosai, J. (1969). Tumors arising from pericytes. Ultrastructure and organ culture of a case. *Arch. Path.*, 88, 653-663.
- Murad, T. M., von Haam, E., and Murthy, M. S. N. (1968). Ultrastructure of a haemangiopericytoma and a glomus tumour. *Cancer (Philad.)*, 22, 1239-1249.
- Murray, M. R., and Stout, A. P. (1942). The glomus tumor. Investigation of its distribution and behavior and the identity of its 'epithelioid' cell. *Amer. J. Path.*, 18, 183-203.
- Paullada, J. J., Lisci-Garmilla, A., Gonzales-Angulo, A., Jurado-Mendoza, J., Quijano-Narezo, M., Gómez-Peralta, L., and Doria-Medina, M. (1968). Hemangiopericytoma associated with hypoglycemia. Metabolic and electron microscopic studies of a case. *Amer. J. Med.*, 44, 990-999.
- Ramsey, H. J. (1966). Fine structure of hemangiopericytoma and hemangioendothelioma. *Cancer (Philad.)*, 19, 2005-2018.
- Rascol, M., Izard, J., and Rascol, A. (1968). Étude ultrastructurale d'une tumeur glomique de Masson. *Observation anatomoclinique. Presse méd.*, 76, 1695-1698.
- Rhodin, J. A. G. (1967). In *The Connective Tissue*. International Academy of Pathology Monograph No. 7. Edited by Bernard M. Wagner and David E. Smith. Williams and Wilkins, Baltimore.
- Stout, A. P., and Murray, M. R. (1942). Hemangiopericytoma: a vascular tumor featuring Zimmerman's pericytes. *Ann. Surg.*, 116, 26-33.
- Tarnowski, W. M., and Hashimoto, K. (1969). Multiple glomus tumors. An ultrastructural study. *J. invest. Derm.*, 52, 474-478.
- Toker, C. (1969). Glomangioma. An ultrastructural study. *Cancer (Philad.)*, 23, 487-492.
- Venkatachalam, M. A., and Grealley, J. G. (1969). Fine structure of glomus tumor: similarity of glomus cells to smooth muscle. *Cancer (Philad.)*, 23, 1176-1184.