

Central retinal artery pressure and carotid artery stenosis

RAN SUN^{1,2}, XIAO-YAN PENG¹, QI-SHENG YOU¹, LI-QUN JIAO³ and JOST B. JONAS⁴

¹Beijing Ophthalmology and Visual Science Key Laboratory, Beijing Institute of Ophthalmology, Beijing Tongren Eye Center, Beijing Tongren Hospital, Capital Medical University, Beijing 100005; Departments of ²Ophthalmology and

³Interventional Radiology, Beijing Xuan Wu Hospital, Capital Medical University, Beijing 100053, P.R. China;

⁴Department of Ophthalmology, Faculty of Clinical Medicine Mannheim, University of Heidelberg, D-68167 Mannheim, Germany

Received September 15, 2015; Accepted December 10, 2015

DOI: 10.3892/etm.2016.3013

Abstract. The central retinal artery (CRA), which can be non-invasively examined with ophthalmoscopy, may be regarded as an extracranial part of the cerebrovascular system. Assessment of CRA pressure may be of help in assessing the impediment of the intracranial blood circulation in patients with a carotid artery stenosis (CAS). The aim of this study was to explore the potential associations between diastolic central retinal artery pressure (diastCRAP) and CAS. The prospective longitudinal clinical observational study included patients with CAS and a control group without CAS. diastCRAP was assessed using ophthalmodynamometry. The study group consisted of 95 patients with CAS (50 of whom had >75% CAS and underwent surgery; the surgical study group) and a control group of 64 individuals without CAS. In all study participants, a lower diastCRAP was significantly associated with a higher degree of CAS ($P < 0.001$). Multivariate analysis indicated that a higher CAS degree was significantly (correlation coefficient: $r = 0.75$) associated with a higher brachial diastolic blood pressure ($P < 0.001$) and lower diastCRAP ($P < 0.001$). Within the surgical study group at the baseline of the study, diastCRAP was significantly lower at the surgical side than at the contralateral side ($P = 0.02$). The diastCRAP on the surgical side increased significantly ($P < 0.001$) after surgery. In the surgical study group at baseline, diastCRAP on the surgical side was not significantly associated with brachial diastolic blood pressure ($P = 0.22$), whereas after surgery, diastCRAP was significantly associated with brachial diastolic blood pressure ($P = 0.001$). DiastCRAP was found to be significantly and linearly corre-

lated with the degree of CAS in intra-individual inter-eye, inter-individual and intra-individual follow-up comparisons. The strong and linear association between diastCRAP and the degree of CAS suggest that diastCRAP should be explored further for use as an indicator of cerebrovascular status.

Introduction

The central retinal artery (CRA), as branch of the ophthalmic artery and the internal carotid artery, can be regarded as an extracranial part of the cerebrovascular system. Since it is possible to examine the CRA ophthalmoscopically, assessment of CRA pressure may be of assistance in obtaining information regarding the impediment of intracranial blood circulation in patients with stenosis of the internal carotid artery or common carotid artery (1-6). The previously developed technique of contact lens-associated ophthalmodynamometry allows the non-invasive estimation of the diastolic CRA pressure (diastCRAP) (7-10). The ophthalmodynamometer consists of a corneal contact lens which facilitates visualization of the central retinal artery using slit-lamp based ophthalmoscopy. This technique allows pressure to be exerted on the eye to increase the intraocular pressure up to the point when the central retinal artery begins to pulsate, which facilitates measurement of the pressure exerted on the eye at the point when the retinal artery begins pulsating (7-10). Previous studies have demonstrated that patients who have undergone internal carotid artery dissection exhibited abnormally low diastCRAP values, as determined by ophthalmodynamometry (10-12). Notably, these ophthalmodynamometry-assessed diastCRAP values correlated with diastolic arterial blood pressure measurements which were conventionally performed on the upper arm. Furthermore, patients with ischemic ophthalmopathy exhibited abnormally low diastCRAP values following ophthalmodynamometry. Carotid artery stenosis is one of the most common causes of cerebral stroke, which remains one of the most common causes of increased disability adjusted life years (13).

Larger studies investigating the association between the presence and degree of carotid artery stenosis (CAS) and ophthalmodynamometry-determined diastCRAP remain scarce. Therefore, the aim of the present study was to

Correspondence to: Professor Xiao-Yan Peng, Beijing Ophthalmology and Visual Science Key Laboratory, Beijing Institute of Ophthalmology, Beijing Tongren Eye Center, Beijing Tongren Hospital, Capital Medical University, 17 Hougou Lane, Chongnei Street, Beijing 100005, P.R. China
E-mail: drpengxy@163.com

Key words: central retinal artery pressure, carotid artery stenosis, ophthalmodynamometry, carotid artery stenosis, ischemic ophthalmopathy

examine whether diastCRAP is associated with the presence and degree of CAS and whether diastCRAP alters when patients undergo surgical treatment for CAS.

Materials and methods

Patient enrolment. This prospective clinical observational study included patients of a study group who suffered from a CAS or carotid artery occlusion and who were consecutively admitted to the Department of Neurosurgery at Xuanwu Hospital, Capital Medical University (Beijing, China) between January 2014 and April 2014. The protocol of the present study was approved by the Medical Ethics Committee of Xuanwu Hospital (BCT01994187) and all participants provided written informed consent. Exclusion criteria were signs of iris neovascularization, neovascular glaucoma or any other type of glaucoma. The study additionally included individuals of a control group of patients with cataract or other ocular disorders such as refractive error problems without association to the retina, optic nerve or cerebrovascular system. The examiners were not masked with respect to study group or control group status; however, they were masked with respect to the degree of CAS within the surgical study group or within the non-surgical study group.

Ophthalmological examination. All study participants underwent a routine ophthalmological examination including measurement of best-corrected visual acuity, tonometry and slit lamp-assisted biomorphometry of the anterior ocular segment and ophthalmoscopy. At the first day of admission to the hospital and at the first day after surgery, ophthalmodynamometry was additionally performed for measurement of diastCRAP. The patients received 1 drop of 0.5% tropicamide (Santen Pharmaceutical Co., Ltd., Osaka, Japan) to induce medical mydriasis. Approximately 10 min later, the corneal surface was topically anesthetized by the instillation of 1 drop of 0.5% proparacaine (Santen Pharmaceutical Co., Ltd.). An ophthalmodynamometer (Meditron GmbH, Völklingen, Germany) was placed onto the anesthetized corneal surface. The ophthalmodynamometer consisted of a conventional Goldmann contact lens that additionally included a pressure sensor at its margin where the contact lens was held during the ophthalmoscopic examination. Using a slit lamp, the optic nerve head was observed through the Goldmann contact lens. The pressure applied onto the globe of the eye through the contact lens was slightly and continuously increased until the CRA started to show pulsations. The pressure asserted onto the eye through the contact lens at this time point was noted. The pressure was provided in force units. On the basis of calculations conducted by Morgan *et al*, the force unit of the device was the equivalent of 0.89 mmHg of intraocular pressure (14). All measurements were repeated nine times. The mean of the 10 measurements was taken for further statistical analysis. The value was designated the ophthalmodynamometric value (ODM-value). The intraocular pressure measured at the baseline of the examination was added to the ODM-value and the sum of the two values was the diastCRAP.

The ophthalmodynamometric method has previously been described in detail (10,11,14-16). The reproducibility of the

technique has been evaluated in previous studies, in which the coefficient of variation for the re-determination of the ODM-value was $9.1 \pm 4.2\%$ (14,15). The systolic CRA pressure, which would have been defined as the pressure asserted onto the globe of the eye at the time point when the CRA stopped to pulsate without showing any sign of further perfusion, was not measured since it would have been necessary to induce complete CRA occlusion by the contact lens-induced pressure on the globe. Although the retinal ischemic tolerance time may be ≥ 90 min according to studies by Hayreh and Jonas (17), the risk of inducing damage to the retina and optic nerve was considered to be too high for such testing to be conducted.

Statistical analysis. Statistical analysis was performed using a commercially available statistical software package (SPSS for Windows, version 21.0; IBM SPSS, Armonk, NY, USA). In a first step of the analysis, the means \pm standard deviations were calculated. In a second step, the Student's t-test for paired samples was used to evaluate the significance of measurements between the two eyes of the same individual, and measurements of the same eyes examined at baseline and after surgery. Applying the Student's t-test for unpaired samples, the diastCRAP in the study group was compared with the diastCRAP in the control group. Multivariate analysis was performed with the degree of CAS as the dependent variable and the independent variables were the parameters that were determined to be significantly associated with the degree of CAS in the univariate analysis. Results are presented with 95% confidence intervals (CIs). All P-values were based on two-sided tests and were considered statistically significant when the values were < 0.05 .

Results

Patient characteristics. The study group included 95 patients (51 of whom were men) with a mean age of 62.6 ± 11.3 years (median, 64 years; range, 34-81 years). The mean systolic blood pressure was 140 ± 22 mmHg (median, 140 mmHg), and the mean diastolic blood pressure was 81 ± 10 mmHg (median, 80 mmHg). The mean blood glucose concentration was 5.76 ± 1.73 mmol/l, the mean concentration of high-density lipoproteins was 1.22 ± 0.35 mmol/l, of low-density lipoproteins was 2.04 ± 0.73 mmol/l, and of triglycerides was 1.45 ± 0.66 mmol/l. Forty-eight (51%) study participants indicated they were smokers. The control group consisted of 64 subjects with a mean age of 62.4 ± 15.0 years (median, 62.3 years; range, 34.0 to 95.2 years). The study group and control group did not differ significantly in age ($P=0.92$).

CAS location and degree. The CAS was located in the internal carotid artery in 32 (34%) patients, at the bifurcation in 54 (57%) patients, in the common carotid artery in 6 (6%) patients, or was combined with a stenosis of the extracranial artery in 3 (3%) patients. The degree of the CAS ranged from 32 to 100% (mean, $70.1 \pm 19.6\%$). Out of the 95 patients, 50 patients (mean age, 63.9 ± 8.6 years) of a surgical study subgroup had a CAS $> 75\%$ (mean, $86.2 \pm 7.9\%$) on one side which then underwent surgery. Thirty-two patients underwent carotid endarterectomy and 18 individuals received a carotid artery stent implant. The patients of the surgical study group had

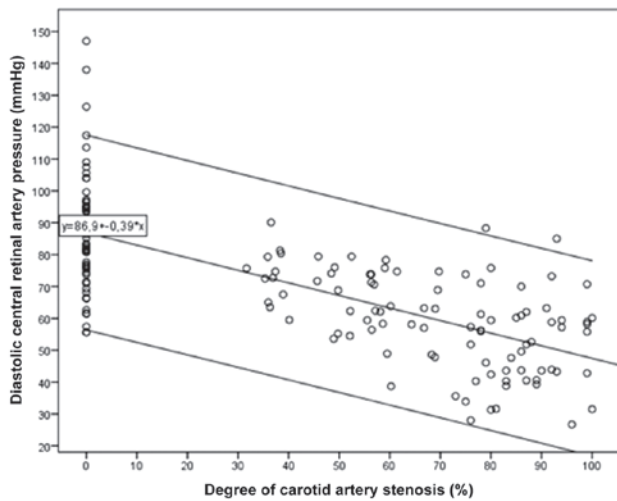


Figure 1. Association of the diastolic central retinal artery pressure value and degree of carotid artery stenosis. The data between the upper and lower lines were located within the 95% confidence interval of the central regression line.

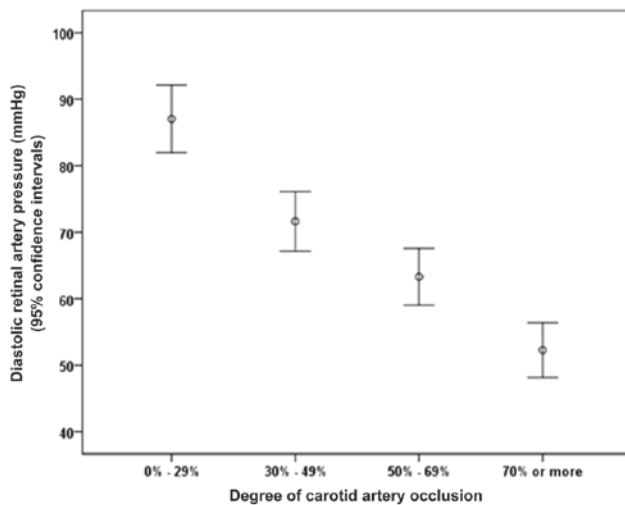


Figure 2. Association of diastolic central retinal artery pressure (diastCRAP) values with different degrees of carotid artery stenosis (CAS). The diastCRAP value decreased as the CAS degree increased.

experienced neurologic symptoms such as transient ischemic attacks that had eventually led to the indication for carotid artery surgery, as also described in previous studies (18,19). Following surgery, the residual stenosis on the surgical side was $22.3 \pm 3.8\%$ (range, 5-37%). On the contralateral side not undergoing surgery, the degree of CAS ranged from 0 to 99% (mean, $56.7 \pm 9.9\%$).

diastCRAP values and their association with CAS degree. In the control group without any CAS, the diastCRAP value was significantly associated with the brachial diastolic blood pressure [$P < 0.001$; standardized coefficient β , 0.54; regression coefficient B, 0.995 (95% CI: 0.57 to 1.42)]. Using the following regression equation from the control group: $\text{diastCRAP} = 0.995 \times \text{diastolic brachial blood pres-}$

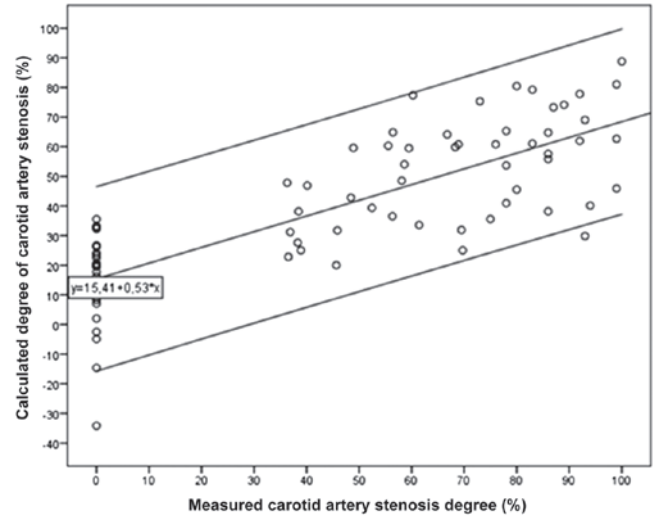


Figure 3. Comparison of the calculated degree of carotid artery stenosis with the measured degree of carotid artery stenosis. All except one point were located within the 95% confidence interval (upper and lower lines) of the central regression line.

sure + 8.85 mmHg), an expected diastCRAP for the whole study population was calculated. The difference between the measured diastCRAP and the calculated diastCRAP was then calculated. In the control group, diastCRAP was not found to be significantly associated with age, neither in univariate analysis ($P = 0.50$) nor in multivariate analysis after adjusting for diastolic blood pressure ($P = 0.14$).

Including all study participants in the statistical analysis revealed that the diastCRAP was significantly associated with the degree of CAS [$P < 0.001$; β , -0.69; B, -0.40 (95% CI: -0.46 to -0.33); Figs. 1 and 2]. If the difference between the measured diastCRAP and expected diastCRAP was taken, the correlation became stronger [$P < 0.001$; β , 0.74; B, 1.25 (95% CI: 1.07 to 1.44)]. Correspondingly, a multivariate analysis with the degree of CAS as dependent variable and measured diastCRAP and diastolic brachial blood pressure as independent variables showed that the degree of CAS was significantly (correlation coefficient overall: $r = 0.75$) associated with a higher brachial diastolic blood pressure [$P < 0.001$; β , 0.27; B, 1.09 (95% CI: 0.66 to 1.53)] and lower diastCRAP [$P < 0.001$; β , -0.73; B, -1.28 (95% CI: -1.47 to -1.09)].

diastCRAP values prior to and following CAS surgery. Within the surgical study group at the baseline of the study, the diastCRAP was significantly lower at the surgical side than at the contralateral side (48.1 ± 13.2 vs. 54.3 ± 14.0 mmHg; $P = 0.02$). At the surgical side, the diastCRAP value increased significantly ($P < 0.001$) after surgery from 48.1 ± 13.2 to 66.9 ± 9.9 mmHg, while at the contralateral side, the diastCRAP did not change significantly [54.3 ± 14.0 mmHg (median, 51.9 mmHg; range, 30.7-88.6 mmHg) vs. 54.3 ± 14.0 mmHg (median, 53.7 mmHg; range: 21.7-77.4 mmHg; $P = 0.86$)]. Subsequently, the diastCRAP value following surgery was significantly higher at the surgical side than at the contralateral side ($P < 0.001$).

In the surgical study group at baseline, the diastCRAP value at the surgical side was not found to be significantly associated

with brachial diastolic blood pressure ($P=0.22$). Similarly, diastCRAP at the contralateral side was not determined to be significantly associated with brachial diastolic blood pressure ($P=0.88$). Following surgery, diastCRAP at the surgical side was significantly associated with brachial diastolic blood pressure [$P=0.001$; β , 0.44; B, 0.55 (95% CI: 0.23, 0.87)].

diastCRAP values in the prediction of CAS degree. The whole study population was randomly divided into two subgroups. These were a 'formula subgroup', comprising 80 individuals whose data were used to calculate the association of the degree of CAS with diastCRAP and brachial diastolic blood pressure, and a 'test subgroup' of 79 individuals in which the formula was tested for its ability to predict the measured degree of CAS. In the formula subgroup, the formula for the degree of CAS was as follows: CAS degree (%) = $0.95 \times$ brachial diastolic blood pressure (mmHg) - $1.19 \times$ diastCRAP (mmHg) + 49.54. In the test subgroup, the calculated CAS value was compared with the measured CAS degree and it was observed that all but one of the points were located within the 95% CI of the regression line (Fig. 3).

Discussion

In this observational study on normal individuals and patients with moderate to severe CAS, diastCRAP as measured by ophthalmodynamometry was found to be highly significantly and linearly correlated with the degree of CAS. Correspondingly, diastCRAP was significantly lower at the side with the more severe CAS in patients with bilateral CAS, and diastCRAP increased significantly following successful surgery, resulting in a reduction in the degree of CAS. Subsequent to successful surgery for CAS, diastCRAP became correlated with diastolic brachial blood pressure, in contrast to the preoperative situation. In view of the strong and linear association between diastCRAP and the degree of CAS, the results suggest that the diastCRAP may be a surrogate for the status of the carotid artery and potentially for the cerebrovascular status in general. Thus, it may be inferred that ophthalmodynamometry could be a useful tool in the diagnosis and follow-up of CAS.

The result of the present study that ophthalmodynamometric measurements of the diastCRAP were correlated with the degree of CAS is concordant with findings obtained in studies performed several decades ago and which used ophthalmodynamometric devices others than the modern Goldmann lens associated ophthalmodynamometer (2-6,20-23). In contrast to the old devices, which provide inaccurate pressure measurements and have difficulties in a precise ophthalmoscopic examination of the optic nerve head, the Goldmann contact lens as applied in the present study provided good optical conditions for the ophthalmoscopic examination of the optic nerve head. The technique is an established technique of contact lens-associated ophthalmodynamometry, which has previously been applied in studies that have examined the central retinal venous pressure in diseases such as central and branch retinal vein occlusion, endocrine orbitopathy, glaucoma and increased brain pressure and that have examined the diastCRAP in diseases such as ischemic ophthalmopathy and dissection of the internal carotid artery (8,11,12,14,15,24-29). The central retinal vessels at the optic nerve head usually have

a diameter of 120-150 μm , so that pulse-synchronous vessel wall movements will occur in the range of $\sim 20 \mu\text{m}$. This value is close to the lateral image resolution of ophthalmoscopy; thus, the modern ophthalmodynamometer with best possible optical conditions for clinical ophthalmoscopy will lead to more precise measurements as compared with the measurements obtained using older ophthalmodynamometer models.

The findings of the present study on the group of patients with severe CAS concur with previous reports on small numbers of patients with a complete occlusion of the carotid artery or a carotid artery dissection (10,12). The results are also congruent with the findings of a reduced retinal blood velocity in patients with CAS and an improvement in blood flow velocity following carotid endarterectomy or carotid artery stenting (30-33).

In addition to the results obtained in the previous investigations, the present study findings showed a correlation between the degree of severe CAS and the reduction in diastCRAP in intra-individual inter-eye, inter-individual intra-individual follow-up comparisons. The results imply that the new Goldmann lens-associated ophthalmodynamometry may be a useful additional tool in the assessment of the patients with CAS. Furthermore, the results may prompt an ophthalmologist to suspect CAS if during a routinely performed Goldmann contact lens examination of the ocular fundus, a slight pressure on the contact lens induces a pulsation of the CRA.

The current study has potential imitations. First, as a hospital-based investigation, the study by principle carries the risk of bias due to the referral bias of patients admitted to the hospital. Secondly, the patients of the study population only showed severe CAS, and patients with minor degrees of CAS were not examined. Therefore, it was not possible to explore the association between diastCRAP and minor degrees of CAS; thus, it was not possible to determine whether the correlation between diastCRAP and CAS was linear or curvilinear. One may assume that for minor degrees of CAS without functional consequences for the cerebrovascular system, the degree of CAS would not be correlated with diastCRAP. If that is the case, future studies may investigate the suitability of ophthalmodynamometry for use in assessment of the functional impediment of cerebrovascular blood perfusion in patients with CAS of varying degrees.

In conclusion, diastCRAP was highly significantly and linearly correlated with the degree of CAS in intra-individual inter-eye, inter-individual and intra-individual follow-up comparisons. The strong and linear association between diastCRAP and the degree of CAS suggests that diastCRAP should be further explored as a surrogate for cerebrovascular status.

References

1. Hedges TR, Weinstein JD, Kassell NF and Langfitt TW: Correlation of ophthalmodynamometry with ophthalmic artery pressure in the rhesus monkey. *Am J Ophthalmol* 60: 1098-1101, 1965.
2. Wunsh SE: Ophthalmodynamometry. *N Engl J Med* 281: 446, 1969.
3. Galin MA, Baras I and Dodick JM: Semiautomated suction ophthalmodynamometry. *Am J Ophthalmol* 68: 237-240, 1969.
4. Bettelheim H: The clinical significance of ophthalmodynamometry and ophthalmodynamography. *Klin Monatsbl Augenheilkd* 155: 769-791, 1969 (In German).

5. Van der Werff TJ: The pressure measured in ophthalmodynamometry. *Arch Ophthalmol* 87: 290-292, 1972.
6. Krieglstein GK and Silva FA: Comparative measurements of the ophthalmic arterial pressure using the Mikuni dynamometer and the Stepanik-arteriotonograph. *Albrecht Von Graefes Arch Klin Exp Ophthalmol* 212: 77-91, 1979 (In German).
7. Entenmann B, Robert YC, Pirani P, Kanngiesser H and Dekker PW: Contact lens tonometry - application in humans. *Invest Ophthalmol Vis Sci* 38: 2447-2451, 1997.
8. Morgan WH, Yu DY, Cooper RL, Alder VA, Cringle SJ and Constable IJ: Retinal artery and vein pressures in the dog and their relationship to aortic, intraocular and cerebrospinal fluid pressures. *Microvasc Res* 53: 211-221, 1997.
9. Firsching R, Schütze M, Motschmann M, Behrens-Baumann W and Meyer-Schwickerath R: Non-invasive measurement of intracranial pressure. *Lancet* 351: 523-524, 1998.
10. Jonas JB: Retinal arterial collapse pressure in eyes with retinal arterial occlusive diseases. *Br J Ophthalmol* 88: 589, 2004.
11. Jonas JB and Niessen A: Ophthalmodynamometric diagnosis of unilateral ischemic ophthalmopathy. *Am J Ophthalmol* 134: 911-912, 2002.
12. Jonas JB and Hennerici M: Ophthalmodynamometry for diagnosis of dissection of internal carotid artery. *Graefes Arch Clin Exp Ophthalmol* 244: 129-130, 2006.
13. Murray CJ, Barber RM, Foreman KJ, Abbasoglu Ozgoren A, Abd-Allah F, Abera SF, Abyans V, Abraham JP, Abubakar I, Abu-Raddad LJ, *et al*; GBD 2013 DALYs and HALE Collaborators: Global, regional, and national disability-adjusted life years (DALYs) for 306 diseases and injuries and healthy life expectancy (HALE) for 188 countries, 1990-2013: Quantifying the epidemiological transition. *Lancet* 386: 2145-2191, 2015.
14. Morgan WH, Cringle SJ, Kang MH, Pandav S, Balaratnasingam C, Ezekial D and Yu DY: Optimizing the calibration and interpretation of dynamic ocular force measurements. *Graefes Arch Clin Exp Ophthalmol* 248: 401-407, 2010.
15. Jonas JB: Reproducibility of ophthalmodynamometric measurements of the central retinal artery and vein collapse pressure. *Br J Ophthalmol* 87: 577-579, 2003.
16. Zaret CR, Sacks JG and Holm PW: Suction ophthalmodynamometry in the diagnosis of carotid stenosis. *Ophthalmology* 86: 1510-1512, 1979.
17. Hayreh SS and Jonas JB: Optic disk and retinal nerve fiber layer damage following transient central retinal artery occlusion: An experimental study in rhesus monkeys. *Am J Ophthalmol* 129: 786-795, 2000.
18. North American Symptomatic Carotid Endarterectomy Trial Collaborators: Beneficial effect of carotid endarterectomy in symptomatic patients with high-grade carotid stenosis. *N Engl J Med* 325: 445-453, 1991.
19. European Carotid Surgery Trialists' Collaborative Group: MRC European Carotid Surgery Trial: Interim results for symptomatic patients with severe (70-99%) or with mild (0-29%) carotid stenosis. *Lancet* 337: 1235-1243, 1991.
20. Sanborn GE, Miller NR, McGuire M and Kumar AJ: Clinical-angiographic correlation of ophthalmodynamometry in patients with suspected carotid artery disease: A prospective study. *Stroke* 12: 770-774, 1981.
21. Mullie MA and Kirkham TH: Ophthalmodynamometry revisited. *Can J Ophthalmol* 18: 165-168, 1983.
22. Weinberger J: Clinical applications of noninvasive carotid artery testing. *J Am Coll Cardiol* 5: 137-148, 1985.
23. Barańska-Gieruszczak M, Laskowska-Studniarska W, Myga W and Ryglewicz D: Diagnostic value of ultrasonography and ophthalmodynamometry in the diagnosis of stenosis and occlusion of the internal carotid artery. *Neurol Neurochir Pol* 21: 281-285, 1987 (In Polish).
24. Morgan WH, Hazelton ML, Balaratnasingam C, Chan H, House PH, Barry CJ, Cringle SJ and Yu DY: The association between retinal vein ophthalmodynamometric force change and optic disc excavation. *Br J Ophthalmol* 93: 594-596, 2009.
25. Morgan WH, Yu DY, Alder VA, Cringle SJ and Constable IJ: Relation between pressure determined by ophthalmodynamometry and aortic pressure in the dog. *Br J Ophthalmol* 82: 821-825, 1998.
26. Jonas JB and Harder B: Ophthalmodynamometric estimation of cerebrospinal fluid pressure in pseudotumor cerebri. *Br J Ophthalmol* 87: 361-362, 2003.
27. Jonas JB: Central retinal artery and vein pressure in patients with chronic open-angle glaucoma. *Br J Ophthalmol* 87: 949-951, 2003.
28. Jonas JB: Ophthalmodynamometric measurement of orbital tissue pressure in thyroid-associated orbitopathy. *Acta Ophthalmol Scand* 82: 239, 2003.
29. Jonas JB and Harder B: Ophthalmodynamometric differences between ischemic versus non-ischemic retinal vein occlusion. *Am J Ophthalmol* 143: 112-116, 2007.
30. Ishikawa K, Kimura I, Shinoda K, Eshita T, Kitamura S, Inoue M and Mashima Y: In situ confirmation of retinal blood flow improvement after carotid endarterectomy in a patient with ocular ischemic syndrome. *Am J Ophthalmol* 134: 295-297, 2002.
31. Cohn EJ Jr, Sandager GP, Benjamin ME, Lilly MP, Hanna DJ and Flinn WR: Assessment of ocular perfusion after carotid endarterectomy with color-flow duplex scanning. *J Vasc Surg* 29: 665-671, 1999.
32. Costa VP, Kuzniec S, Molnar LJ, Cerri GG, Puech-Leão P and Carvalho CA: The effects of carotid endarterectomy on the retrobulbar circulation of patients with severe occlusive carotid artery disease. An investigation by color Doppler imaging. *Ophthalmology* 106: 306-310, 1999.
33. Wong YM, Clark JB, Faris IB, Styles CB and Kiss JA: The effects of carotid endarterectomy on ocular haemodynamics. *Eye (Lond)* 12: 367-373, 1998.