



HHS Public Access

Author manuscript

World J Respirol. Author manuscript; available in PMC 2016 March 04.

Published in final edited form as:

World J Respirol. 2015 July 28; 5(2): 69–77. doi:10.5320/wjr.v5.i2.69.

Post splenectomy related pulmonary hypertension

Atul V Palkar,

Department of Pulmonary, Critical Care and Sleep Medicine, North Shore - LIJ Health System, New York, NY 11040, United States

Abhinav Agrawal,

Department of Medicine, Monmouth Medical Center, Long Branch, NJ 07740, United States

Sameer Verma,

Department of Pulmonary, Critical Care and Sleep Medicine, North Shore - LIJ Health System, New York, NY 11040, United States

Feinstein Institute of Medical Research, Center for Heart and Lung Research, New York, NY 11030, United States

Asma Iftikhar,

Department of Pulmonary, Critical Care and Sleep Medicine, North Shore - LIJ Health System, New York, NY 11040, United States

Feinstein Institute of Medical Research, Center for Heart and Lung Research, New York, NY 11030, United States

Edmund J Miller, and

Department of Pulmonary, Critical Care and Sleep Medicine, North Shore - LIJ Health System, New York, NY 11040, United States

Feinstein Institute of Medical Research, Center for Heart and Lung Research, New York, NY 11030, United States

Arunabh Talwar

Department of Pulmonary, Critical Care and Sleep Medicine, North Shore - LIJ Health System, New York, NY 11040, United States

Feinstein Institute of Medical Research, Center for Heart and Lung Research, New York, NY 11030, United States

Abstract

Open-Access: This article is an open-access article which was selected by an in-house editor and fully peer-reviewed by external reviewers. It is distributed in accordance with the Creative Commons Attribution Non Commercial (CC BY-NC 4.0) license, which permits others to distribute, remix, adapt, build upon this work non-commercially, and license their derivative works on different terms, provided the original work is properly cited and the use is non-commercial. See: <http://creativecommons.org/licenses/by-nc/4.0/>

Correspondence to: Arunabh Talwar, MD, FCCP, Department of Pulmonary, Critical Care and Sleep Medicine, North Shore - LIJ Health System, 410 Lakeville Rd. Suite 107 New Hyde Park, New York, NY 11040, United States. arunabhtalwar1@gmail.com, Telephone: +1-516-4655400, Fax: +1-516-4655454.

Author contributions: All the authors equally contributed to this work.

Conflict-of-interest statement: The authors declare no conflicts of interest.

Splenectomy predisposes patients to a slew of infectious and non-infectious complications including pulmonary vascular disease. Patients are at increased risk for venous thromboembolic events due to various mechanisms that may lead to chronic thromboembolic pulmonary hypertension (CTEPH). The development of CTEPH and pulmonary vasculopathy after splenectomy involves complex pathophysiologic mechanisms, some of which remain unclear. This review attempts to congregate the current evidence behind our understanding about the etio-pathogenesis of pulmonary vascular disease related to splenectomy and highlight the controversies that surround its management.

Keywords

Pulmonary hypertension; Thalassemia; Splenectomy; Thrombocytosis; Chronic thromboembolic pulmonary hypertension

INTRODUCTION

The spleen plays a key role in immune homeostasis through its ability to link innate and adaptive immunity. Splenectomy predisposes the individual to a life-long increased risk of severe infections^[1]. Besides a risk of localized or generalized infection there is also a well known risk of thromboembolic events due to thrombocytosis post-splenectomy^[2]. More specifically, in post-splenectomy patients there is a risk of pulmonary complications such as pneumonia, pleural effusion. Recently, there has been a growing interest about non-infectious complications such as thromboembolic events and pulmonary vasculopathies (Table 1). Pulmonary thromboembolic disease in the form of pulmonary embolism leading to chronic thromboembolic pulmonary hypertensive disease is one of the observed pulmonary complications of splenectomy. The pathophysiology of these conditions is complex and not yet clearly understood. Herein we attempt to describe the possible mechanisms of postsplenectomy pulmonary hypertension with a review of the literature.

INDICATIONS FOR SPLENECTOMY

There are many indications for splenectomy but the most common cause remains traumatic injury leading to rupture of the spleen. In addition there are many benign and neoplastic conditions that may lead to removal of the spleen. Hematologic causes may include autoimmune thrombocytopenia, idiopathic thrombocytopenic purpura (ITP), hereditary spherocytosis, pyruvate kinase deficiency, glucose-6 phosphate dehydrogenase deficiency or hypersplenism^[3]. In addition there are neoplastic conditions that warrant splenectomy such as Hodgkin's disease, non-Hodgkin's lymphoma, chronic myelogenous leukemia, chronic lymphocytic leukemia, hairy cell leukemia and primary or metastatic tumors^[3]. Other benign indications may be Gaucher's disease^[4] and Chediak-Higashi Syndrome^[5]. Complications postsplenectomy include acute complications of general surgery that include impaired wound healing, bleeding, post surgical infection due to high dose corticosteroids or possible gastric or pancreatic fistulas. However, splenectomy may be associated with an elevated risk for cardiovascular events such as myocardial infarction and stroke^[6]. In addition to the aforementioned complications splenectomy predisposes patients for increased thromboembolic events^[7] and pulmonary hypertension^[8].

PULMONARY HYPERTENSION AND SPLENECTOMY

Pulmonary hypertension (PHTN) is characterized by a mean pulmonary arterial pressure (mPAP) ≥ 25 mmHg at rest^[9]. The World Health Organization (WHO) has proposed a classification system for pulmonary hypertension based on common clinical features (Table 2)^[10]. Patients with splenectomy can develop PHTN with histopathological changes similar to those with WHO Group 1 Pulmonary Arterial Hypertension (PAH)^[8,11] and WHO Group 4 - Chronic Thromboembolic Pulmonary Hypertension (CTEPH)^[11-13]. In addition splenectomized patients developing PHTN in the setting of hemolytic disorders, trauma, sickle cell disease, Gaucher's disease are included in WHO Group 5 definition of pulmonary hypertension.

Initially the link between splenectomy and PHTN was suggested in patients with thalassemia and hereditary stomatocytosis^[12,14,15]. It has been estimated that the time interval between splenectomy and the development of PHTN is long (range 2-35 years)^[8,11]. Autopsy findings from 58 patients with thalassemia showed pulmonary vascular changes indicative of microthromboemboli in 54% splenectomized patients compared to 16% of those who had not had splenectomy^[14]. In a study by Hoepfer *et al*^[8] the prevalence of asplenia (including traumatic asplenia) was significantly higher (11.5%) among 61 patients with unexplained PHTN. In a study by Jaïs *et al*^[11] a cohort of 257 patients referred for the treatment of CTEPH, 22 patients (8.6%) had a history of splenectomy. In the control group of idiopathic PHTN in the same study, 2.5% of patients had splenectomy compared to 0.56% in patients with chronic lung conditions^[11]. In another study of 134 adults with Gaucher's disease, PHTN was diagnosed on echocardiogram in 9 patients (7%) on enzyme replacement therapy; 6 patients had prior splenectomy^[16].

An increased incidence of PHTN has also been described in patients who have undergone splenectomy for trauma^[8,11], hemolytic disorders such as thalassemia, pyruvate kinase deficiency, hereditary spherocytosis, and stomatocytosis^[14,17-20] and Gaucher's disease^[16,21].

Based on the literature it is difficult to differentiate if the hypercoagulability is caused by splenectomy from or is due to the underlying hemolytic disorder. Even the risk of PHTN after splenectomy may differ between hemolytic disorders. This suggests that in addition to the loss of splenic filter, the development of PHTN in post-splenectomy patients is likely a slow multifactorial process. In a study by Jaïs *et al*^[11] only 4 of 22 patients had a hemolytic disorder, in most of the others, the spleen had been removed for trauma. In another study, of seven patients with unexplained PHTN after splenectomy, 3 patients had splenectomy due to trauma^[8]. Thus, it is clear that splenectomy by itself is a risk factor for PHTN even in the absence of hematologic disorders. All studies on regarding PHTN have been summarized in Table 3.

MECHANISMS FOR PULMONARY HYPERTENSION POST SPLENECTOMY

Venous thromboembolism and CTEPH

Splenectomy is associated with venous thrombosis in general and in particular, with deep venous thrombosis and non-resolving and recurrent venous thromboembolism^[22,23]. Deep venous thrombosis may be complicated by pulmonary embolism. Compared to the general population and appendectomy patients respectively, Thomsen *et al*^[23] found a 19.8-fold (95%CI: 8.8–44.7) and 2.3-fold (95%CI: 1.3–4.1) increased risk of DVT and a 32.6-fold (95%CI: 13.9–76.3) and 3.2-fold (95%CI: 1.8–5.5) higher risk of PE in splenectomized patients within the first 90 d after splenectomy.

One late consequence of non-resolution of venous and pulmonary thromboemboli is CTEPH^[24]. This condition is defined by the absence of thrombus resolution after one or more episodes of acute pulmonary embolism causing sustained vascular obstruction and subsequent pulmonary hypertension. In a study by Pengo *et al*^[25] a cumulative incidence of 3% was found for symptomatic chronic thromboembolic pulmonary hypertension in patients with acute pulmonary embolism at 2 year follow up. Autopsies in patients with thalassemia have confirmed microthromboembolism in the pulmonary vasculature^[14]. Histologic examination of explanted lungs in patients with unexplained PHTN undergoing lung transplant showed abundant thrombotic lesions in conjunction with medial hypertrophy, plexiform lesions and marked intimal thickening^[8]. In a study by Frey *et al*^[26], mass spectral analysis of human pulmonary endarterectomy specimens in CTEPH after splenectomy showed increased anionic phospholipids. These anionic phospholipids inhibit angiogenesis *in vitro* thereby delaying thrombus resolution^[26]. In the same study, thrombi volumes and cross sectional areas were compared in splenectomized and sham-operated mice after inferior vena caval ligation to create stagnant flow venous thrombosis and model human deep vein thrombosis. Splenectomized mice showed larger initial thrombi and delayed thrombus resolution^[26]. In the study by Jaïs *et al*^[11] of the 22 patients with CTEPH who had had splenectomy, only eight were suitable for thrombo-endarterectomy. Also, in the same study, only 7 (2.5%) of 276 patients with idiopathic PHTN had splenectomy compared to prevalence of 11.5% of aplenia in patients with unexplained PHTN reported in an earlier study^[8]. However, in the study by Hoepfer *et al*^[8], splenectomized subjects had prominent thrombotic pulmonary arteriopathy. This raises the possibility of a continuum between CTEPH, thrombotic form of idiopathic PHTN and PAH without thrombosis^[27]. Further, it suggests that PHTN after splenectomy occurs mainly through thromboembolic involvement of pulmonary microvasculature. This may occur by two mechanisms; (1) Increased thrombus formation; and (2) Delayed thrombus resolution as discussed below.

Increased thrombus formation

Patients undergoing splenectomy may have significant enrichment of anion phospholipids and this has been proposed to be the key to thrombogenicity^[26]. In animal studies, platelet-derived micro particles (MP) were significantly increased in the blood of the splenectomized mice^[26]. These microparticles can act as pro-coagulants by providing a negative charged surface for the assembly of coagulation proteases thus contributing to thrombus formation^[28]. A similar rise in platelet derived MPs was observed in humans after

undergoing splenectomy^[29]. Anionic phospholipids of the erythrocyte membrane phosphatidylserine (PS) are localized in the inner membrane leaflet of the cell membrane of red blood cells in normal individuals^[30]. The translocation of such phospholipids (*e.g.*, PS) to the outer leaflets of the erythrocyte membrane supports coagulation by acting as cofactors for proteolytic reactions^[31]. Kuypers *et al*^[32] showed that number of erythrocytes with modified PS expression was 20 times higher after splenectomy. The loss of splenic filtering function allows abnormal red cells to remain in circulation after splenectomy. Thus increased MPs and anionic phospholipids can enhance thrombogenicity, and result in CTEPH.

Delayed thrombus resolution

In the mouse models of Frey *et al*^[26] the anionic phospholipids PS and phosphatidylglycerol (PG) as well as the neutral phospholipid phosphatidylethanolamine (PE) were increased in the later phase of vascular remodeling along with delayed incidence of thrombus resolution. This supports the possibility that cellular effects of these phospholipids may be driving the delay in thrombus resolution. Angiogenesis is a key event in vascular remodeling. It has been demonstrated that non-resolution of the thrombus has been associated with low expression of angiogenesis associated genes. PS may inhibit angiogenesis via brain specific angiogenesis inhibitor 1. This adhesion type G protein coupled receptor binds PS on apoptotic cells. This has shown to inhibit *in vivo* neovascularization^[33,34] that in turn leads to delayed thrombus resolution. While Frey *et al*^[26] also demonstrated compromised lymphangiogenesis in splenectomized patients, whether it plays a role in thrombus non-resolution is a subject of further research.

In patients with thalassemia, the high oxidative state of the red blood cells due to iron accumulation in the membrane induces a similar high oxidative state in the platelets, leading to their activation^[35]. Furthermore, rheological abnormality of the red blood cells also tends to favor their aggregation^[36]. Garozzo *et al*^[37] have reported increased adhesion molecules on nucleated red blood cells in patients with thalassemia intermedia and major, which may contribute to the hypercoagulable state. Splenectomized patients with thalassemia have more abnormal red blood cells and precursors thus possibly leading to thrombosis that in turn may lead to elevated pulmonary pressures^[38].

Thrombocytosis

Reactive thrombocytosis immediately following splenectomy is due to decreased cell degradation and increases the risk of subsequent venous thromboembolism^[39,40]. However, this association is likely due to additional risk factors of severely ill trauma patients included in these studies^[41]. No increase in the incidence of thromboembolism was evident directly after splenectomy in another study^[2]. Thrombocytosis normally diminishes following splenectomy, however pulmonary hypertension may develop if thrombocytosis persists^[27]. Long standing thrombocytosis after splenectomy has been shown in one case to be associated with elevated fibronopeptide A, thromboxane B2 and β -thromboglobulin levels resulting in endothelial damage, local platelet activation and thrombin generation leading to CTEPH. Treatment of the thrombocytosis led to improvement in the clinical condition as well as pulmonary symptoms^[42]. In another case treatment with hydroxyurea improved both

vascular and cardiac function in a patient who developed pulmonary hypertension and right heart failure due to thrombocytosis following splenectomy^[43]. Singer *et al*^[44] also showed higher levels of sPECAM-1, which has a role in platelet activation, and adhesion signaling in splenectomized thalassemia intermedia patients. Thus besides thrombocytosis, increased platelet adhesion may contribute to the development of pulmonary vasculopathy.

Megakaryocytes

There is strong indirect evidence indicating transmigration of intact megakaryocytes from the bone marrow into the circulation and the release of platelets from these megakaryocytes in the pulmonary capillary bed^[45,46]. These large sized platelet precursors can contribute to distal in situ thrombosis leading to CTEPH after splenectomy. This explains the observation that many patients with CTEPH are not suitable for thromboendarterectomy^[11,47]. In patients with hemolytic anemia and myeloproliferative disorders especially in the setting of splenectomy extramedullary hematopoiesis (EMH) occurs, where the megakaryocyte can play a key role^[45]. EMH commonly involves the liver and the spleen. However after splenectomy, the lungs can become an alternate site of EMH. Pulmonary EMH has been observed in Gaucher's disease with the presence of Gaucher's cells and megakaryocytes in the lungs^[48]. Thus the presence of increased megakaryocytes as a result of EMH in pulmonary bed can contribute to PHTN. 'Pathologic emperipolesis' is seen in myelofibrosis in which the megakaryocytes cause marrow fibrosis through the release of fibrogenic mediators like vascular endothelial growth factor, platelet derived growth factor (PDGF) and transforming growth factor- β ^[49]. It has been proposed that megakaryocytes at sites of pulmonary EMH may be responsible for a similar phenomenon which leads to fibrosis of the pulmonary vasculature and PHTN^[45]. In sickle cell disease, autosplenectomy can lead to EMH in the lungs and PHTN. While possible mechanisms have been mentioned above, more studies are needed to ascertain the exact role of megakaryocytes in the pathogenesis of PHT after splenectomy.

Nitric oxide

In patients with chronic hemolytic disorder, free hemoglobin released from lysed red cells can scavenge nitric oxide, an important pulmonary vasodilator^[27]. Elevated cell-free hemoglobin is modestly correlated with mean pulmonary artery pressures and pulmonary vascular resistance in pulmonary arterial hypertension^[50]. Splenectomy leads to impaired clearance of senescent red cells especially in patients with hemoglobinopathies. Thus, higher plasma hemoglobin levels and increased scavenging of nitric oxide in splenectomized patients may contribute to pulmonary vasculopathy and the development of PHTN^[51,52]. Nitric oxide also has an inhibitory function on megakaryocytes leading to their apoptosis^[53]. Depletion of nitric oxide can lead to increased megakaryocytes in the pulmonary circulation and development of PHTN as mentioned above.

Endothelin-1

In the study by Singer *et al*^[44], endothelin-1 (ET-1), a potent vasoconstrictor produced by vascular endothelial and smooth muscle cells was higher in non-transfused splenectomized thalassemia patients compared to the transfused group. ET-1 is known to cause pulmonary

vasoconstriction and thus could play an important role in developing pulmonary vasculopathy after splenectomy. The role of ET-1 is even more crucial, since theoretically ET antagonists can also play a part in the treatment of PHTN in such patients.

DIAGNOSIS AND MANAGEMENT

Transthoracic doppler echocardiography in patients with hemoglobinopathies like thalassemia is cost effective and an established screening tool for PHTN. It is also suggested to screen patients with Gaucher's disease and at high risk for developing pulmonary hypertension^[16]. Echocardiography may overestimate pulmonary artery pressure. Therefore elevated pulmonary artery systolic pressure on echocardiography should be confirmed by right heart catheterization. Although not all studies on splenectomized patients have used right heart catheterization for the diagnosis of PHTN (Table 3). Splenectomized patients may develop PHTN and hence should be screened for the development of exercise intolerance. However, currently there is no data to support routine screening in patients after splenectomy for non-hematologic disorders for the development of PHTN.

In patients with thalassemia, regular blood transfusions and iron chelation may reduce the need for splenectomy and prevent the development of PHTN^[38,44]. Proper transfusion therapy likely restores tissue oxygen delivery and suppresses the synthesis of native defective erythrocytes, hence preventing rapid red cell turnover and hypercoagulability. Reduction of platelet counts with hydroxyurea or by the use of an anti-platelet agent has been suggested for the prevention of thrombotic complications in splenectomized non-transfused thalassemia intermedia patients^[54].

There is a paucity of large randomized, controlled clinical trials demonstrating benefit of currently available PHTN specific therapies in patients with hemolytic disorders as well as in the subset of these patients undergoing splenectomy. According to the WHO classification, patients with PAH are included in group 1, CTEPH in group 3, and those with PHTN due to hemolytic disorders or Gaucher's disease are included in group 5. Also, patients with PHTN in the setting of splenectomy without other predisposing co-morbidities are included in group 5. WHO treatment guidelines for PHTN for groups 1 and 4 are well defined. However, no recommendations yet exist for the use of PHTN specific therapy in patients with group 5 PHTN. Many patients with PHTN post-splenectomy are treated with vasodilators similar to patients with group 1 PHTN in the absence of overt thromboembolic disease. Therefore, the treatment algorithm for PHTN in post-splenectomy patients remains unclear given the complex interplay of mechanisms discussed previously.

PHTN associated with Gaucher's disease has been treated with enzyme replacement therapy and anecdotally with adjuvant vasodilator therapies such as prostacyclin, bosentan and/or sildenafil with improvement in clinical and hemodynamic parameters^[55]. No data specifically addresses PHTN therapy of splenectomized patients with Gaucher's disease.

Sildenafil, a phosphodiesterase-5 inhibitor was studied in sickle cell disease associated PHTN in the walk-PHaSST trial^[56]. This was the first multicenter randomized trial of sildenafil in sickle cell disease sponsored by the National Institute of Health. The study was

prematurely terminated due to increased incidence of painful crises in the treatment group^[56].

The efficacy and safety of sildenafil in patients with thalassemia is limited to small studies defining PHTN using Doppler echocardiography^[57,58]. Sildenafil has been shown to be safe, improved pulmonary hemodynamics in patients in both studies while in the study by Derchi *et al*^[57], Sildenafil improved exercise capacity.

Both non-selective dual action endothelin receptor antagonists including Bosentan and Macitentan and selective receptor antagonists of endothelin receptor A such as Ambrisentan are approved for treatment of group 1 PHTN. However, a trial with Bosentan in sickle cell disease with pulmonary arterial hypertension was also suspended early because of poor enrollment, and some of the beneficial effects observed were not statistically significant^[59]. Anticoagulation is currently indicated for the treatment of patients with group 1 and 4 PHTN (CTEPH)^[60]. However, there is no evidence to support routine use of anticoagulants for the treatment of post splenectomy group 5 PHTN.

Riociguat a soluble guanylate cyclase stimulator approved for CTEPH, and may be considered in patients developing pulmonary hypertension after splenectomy in the setting of pulmonary thromboembolic phenomenon. However, with mechanism of action being related to phosphodiesterase inhibition and lack of safety data in splenectomized patients, routine use in this subgroup of patients is currently not recommended.

CONCLUSION

Patients undergoing splenectomy are known to develop pulmonary complications including pneumonia and pleural effusion. However, the development of pulmonary hypertension after splenectomy also needs to be considered. The risk of development of PHTN after splenectomy is currently unknown for any given patient. Nevertheless, this complication does occur after splenectomy likely through a multitude of factors (Figure 1). Further research is required to identify markers or screening tools to predict the development of PHTN in this patient population. Whether therapies approved for specific groups of PHTN would be effective for treatment of patients with PHTN after splenectomy remains to be determined. It is clear that more studies are necessary to guide rational treatment strategies targeting specific mechanisms that lead to PHTN after splenectomy.

It is important for physicians to be vigilant about PHTN as it may develop years or decades after splenectomy. Since PHTN usually manifests with non-specific symptoms, patients should be screened for symptoms such as fatigue, exercise intolerance and dyspnea. Screening for PHTN cannot be underemphasized for post-splenectomy patients with hematologic disorders given increased risk for the development of PHTN in this subgroup. Early recognition is essential to institute interventions that may improve outcome.

Acknowledgments

Supported by NIH 1R01HL111469 and ECRIP Fellowship.

REFERENCES

1. Edgren G, Almqvist R, Hartman M, Utter GH. Splenectomy and the risk of sepsis: a population-based cohort study. *Ann Surg.* 2014; 260:1081–1087. [PMID: 24374533]. [PubMed: 24374533]
2. Boxer MA, Braun J, Ellman L. Thromboembolic risk of postsplenectomy thrombocytosis. *Arch Surg.* 1978; 113:808–809. [PMID: 678089]. [PubMed: 678089]
3. Katz SC, Pachter HL. Indications for splenectomy. *Am Surg.* 2006; 72:565–580. [PMID: 16875077]. [PubMed: 16875077]
4. Rubin M, Yampolski I, Lambrozo R, Zaizov R, Dintsman M. Partial splenectomy in Gaucher's disease. *J Pediatr Surg.* 1986; 21:125–128. [PMID: 3950849]. [PubMed: 3950849]
5. Aslan Y, Erduran E, Gedik Y, Mocan H, Yildiran A. The role of high dose methylprednisolone and splenectomy in the accelerated phase of Chédiak-Higashi syndrome. *Acta Haematol.* 1996; 96:105–107. [PMID: 8701696]. [PubMed: 8701696]
6. Schilling RF. Spherocytosis, splenectomy, strokes, and heat attacks. *Lancet.* 1997; 350:1677–1678. [PMID: 9400518]. [PubMed: 9400518]
7. Mohren M, Markmann I, Dworschak U, Franke A, Maas C, Mewes S, Weiss G, Jentsch-Ullrich K. Thromboembolic complications after splenectomy for hematologic diseases. *Am J Hematol.* 2004; 76:143–147. [PMID: 15164380]. [PubMed: 15164380]
8. Hoepfer MM, Niedermeyer J, Hoffmeyer F, Flemming P, Fabel H. Pulmonary hypertension after splenectomy? *Ann Intern Med.* 1999; 130:506–509. [PMID: 10075618]. [PubMed: 10075618]
9. Hoepfer MM, Bogaard HJ, Condliffe R, Frantz R, Khanna D, Kurzyna M, Langleben D, Manes A, Satoh T, Torres F, Wilkins MR, Badesch DB. Definitions and diagnosis of pulmonary hypertension. *J Am Coll Cardiol.* 2013; 62:D42–D50. [PMID: 24355641]. [PubMed: 24355641]
10. Simonneau G, Gatzoulis MA, Adatia I, Celermajer D, Denton C, Ghofrani A, Gomez Sanchez MA, Krishna Kumar R, Landzberg M, Machado RF, Olschewski H, Robbins IM, Souza R. Updated clinical classification of pulmonary hypertension. *J Am Coll Cardiol.* 2013; 62:D34–D41. [PMID: 24355639]. [PubMed: 24355639]
11. Jaïs X, Ioos V, Jardim C, Sitbon O, Parent F, Hamid A, Fadel E, Darteville P, Simonneau G, Humbert M. Splenectomy and chronic thromboembolic pulmonary hypertension. *Thorax.* 2005; 60:1031–1034. [PMID: 16085731]. [PubMed: 16085731]
12. Aessopos A, Stamatelos G, Skoumas V, Vassilopoulos G, Mantzourani M, Loukopoulos D. Pulmonary hypertension and right heart failure in patients with beta-thalassemia intermedia. *Chest.* 1995; 107:50–53. [PMID: 7813310]. [PubMed: 7813310]
13. Bonderman D, Jakowitsch J, Adlbrecht C, Schemper M, Kyrle PA, Schönauer V, Exner M, Klepetko W, Kneussl MP, Maurer G, Lang I. Medical conditions increasing the risk of chronic thromboembolic pulmonary hypertension. *Thromb Haemost.* 2005; 93:512–516. [PMID: 15735803]. [PubMed: 15735803]
14. Sumiyoshi A, Thakerngpol K, Sonakul D. Pulmonary microthromboemboli in thalassemic cases. *Southeast Asian J Trop Med Public Health.* 1992; 23(Suppl 2):29–31. [PMID: 1298989]. [PubMed: 1298989]
15. Stewart GW, Amess JA, Eber SW, Kingswood C, Lane PA, Smith BD, Mentzer WC. Thromboembolic disease after splenectomy for hereditary stomatocytosis. *Br J Haematol.* 1996; 93:303–310. [PMID: 8639421]. [PubMed: 8639421]
16. Elstein D, Klutstein MW, Lahad A, Abrahamov A, Hadas-Halpern I, Zimran A. Echocardiographic assessment of pulmonary hypertension in Gaucher's disease. *Lancet.* 1998; 351:1544–1546. [PMID: 10326537]. [PubMed: 10326537]
17. Cappellini MD, Robbiolo L, Bottasso BM, Coppola R, Fiorelli G, Mannucci AP. Venous thromboembolism and hypercoagulability in splenectomized patients with thalassaemia intermedia. *Br J Haematol.* 2000; 111:467–473. [PMID: 11122086]. [PubMed: 11122086]
18. Chou R, DeLoughery TG. Recurrent thromboembolic disease following splenectomy for pyruvate kinase deficiency. *Am J Hematol.* 2001; 67:197–199. [PMID: 11391719]. [PubMed: 11391719]
19. Jardine DL, Laing AD. Delayed pulmonary hypertension following splenectomy for congenital spherocytosis. *Intern Med J.* 2004; 34:214–216. [PMID: 15086707]. [PubMed: 15086707]

20. Murali B, Drain A, Sellar D, Dunning J, Vuylsteke A. Pulmonary thromboendarterectomy in a case of hereditary stomatocytosis. *Br J Anaesth.* 2003; 91:739–741. [PMID: 14570800]. [PubMed: 14570800]
21. Mistry PK, Sirrs S, Chan A, Pritzker MR, Duffy TP, Grace ME, Meeker DP, Goldman ME. Pulmonary hypertension in type 1 Gaucher's disease: genetic and epigenetic determinants of phenotype and response to therapy. *Mol Genet Metab.* 2002; 77:91–98. [PMID: 12359135]. [PubMed: 12359135]
22. Stamou KM, Toutouzas KG, Kekis PB, Nakos S, Gafou A, Manouras A, Krespis E, Katsaragakis S, Bramis J. Prospective study of the incidence and risk factors of postsplenectomy thrombosis of the portal, mesenteric, and splenic veins. *Arch Surg.* 2006; 141:663–669. [PMID: 16847237]. [PubMed: 16847237]
23. Thomsen RW, Schoonen WM, Farkas DK, Riis A, Fryzek JP, Sørensen HT. Risk of venous thromboembolism in splenectomized patients compared with the general population and appendectomized patients: a 10-year nationwide cohort study. *J Thromb Haemost.* 2010; 8:1413–1416. [PMID: 20218983]. [PubMed: 20218983]
24. Lang IM, Klepetko W. Chronic thromboembolic pulmonary hypertension: an updated review. *Curr Opin Cardiol.* 2008; 23:555–559. [PMID: 18830069]. [PubMed: 18830069]
25. Pengo V, Lensing AW, Prins MH, Marchiori A, Davidson BL, Tiozzo F, Albanese P, Biasiolo A, Pegoraro C, Iliceto S, Prandoni P. Incidence of chronic thromboembolic pulmonary hypertension after pulmonary embolism. *N Engl J Med.* 2004; 350:2257–2264. [PMID: 15163775]. [PubMed: 15163775]
26. Frey MK, Alias S, Winter MP, Redwan B, Stübiger G, Panzenboeck A, Alimohammadi A, Bonderman D, Jakowitsch J, Bergmeister H, Bochkov V, Preissner KT, Lang IM. Splenectomy is modifying the vascular remodeling of thrombosis. *J Am Heart Assoc.* 2014; 3:e000772. [PMID: 24584745]. [PubMed: 24584745]
27. Peacock AJ. Pulmonary hypertension after splenectomy: a consequence of loss of the splenic filter or is there something more? *Thorax.* 2005; 60:983–984. [PMID: 16299113]. [PubMed: 16299113]
28. Owens AP, Mackman N. Microparticles in hemostasis and thrombosis. *Circ Res.* 2011; 108:1284–1297. [PMID: 21566224]. [PubMed: 21566224]
29. Fontana V, Jy W, Ahn ER, Dudkiewicz P, Horstman LL, Duncan R, Ahn YS. Increased procoagulant cell-derived microparticles (C-MP) in splenectomized patients with ITP. *Thromb Res.* 2008; 122:599–603. [PMID: 18334267]. [PubMed: 18334267]
30. Atichartakarn V, Angchaisuksiri P, Aryurachai K, Onpun S, Chuncharunee S, Thakkinstian A, Atamasirikul K. Relationship between hypercoagulable state and erythrocyte phosphatidylserine exposure in splenectomized haemoglobin E/beta-thalassaemic patients. *Br J Haematol.* 2002; 118:893–898. [PMID: 12181063]. [PubMed: 12181063]
31. Kuypers FA. Phospholipid asymmetry in health and disease. *Curr Opin Hematol.* 1998; 5:122–131. [PMID: 9570705]. [PubMed: 9570705]
32. Kuypers FA, Yuan J, Lewis RA, Snyder LM, Kiefer CR, Bunyaratvej A, Fucharoen S, Ma L, Styles L, de Jong K, Schrier SL. Membrane phospholipid asymmetry in human thalassemia. *Blood.* 1998; 91:3044–3051. [PMID: 9531618]. [PubMed: 9531618]
33. Park D, Tosello-Tramont AC, Elliott MR, Lu M, Haney LB, Ma Z, Klibanov AL, Mandell JW, Ravichandran KS. BAI1 is an engulfment receptor for apoptotic cells upstream of the ELMO/Dock180/Rac module. *Nature.* 2007; 450:430–434. [PMID: 17960134]. [PubMed: 17960134]
34. Kaur B, Brat DJ, Devi NS, Van Meir EG. Vasculostatin, a proteolytic fragment of brain angiogenesis inhibitor 1, is an antiangiogenic and antitumorigenic factor. *Oncogene.* 2005; 24:3632–3642. [PMID: 15782143]. [PubMed: 15782143]
35. Amer J, Fibach E. Oxidative status of platelets in normal and thalassaemic blood. *Thromb Haemost.* 2004; 92:1052–1059. [PMID: 15543333]. [PubMed: 15543333]
36. Chen S, Eldor A, Barshtein G, Zhang S, Goldfarb A, Rachmilewitz E, Yedgar S. Enhanced aggregability of red blood cells of betathalassaemia major patients. *Am J Physiol.* 1996; 270:H1951–H1956. [PMID: 8764243]. [PubMed: 8764243]
37. Garozzo G, Distefano R, Miceli A, Bonomo P. Detection of ICAM-1, ICAM-2, ICAM-3, PECAM-1 and VCAM-1, evaluation of hypercoagulable state and platelet aggregation in

- hemoglobinopathy patients with erythroblasts. *Haematologica*. 2001; 86:778–779. [PMID: 11454542]. [PubMed: 11454542]
38. Phrommintikul A, Sukonthasarn A, Kanjanavanit R, Nawarawong W. Splenectomy: a strong risk factor for pulmonary hypertension in patients with thalassaemia. *Heart*. 2006; 92:1467–1472. [PMID: 16621878]. [PubMed: 16621878]
 39. Ho KM, Yip CB, Duff O. Reactive thrombocytosis and risk of subsequent venous thromboembolism: a cohort study. *J Thromb Haemost*. 2012; 10:1768–1774. [PMID: 22784217]. [PubMed: 22784217]
 40. Kashuk JL, Moore EE, Johnson JL, Biffi WL, Burlew CC, Barnett C, Sauaia A. Progressive postinjury thrombocytosis is associated with thromboembolic complications. *Surgery*. 2010; 148:667–674. discussion 674–675 [PMID: 20719351]. [PubMed: 20719351]
 41. Valade N, Decailliot F, Rébufat Y, Heurtematte Y, Duvaldestin P, Stéphan F. Thrombocytosis after trauma: incidence, aetiology, and clinical significance. *Br J Anaesth*. 2005; 94:18–23. [PMID: 15486007]. [PubMed: 15486007]
 42. Rostagno C, Prisco D, Abbate R, Poggese L. Pulmonary hypertension associated with long-standing thrombocytosis. *Chest*. 1991; 99:1303–1305. [PMID: 1826875]. [PubMed: 1826875]
 43. Marvin KS, Spellberg RD. Pulmonary hypertension secondary to thrombocytosis in a patient with myeloid metaplasia. *Chest*. 1993; 103:642–644. [PMID: 8432180]. [PubMed: 8432180]
 44. Singer ST, Kuypers F, Fineman J, Gildengorin G, Larkin S, Sweeters N, Rosenfeld H, Kurio G, Higa A, Jeng M, Huang J, Vichinsky EP. Elevated tricuspid regurgitant jet velocity in subgroups of thalassemia patients: insight into pathophysiology and the effect of splenectomy. *Ann Hematol*. 2014; 93:1139–1148. [PMID: 24577514]. [PubMed: 24577514]
 45. Thachil J. The enigma of pulmonary hypertension after splenectomy--does the megakaryocyte provide a clue? *QJM*. 2009; 102:743–745. [PMID: 19622674]. [PubMed: 19622674]
 46. Zucker-Franklin D, Philipp CS. Platelet production in the pulmonary capillary bed: new ultrastructural evidence for an old concept. *Am J Pathol*. 2000; 157:69–74. [PMID: 10880377]. [PubMed: 10880377]
 47. Hill G, McClean D, Fraser R, Hart D, Crozier I, Snowden J, Gibbons S. Pulmonary hypertension as a consequence of alveolar capillary plugging by malignant megakaryocytes in essential thrombocythaemia. *Aust N Z J Med*. 1996; 26:852–853. [PMID: 9028525]. [PubMed: 9028525]
 48. Theise ND, Ursell PC. Pulmonary hypertension and Gaucher's disease: logical association or mere coincidence? *Am J Pediatr Hematol Oncol*. 1990; 12:74–76. [PMID: 2309982]. [PubMed: 2309982]
 49. Tefferi A. Pathogenesis of myelofibrosis with myeloid metaplasia. *J Clin Oncol*. 2005; 23:8520–8530. [PMID: 16293880]. [PubMed: 16293880]
 50. Brittain EL, Janz DR, Austin ED, Bastarache JA, Wheeler LA, Ware LB, Hemnes AR. Elevation of plasma cell-free hemoglobin in pulmonary arterial hypertension. *Chest*. 2014; 146:1478–1485. [PMID: 24945582]. [PubMed: 24945582]
 51. Morris CR, Kuypers FA, Kato GJ, Lavrisha L, Larkin S, Singer T, Vichinsky EP. Hemolysis-associated pulmonary hypertension in thalassemia. *Ann N Y Acad Sci*. 2005; 1054:481–485. [PMID: 16339702]. [PubMed: 16339702]
 52. Ghosh K, Meera V, Jijina F. Pulmonary hypertension in patients with hematological disorders following splenectomy. *Indian J Hematol Blood Transfus*. 2009; 25:45–48. [PMID: 23100974]. [PubMed: 23100974]
 53. Battinelli E, Loscalzo J. Nitric oxide induces apoptosis in megakaryocytic cell lines. *Blood*. 2000; 95:3451–3459. [PMID: 10828028]. [PubMed: 10828028]
 54. Mannucci PM. Red cells playing as activated platelets in thalassemia intermedia. *J Thromb Haemost*. 2010; 8:2149–2151. [PMID: 20727069]. [PubMed: 20727069]
 55. Lo SM, Liu J, Chen F, Pastores GM, Knowles J, Boxer M, Aleck K, Mistry PK. Pulmonary vascular disease in Gaucher disease: clinical spectrum, determinants of phenotype and long-term outcomes of therapy. *J Inher Metab Dis*. 2011; 34:643–650. [PMID: 21445609]. [PubMed: 21445609]
 56. Machado RF, Barst RJ, Yovetich NA, Hassell KL, Kato GJ, Gordeuk VR, Gibbs JS, Little JA, Schraufnagel DE, Krishnamurti L, Girgis RE, Morris CR, Rosenzweig EB, Badesch DB, Lanzkron

- S, Onyekwere O, Castro OL, Sachdev V, Waclawiw MA, Woolson R, Goldsmith JC, Gladwin MT. Hospitalization for pain in patients with sickle cell disease treated with sildenafil for elevated TRV and low exercise capacity. *Blood*. 2011; 118:855–864. [PMID: 21527519]. [PubMed: 21527519]
57. Derchi G, Forni GL, Formisano F, Cappellini MD, Galanello R, D' Ascola G, Bina P, Magnano C, Lamagna M. Efficacy and safety of sildenafil in the treatment of severe pulmonary hypertension in patients with hemoglobinopathies. *Haematologica*. 2005; 90:452–458. [PMID: 15820939]. [PubMed: 15820939]
58. Morris CR, Kim HY, Wood J, Porter JB, Klings ES, Trachtenberg FL, Sweeters N, Olivieri NF, Kwiatkowski JL, Virzi L, Singer ST, Taher A, Neufeld EJ, Thompson AA, Sachdev V, Larkin S, Suh JH, Kuypers FA, Vichinsky EP. Sildenafil therapy in thalassemia patients with Doppler-defined risk of pulmonary hypertension. *Haematologica*. 2013; 98:1359–1367. [PMID: 23585527]. [PubMed: 23585527]
59. Barst RJ, Mubarak KK, Machado RF, Ataga KI, Benza RL, Castro O, Naeije R, Sood N, Swerdlow PS, Hildesheim M, Gladwin MT. Exercise capacity and haemodynamics in patients with sickle cell disease with pulmonary hypertension treated with bosentan: results of the ASSET studies. *Br J Haematol*. 2010; 149:426–435. [PMID: 20175775]. [PubMed: 20175775]
60. Galiè N, Corris PA, Frost A, Girgis RE, Granton J, Jing ZC, Klepetko W, McGoon MD, McLaughlin VV, Preston IR, Rubin LJ, Sandoval J, Seeger W, Keogh A. Updated treatment algorithm of pulmonary arterial hypertension. *J Am Coll Cardiol*. 2013; 62:D60–D72. [PMID: 24355643]. [PubMed: 24355643]
61. Baughan AS, Worsley AM, McCarthy DM, Hows JM, Catovsky D, Gordon-Smith EC, Galton DA, Goldman JM. Haematological reconstitution and severity of graft-versus-host disease after bone marrow transplantation for chronic granulocytic leukaemia: the influence of previous splenectomy. *Br J Haematol*. 1984; 56:445–454. [PMID: 6365154]. [PubMed: 6365154]
62. Galiè N, Simonneau G. 5th World Symposium on Pulmonary Hypertension. *Journal of the American College of Cardiology*. 2013; 62:D1–D3. [PubMed: 24355633]
63. Palkar AV, Verma S, Iftikhar A, Lisker G, Kohn N, Talwar A. Splenectomy: Implications in Patients Referred for Evaluation of Pulmonary Hypertension. *Am J Respir Crit Care Med*. 2015; 191:A5514.

Core tip

Pulmonary hypertension is an often underrecognized non-infectious complication after splenectomy. The mechanisms for the development of pulmonary hypertension in this setting are multifactorial and are not clearly elucidated. We attempt to outline and highlight the current evidence behind these proposed mechanisms of post splenectomy related pulmonary hypertension.

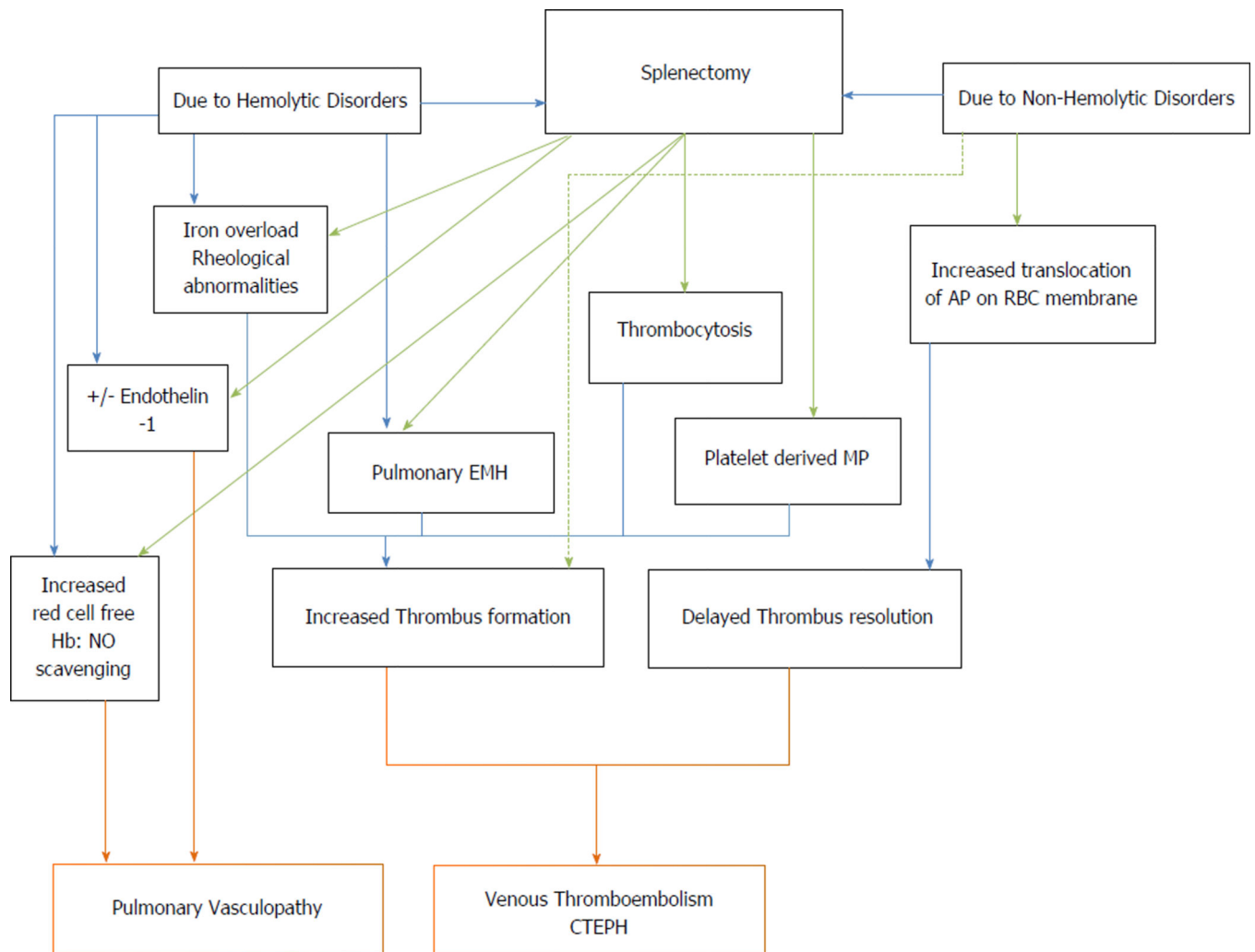


Figure 1. Proposed mechanisms for the development of pulmonary vasculopathy after splenectomy

Solid lines represents known mechanisms, Dotted line represents hypothesized mechanisms.

Hb: Hemoglobin; NO: Nitric oxide; EMH: Extra medullary hematopoiesis; MP: Micro-particles; AP: Anionic phospholipids; RBC: Red blood cell; CTEPH: Chronic thromboembolic pulmonary hypertension.

Table 1

Medical complications after splenectomy

Early
Lower lobe collapse of left lung
Left pleural effusion
Pneumonia
Venous thromboembolism
Subphrenic abscess
Delayed
Overwhelming infections: bacterial (<i>Streptococcus pneumoniae</i> , <i>Hemophilus influenzae</i> , <i>Staphylococcus aureus</i> , <i>Streptococcus</i> group B, <i>Salmonella</i> species, <i>Escherichia coli</i> and other coliforms, <i>Campylobacter jejuni</i> and rarely <i>Pseudomonas aeruginosa</i>), parasitic (Babesiosis Plasmodium species, Ehrlichiosis)
Venous thromboembolism
Pulmonary Hypertension
Graft vs host disease ^[61]

Author Manuscript

Author Manuscript

Author Manuscript

Author Manuscript

Table 2World Health Organization's classification of pulmonary hypertension^[10]

<p>Group I - Pulmonary Arterial hypertension (PAH)</p> <ul style="list-style-type: none"> Idiopathic PAH Heritable PAH (BMPR2, ALK1, ENG, SMAD9, CAV1, KCNK3, Unknown) Drug and toxin induced Associated with (1) Connective tissue disease; (2) HIV infection; (3) Portal hypertension; (4) Congenital heart disease; and (5) Schistosomiasis Pulmonary veno-occlusive disease and/or pulmonary capillary hemangiomatosis Persistent pulmonary hypertension of the newborn <p>Group II - Pulmonary hypertension due to left heart disease</p> <ul style="list-style-type: none"> Left ventricular systolic dysfunction Left ventricular diastolic dysfunction Valvular disease Congenital/acquired left heart inflow/outflow tract obstruction and congenital cardiomyopathies <p>Group III - Pulmonary hypertension due to lung diseases and/or hypoxia</p> <ul style="list-style-type: none"> Chronic obstructive pulmonary disease Interstitial lung disease Other pulmonary diseases with mixed restrictive and obstructive pattern Sleep-disordered breathing Alveolar hypoventilation disorders Chronic exposure to high altitudes Developmental lung disease <p>Group IV - Chronic thromboembolic pulmonary hypertension</p> <p>Group V - Pulmonary hypertension with unclear multifactorial mechanisms</p> <ul style="list-style-type: none"> Hematologic disorders: chronic hemolytic anemia, myeloproliferative disorders, splenectomy Systemic disorders: sarcoidosis, pulmonary histiocytosis, lymphangioleiomyomatosis Metabolic disorders: glycogen storage disease, Gaucher's disease, hypothyroidism Others: tumoral obstruction, fibrosing mediastinitis, chronic renal failure, segmental pulmonary hypertension
--

Adapted from Galiè *et al*^[62]. BMPR: Bone morphogenic protein receptor type II; CAV1: Caveolin-1; ENG: Endoglin; HIV: Human immunodeficiency virus.

Table 3

List of splenectomy and pulmonary hypertension studies

Ref.	Patient cohort (n)	Study design	No. of patients with splenectomy	Method of PH diagnosis	Comment
Hooper <i>et al</i> ^[8]	Unexplained PHTN (61)	Retrospective	7	RHC	3 patients had splenectomy for hereditary spherocytosis and trauma, one patient with ITP
Jaïs <i>et al</i> ^[11]	CTEPH (257)	Retrospective	22 (8.6%)	RHC	15 patients had splenectomy after trauma, 4 with hemolytic disorder
Jaïs <i>et al</i> ^[11]	Idiopathic PHTN (276)	Retrospective	7 (2.5%)	RHC	Lower prevalence of splenectomy in idiopathic PHTN compared to prior study
Phrommintikul <i>et al</i> ^[38]	PHTN in Thalassemia with Hb < 10 g/dL (29)	Retrospective	29 (75.8%)	TTE	Increased prevalence of PHTN with higher nucleated red cells, platelets and transfusion requirement in splenectomised patients than those with intact spleen.
Elstein <i>et al</i> ^[16]	Gaucher's disease (134), 9 patients had PH	Retrospective	6	TTE	All patients with PHTN had enzyme replacement therapy
Stewart <i>et al</i> ^[15]	Hereditary stomatocytosis after splenectomy (9)	Retrospective	9	2 RHC 1 on autopsy	3 patients developed CTEPH, one portal hypertension
Palkar <i>et al</i> ^[63]	PHTN after splenectomy (9)	Retrospective	9	RHC	4 patients belonged to group 1, two to group 4 and one each in groups 2, 3 and 5

RHC: Right heart catheterization; TTE: Transthoracic echocardiography; ITP: Immune thrombocytopenic purpura; PHTN: Pulmonary hypertension.