

The demonstration of plasma cells and other immunoglobulin-containing cells in formalin-fixed, paraffin-embedded tissues using peroxidase-labelled antibody

C. R. TAYLOR AND J. BURNS

From the Department of Pathology, Gibson Laboratories, Radcliffe Infirmary, Oxford

SYNOPSIS A method is described for the demonstration of specific immunoglobulin in plasma cells and other lymphoid cells in sections taken from routine surgical histology specimens which have been formalin fixed and paraffin embedded.

An indirect sandwich technique was employed using specific rabbit antihuman immunoglobulin antisera (anti-K, L, G, A, and M) and a swine antirabbit serum Ig G, conjugated with horseradish peroxidase. The presence of plasma cells was revealed by staining the tissue-bound peroxidase-labelled antibody, having previously stained the endogenous peroxidase a contrasting colour.

It was possible to demonstrate clearly immunoglobulin in the plasma cells of tissues processed and embedded several years previously.

Some of the potential uses of the method are discussed.

Plasma cells have been recognized by histologists since the classical description of Marschalkó (1895a and b). The relationship of these cells to antibody production became widely accepted following the work of Amano *et al* in 1944 (see 'The morphology of plasma cells', Feldman, 1972) and Fagreau (1948), and the development of fluorescein labelling methods (Coons, Creech, and Jones, 1941; Coons, 1956). Fluorescent antibody techniques have since been used extensively to demonstrate the presence of immunoglobulins within cells or bound to tissue components.

The routine use of immunofluorescence is inhibited by the requirement for frozen unfixed tissue or cold alcohol-fixed tissue (Sainte-Marie, 1962). There is also the problem of standardization (Holborow 1970), while rapid fading of positive fluorescence makes it difficult to refer back directly to previous work. Formalin-fixed tissue does not lend itself to immunofluorescence methods, because the enhancement of intrinsic tissue autofluorescence masks any specific fluorescent staining.

The use of antibody labelled with horseradish

peroxidase (Nakane and Pierce, 1966; Nakane, 1968; Avrameas, 1969; Avrameas and Ternynck, 1969) has resolved some of these difficulties as it affords a permanent preparation. Tissue-bound immunoglobulin has been successfully demonstrated, eg, on renal basement membranes (Davey and Busch, 1970) using peroxidase-conjugated antibody and the specificity and sensitivity of the method have been favourably compared with established fluorescence methods (Nakane and Pierce, 1966; Davey and Busch, 1970; Petts and Roitt, 1971).

This paper presents a method for demonstrating the presence of immunoglobulin in lymphoid cells in routine formalin-fixed, paraffin-embedded tissues using a peroxidase-conjugated antibody and an indirect sandwich technique.

Materials and Methods

Paraffin-embedded tissue blocks were selected from surgical histology specimens received in the Department of Morbid Anatomy at the Radcliffe Infirmary. Tissues had been routinely processed on the laboratory Histokinettes by the recommended schedule using industrial methylated spirit and chloroform

following adequate fixation in 10% formol saline.

Blocks were selected on the basis of the presence of plasma cells in haematoxylin and eosin preparations and sections were cut at 3-4 μ on a sliding microtome. The sections were dewaxed with xylol and taken through the alcohols to water.

The subsequent method is summarized in table I. Sections in water were stained to demonstrate endogenous peroxidase using either the Graham alpha-naphthol-pyronin stain (Lillie, 1965) or the diaminobenzidine (DAB¹) method (Graham and Karnovsky 1966). The duration of exposure of the sections to DAB or to the pyronin component of the alpha-naphthol-pyronin stain was greatly reduced so that the cells containing endogenous peroxidase were only lightly stained. This preliminary reaction was utilized to 'block' the endogenous peroxidase and prevent it staining when the antibody-conjugated peroxidase was developed subsequently. The intensity of the alpha-naphthol-pyronin reaction could be further reduced if desired by differentiation in 70% alcohol. This was found to be more generally acceptable than orthodox blocking reactions which failed to eliminate completely endogenous peroxidase activity.

Sections were then placed in phosphate-buffered saline (PBS), pH 7.4, and exposed to a range of rabbit antihuman immunoglobulin antibodies. A dilution of antibody of 1/10 with an exposure of one hour was generally satisfactory. Preparations were washed in a bath of PBS for one hour with gentle agitation and were then treated with swine antirabbit serum IgG conjugated with horseradish peroxidase (SwaR/P) at a dilution of 1/10 for one hour, followed by a further thorough washing in phosphate-buffered saline.

¹3,3'-Diaminobenzidine tetrahydrochloride (3,4,3',4'-tetra-aminobiphenyl hydrochloride) (BDH Chemicals, Poole, England), being the soluble form, was used as recommended by Graham and Karnovsky.

The tissue-bound peroxidase-conjugated antibody was then stained by the Graham alpha-naphthol-pyronin or the DAB method to produce a colour contrasting with the endogenous peroxidase (see table I). At this stage the full intensity of the reaction was allowed to develop.

Optimum results were achieved by observing the development of the reaction on a microscope stage until a maximum contrast was obtained between positive cells and background. The reaction was then halted simultaneously in all the sections of a series by washing in phosphate-buffered saline. If the DAB reaction was allowed to proceed for more than 10 to 15 minutes background staining became a problem, particularly if much collagen was present. Osmication was not employed with either method. Finally the sections were briefly counterstained with methyl green or a modified Harris's haematoxylin (Lie, Holley, Kampa, and Titus, 1971) with or without eosin, dehydrated, cleared, and mounted in DPX.

The swine antirabbit serum IgG was obtained from Dakopatts A-S (through Mercia, Sandown Road, Watford, England). Unconjugated rabbit antihuman kappa (K) and lambda (L) light chains (Bence Jones) were also obtained from Dakopatts, and the rabbit antihuman Ig G, IgA, and IgM (heavy chains) from Behringwerke AG, Germany. Control preparations used included alpha naphthol pyronin alone, DAB alone, and alpha naphthol pyronin followed by DAB, SwaR/P with DAB, and anti-kappa or anti-lambda blocked with a urine concentrate of Bence Jones protein kappa (13 mg/ml) or lambda (20 mg/ml) type.

In addition the series of antibodies (anti-K, L, G, A, or M) used with each specimen acted as an inherent control by the varying number of cells staining with each antibody, both positive and negative plasma cells being seen in every case.

Colour photomicrographs were obtained with Agfachrome 50 L (18 DIN. ASA 50).

Stage No.	Procedure
1	3 μ paraffin sections, xylol-alcohols-water
2	Alpha-naphthol pyronin or DAB (briefly) to demonstrate and block endogenous peroxidase ¹
3	Transfer to PBS, pH 7.4, for optimum antibody activity
4	Rabbit antihuman gamma globulin 1/10 for 1 hour (use anti-K or L, G, A, or M on serial sections)
5	Wash 1 hour PBS
6	SwaR/P 1/10 for 1 hour
7	Wash 1 hour PBS
8	Develop antibody-conjugated peroxidase with DAB (if alpha naphthol pyronin used in 2) or with alpha naphthol pyronin (if DAB used in 2) allowing full intensity of reaction to develop
9	Wash in PBS
10	Counterstain with methyl green or haematoxylin and eosin
11	Blot dry (for methyl green), dehydrate through the alcohols-xylol, mount in DPX

Table I Summary of method for demonstration of immunoglobulin-containing cells in formalin-fixed, paraffin-embedded tissues.

¹This 'blocking' reaction may be omitted if a preliminary stain shows very few cells containing endogenous peroxidase. Also directly conjugated anti-IgG and anti-IgM have been used with satisfactory results, eliminating stages 6 and 7.

Results

Generally the best results were obtained by staining the endogenous peroxidase with alpha-naphthol-pyronin. This produced a reddish purple colour which could be reduced in intensity if required so as not to be apparent after counterstaining. The antibody-conjugated peroxidase was then demonstrated using the DAB method and a high intensity brown colour achieved without any brown discolouration of cells containing endogenous peroxidase (figs 1, 3, and 4).

The converse reaction, staining the endogenous peroxidase with DAB (brown) and developing the antibody-conjugated peroxidase with alpha naphthol (pink), also produced satisfactory results, but the pink plasma cells were less prominent than when developed brown with DAB (compare fig 2 with fig 4).

When preliminary haematoxylin and eosin or DAB staining showed few or no plasma cells the initial blocking stage was unnecessary. This was often the case with plasmacytomas which included few neutrophils or eosinophils (figs 5 and 6).

The presence of haemoglobin peroxidase causes red cells to stain brown with the DAB reaction, and, unlike eosinophil and neutrophil peroxidase, this is not masked by previous exposure to alpha naphthol pyronin. This, however, provided few problems in interpretation of most specimens, the exception being marrow tissue where some of the brown

staining erythroblasts were not readily distinguishable from positive lymphocytes and plasma cells.

Methyl green was a satisfactory counterstain for low power microscopy, producing very good contrast (figs 3 and 4). For more detailed cell morphology a modified Harris's haematoxylin (Lie *et al*, 1971) was used, alone or with eosin (fig 1).

The morphology of the positive cells in many cases corresponded to the classical plasma cell, but some cells were more lymphoid in form. Particularly the cells staining with anti-IgM showed a wide range of morphology.

The relative proportion of positive cells in each specimen examined is shown in table II. The high intensity of positive staining observed was in the majority of cases clearly distinguishable from any background stain. In Hodgkin's disease, Hashimoto's disease, and reactive lymph node hyperplasia both K and L cells were present in large numbers. Similarly positive cells were distributed in each of the three immunoglobulin classes G, A, and M. Also with each antibody both positive and negative plasma cells were seen in the same section (fig 1). In the plasmacytomas the distribution of positive immunoglobulin-containing cells was notably different. Not all the abnormal plasma cells showed positive staining, but those which could be shown to contain immunoglobulin were of a single type, K or L, and either G, A, or M (figs 5 and 6).

The specificity of the anti-K and anti-L antisera used was further confirmed by the blocking reactions

Case Number	Tissue	Diagnosis	Relative Number of Positive Cells ¹						Total % Lymphoid Cells Positive ²	Endogenous Peroxidase Activity ³
			Anti-K	Anti-L	Anti-IgG	Anti-IgA	Anti-IgM	Control		
6270/73	Thyroid	Hashimoto's disease	+++++	+++++	+++++	+++++	+	-	60	-
6021/73	Lymph node	Hodgkin's disease	+++++	++++	+++++	+++	+	-	10	++
2387/73	Lymph node	Hodgkin's disease	+++++	++++	+++++	+++++	+	-	15	+++
9706/72	Lymph node	Reactive hyperplasia	+++++	++++	+++++	+++++	+	-	25	+
5154/72	Biopsy of cervix	Solitary plasmacytoma, serial biopsies; same patient	++++	-	-	-	-	-	30	- ⁴
5114/72			+++++	-	-	-	-	-	60	- ⁴
3013/71			+++++	-	++	-	-	-	60	- ⁴
7379/71	Biopsy bowel	Solitary plasmacytoma	+++++	(+) ³	(-) ³	(+) ³	+++++	-	80	- ⁴
4926/70	Biopsy bone	Multiple myeloma	(+) ³	+++++	++++	(+) ³	-	-	60	- ⁴
1071/70	Biopsy maxillary antrum	Multiple myeloma	+++++	-	++++	-	-	-	80	- ⁴

Table II Summary of results in specimens examined

¹Only strongly positive cells were scored. These were easily distinguished as background staining was minimal. Control preparations, saline substituted for rabbit antihuman antisera in stage 4 (table I).

²Total percentage of lymphoid cells positive estimated from sum of K positive and L positive cells.

³Occasional morphologically normal plasma cells in inflammatory response at periphery of tumour proper. Abnormal cells of tumour itself uniformly negative.

⁴In these specimens staining of endogenous peroxidase unnecessary as very few neutrophils or eosinophils present. Endogenous peroxidase activity, score of neutrophils and eosinophils present.

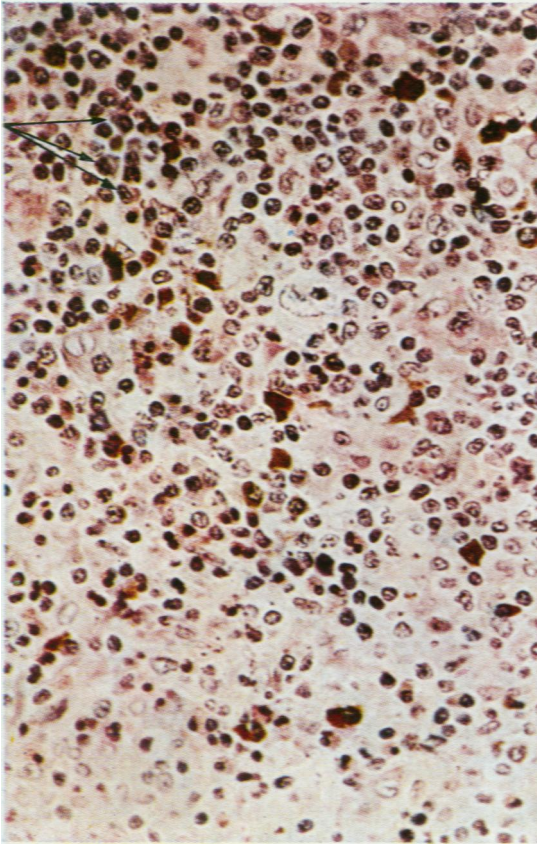


Fig 1

Fig 1 SH. 2387/73. Lymph node. Hodgkin's disease. Endogenous peroxidase 'blocked' with alpha naphthol pyronin. Anti-L followed by SwaR/P and DAB. Plasma cells containing lambda chains appear brown. Arrows indicate negative plasma cells (K type). Counterstain H and E \times 400.

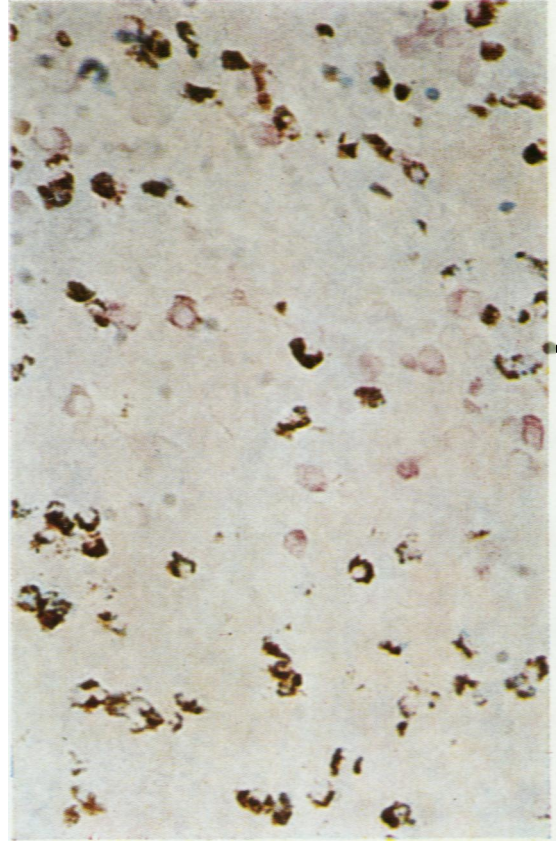


Fig 2

Fig 2 SH. 2387/73. Endogenous peroxidase 'blocked' with DAB. Anti-K followed by SwaR/P and alpha naphthol pyronin. Plasma cells containing kappa chains appear pink. Eosinophils brown. No counterstain. \times 500.

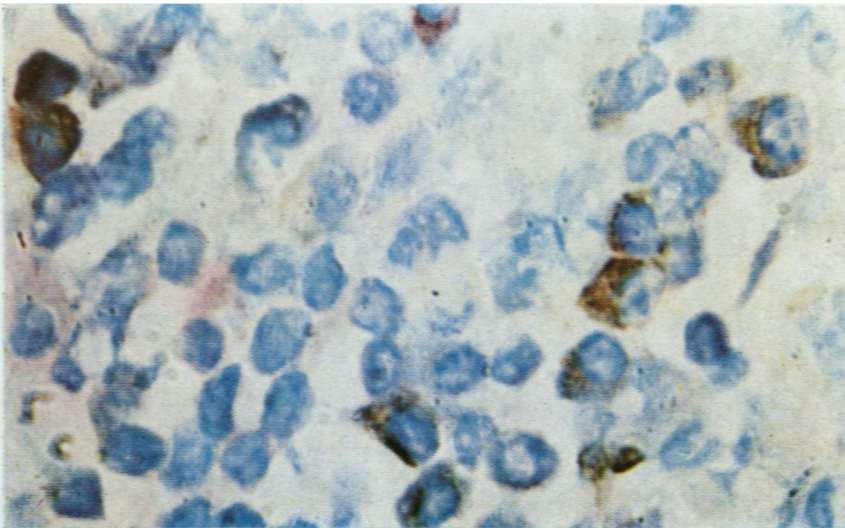


Fig 3 SH. 2387/73. Endogenous peroxidase 'blocked' with alpha naphthol pyronin. Anti-G followed by DAB. Plasma cells containing G heavy chains appear brown. Eosinophils red, as pyronin stain allowed to develop full intensity. Counterstain methyl green. \times 1200.

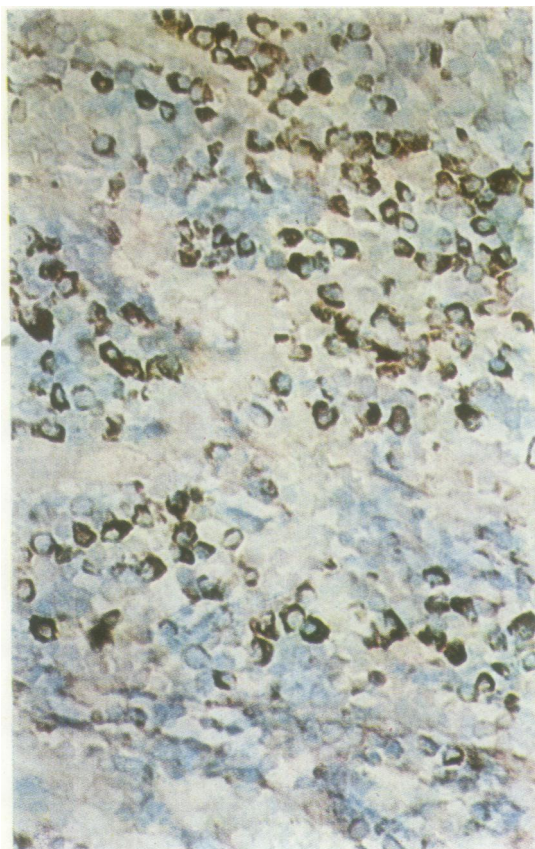

Fig. 4

Fig 4 SH. 2387/73. Endogenous peroxidase 'blocked' with alpha naphthol pyronin. Anti-K followed by DAB. Plasma cells containing kappa chains appear brown. Eosinophils not prominent as pyronin reduced in intensity. Counterstain methyl green. × 500.

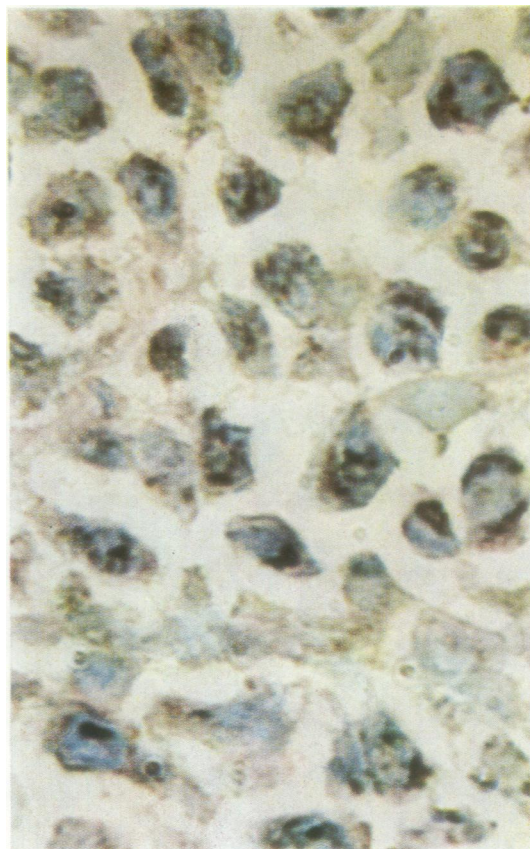

Fig. 5

Fig 5 SH. 5114/72. Plasmacytoma. Blocking of endogenous peroxidase not necessary. Anti-K followed by DAB. Cells containing kappa chains appear brown. Counterstain methyl green. × 1200. Compare with figure 6.

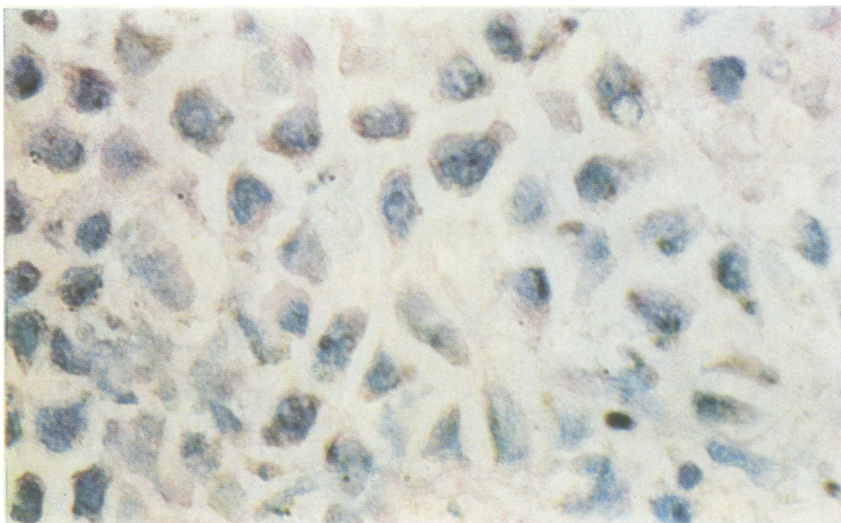


Fig 6 SH. 5114/72.
Blocking of endogenous peroxidase not necessary, serial section to figure 5. Anti-L followed by DAB. There are no brown positive cells, indicating the monoclonal nature of the plasmacytoma cell population. Counterstain methyl green. × 1200.

with urine concentrates of Bence Jones proteins, K or L type (table III).

	<i>Intensity of Positive Staining^a of Serial Sections of SH 6270/73</i>
Anti-K diluted 1/10 with L urine	+++
Anti-K diluted 1/10 with K urine	±
Anti-L diluted 1/10 with L urine	+±
Anti-L diluted 1/10 with K urine	+++
Anti-K diluted 1/10 PBS	++++
Anti-L diluted 1/10 PBS	++++

Table III *Blocking of anti-K and anti-L with kappa (K) and lambda (L) light chains¹*

¹Concentrated Bence Jones urine: K 13 mg/ml and L 20 mg/ml of light chain.

²The method was as in table I with the above antibodies substituted in stage 4.

Discussion

The method described has been successfully used to demonstrate specifically immunoglobulin within the lymphoid cells of the tissues examined. The majority of positive cells have a typical plasma cell morphology but some other cells of the lymphoid series also contain immunoglobulin. This spectrum of appearances for immunoglobulin-producing cells is in agreement with other studies (Bosman, Feldman, and Pick, 1969; Bosman and Feldman, 1970). In the cases of Hodgkin's disease examined some of the Reed-Sternberg-type cells also showed positive staining of moderate intensity. The specificity and significance of this observation is the subject of continuing study.

Good results have been obtained in formalin-fixed, paraffin-embedded tissues which have been routinely stored for five years or more. Initial results suggest that as a means of recognizing or quantitating immune responses this technique is superior to plasma cell counting with orthodox histological stains.

In addition the cellular morphology observed in these preparations is much more distinct than that seen in immunofluorescence studies using frozen sections or cold alcohol processed material (Sainte-Marie, 1962). The specificity and sensitivity of peroxidase-labelled antibody techniques have been favourably compared to immunofluorescence methods (Nakane and Pierce, 1966; Davey and Busch, 1970), and a study comparing the two methods is currently proceeding.

In sections exposed simultaneously to both anti-K and anti-L, negative plasma cells clearly comprised less than 10% of the total, indicating a useful degree of sensitivity. Specificity was also of a high order, for with each antiserum there remained a negative

population of plasma cells alongside those showing clear positive staining, and the number of positive cells varied for anti-IgG, anti-IgA, and anti-IgM. The labelled antibody having a molecular weight in the region of 200,000 appeared to penetrate the section adequately.

The preliminary staining of endogenous peroxidase with a contrasting colour proved highly successful and excluded further staining when the conjugated peroxidase was subsequently developed. The intensity of staining could be varied so as to visualize eosinophils and neutrophils, or it could be reduced so that these cells were not apparent after counter-staining. Effective blocking of endogenous peroxidase activity by other means was not achieved.

The results described have been reproduced by other workers in these laboratories and wider application may allow some quantitation of the degree of antibody response in the large number of surgical specimens stored as paraffin blocks in any routine histology laboratory.

The technique may be of especial value in the diagnosis of multiple myeloma where the malignant clone can be recognized as purely K or purely L chain in nature, and exclusively IgG, IgA, or IgM. This was demonstrated in the four cases reported here, where the plasmacytoma cells were of a single type in each case. In the inflammatory tissue at the periphery of some of these plasma cell tumours morphologically normal plasma cells were seen, with the normal mixture of immunoglobulin types present. A more extensive study of myeloma tissue, both from biopsy and from marrow aspiration, is in progress.

We are indebted to Maria Lobban for valuable technical assistance, to Dr D. Y. Mason for clinical information on the myeloma cases, to Dr T. Parry for preparation of the photographs, to Mrs J. Braidwood for typing the script, and to Dr A. H. T. Robb-Smith for unflinching encouragement. M. Lobban is supported by a grant from the Leukaemia Research Fund.

References

- Avrameas, S. (1969). Indirect immunoenzyme techniques for the intracellular detection of antigens. *Immunochemistry*, **6**, 825-831.
- Avrameas, S., and Ternynck, T. (1969). The cross-linking of proteins with glutaraldehyde and its use for the preparation of immunoadsorbents. *Immunochemistry*, **6**, 53-66.
- Bosman, C., and Feldman, J. D. (1970). Heterogeneity and homogeneity of immunoglobulin-forming cells. *Lab. Invest.*, **22**, 309-317.
- Bosman, C., Feldman, J. D., and Pick, E. (1969). Heterogeneity of antibody-forming cells: an electron microscopic analysis. *J. exp. Med.*, **129**, 1029-1044.
- Coons, A. H. (1956). Histochemistry with labelled antibody. *Int. Rev. Cytol.*, **5**, 1-23.
- Coons, A. H., Creech, H. J., and Jones, R. N. (1941). Immunological properties of an antibody containing a fluorescent group. *Proc. Soc. exp. Biol. (N.Y.)* **47**, 200-202.

- Davey, F. R., and Busch, G. J. (1970). Immunohistochemistry of glomerulonephritis using horseradish peroxidase and fluorescein-labeled antibody: a comparison of two techniques. *Amer. J. clin. Path.*, **53**, 531-536.
- Fagreus, A. (1948). Antibody production in relation to the development of plasma cells: in vivo and in vitro experiments. *Acta med. scand.*, **130**, Suppl. 204.
- Feldman, J. D. (1972). The morphology of plasma cells. In *Hematology*, edited by W. J. Williams *et al*, pp. 771-781. McGraw-Hill New York.
- Graham, R. C., Jr., and Karnovsky, M. J. (1966). The early stages of absorption of injected horseradish peroxidase in the proximal tubules of mouse kidney: ultrastructural cytochemistry by a new technique. *J. Histochem. Cytochem.*, **14**, 291-302.
- Holborow, E. J. Ed. (1970). *Standardisation in Immunofluorescence*. Blackwell, Oxford.
- Lie, J. T., Holley, K. E., Kampa, W. R., and Titus, J. L. (1971). New histochemical method for morphological diagnosis of early stages of myocardial ischaemia. *Mayo Clin. Proc.*, **46**, 319-327.
- Lillie, R. D. (1965). *Histopathological Technic and Practical Histochemistry*, 3rd. ed., p. 371. McGraw-Hill, London.
- Marschalkó, T. (1895a). Ueber die sog en annten. Plasmazellen, ein Beitrag, zur Kenntniss der Herkunft der Entzündlichen Infiltrationszellen. *Arch. Derm. Syph. (Berl.)*, **30**, 241-282.
- Marschalkó, T. (1895b). A agynevezett plasmasejtekéről, adatok a lobos beszűrődés sejteinek eredetéhez (The so-called plasma cells: contributions on the origin of the inflammatory percolation of cells). *Orv. Hetil.*, **39**, **36**, 49 and 63.
- Nakane, P. K. (1968). Simultaneous localization of multiple tissue antigens using the peroxidase-labeled antibody method: a study on pituitary glands of the rat. *J. Histochem. Cytochem.*, **16**, 557-560.
- Nakane, P. K., and Pierce, G. B., Jr. (1966). Enzyme-labelled antibodies: preparation and application for the localization of antigens. *J. Histochem. Cytochem.*, **14**, 929-931.
- Petts, V., and Roitt, I. M. (1971). Peroxidase conjugates for demonstration of tissue antibodies: evaluation of the technique. *Clin. exp. Immunol.*, **9**, 407-418.
- Sainte-Marie, G. (1962). A paraffin embedding technique for studies employing immunofluorescence. *J. Histochem. Cytochem.*, **10**, 250-256.