

RADIOKYMOGRAPHY IN PATENT DUCTUS ARTERIOSUS

BY

K. SHIRLEY SMITH AND FRANKLIN G. WOOD

From The London Chest Hospital

Received February 9, 1949

The introduction of radiokymography dates from the pioneer work of Gött and Rosenthal (1912). The modern multiple slit kymograph was developed subsequently by Stumpf and his co-workers (1934), while later studies were made by Faber and Kjaergaard (1936) and Bordet and Fischgold (1937). In an earlier paper one of us (Wood, 1939) described the kymographic patterns that comprise the borders of the normal cardiac silhouette.

In the present study, X-ray kymography has been applied to the diagnosis of patent ductus arteriosus. The development during the past decade of the surgical treatment of the condition has greatly increased the importance of a diagnosis that may be difficult. In some cases the characteristic continuous murmur is not present and according to statistics quoted by Brown (1939) the pathognomonic murmur is absent in more than half of the cases. On the other hand Taussig (1947) claims that the diagnosis is based on the finding of a continuous murmur over the pulmonary area and that unless such a murmur is present the diagnosis cannot be made with certainty. It is when a murmur confined to systole is heard at the pulmonary area that diagnostic difficulties are likely to arise. Differentiation from pulmonary stenosis may not be easy and the possibility that patency of the ductus may be associated with other anomalies has to be remembered. It is an essential part of the diagnosis to exclude associated defects since when these exist ligature of a ductus may abolish an important compensatory mechanism. As exploratory operations are obviously undesirable, no effort must be spared to determine the correct diagnosis. We consider that the radiokymographic appearances which we now present should help to place the diagnosis of patent ductus arteriosus on a secure basis.

METHOD OF INVESTIGATION AND RADIOGRAPHIC TECHNIQUE

We have made radiokymographs in every patient in whom a diagnosis of patent ductus arteriosus was made or entertained. The majority of these later came to operation and in every instance the diagnosis was confirmed. The kymographs were all taken with the moving grid technique at a focus film distance of four feet. The grid used has a spacing of 11.5 mm. between the horizontal slits. At first, an exposure time of 3 seconds was used but later the rate of fall of the grid was increased to give an exposure of 1.8 seconds. At this speed satisfactory tracings were obtained with a heart beating at the normal rate, and also in patients with tachycardia.

Kymographs in the postero-anterior position were taken and these were supplemented by films in the oblique positions, especially the left oblique, whenever this appeared desirable. A standard exposure time was maintained so that the tracings made were comparable. This applied particularly where kymographs before and after operation were contrasted. The exposure factors were 65 KVP for children and as much as 90 KVP for full size adults, using 100 milliamperes with a rotating anode tube. In sixteen patients operation for ligature of the patent ductus was subsequently undertaken.

X-RAY APPEARANCES

The abnormality most commonly found in postero-anterior films of patients with patent ductus arteriosus is a prominence of the pulmonary arc and, in less degree, of the pulmonary conus. The cardiac outline may in other instances be entirely normal in patients proved at operation to have the same congenital defect. Taussig (1947) has referred to the slight prominence of the pulmonary conus in some normal children, and has insisted that the

diagnosis of patent ductus arteriosus should never be based solely on the contour of the heart. Consequently, the diagnosis must depend largely upon the murmurs unless other means are available, such as radiokymography.

The kymographic appearances of the left border of the cardiac silhouette in the normal heart may be summarized as follows. In the ventricular area waves of a certain type are seen; these consist of a curved upper limb due to the slow relaxation of the ventricle in diastole and a more horizontal lower limb representing the rapid contraction in systole. Above this is the zone of mixed or confused movements described originally by Stumpf (1934). This lies between the pulmonary artery waves above and those of the left ventricle below. The aorta and pulmonary artery show characteristic waves which have an almost horizontal upper limb due to lateral displacement by the pulse wave and a sloping lower limb representing the subsequent slower elastic recoil.

Light is thrown on the origin of the mixed movements by the kymograph shown in Fig. 1 which is taken from a man aged, 70, with complete heart block. There is one large ventricular wave recorded in the left ventricular area in each segment whereas at the lower part of the right border during the corresponding interval of time three distinct waves are seen which can only be ascribed to auricular contractions. In the segment immediately above

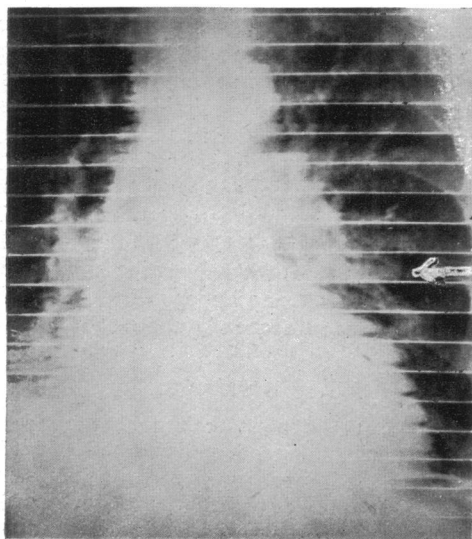
the left ventricular region a further three waves can be seen of a similar rhythm which must also be auricular in origin and be ascribed to the left auricle or left auricular appendix which curves forward in this area at the root of the great vessels. This provides evidence that the left auricle may form part of the left border of the cardiac silhouette. It also shows that the mixed movements described must be partly auricular in origin, the other components being the super-imposed pulmonary artery waves. This zone of mixed movements must not be confused with the fine vibration waves described below, which lie in the ductus area between the aortic and the pulmonary artery levels.

KYMOGRAPHIC SIGNS IN PATENT DUCTUS ARTERIOSUS


In our kymographic study of sixteen patients with patent ductus arteriosus proved at operation, we have observed four special features of the left border of the cardiac silhouette. They are as follows.

- (1) Para-aortic waves.
- (2) Vibration waves.
- (3) Exaggerated pulmonary artery waves.
- (4) Exaggerated upper left ventricular waves.

Of these four signs the first two relate to the lesion itself while the last two are consequences of the hæmodynamic disorder caused by the defect. The features of each sign are described as follows.



A



B

FIG. 1.—Man, aged 70. Complete A-V block. (A) Kymograph. (B) Tracing showing auricular waves (marked by arrow) on left border of heart.

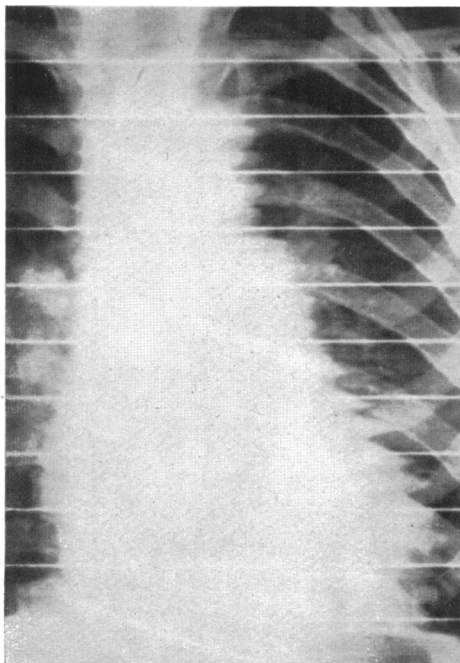
Para-aortic waves. These are wave forms which lie parallel to and lateral to the aortic knuckle. They are less dense than the shadow of the aorta, but are usually well seen when present as in Fig. 2. These waves differ from the zig-zag vascular shadows often seen well away from the mediastinum in the lung fields, which show transmitted pulsation from the aorta or left ventricle. This sign was present in six of our cases. It has been encountered in no other condition and we have never seen it in any kymograph taken after ligation of the ductus.

Vibration waves. These occupy a narrow region immediately below the aortic waves and blend farther down with the pulmonary artery waves. They are shown in Fig. 3 in which (A) shows the whole kymograph and (B) a magnification of the encircled zone in (A). The fine fibrillation waves of a frequency of approximately 400 a minute are seen at the centre of the magnified zone. Careful scrutiny is often required to detect these waves, by the naked eye in the kymograph. The reproduction in Fig. 4 shows ill-defined vibration waves, but the accompanying drawing made from the film by tracing the outline of the waves from the film, placed over a horizontal viewing box, illustrates them and their


position. Fig. 5 shows a kymograph taken in the left anterior oblique position. The vibration waves are seen in the magnified section on the border of the ascending part of the arch of the aorta, a position that is surprising in view of the comparative remoteness from the ductus region. However, it is difficult to assign any other interpretation to these waves, which have been encountered on several occasions in left oblique films.

It is suggested that vibration waves constitute a visual radiological counterpart of the palpable clinical thrill, and that they are caused by the vibration of the ductus and the adjacent parts of the aorta and pulmonary artery. In some of our earlier kymographs, the zone of fine wave-forms was not well seen. This was due in part to the inherent difficulties of radiography in young children. With increased experience of the method and the subject better results were obtained and we have found the zone of fine wave forms to be a frequent feature of the kymograph in patent ductus arteriosus, being present in 12 of our 16 cases. Moreover, in kymographs taken after operative cure of the condition these special wave forms are no longer seen.

Exaggerated pulmonary artery waves. These are



A



B

FIG. 2.—Boy, aged 6. Patent ductus arteriosus. (A) Kymograph showing para-aortic waves. (B) Tracing of the kymograph: para-aortic waves shaded.

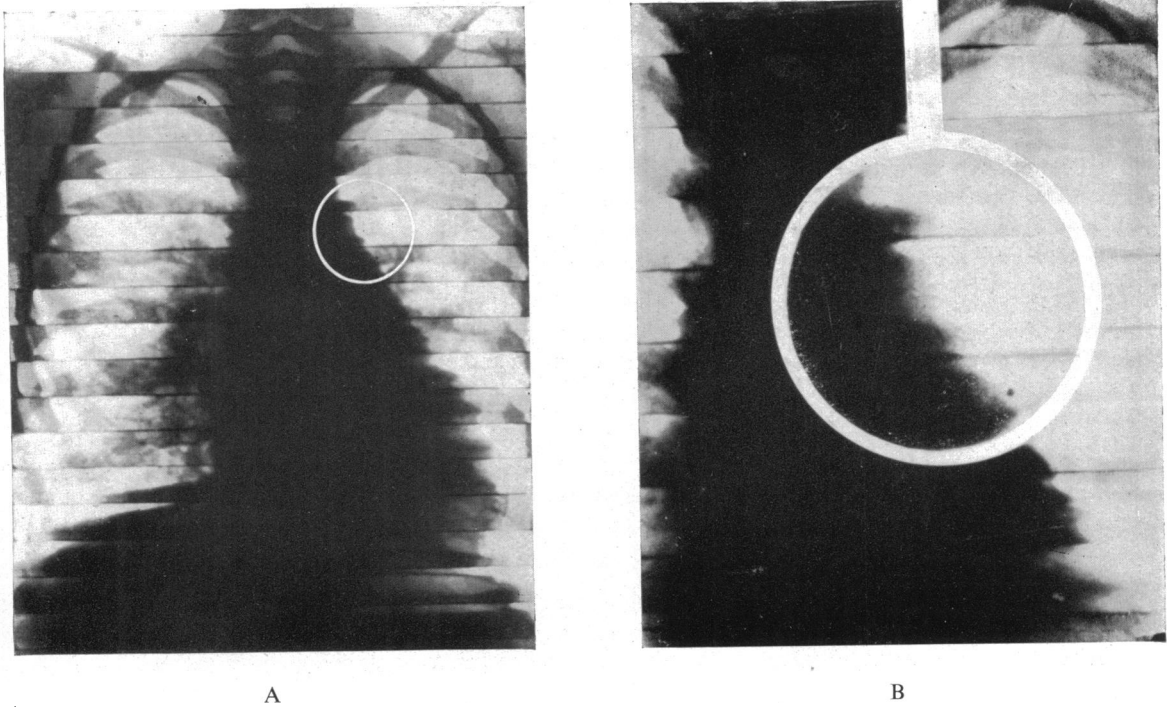


FIG. 3.—Girl, aged 6. Patent ductus arteriosus. (A) Kymograph. (B) Magnification of encircled zone in (A) to show vibration waves.

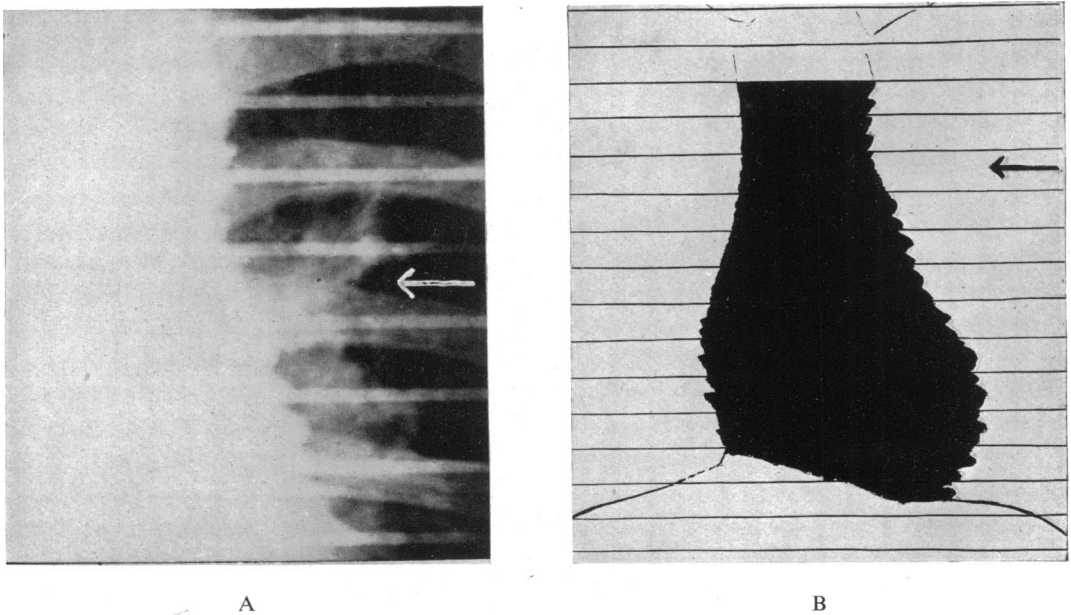


FIG. 4.—Boy, aged 13. Patent ductus arteriosus. (A) Portion of kymograph showing ill-defined vibration waves. (B) Tracing of the whole kymograph to illustrate position (arrow).

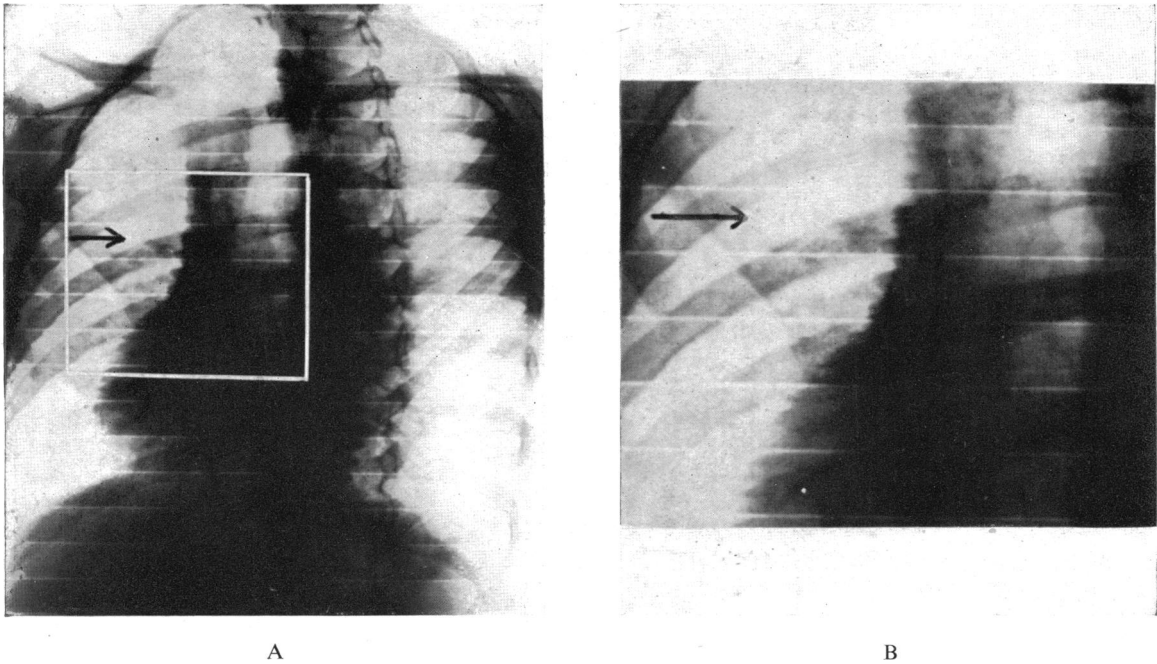


FIG. 5.—Girl, aged 7. Patent ductus arteriosus. (A) Kymograph in left anterior oblique position. (B) Oblong marked area magnified to show vibration waves on border of shadow of ascending part of arch of aorta (arrow).

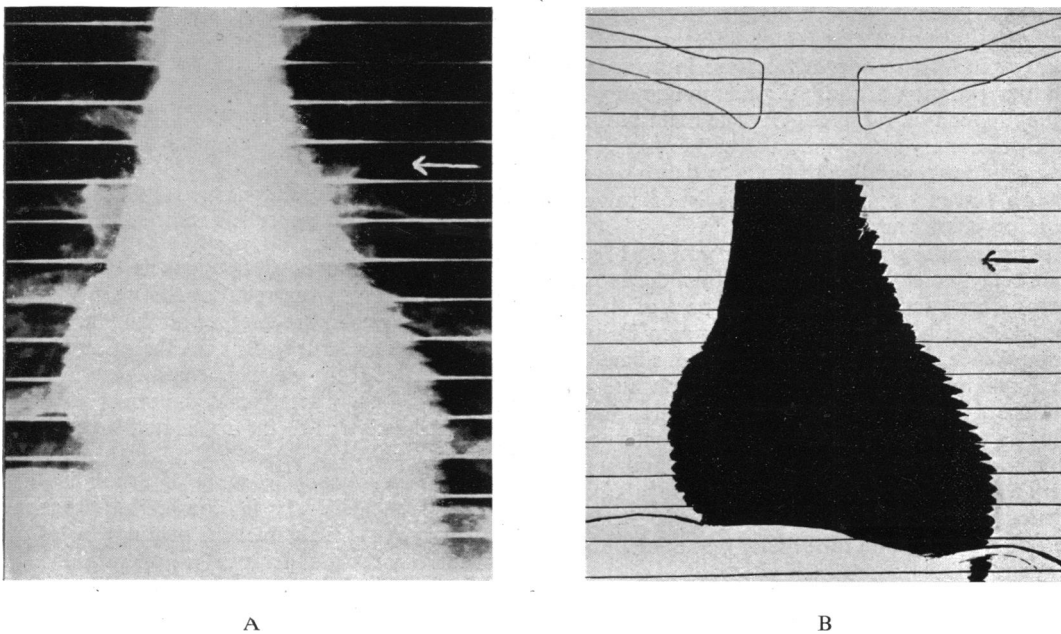


FIG. 6.—Woman, aged 30. Patent ductus arteriosus. (A) Kymograph showing slightly convex pulmonary arc with exaggerated waves. (B) Tracing of kymograph to illustrate.

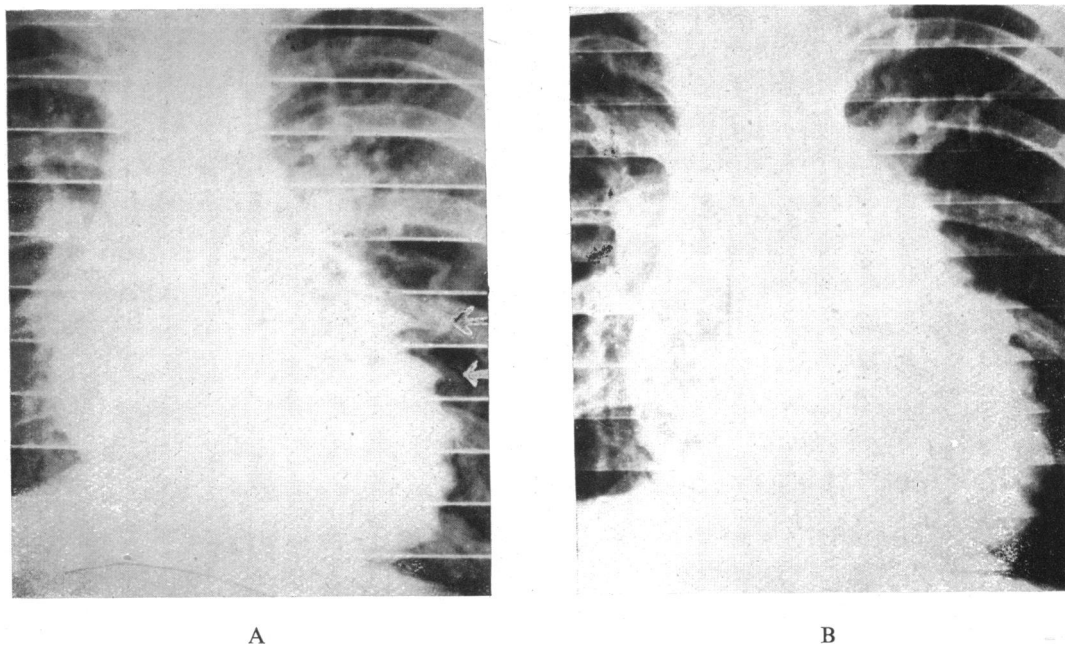


FIG. 7.—Boy, aged 7. Patent ductus arteriosus. (A) Kymograph showing exaggerated upper left ventricular waves. (B) Kymograph of same patient after operation showing disappearance of the abnormally large waves.

shown in Fig. 6A in which the pulmonary arc is slightly convex. The accompanying drawing (Fig. 6B) illustrates the essential features of the kymograph. These appearances are in accordance with the prominent and pulsatile pulmonary arc frequently seen on radioscopy. The main branches of the pulmonary artery may also show exaggerated movement corresponding to the hilar dance so often seen on screen examination; this is of value in excluding pulmonary stenosis.

Exaggerated upper left ventricular waves. Fig. 7A shows very conspicuous wave forms due to the vigorous contraction of the upper part of the left ventricle. Such exaggeration is also seen in aortic incompetence. This is not surprising since both conditions involve a leak from the aorta and may therefore be expected to produce similar hæmodynamic disorders. After closure of the communication between the aorta and the pulmonary artery by ligation of the ductus, these abnormal ventricular contractions disappear, as is shown in Fig. 7B, a kymograph taken after operation.

SUMMARY

Radiokymography has been applied to the diagnosis of patent ductus arteriosus. The series here presented comprises sixteen patients proved at

operation to have this congenital defect. The following four kymographic signs are described.

- (1) Para-aortic waves lying parallel to and lateral to the aortic zone.
- (2) Vibration waves situated immediately below the aortic zone and between this and the pulmonary zone.
- (3) Exaggerated pulmonary artery waves.
- (4) Exaggerated upper left ventricular waves.

The production of these signs is discussed and reasons are given for relating the para-aortic and vibration waves to the ductus and the vibration in it and in adjacent structures. On the other hand, the amplification of the waves normally seen in relation to the pulmonary artery and the upper part of the left ventricle is due to the associated hæmodynamic disorder.

Reference is made to some of the difficulties in clinical diagnosis. It is considered that radiokymography is valuable in helping to establish conclusively the diagnosis before operation.

We wish to thank our surgical colleagues at the London Chest Hospital, especially Mr. T. Holmes Sellors, for their co-operation and help with the surgical data relating to the patients.

REFERENCES

- Bordet, E., and Fischgold, H. (1937). *La Radiokymographie du Coeur*, Paris.
- Brown, J. W. (1939). *Congenital Heart Disease*, London.
- Faber, B., and Kjaergaard, H. (1936). *Brit. J. Radiol.*, **9**, 235.
- Gött, T., and Rosenthal, J. (1912). *Münch. med. Wschr.*, **38**, 2033.
- Stümpf, P. (1934). *Brit. J. Radiol.*, **7**, 707.
- , Weber, H. H., and Weltz, G. A. (1936). *Roentgenkymographische Bewegungslehre*, Leipzig.
- Taussig, H. B. (1937). *Congenital Malformation of the Heart*, New York.
- Wood, F. G. (1939). *Lancet*, **1**, 249.