

THE EARLY DIAGNOSIS OF PHEOCHROMOCYTOMA

BY

LESLIE COLE

From Addenbrook's Hospital, Cambridge

Received October 21, 1949

It is now well known that tumours of the adrenal medulla are a cause of paroxysmal hypertension. It is less generally recognized that these attacks may only occur late or not at all. When this is so, if the risk of surgical treatment is to be reduced to a minimum, diagnosis should be made in the early stages when paroxysmal symptoms are absent and hypertension, if present, closely resembles the benign or malignant form. The first paroxysm may be the last because after it has occurred the patient may be too ill for operation. This paper describes the clinical features of such a patient from the early stages and serves as a basis for discussion of some of the difficulties of diagnosis.

Patients with pheochromocytoma may present in various ways.

(1) With recurrent attacks of paroxysmal hypertension and vasomotor instability, with or without sustained hypertension between attacks.

(2) Without paroxysms with sustained hypertension resembling benign or malignant hypertension.

(3) In extremis, from some cardiovascular accident when previous symptoms have not been severe enough to lead them to consult a doctor.

(4) Simulating Addison's disease from local pressure on the adrenal cortex (Mackeith, 1944).

The classical picture of the adrenal sympathetic syndrome is too well known to need description here. It is characterized by periodic attacks of paroxysmal hypertension with palpitation, anxiety, shakiness, headache, vomiting and vasomotor phenomena. Transient glycosuria may also be present. The similarity of this picture to that produced by the injection of a large dose of adrenalin is evident.

It is less generally known that pheochromocytoma may produce a picture without paroxysms, closely resembling benign or malignant hypertension, but this had been pointed out by many writers (Binger and Craig, 1938; Thorn, Hindle, and Sandmeyer, 1944; Palmer and Castleman, 1938; McCullagh and Engel, 1942; and Mackeith, 1944). That persistent hypertension is a good deal commoner than has been realized, is suggested by Green (1946) who in a recent review of 51 cases of pheochromocytoma found that only 14 showed intermittent hypertension, while 37 had chronic hypertension. Smithwick's (1946) series of 1000 hypertensive patients subjected to lumbo-dorsal sympathectomy showed an incidence of pheochromocytoma of 0.05 per cent. There is thus considerable evidence to show that sustained hypertension of the benign or malignant type may be due to pheochromocytoma, and it is clear that if the diagnosis is to be made earlier and more frequently, it must be considered as a possible cause in every case until it has been excluded. Soffer (1946) has pointed out that success depends first and foremost on the index of suspicion of the physician. Put more simply, he must think of the possibility in every case of hypertension.

Cases that are first seen in extremis after some cardiovascular accident (Hick, 1933) bear evidence to the fact that paroxysms of hypertension are dangerous and may be fatal and that diagnosis should, if possible, be made before they occur. The case described in this paper is an example of this.

CASE REPORT

A married woman, aged 35, who had been previously healthy was admitted to Addenbrooke's Hospital in October 1946 under Dr. J. R. C. Canney for a severe ante-partem hæmorrhage. Her pregnancy had been uneventful up to this time and her blood pressure normal throughout.

Previously she had always been healthy and active, leading an energetic life as a farmer's wife. She had three children alive and well, aged 8, 5, and 3, and her previous confinements had been without incident. Her husband was healthy and the family history did not reveal any tendency to raised blood pressure, or heart, kidney, or other relevant disease.

On admission she was very anæmic and shocked but no other abnormalities were found, and after a transfusion a stillborn child of 30 weeks was delivered by Cæsarean section. A few days later she developed a slight thrombosis in the left leg but she was discharged apparently well on October 29th, fifteen days after her hæmorrhage.

On November 2nd, in the evening, while she was sitting up in bed, she suddenly developed frontal headache and this persisted. I saw her for the first time on November 5th. She was then complaining of dull continuous headache, frontal and mainly on the right side but spreading over to the left at times. It was worse in the early morning and was accentuated by movement. On examination, there was slight œdema of the left ankle, but there were no other abnormalities. Blood pressure, 130/90; pulse rate, 84; and fundi normal.

During the next four months her general condition improved and she was moderately active, but her headaches continued to trouble her until February 1947 when they cleared up. She remained practically free from symptoms until April, when they returned and continued as before. In July, because they were rather worse, she was readmitted to hospital for investigation.

The headaches were still frontal, sometimes on one side, sometimes on the other. They were worse in the early morning, passed off about noon, and often came back in the evening. They were made worse by effort or movement but nothing else seemed to affect them. She said that at times she used to become very shaky, especially if anything worried her, and attributed this to the shock of the operation (for she had never been ill before) and the fact that she had had a good deal of worry the previous summer. She had no other symptoms.

On examination, her blood pressure was 180/120–130, in both arms. This was taken on many occasions at different times of the day and in different postures and hardly varied. Slight œdema of the left leg was still present. Her urine occasionally contained a trace of albumen, but this was not constant. Clinical examination revealed nothing otherwise; she had no fever and her pulse rate remained between 80 and 90, hardly varying with mild effort. Special investigation only showed a slight *B. coli* bacilluria and a very slight dilatation of the pelvis of the right kidney, which was not considered significant.

The hypertension was thought to be benign and did not seem to be enough to account for her headache, which was the outstanding symptom; and it seemed likely from her general nervousness that there was a considerable functional element present. She was given a course of sulphamezathine for her *B. coli* bacilluria.

During the next three months her headaches persisted except for a three-weeks remission while she was on holiday in August. They maintained the same character and rhythm but grew more severe. In September she began to suffer from short early morning nausea and her appetite began to fail and in October she was readmitted. She said then that her head did not throb but felt at times as if someone were sticking knives into her forehead. She began to retch occasionally. At times she had "peculiar sensations," during which she felt worked up and excited, and on these occasions she looked tremulous and anxious. At times she seemed to be in a state of repressed excitement and shaking like a patient with exophthalmic goitre but without thyrotoxicosis. As vomiting became more frequent her nutrition and general condition began to deteriorate for the first time. During October her blood pressure taken on many occasions varied between 180/120 and 175/115 and her pulse rate was steady between 70 and 80. Clinical examination was otherwise normal and the following special investigations did not help.

Examination of her pelvis, eyes (fundus, visual fields and refraction), ears, nose, and throat, and renal function, were all normal. Blood urea 17 and 28 mg. Urea clearance 90 per cent. Full blood count normal. Sedimentation rate (Westergren) 17 mm. Wassermann and Kahn reactions negative. X-rays of her skull, cervical spine, nasal sinuses, and lungs, all normal. Cardioscopy slight ventricular hypertrophy and slight uncoiling of the aorta. Electrocardiogram, left axis deviation only. The urinary deposit showed epithelial cells only and no albumen or sugar. The cerebrospinal fluid was under pressure (400/350 mm.) but was otherwise normal, and the Wassermann reaction was negative.

On October 31st she was discharged home at her own request pending transfer to a cerebral unit, where her condition remained the same until November 9th. On that afternoon she had some kind of fit, a sudden attack of headache, vomiting, and intense excitement, and her doctor found that her blood pressure rose temporarily to 240/160—a typical paroxysm of hypertension. The same afternoon, her headache dramatically disappeared, she stopped vomiting, and was able to take more food. On the morning of the 10th, her blood pressure had fallen to 170/110 and in the afternoon she was suddenly seized with a very severe pain in the right renal region which did not radiate and only gradually eased. On the 11th the pain was still present and much less severe but her abdomen was slightly distended. Her bowels had not been open since the onset of the pain but she had passed flatus. An acute abdominal condition was suspected and she was readmitted to hospital.

On admission, she was anxious and excited with slight tremor of the hands. Her hands and feet were cold and she sweated profusely at times. Temperature, 101; pulse rate, 110; respiration rate, 20. She looked a little dehydrated. Her headache and vomiting had stopped. The abdomen was slightly distended and there was marked tenderness in the right renal angle and over the right side, but no true rigidity. Vigorous peristalsis was audible and she passed flatus. Rectal examination was normal. The blood pressure was 180/130. The urine contained a heavy cloud of albumen. Microscopically there was no deposit and no other abnormalities were found. Enemas yielded very little result. The next morning her general condition was unchanged. Blood count showed a leucocytosis of 29,000 with 89 per cent polymorphs. During the day her abdomen became more distended and she was seen in consultation with Mr. P. H. R. Ghey. In view of the progressive distension it was thought that she might have general peritonitis with paralytic ileus or subacute obstruction and laparotomy was performed.

No evidence of peritonitis or obstruction was found. The whole of the large and small bowel was distended with gas and the cæcum was enormous. There were a few hard faecal masses at the hepatic flexure. A round solid tumour about 3 inches in diameter was felt in the region of the left suprarenal which seemed rather fixed. As her general condition was rather poor it was considered inadvisable to attempt to remove this until the ileus had been controlled, so cæcostomy was performed and a de Pezzer catheter inserted.

During the next six days she was given eucortone and glucose saline, plasma or normal saline intravenously at the rate of 4 pints a day, and every effort was made to improve her general condition. This hope was not realized and as it threatened to deteriorate, Mr. Ghey performed a second operation on November 17th. A tumour which subsequently proved to be a typical pheochromocytoma was removed from the site of the left suprarenal gland. Section of the last blood vessels to the tumour was followed by a sudden profound fall in blood pressure. In anticipation of this, an intravenous adrenalin drip (1 : 10,000) which had previously been connected, was turned on at once, but without effect and death took place a few minutes later.

POST-MORTEM REPORT

The following are extracts from the full post-mortem report for which I am indebted to Dr. A. M. Barrett.

Left suprarenal. Thin triangular remnant (sides 3, 2, and 2 cm.) of suprarenal tissue consisting

of two thin layers of yellow cortex without any visible medulla at site of otherwise absent left suprarenal. Considerable enlargement of ligatured and divided left suprarenal blood vessels.

Microscopic sections were normal.

Suprarenal tumour. (Fig. 1.) Ovoid tumour (9.5×7.5×5.7 cm.) enclosed with thin capsule.

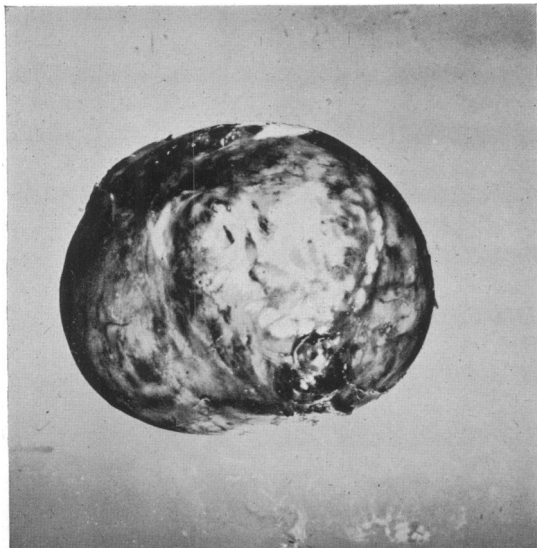


FIG. 1.—Photograph of the suprarenal tumour. The measurements were 9.5×7.5×5.7 cm. and the weight 227 g.

Wt. 227 g. Near one pole a slightly raised yellow ridge (4×0.3 cm. wide) apparently consisting of suprarenal cortex; small yellow islands are also present here and there elsewhere on the pale grey-brown outer surface. The consistency of the tumour is soft, almost cystic, with dull purplish areas as of hæmorrhage which show through the capsule here and there. The predominant colour of the bulging cut surface is a rich purple-red, but on closer inspection it is seen that there are everywhere close-set purple dots and streaks (about 0.1 cm. diameter) set in a greyish white ground.

Microscopical section. (Fig. 2.) This shows chromaffin tumour of suprarenal medulla, with numerous blood spaces devoid of any lining and also areas of hæmorrhage with necrotic tumour cells.

Right suprarenal. Weight, 9 g. Abundant yellow lipoid, very scanty brown pigment, and normal grey-white medulla in rather large gland. Microscopic sections normal.

Cardiovascular system. Heart weight, 36 g. Moderate hypertrophy of firm, brown-red myo-

cardium of contracted left ventricle (L.V. : R.V., 2.5 : 0.5). No hypertrophy of the rest of the heart. Pale brown ante-mortem thrombosis for the most part only lightly adherent, but in one

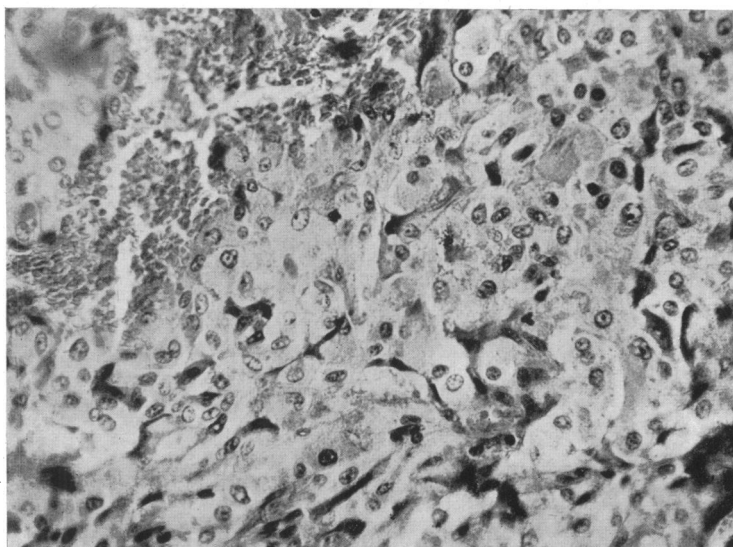


FIG. 2.—Photomicrograph, showing the histological appearances of the tumour.

place apparently merging with the underlying muscle lining the apex of left ventricle. Moderate atheroma without narrowing in the coronary arteries. Slight to moderate atheroma of normal-sized aorta. Thrombosis of right and left posterior tibial veins and of left femoral vein.

On section the mural thrombosis was shown to have formed ante-mortem.

Respiratory system. About a dozen fragments of ante-mortem clot impacted in branches of the pulmonary arteries in both lungs. The emboli were about 1 cm. in diameter. Altogether they must have caused considerable reduction in the arterial "bed" of the lungs.

Urogenital system. Many yellow-white areas of infarction in the right kidney apparently involving altogether about half its substance. On the outer surface the infarcted areas were neither raised nor sunken. Scanty fibrinous exudate on the outside of the capsule of the right kidney. This embolus satisfactorily accounted for the largest area of infarction, but there were many other smaller areas. Slight dilatation of right renal pelvis. No infarction of well developed left kidney.

On section, infarction with fibrinoid degeneration of afferent glomerular arterioles and other abnormalities of glomerular tufts which are probably related to it.

Special investigations. The chromaffin reaction (Schmorl) was positive.

The test for adrenalin by Craner's method was very suggestive of the presence of much adrenalin. The test by Masson's method showed that argentaffin cells appeared to be present.

DISCUSSION

When paroxysmal hypertension is absent a tentative diagnosis of pheochromocytoma would appear to depend more on careful consideration of the symptoms found in association with hypertension than on the physical signs, which are not distinctive unless the tumour is palpable.

The syndrome presented by this patient was quite different from any I had seen before, and during the three months before her attack of paroxysmal hypertension presented a clinical picture that once seen could not be forgotten or pass unrecognized again. It is, therefore, worth studying her symptoms and signs in detail.

The unusual clinical features in the early stages appeared to be as follows: the sudden onset of headache preceding the rise in blood pressure, the periodicity of the headache in the early morning and evening, the "peculiar sensations" in the upper abdomen with sinking feelings, turmoil, and excitement, and the slow but steady increase in the intensity of the symptoms without any corresponding rise in blood pressure.

In the later stages the unusual features were the severity of the headache, out of all proportion to the blood pressure, and its character—"like knives being driven into the head"—and the attacks of sweating and cold hands and feet.

It is also worth noting that this syndrome developed in a patient who had been particularly well balanced mentally and physically in the past, and had never previously had a headache in her life, and was without any obvious hereditary or environmental causes for her symptoms.

Further special investigations that might have been done to establish the diagnosis earlier may conveniently be considered under the three following headings.

(1) *Tests that suggest hypersecretion of adrenalin.* Attempts to demonstrate the presence of a pressor substance in the blood have only occasionally been successful, are difficult to perform, and cannot be relied on. Beer, King, and Prinzmetal (1937), by perfusing a denervated rabbit's ear with blood obtained from a patient during an induced paroxysm, were able to demonstrate the presence of such an active principle. Because of the great practical difficulties that attend this method, it cannot often be applied clinically.

Paroxysms can sometimes be induced deliberately, but this is not devoid of risk. Massage or manipulation of the tumour by change of posture sometimes bring on an attack and indirectly give a clue to its site. Starvation for from 12 to 24 hours may induce one (Soffer, 1946), or the injection of adrenalin (Mackeith, 1944). Since the greatest difficulties in diagnosis occur in patients in whom

the existence and site of the tumour are not known, the injection of adrenalin is the easiest, but because of its risk is perhaps better avoided.

Shortly after this patient died, Goldenberg (1947) described a simple test for hypertension caused by excess circulating adrenalin and claimed to have established its value in the diagnosis of pheochromocytoma. Briefly, the test consists in perfusing the patient with benzodioxanes (1164F or 933 F) which given in the appropriate dose are adrenolytic in action and block sympathetic activity. He found that in patients with pheochromocytomas or with hypertension induced by perfusion with adrenalin, blood pressure readings taken over a period of 15 minutes after the injection showed a characteristic fall that was in contrast to the rise obtained in those with malignant or essential hypertension. Smithwick (1948) confirmed the diagnostic value of this test and if further observations confirm Goldenberg's findings, it should be of great benefit in helping to diagnose difficult cases of pheochromocytoma in the early stages. It is clearly easier to localize the tumour when there is strong evidence that it is present than when its existence is still in doubt.

Another test for pheochromocytoma is by intravenous injection of histamine. It is claimed that this is followed immediately by a rise in blood pressure in contrast to the usual fall obtained in normal people. Roth and Kuale (1945) suggest that this test is specific for the condition.

(2) *Localization of the tumour.* This may be easy or it may be very difficult. It may be palpable or only observable by exploration and may be found by accident in the course of operation for lumbo-dorsal sympathectomy in hypertension or as in the present case for some complication. It is noteworthy that in the patient described here, while all the signs and symptoms pointed to the right side, the pheochromocytoma was on the left. It should also be remembered that bilateral tumours may occur (Reid and Salm, 1949). If the tumour is not palpable, radiological investigation of the kidneys is the procedure most likely to yield definite evidence. Howard and Barker (1937) estimated that an intravenous pyelogram would have suggested the presence of the tumour in 11 of these 18 cases. If this measure fails a retrograde pyelogram or even perirenal insufflations with oxygen have proved invaluable (Soffer, 1946). It is important, too, to remember that the position of these tumours in the abdomen is very varied. They may also be located in the neck and even in the chest, but do not appear to be active in these situations (Phillips, 1940). Diagnostic procedures should be as innocuous as possible because these patients stand manipulation badly. This makes it all the more desirable that the tumour should be located early and accurately.

(3) *Other investigations.* The basal metabolic rate perhaps comes next in order of importance for this is often above 20 per cent (Binger, 1938, and McCullagh, 1942) and indeed the differential diagnosis from hyperthyroidism may be very difficult and has often led to confusion. This is not surprising, for the clinical resemblance between excessive secretion of adrenalin, chronic anxiety, and hyperthyroidism may be very close. Mistakes will be less likely to occur if this resemblance is remembered in typical cases of hyperthyroidism coupled with the fact that the B.M.R. is often raised in pheochromocytoma.

Other investigations are useful chiefly for excluding intercurrent disease and for demonstrating changes that occur in hypertension from any cause but are not specific for pheochromocytoma. Thus cardiographic studies may show changes associated with hypertension; cardioscopy, general cardiac enlargement, and left ventricular hypertrophy; and renal function tests, a greater or lesser degree of impairment but nothing diagnostic.

Glycosuria and a raised blood sugar have been found occasionally and although the association of these with excessive secretion of adrenalin is clear, they do not occur frequently enough to be of much value in diagnosis. Pheochromocytoma has also been found with frank diabetes mellitus (McCullagh, 1942). Retinal changes do not differ from those found in benign or malignant hypertension. Blood counts do not show any significant change. The high pressure in the cerebro-spinal fluid found in this patient has also been recorded in another (Palmer, 1938) but might well occur in hypertension from any other cause. If for any reason lumbar puncture is considered advisable, the risk of its provoking a paroxysm must be remembered, and the blood pressure and general condition carefully measured both before and after.

SUMMARY

The symptoms in a patient with sustained hypertension due to pheochromocytoma are described in detail. The diagnosis is discussed and the importance of early diagnosis is emphasized.

The author wishes to thank Dr. A. M. Barrett for the post-mortem report and Mr. H. P. Hudson for the photograph and photomicrograph.

REFERENCES

- Beer, E., King, F. H., and Prinzmetal, M. (1937). *Ann. Surg.*, **106**, 85.
Binger, M. W., and Craig, W. McK. (1938). *Proc. Staff. Meet., Mayo Clin.*, **13**, 17.
Goldenberg, M., Snyder, C. H., and Aranow, H. (1947). *J. Amer. med. Assoc.*, **135**, 971.
Green, D. M. (1946). *Ibid.*, **131**, 1260.
Hick, F. K. (1933). *Arch. Path.*, **15**, 665.
Howard, J. E., and Barker, W. H. (1937). *Bull. Johns Hopkins Hosp.*, **61**, 371.
Mackeith, R. (1944). *Brit. Heart J.*, **6**, 1.
McCullagh, E. P., and Engel, W. J. (1942). *Ann. Surg.*, **116**, 61.
Palmer, R. S., and Castleman, B. (1938). *New England J. Med.*, **219**, 793.
Phillips, B. (1940). *Arch. Path.*, **30**, 916.
Platt, R. (1947). *Quart. J. Med., N.S.*, **16**, 111.
Reid, T. M., and Salm, R. (1949). *Brit. med. J.*, **1**, 1116.
Roth, G. M., and Kuale, W. F. (1945). *Amer. J. Sci.*, **210**, 653.
Smithwick, R. H. (1946). Personal communication quoted by Goldenberg (1947). *J. Amer. med. Assoc.*, **135**, 971.
—, (1948). Lecture at Cambridge.
Soffer, Louis J. (1946). *Diseases of the Adrenals*, (Henry Kimpton), **X**, 273.
Thorn, G. W., Hindle, J. A., and Sandmeyer, J. A. (1944). *Ann. intern. Med.*, **21**, 122.