

# A COMPLICATION FOLLOWING CORONARY SINUS AND CARDIAC VEIN CATHETERIZATION IN MAN

BY

J. McMICHAEL and J. P. D. MOUNSEY

*From the Department of Medicine, Postgraduate Medical School of London*

Received June 1, 1951

Right auricular catheterization in man is a safe and simple procedure, but the introduction of the catheter into the right ventricle and pulmonary artery is often technically more difficult and introduces new risks. Most of these can be avoided if their existence is recognized. The unrecognized entry of the catheter into a cardiac vein either via the coronary sinus or even directly from the right atrium constitutes one of these risks. In a total of approximately 300 right heart catheterizations at this hospital during the past two years, in which the prime object was to enter the right ventricle or pulmonary artery, there have been five such complications. A preliminary report on three of these cases, tentatively labelled "coronary thrombosis" has already been made by Zimdahl (1951). In all cases Cournand catheters were passed through the median basilic vein and directed under fluoroscopic control. A continuous slow infusion of heparanized 5 per cent glucose was maintained through the catheter.

## CASE REPORTS

*Case 1.* A 69-year-old woman, suffering from chronic bronchitis and emphysema was catheterized for assessment of her cardiac condition. No pre-medication was given. A size 9F catheter was used. After leaving the right atrium the catheter was seen in the antero-posterior view to pass diagonally across the heart to "the pulmonary outflow tract." Four unsuccessful attempts were made in this position to advance the tip further into the pulmonary artery, but each time the tip advanced diagonally and was arrested at the left border of the cardiac silhouette. The patient later admitted that she had had substernal pain going through to the back in the interscapular region at this time. Pressure recordings were low and a blood sample aspirated appeared to have a very low oxygen saturation on immediate inspection. It was then suspected that the catheter was in the coronary sinus and this was confirmed on turning the patient into the left oblique position where the catheter was seen to be lying at the posterior border of the heart. The patient now complained for the first time of pain and exhaustion. The catheter was withdrawn. She became cold and cyanosed, sweated profusely, and nausea was soon followed by vomiting. The pulse became feeble, the systolic blood pressure being 80 mm., but the rate was unchanged at 80-90 a minute. The jugular venous pressure rose slightly to 2 cm. above the sternal angle. She was immediately returned to the ward where she was given morphia and oxygen therapy and slow digitalization was begun. An electrocardiogram a few hours later showed no significant change since admission.

Over the next five days she gradually improved, the blood pressure rising to 120/70 mm. after twenty-four hours. The pain persisted for five days, although gradually diminishing in intensity. Referred pain in the back was a predominant feature in this case. During the first three days a transient pyrexia up to 100° F. was seen. On the fifth day the patient was found to have auricular fibrillation and this rhythm change persisted for twenty-four hours, after which sinus rhythm returned. The erythrocyte sedimentation rate rose during the first week to 27 mm. in one hour (Westergren), returning to normal after a further week. There was no significant change in total white cell count.

Serial electrocardiograms during the first five days (Fig. 1) showed progressive changes with S-T elevation and T wave inversion in V5, VF, and III without pathological Q waves. These were interpreted as indicating

postero-lateral myocardial ischæmia. Recovery was complete by the tenth day, but the patient was left with persistent tinnitus and giddiness, probably due to the prolonged low blood-pressure state.

*Case 2.* A 59-year-old woman, suffering from pulmonary fibrosis of obscure ætiology, was catheterized for further assessment of a difficult diagnostic problem. She was given 3 grains of sodium amytal orally as premedication. The catheter was introduced easily and passed from the right atrium "to the pulmonary outflow tract." On reaching the left border of the cardiac silhouette in this position, the tip was seen to curve downwards again for a short distance. Screening in the antero-posterior position only was used to locate the catheter. The patient then complained of pain in the back between the shoulder blades and was noticed to have a cardiac irregularity. The catheter was at once withdrawn and 100 mg. of procaine hydrochloride in 1 per cent solution given intravenously. Her condition now gave cause for alarm. The peripheral pulse was unobtainable, but the apical rate was 80 and regular. She was cold and cyanosed and unable to comprehend and answer questions. On return to the ward continuous oxygen was given by BLB mask

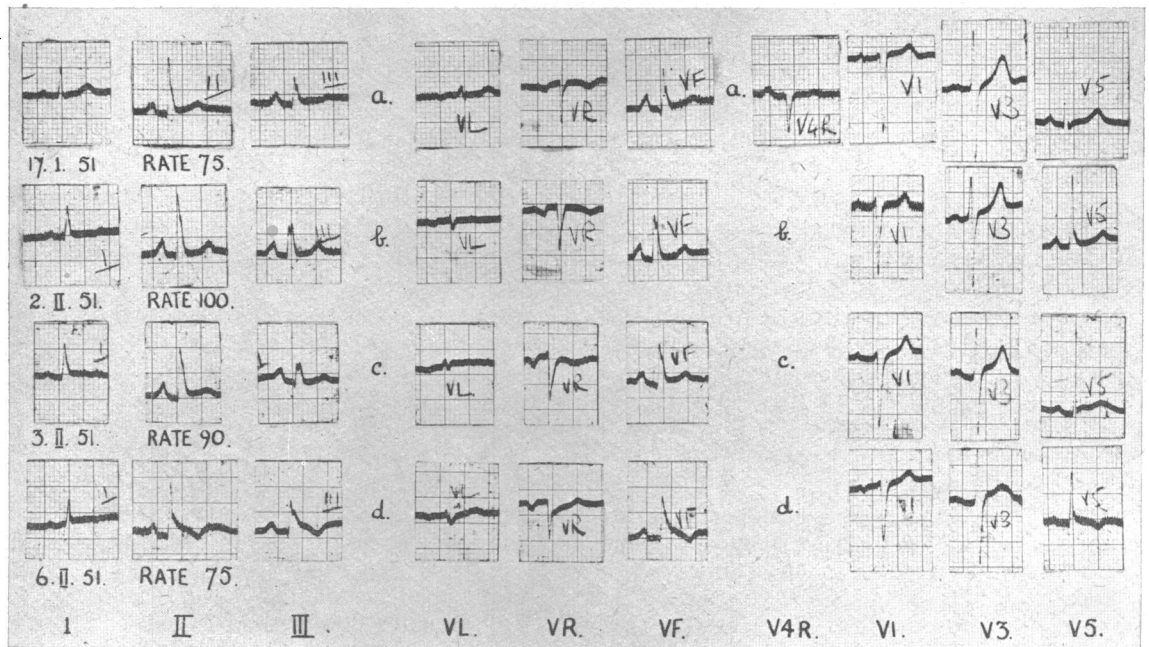


FIG. 1.—Case 1. (a) Control cardiogram before catheterization. (b) 2 hours after catheterization. No change beyond increase in heart rate and flat T wave in I, VL. (c) Slight S-T segment elevation and flattening of T wave in II, VF, V5. (d) Marked S-T segment elevation in II, III, VF, V3, V5 with T-wave inversion in II, III, VF, V5. Postero-lateral myocardial ischæmia.

and her condition improved after twenty minutes sufficiently to enable her to speak, when she complained of persistence of interscapular and sternal pain without radiation elsewhere.

Routine treatment for shock was given, and in view of vomiting a rectal glucose drip was set up. The following day her blood pressure level had improved, rising to 100/70 mm. The pulse remained of normal rate and regular. The jugular venous pressure was now noted to have risen to 2 cm. above the sternal angle. There was also a slight rise in temperature to 99.5° F., which persisted for five days.

Electrocardiograms (Fig. 2) were taken three hours after catheterization and also three days later. The first tracing showed no change beyond a decrease in voltage but the second gave evidence of pericarditis.

The patient continued to complain of interscapular and sternal pain at this time, but no pericardial rub or evidence of pericardial effusion was detected, although signs of these were constantly sought for. The subsequent course in this patient was uneventful and recovery was complete by the tenth day.

*Case 3.* A 66-year-old man, suffering from Paget's disease, with some question of ischæmic heart disease, was catheterized. No premedication was given. The patient appeared quiet and not apprehensive. After entering the right atrium attempts were made to advance the catheter into the right ventricle, but

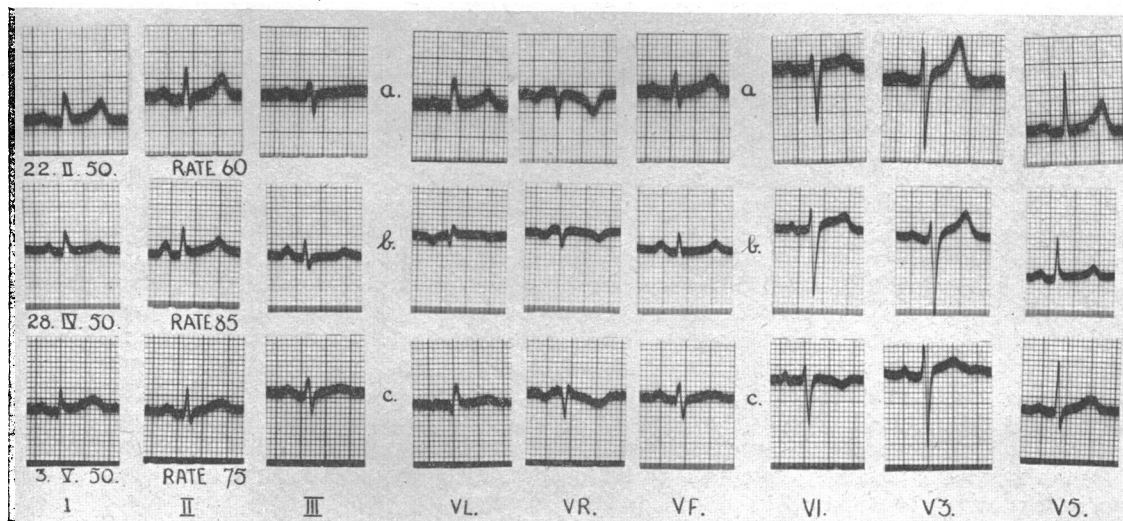


FIG. 2.—Case 2. (a) Control cardiogram before catheterization. (b) 1 hour after catheterization. No change beyond low voltage and slight increase in heart rate. (c) Slight S-T segment elevation and coving in I, II, III, V3, V5 with T wave inversion in V1; suggestive of pericarditis.

each time this manœuvre was attempted the catheter was seen in the antero-posterior view to be passing into the coronary sinus. Once on reaching the left border of the cardiac shadow the tip of the catheter curved downwards for a short distance, an event exactly parallel what was seen in Case 2. The patient at once complained of pain in the chest, substernal radiating through to the back and up to the back of the neck into the ears and occiput. It was noted at this time that the pulse was irregular and the catheter was immediately withdrawn. Following this the pain persisted, but the pulse became regular again, remaining at a normal rate of 80–90 a minute. The sequence of events during the next three hours was complicated by the development of a rigor.

No major fall of blood pressure occurred at any time in this case and there was no nausea nor vomiting. He was free from pain when lying still in bed on the following day, but complained of mild upper sternal pain when up in the ward. The temperature was raised to 99° F. for three days. The electrocardiogram showed no significant change. Recovery was complete by the third day.

*Case 4.* A 54-year-old woman suffering from benign hypertension was catheterized for study of the hæmodynamic effects of hexamethonium therapy. No premedication was given. A size 7F catheter was used. After leaving the right atrium the catheter appeared to pass easily into the lower portion of the right ventricle, its course running parallel and close to the inferior border of the cardiac silhouette as seen in the antero-posterior position. On reaching the apex of the heart the tip curved upwards for a short distance. The patient then complained of slight substernal discomfort and the catheter was withdrawn about five centimetres. The pain going off, the catheter was again advanced. The pressure was now measured and found to be low. It was therefore suspected that the catheter lay in the coronary sinus and an attempt was made to withdraw a blood sample to confirm this. A few ml. of slightly blood-stained fluid were withdrawn and similar amounts came back into the syringe on repeated aspirations. In view of this finding it was considered that the catheter had possibly perforated a vein and lay not in the coronary sinus but in the pericardium into which fluid had been flowing from the manometer reservoir. The catheter was now withdrawn and the patient began to complain of increasing substernal pain radiating to the neck and jaws. The pulse did not rise, remaining at 80–90 a minute, but the blood pressure fell immediately from 190/110 to 110/70 mm. There was no nausea and no peripheral signs of collapse.

On return to the ward the patient's general condition was quite good. The jugular venous pressure was found to be 1 cm. above the sternal angle. There were no clinical signs of pericarditis and a cardiogram taken immediately was normal as was a chest X-ray the following day. The pain persisted for three days, gradually diminishing. The blood pressure returned to 150/85 mm. after twenty-four hours. Serial cardiograms during the next three days showed no significant change and the temperature, total white cell

count, and erythrocyte sedimentation rate did not rise. Recovery was complete by the third day except for transient slight attacks of præcordial pain during the next two weeks.

The exact course of the catheter in this case remains in doubt. It is probable that it entered the pericardium through a cardiac vein. Its course, as watched in the antero-posterior position, closely followed the direction of two cardiac veins, the middle cardiac vein, catheterization of which has been reported by Bing *et al.* (1947) and the right marginal vein, which may either drain directly into the right atrium or into the coronary sinus via the lesser cardiac vein. It seems possible therefore that retrograde catheterization of one of these veins, either directly from the atrium or via the coronary sinus, led to its perforation. The choice of a relatively small bore catheter (size 7F) in this case may have facilitated this manœuvre.

*Case 5.* A 48-year-old man, suffering from rheumatic heart disease with mitral stenosis, auricular fibrillation, and congestive cardiac failure, was catheterized on two successive occasions for hæmodynamic assessment of progress. The first catheterization was carried out without incident. The notes referring to the second catheterization are incomplete, but the main facts are outlined here. The passage of the catheter from the right atrium into the right ventricle and pulmonary artery was viewed in the antero-posterior position. After advancing the catheter into "the pulmonary artery" pressures were measured but no free reading could be obtained, and it was apparent that the coronary sinus had been entered. The catheter was withdrawn into the atrium and was finally passed successfully into the right ventricle where satisfactory pressure recordings were made. Shortly afterwards the patient began to complain of sternal pain, became cold, pale and collapsed, and the blood pressure was found to have fallen from 120/80 to 90/60 mm. The pulse remained regular at 90 a minute. The investigation had therefore to be terminated and the patient was returned to the ward, where he was given oxygen therapy and routine treatment for shock.

During the next week the patient continued to have right sternal pain intermittently and on the fourth day after catheterization developed a pericardial rub. Serial cardiograms showed changing patterns in the left chest leads with development of an RSR pattern with S-T elevation in leads V4 and V5. This change was maximal on the fifth and sixth days after catheterization, reverting later to a more normal RS pattern in V5, but with T wave inversion in V3 and V5. These cardiographic findings were considered compatible with a small antero-lateral myocardial infarct. Over this period the patient had an intermittent low pyrexia, the erythrocyte sedimentation rate rose to 32 mm. in one hour (Westergren), but the white cell count was not raised. Recovery was complete after a fortnight and there have been no sequelæ.

#### DISCUSSION

The position generally occupied by the catheter is shown diagrammatically in Fig. 3. The clinical picture in all five cases, while varying in the degree of severity, was essentially similar in nature. Substernal pain radiating to the back, coming on at once during cardiac catheterization, was a characteristic of the three cases in which there was good evidence on screening that a cardiac vein had been entered via the coronary sinus. In the fourth case, in which the pericardium was probably entered via a cardiac vein, the site of radiation of substernal pain was different in that it spread to the neck and jaws only and not to the back. In the fifth case, a detailed account of events during catheterization and of exact symptomatology is lacking, but the general course of events strongly suggests that it should be included in the group. The severity of the initial collapse and degree of fall in blood pressure corresponded with the subsequent duration of substernal pain and the time elapsing before recovery.

The pathological process responsible for these clinical changes is uncertain, since, happily, all patients made a good recovery. Bing *et al.* (1949) reported no complications in studies with coronary sinus catheterization in man, but in his work care was taken not to advance too far into the coronary sinus. No strict parallel can be drawn between the experimental work of Gross *et al.* (1936) and the surgical approach to angina pectoris of Fauteux (1946), in which the coronary sinus was ligated, since the catheter is not of sufficient diameter to obstruct the mouth of the coronary sinus. It is of interest, however, to note that bradycardia following coronary sinus ligation was a constant finding in Gross's experiments, in view of the absence of any marked increase in pulse rate in the presence of a profound fall in blood pressure seen in our cases. It is probable that cardiac vein rather than coronary sinus catheterization is the harmful procedure, as in all our cases the catheter was passed to the point where it became wedged in the vein and could not be advanced

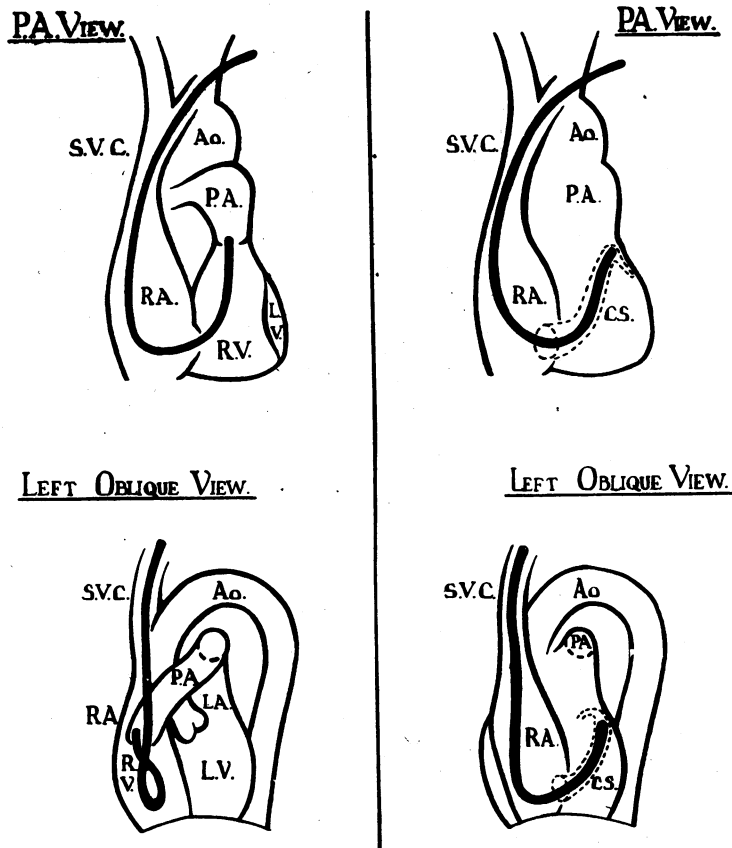


FIG. 3.—Diagram to show fluoroscopic appearances of a cardiac catheter in the pulmonary outflow tract and in the coronary sinus. On the left the catheter is seen in the right atrium and right ventricle with the tip in the pulmonary outflow tract. On the right the catheter is seen in the right atrium and coronary sinus with the tip at the origin of the coronary sinus.

further. Our experience of this unfortunate complication is not unique, as Dr. Warren Smith of New York has kindly informed us of a similar incident.

Goodale *et al.* (1948) in experiments on dogs, in which deep coronary catheterization was practised, reported hæmorrhages in the myocardium and coronary vein thromboses. Electrocardiographic changes were also noted by him in experiments in which the catheter was inserted into the great cardiac vein, with the development of T wave inversion and S-T segment elevation in one or more standard leads following the procedure. Such changes were associated at subsequent necropsy with intramural sub-epicardial hæmorrhage in areas drained by the catheterized vein in one case and in another with thrombotic occlusion of the great cardiac vein. No electrocardiographic changes were noted following experiments in which the catheter was inserted only a short distance into the coronary sinus. It is possible that a similar pathological process occurred in our cases, due to blocking of blood flow and damage to a cardiac vein with resultant myocardial injury in the area of muscle drained by this vein. The cardiographic changes suggesting localized myocardial ischæmia in two cases and pericarditis in a third lend support to this theory. A pericardial rub developed in one and in Case 4 there was strong evidence that the pericardium was entered by the catheter, but in none was there evidence of cardiac tamponade or pericardial effusion. It is worthy of note that four of our patients were of a type or age liable to have pathological changes in the coronary arteries.

It is suggested that the complication described in this paper can be avoided if due precautions are taken during the passage of the catheter from the right atrium to the right ventricle using fluoroscopic control. It has been shown by Hellerstein *et al.* (1951) that the anatomical variations of the orifice of the coronary sinus are great and in view of this it is probably unwise to attempt to recognize a typical course, in the antero-posterior view, of a catheter entering the coronary sinus. Screening in the left oblique position (Fig. 3) removes any possible doubt as to whether the catheter is entering the coronary sinus or the right ventricle, and we have now adopted this procedure in every case as a precaution against a recurrence of this serious complication.

#### SUMMARY

Inadvertent coronary sinus and cardiac vein catheterization in subjects past middle age has been followed by præcordial pain and collapse in five patients: all of them made a good recovery.

In one case there was evidence that a vein was perforated.

Electrocardiograms in three cases showed changes compatible with myocardial ischæmia or pericarditis.

It is important to realize the possible serious consequences of coronary sinus and cardiac vein catheterization and recommendations are made for the avoidance of this complication.

#### REFERENCES

- Bing, R. J., Hammond, M. M., Handelsman, J. C., Powers, S. R., Spencer, F. C., Eckenhoff, J. E., Goodale, W. T., Hafkenschiel, J. H., and Kety, S. S. (1949). *Amer. Heart J.*, **38**, 1.  
—, Vandam, L. D., Gregoire, F., Handelsman, J. C., Goodale, W. T., and Eckenhoff, J. E. (1947). *Proc. Soc. Exp. Biol. Med.*, **66**, 239.  
Fauteux, M. (1946). *Ann. Surg.*, **124**, 1041.  
Goodale, W. T., Lubin, M., Eckenhoff, J. E., Hafkenschiel, J. H., and Banfield, W. G. (1948). *Amer. J. Physiol.*, **152**, 340.  
Gross, L., Silverman, G., and Master, A. M. (1936). *Amer. Heart J.*, **11**, 734.  
Hellerstein, H. K., and Orbison, J. L., (1951). *Circulation*, **3**, 514.  
Smith, Warren, W. (1951). Personal communication.  
Zimdahl, W. T. (1951). *Amer. Heart J.*, **41**, 204.