

Thalidomide Effects in Patients with Hereditary Hemorrhagic Telangiectasia During Therapeutic Treatment and in Fli-EGFP Transgenic Zebrafish Model

Hong-Ling Peng¹, Yi-Fang Yi¹, Shun-Ke Zhou², Si-Si Xie¹, Guang-Sen Zhang¹

¹Division of Hematology, Second Xiangya Hospital, Central South University, Changsha, Hunan 410011, China

²Division of Radiology, Second Xiangya Hospital, Central South University, Changsha, Hunan 410011, China

Abstract

Background: Hereditary hemorrhagic telangiectasia (HHT) is an autosomal dominant disease characterized by recurrent epistaxis, mucocutaneous telangiectasia, and arteriovenous malformations. The efficacy of traditional treatments for HHT is very limited. The aim of this study was to investigate the therapeutic role of thalidomide in HHT patients and the effect in Fli-EGFP transgenic zebrafish model.

Methods: HHT was diagnosed according to Shovlin criteria. Five HHT patients were treated with thalidomide (100 mg/d). The Epistaxis Severity Score (ESS), telangiectasia spots, and hepatic computed tomography angiography (CTA) were used to assess the clinical efficacy of thalidomide. The Fli-EGFP zebrafish model was investigated for the effect of thalidomide on angiogenesis. Dynamic real-time polymerase chain reaction assay, ELISA and Western blotting from patient's peripheral blood mononuclear cells and plasma were used to detect the expression of transforming growth factor beta 3 (TGF- β 3) messenger RNA (mRNA) and vascular endothelial growth factor (VEGF) protein before and after 6 months of thalidomide treatment.

Results: The average ESS before and after thalidomide were 6.966 ± 3.093 and 1.799 ± 0.627 , respectively ($P = 0.009$). The "telangiectatic spot" on the tongue almost vanished; CTA examination of case 2 indicated a smaller proximal hepatic artery and decreased or ceased hepatic artery collateral circulation. The Fli-EGFP zebrafish model manifested discontinuous vessel development and vascular occlusion (7 of 10 fishes), and the TGF- β 3 mRNA expression of five patients was lower after thalidomide therapy. The plasma VEGF protein expression was down-regulated in HHT patients.

Conclusions: Thalidomide reverses telangiectasia and controls nosebleeds by down-regulating the expression of TGF- β 3 and VEGF in HHT patients. It also leads to vascular remodeling in the zebrafish model.

Key words: Hereditary Hemorrhagic Telangiectasia; Thalidomide; Zebrafish

INTRODUCTION

Hereditary hemorrhagic telangiectasia (HHT) is a hereditary autosomal dominant vascular dysplasia characterized by recurrent epistaxis, mucocutaneous telangiectasia, and arteriovenous malformations. Most HHT patients present recurrent and progressive epistaxis.^[1] The efficacy of traditional treatments including compression, laser therapy, embolization, electrocautery, and sclerotherapy is unsatisfactory. Recent reports suggest that vascular endothelial growth factor (VEGF) inhibitor efficiently controlled nosebleeds; however, the normal physiology was affected.^[2-4] Thalidomide has also been used to treat HHT patients and control epistaxis.^[5-7] Here, we report 5

HHT cases treated with thalidomide, showing that it not only controlled nose bleeds but also reversed telangiectasia.

HHT diagnosis is based on the presence of any three of the four criteria, known as the "Curaçao criteria"^[8] as (1) epistaxis, (2) telangiectasia of the lips, oral cavity, fingers, nose, or gastrointestinal tract, (3) arteriovenous malformations of the

Address for correspondence: Dr. Guang-Sen Zhang,
Division of Hematology, Second Xiangya Hospital, Central South
University, Changsha, Hunan 410011, China
E-Mail: zgsllzy@163.com

This is an open access article distributed under the terms of the Creative Commons Attribution-NonCommercial-ShareAlike 3.0 License, which allows others to remix, tweak, and build upon the work non-commercially, as long as the author is credited and the new creations are licensed under the identical terms.

For reprints contact: reprints@medknow.com

© 2015 Chinese Medical Journal | Produced by Wolters Kluwer - Medknow

Received: 26-06-2015 **Edited by:** Li-Shao Guo
How to cite this article: Peng HL, Yi YF, Zhou SK, Xie SS, Zhang GS. Thalidomide Effects in Patients with Hereditary Hemorrhagic Telangiectasia During Therapeutic Treatment and in Fli-EGFP Transgenic Zebrafish Model. Chin Med J 2015;128:3050-4.

Access this article online

Quick Response Code:



Website:
www.cmj.org

DOI:
10.4103/0366-6999.169068

lungs, liver, and central nervous system, and (4) family history involving first-degree relatives. Genetic testing is not necessary. Endoglin (ENG), activin receptor-like kinase-1 (ALK1), and SMAD4 were identified as related to HHT. The degree of epistaxis was estimated by Epistaxis Severity Score (ESS), which is based on six questions including epistaxis frequency, duration, intensity, need for treatment, the presence of anemia, and the need for blood transfusion. ESS is a valuable tool for monitoring disease progression.^[1]

Thalidomide was removed from market due to severe congenital defects. It was rediscovered in the treatment of erythema nodosum leprosum and recognized for its anti-angiogenic properties in cancer treatment.^[9] A study by Lebrin *et al.* reports that treatment with thalidomide in a mouse model of HHT stimulated mural cell coverage and thus, rescued vessel wall defects. It increased platelet-derived growth factor-B expression in endothelial cells and stimulated mural cell activation.^[7] Angiodysplasia of HHT is characterized by elevated serum levels of VEGF. Transforming growth factor beta (TGF- β) signaling plays an important role in HHT vascular development.^[10] We explored the mechanism of thalidomide treatment in HHT and found that VEGF and TGF- β were down-regulated following thalidomide therapy. Analysis of Fli-EGFP transgenic zebrafish revealed abnormal vascular development following thalidomide treatment.

METHODS

Study design

HHT was diagnosed according to Curaçao criteria.^[8] Five HHT patients were treated with thalidomide (100 mg/d) continuously at Second Xiangya Hospital between November 2008 and December 2012. Patients' charts were reviewed, and ESSs were recorded initially and 6 months later, to evaluate the efficiency of epistaxis control. Imaging of telangiectasia spots on tongue every 2 months and selective hepatic computed tomography angiography (CTA) was conducted every 6 months. Written informed consent was obtained from the patients and ethical approval was given by the Medical Ethics Committee of Second Xiangya Hospital.

DNA extraction, amplification, and sequencing

DNA was extracted from HHT patients' blood using the QIAGEN DNA Isolation kit (QIAGEN, Germany). ALK1, ENG, and SMAD4 exon polymerase chain reaction (PCR) reactions were carried out in a total volume of 50 μ l with 10 mmol/L Tris-HCl, pH 8.3, 1.5 mmol/L MgCl₂, 50 mmol/L KCl, 0.2 mmol/L dNTPs, and 30 nmol/L primers. The PCR conditions included 94 cycles for 5 min, followed by 35 cycles with annealing temperatures of 60°C for 0.5 min and 72°C for 0.5 min. The reactions were terminated with a final extension step at 72°C for 5 min.

PCR products were Sanger-sequenced and analyzed on ABI Sequencer (3100) using GeneScan and Genotyper software (PE Applied Biosystems, USA). The nucleotide sequences were deposited in GenBank.

Real-time polymerase chain reaction

Total cellular RNA was isolated from HHT patients' peripheral blood mononuclear cells (PBMNCs) using an RNA kit. First-strand complementary DNA (cDNA) synthesis was performed employing moloney murine leukemia virus reverse transcriptase, according to the manufacturer's protocol (Invitrogen, USA). The TGF- β 3 expression was quantified by amplification of cDNA using a real-time thermocycler (Lightcycler 96, Roche, Germany) and SYBR Green I chemistry. The primer sequences were as follows: TGF- β 3 (NM_003239.3) sense, 5'GGAAAACACCGAGTCGGAATAC3', and antisense, 5'GCGGAAAACCTTGGAGGTAAC3'. Optimized amplification conditions were 0.2 μ mol/L of each primer, 2.5 mmol/L MgCl₂, annealing and extension at 72°C for 40 cycles. The expression levels were standardized with reference to the housekeeping gene β -actin, and the final results were normalized to β -actin. The relative quantification was conducted using the comparative Cr method and expressed as arbitrary units.^[11]

Western blotting

Equal quantities of plasma were run on 8% sodium dodecyl sulfate-polyacrylamide gel electrophoresis and electroblotted onto nitrocellulose membranes, exposed to blocking reagent 10% milk in phosphate buffered saline-Tween, and then incubated overnight at 4°C with rabbit anti-human VEGF (Abcam, UK) or mouse anti-human β -actin (Sigma, USA) as the primary antibody, followed by horseradish peroxidase (HRP)-conjugated secondary antibodies. The protein bands were detected using chemiluminescence substrate solution and images were obtained with a gel analyzer system. The VEGF protein was quantified by normalization to β -actin protein and expressed as arbitrary units.

ELISA assay for vascular endothelial growth factor

Peripheral venous blood samples from the five HHT patients were collected into a sterile tube containing ethylenediaminetetraacetic acid and centrifuged at 2000 \times g for 10 min. The plasma was stored at -70°C before and after thalidomide treatment until assayed for VEGF. The VEGF plasma concentration was determined using a DVE00 Human VEGF Quantikine ELISA kit (R and D, Wiesbaden, Germany) according to the manufacturer's instructions. All analyses were carried out in duplicate.

Zebrafish strain and maintenance

Fli-EGFP-Tg transgenic zebrafish models were gifted by Hunan Normal University and maintained in aquaria according to standard procedures on a 10-h dark/14-h light cycle at 28°C.^[12] Approximately, 96 hpf (hours postfertilization) zebrafish embryos were used for experiments. Before experimental operations, all zebrafishes were anesthetized with 0.02% tricaine (Tricaine Methane Sulfonate, MS-222, Sigma, USA). The zebrafish facility and all experimental procedures were approved by the Second Xiangya Hospital Animal Ethical Committee.

Thalidomide treatment

Fli-EGFP-Tg zebrafish were exposed to 100 µmol thalidomide at 4 hpf and incubated with 96 hpf. The negative control included embryos treated only with 0.1% dimethyl sulfoxide simultaneously. The zebrafish was imaged under confocal microscope.

Confocal microscopy

Ninety-six hours postfertilization embryos were embedded in low melting-point agarose and examined under a confocal microscope (Leica TCS SP5 II microscope Leica Microsystems, Germany). Zebrafish was scanned at 2 µm per section and assembled into three-dimensional images. Vessel analysis was performed with at least 10 fish in each group using the color range tool of Adobe Photoshop CS2 version 9.0.2 software program (Adobe, USA).

Statistical analysis

Data were presented as mean ± standard deviation (SD) analyzed by SPSS Statistics 17 (IBM, Chicago, USA). A standard Student's *t*-test was used for statistical analysis, *P* < 0.05 was considered statistically significant.

RESULTS

Clinical features of five hereditary hemorrhagic telangiectasia patients

Five HHT patients were selected from three families and diagnosed according to the “Curaçao criteria”^[8] as follows:

- Family one: The proband was a 56-year-old woman with severe epistaxis, involving bleeding from gastric mucosa telangiectasia and bleeding anemia; the gene mutation involved ALK1^[13]
- Family two: The proband (case 2) was a 45-year-old woman with recurrent epistaxis and severe mucocutaneous telangiectasia of the tongue [Figure 1a]. Her two affected sisters (case 3 and case 4) also manifested epistaxis and telangiectasia of lips and fingers. The whole exome sequencing identified ALK1 gene mutation (exon 3, +244 A > C, leading to Thr 82 to Pro variation).
- Family three: The proband (case 5) was a 51-year-old woman who presented with severe epistaxis, mucocutaneous telangiectasia of lip and oral cavity. ALK1, ENG, and Smad4 exon sequencing revealed no mutations.

Thalidomide efficiently controls nosebleeds and reverses telangiectasia

The severity of epistaxis was evaluated by ESS, including frequency, intensity, duration, need for medical attention, transfusion related to epistaxis, and anemia. In the pretreatment period, the average ESS was 6.966 (standard deviation [SD] = 3.093). Following 6 months of thalidomide therapy, the average ESS was 1.799 (SD = 0.627), which was statistically significant (*P* = 0.009) [Table 1].

In all cases, the “telangiectatic spot” on tongue almost disappeared or decreased in size [Figure 1b]. CTA

Table 1: HHT patient clinical profile after thalidomide treatment represented by the ESS

Subject	Before therapy				After 6 months of therapy			
	Nose bleeds Frequencies*	Bleeding Intensity†	Blood transfusion‡	Anemia (Hemoglobin concentration, g/L)‡‡	Nose bleeds Frequencies*	Bleeding Intensity†	Blood transfusion‡	Anemia (Hemoglobin concentration, g/L)‡‡
Family one (case 1)	3	4	1	1 (40)	0	0	1	0 (118)
Family two (case 2)	5	3	1	1 (63)	0	0	1	0 (125)
Family two (case 3)	3	1	0	0 (110)	0	0	0	0 (122)
Family two (case 4)	3	1	0	0 (110)	0	0	0	0 (122)
Family three (case 5)	5	3	1	1 (60)	0	0	1	0 (123)

*How often do you have nose bleeding? Coefficient: 0.14. †How long do your typical nose bleeds last? Coefficient: 0.25. ‡How long do you typically nose bleeds last? Coefficient: 0.25. 1: 1–5 minutes; 3: 16–30 minutes; 4: >30 minutes. ‡‡How would you describe your typical nose bleeding intensity? Coefficient: 0.25. 0: Not typically gushing; 1: Typically gushing or pouring. †Have you ever received a red blood cell transfusion specifically because of nose bleeding? Coefficient: 0.31. 0: No; 1: Yes. ‡Are you anemic currently? Coefficient: 0.20. 0: No; 1: Yes. ‡Have you every sought medical attention for nose bleeding? Coefficient: 0.30. 0: No; 1: Yes. Average ESS: 6.966 (before therapy); 1.799 (after therapy). HHT: hereditary hemorrhagic telangiectasia. ESS: epistaxis severity score.

examination of case 2 indicated a tortuous malformation in hepatic artery and its branches [Figure 1c]. After a 6-month therapy, the proximal hepatic artery was smaller and hepatic artery collateral circulation decreased or ceased [Figure 1d].

Thalidomide down-regulated the transforming growth factor beta 3 and vascular endothelial growth factor expression in hereditary hemorrhagic telangiectasia patients

To explore the potential mechanism of thalidomide therapy, dynamic real-time PCR assay was used to detect the PBMNCs of HHT patients before and after thalidomide treatment. The TGF- β 3 messenger RNA expression of five patients was lower after thalidomide therapy. The plasma VEGF protein expression in HHT patients was down-regulated, as determined by ELISA (239 ng/ml compared with 159 ng/ml; $P = 0.019$) and in three of five patients tested by Western blotting [Figure 2].

Thalidomide leads to blood vessel remodeling in zebrafish model

Confocal microscopy of the Fli-EGFP transgenic zebrafish model revealed discontinuous development and blood vessel occlusion of the dorsal longitudinal anastomotic vessel and intersegmental blood vessel in 7 of 10 fish in the thalidomide treatment group [Figure 3].

DISCUSSION

The efficacy of traditional therapies for HHT including local therapy, surgery, and drug therapy are unsatisfactory. Since 2010, a few cases were reported showing that thalidomide successfully controlled HHT-related nose bleeds.^[7,14-16] Most of them included case reports except for Franck

Lebrin's study exploring the mechanism of thalidomide in vessel development.^[7] We not only observed improved epistaxis, but telangiectasia was actually reversed after thalidomide therapy, unlike previous studies. The hepatic vessel abnormality was also partly reversed.

Mutations in ENG and ALK1 in the TGF- β signaling pathway have been reported to cause up to 85% of HHT. TGF- β family members play an important role in vascular development. The effect of TGF- β on angiogenesis is context-dependent.^[17,18] TGF- β was shown to promote EC proliferation and migration at low concentrations whereas high concentrations had the opposite effect.^[17-20] Low concentrations of TGF- β enhanced the angiogenic effects of VEGF. Of the three isoforms of TGF- β , TGF- β 1 was the most effective. We detected the expression of TGF- β 1, TGF- β 2, and TGF- β 3 before and after thalidomide therapy, and found that only TGF- β 3 was regularly altered, which was probably related to limited sample size.

VEGF signaling plays a crucial role in angiogenesis, and several studies suggest a crosstalk between VEGF and ALK1/endoglin signaling in angiogenesis.^[21] Our previous study showed a higher VEGF expression in HHT patients. Our data showed that the VEGF expression level was down-regulated after thalidomide treatment. VEGF activation triggers multiple signaling networks that result in endothelial cell survival, mitogenesis, migration, and differentiation. Down-regulated VEGF probably explains the effect of thalidomide in reversing the vessel abnormality.^[22]

Fli-EGFP is an ideal model for vascular research and development involving EGFP with VEGF receptor. Our research suggests that zebrafish vessel development was affected following thalidomide intervention. Thalidomide appears to be a good choice in severe HHT-related bleeding, without any of the adverse effects associated with traditional therapies.

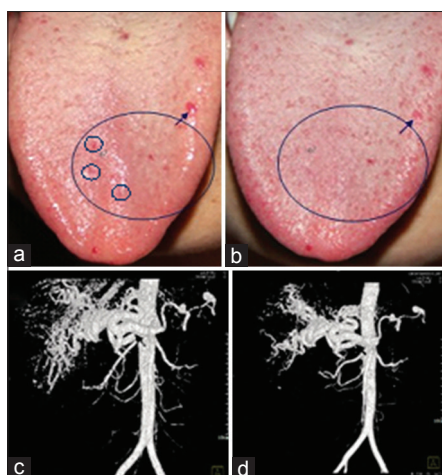


Figure 1: Telangiectasia images of case two with hereditary hemorrhagic telangiectasia. (a) Multiple mucocutaneous telangiectasia on the nose (before thalidomide therapy); (b) 6 months after thalidomide therapy; (c) the image of hepatic CTA (before thalidomide therapy); and (d) the image of hepatic CTA for 6 months after thalidomide therapy; the hepatic proper artery proximal transverse diameter is 125 mm, which is smaller than before thalidomide therapy (130 mm). Arrows show the hepatic proper artery proximal.

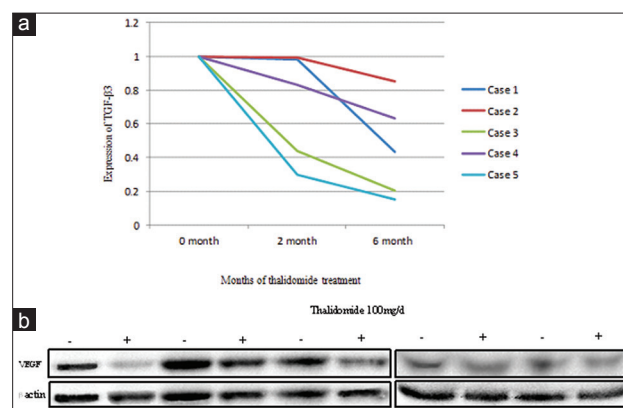


Figure 2: Changes of transforming growth factor beta 3 messenger RNA in peripheral blood mononuclear cells before and after thalidomide treatment in patients with hereditary hemorrhagic telangiectasia. (a) Real-time polymerase chain reaction results; (b) plasma vascular endothelial growth factor protein expression Western blotting results after 6 months of thalidomide therapy in 5 hereditary hemorrhagic telangiectasia patients ("-" means no thalidomide treatment; "+" represents thalidomide treatment).

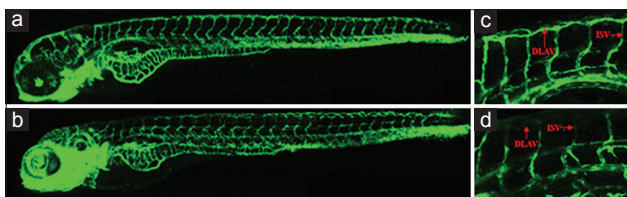


Figure 3: The effect of thalidomide on blood vessel generation on FLI; EGFP zebrafish model (result of morphological observation under confocal microscope). Red arrows indicate DLAV, ISV of zebrafish. Scale bar = 250 μ m. (a and c) Negative control: Embryos treated only with 0.1% dimethyl sulfoxide at 4 hpf (hours post fertilization) for 96 h; (b and d) zebrafishes treated with 100 μ mol thalidomide at 4 hpf for 96 h, discontinuous DLAV and ISV development and documented in 7 out of 10 fishes. DLAV: Dorsal longitudinal anastomotic vessel; ISV: Intersegmental blood vessel.

Financial support and sponsorship

This work was supported by grants from the National Natural Science Foundation of China (No. 81200368) and Project involving “Famous Clinical Doctor in Xiang-Ya Medical College, Central South University” (2012–2014) and General project of science and technology of Hunan science and Technology Department 2011WK3043.

Conflicts of interest

There are no conflicts of interest.

REFERENCES

- Hoag JB, Terry P, Mitchell S, Reh D, Merlo CA. An Epistaxis Severity Score for hereditary hemorrhagic telangiectasia. *Laryngoscope* 2010;120:838-43.
- Karnezis TT, Davidson TM. Efficacy of intranasal bevacizumab (Avastin) treatment in patients with hereditary hemorrhagic telangiectasia-associated epistaxis. *Laryngoscope* 2011;121:636-8.
- Karnezis TT, Davidson TM. Treatment of hereditary hemorrhagic telangiectasia with submucosal and topical bevacizumab therapy. *Laryngoscope* 2012;122:495-7.
- Guldmann R, Dupret A, Nivoix Y, Schultz P, Debry C. Bevacizumab nasal spray: Noninvasive treatment of epistaxis in patients with Rendu-Osler disease. *Laryngoscope* 2012;122:953-5.
- Chen CH, Hsu HH, Hu RH, Lee PH, Ho CM. Long-term therapy with thalidomide in hereditary hemorrhagic telangiectasia: Case report and literature review. *J Clin Pharmacol* 2012;52:1436-40.
- Amanzada A, Töppler GJ, Cameron S, Schwörer H, Ramadori G. A case report of a patient with hereditary hemorrhagic telangiectasia treated successively with thalidomide and bevacizumab. *Case Rep Oncol* 2010;3:463-70.
- Lebrin F, Srun S, Raymond K, Martin S, van den Brink S, Freitas C, et al. Thalidomide stimulates vessel maturation and reduces epistaxis in individuals with hereditary hemorrhagic telangiectasia. *Nat Med* 2010;16:420-8.
- Shovlin CL, Guttmacher AE, Buscarini E, Faughnan ME, Hyland RH, Westermann CJ, et al. Diagnostic criteria for hereditary hemorrhagic telangiectasia (Rendu-Osler-Weber syndrome). *Am J Med Genet* 2000;91:66-7.
- Franks ME, Macpherson GR, Figg WD. Thalidomide. *Lancet* 2004;363:1802-11.
- Pardali E, Goumans MJ, ten Dijke P. Signaling by members of the TGF-beta family in vascular morphogenesis and disease. *Trends Cell Biol* 2010;20:556-67.
- Pfaffl MW. A new mathematical model for relative quantification in real-time RT-PCR. *Nucleic Acids Res* 2001;29:e45.
- Weinstein BM, Schier AF, Abdelilah S, Malicki J, Solnica-Krezel L, Stemple DL, et al. Hematopoietic mutations in the zebrafish. *Development* 1996;123:303-9.
- Yu Q, Shen XH, Li Y, Li RJ, Li J, Luo YY, et al. An intron mutation in the ACVRL1 may be associated with a transcriptional regulation defect in a Chinese family with hereditary hemorrhagic telangiectasia. *PLoS One* 2013;8:e58031.
- Wang XY, Chen Y, Du Q. Successful treatment of thalidomide for recurrent bleeding due to gastric angiodysplasia in hereditary hemorrhagic telangiectasia. *Eur Rev Med Pharmacol Sci* 2013;17:1114-6.
- Penalzoza A, Vekemans MC, Lambert C, Hermans C. Deep vein thrombosis induced by thalidomide to control epistaxis secondary to hereditary haemorrhagic telangiectasia. *Blood Coagul Fibrinolysis* 2011;22:616-8.
- Alam MA, Sami S, Babu S. Successful treatment of bleeding gastro-intestinal angiodysplasia in hereditary haemorrhagic telangiectasia with thalidomide. *BMJ Case Rep* 2011;2011. pii: Bcr0820114585.
- Pardali E, ten Dijke P. Transforming growth factor-beta signaling and tumor angiogenesis. *Front Biosci (Landmark Ed)* 2009;14:4848-61.
- Goumans MJ, Valdimarsdottir G, Itoh S, Rosendahl A, Sideras P, ten Dijke P. Balancing the activation state of the endothelium via two distinct TGF-beta type I receptors. *EMBO J* 2002;21:1743-53.
- Pepper MS. Transforming growth factor-beta: Vasculogenesis, angiogenesis, and vessel wall integrity. *Cytokine Growth Factor Rev* 1997;8:21-43.
- Serrati S, Margheri F, Pucci M, Cantelmo AR, Cammarota R, Dotor J, et al. TGFbeta1 antagonistic peptides inhibit TGFbeta1-dependent angiogenesis. *Biochem Pharmacol* 2009;77:813-25.
- Cunha SI, Pardali E, Thorikay M, Anderberg C, Hawinkels L, Goumans MJ, et al. Genetic and pharmacological targeting of activin receptor-like kinase 1 impairs tumor growth and angiogenesis. *J Exp Med* 2010;207:85-100.
- Hicklin DJ, Ellis LM. Role of the vascular endothelial growth factor pathway in tumor growth and angiogenesis. *J Clin Oncol* 2005;23:1011-27.