

THE APICAL SYSTOLIC MURMUR IN MITRAL STENOSIS

BY

PATRICK MOUNSEY AND WALLACE BRIGDEN

From the Cardiac Department of the London Hospital

Received January 11, 1954

The purpose of this work was to determine how reliable a guide an apical systolic murmur can be to the finding at mitral valvotomy of incidental mitral regurgitation complicating dominant mitral stenosis.

The history of the systolic murmur in mitral stenosis is a confused one, since general agreement was not reached about the timing of systolic and diastolic murmurs in mitral stenosis for nearly a century after Laennec (1819) first described the "bruit de soufflet" and "bruit de scie." Thus Ormerod (1864), Dickinson (1887), and Brockbank (1910) held that the characteristic murmur in mitral stenosis was in early systole and due to associated mitral regurgitation. On the other hand, Fauvel (1843), Gairdner (1861), and Fagge (1870) believed that the murmur was in late diastole and resulted from obstruction to the passage of blood through the mitral valve, as Laennec had originally suggested. With the advent of the electrocardiogram and phonocardiogram, the time of the murmur was fixed more accurately in the cardiac cycle. It became accepted that both diastolic and systolic murmurs were heard in mitral stenosis, the diastolic murmur being of chief importance as indicating stenosis, the systolic murmur, when present, being of secondary significance only, since it indicated merely a degree of incidental mitral regurgitation. With the introduction of mitral valvotomy and the consequent need for more detailed knowledge of the functional pathology of the mitral valve, interest has been re-awakened in the systolic murmur as one possible guide to the presence of regurgitation complicating mitral stenosis (Baker *et al.*, 1952; Froment and Gravier, 1952; Abelmann *et al.*, 1953; Sellors *et al.*, 1953).

METHOD

Fifty patients, judged to have dominant mitral stenosis, were treated by mitral valvotomy, where the surgeon's finger estimated with special care the degree of incidental mitral regurgitation complicating dominant mitral stenosis.*

The age of the patients varied between 17 and 49 years, the majority being in the 30 to 39 age group. Thirty-two patients were in sinus rhythm and 18 had auricular fibrillation. Clinical, radiological, and electrocardiographic evidence of left ventricular enlargement was absent in all patients in this series, with the exception of five, in whom the radiological evidence of slight enlargement was thought to be due to aortic incompetence. In no case was there great enlargement of the left auricle. Right ventricular hypertrophy, as assessed by the electrocardiogram, was present in 32 of the 50 patients.

Clinical examination was amplified by a phonocardiogram in every case and this was recorded on a four-channel phonocardiograph, as described by Leatham (1949); an electrocardiogram was used as a reference tracing.

RESULTS

Findings at Operation. The presence of mitral stenosis was confirmed at valvotomy in every patient, but the degree of stenosis varied (Fig. 1). In the majority the long diameter of the aperture

* Mr. Vernon Thompson and Mr. Geoffrey Flavell performed the valvotomies.

MITRAL REGURGITATION AT OPERATION					
NONE	SLIGHT	MODERATE	CONSIDERABLE		
●●●●●● ○○	○			0.5	MITRAL VALVE ORIFICE DIAMETER (CM)
○●●●●●●● ●●●●●●●● ○○	○●●●●●●	○○		1.0	
○○●●●●●	○●●●●	○○		1.5	
			○	2.0	
				2.5	
		●		3.0	

FIG. 1.—The relationship between the long diameter of the mitral valve orifice and the degree of incidental mitral regurgitation, as estimated in the 50 patients at valvotomy. The measurement of the long diameter of the valve orifice is given in centimetres. The open circles indicate patients with calcification of the mitral valve.

was estimated at about 1 cm.: in a few it was considerably less than this (about 0.5 cm.) and in some greater (between 1 and 1.5 cm.). In one patient the long diameter was judged to be 2 cm.; in the single case in which valvotomy was not performed it was estimated at 3 cm.

In 18 patients a regurgitant stream was felt by the exploring finger in the left auricle. In none was the regurgitation judged to be great or to predominate over the stenosis. A rough reverse relationship was noted between the degree of incidental mitral regurgitation and the degree of mitral stenosis. In patients with a long diameter of the valve of less than 1.5 cm., regurgitation was found to be slight or moderate. A greater degree of regurgitation was met in the patient with a valve diameter of 2 cm. Even in this case, however, stenosis predominated over regurgitation, which appeared to be due to defective apposition rather than to shortening of the mitral valve cusps, since firm digital pressure on the antero-medial cusp was found temporarily to abolish the central regurgitant stream.

A fall in systemic blood pressure always occurred at the time of operation and this may have temporarily diminished or abolished regurgitation that would have been present under more normal conditions. For this reason alone, operation findings cannot be taken as an absolute indication of the presence or degree of regurgitation.

Calcification of the mitral valve was found at operation in 13 patients; in eight of these it was seen on screening. Regurgitation at operation was found to be more frequent in those with calcification. Thus of 13 patients with calcification, 8 had some degree of regurgitation also, while of the remaining 37 without calcification only 10 had regurgitation.

The Apical Systolic Murmur. An apical systolic murmur was heard in 31 cases. In 9 it was pan-systolic (Fig. 2) and in 22 it was in the first half of systole (Fig. 3). The pan-systolic murmur varied widely in intensity, the louder murmur being conducted over the whole præcordium and into the axilla, but in no case was a thrill felt. In most instances, the murmur had a high-pitched blowing quality. When the apical murmur was in the first half of systole, it was always soft and

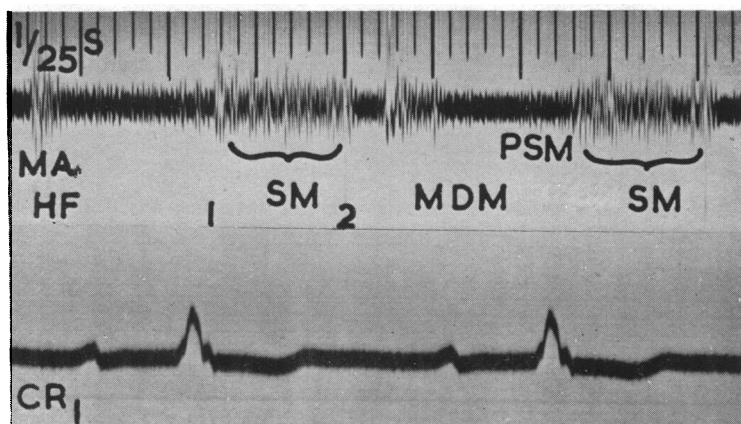


FIG. 2.—Apical pan-systolic murmur. MA=mitral area. HF=high frequency filter. 1 and 2=first and second heart sounds. SM=systolic murmur. MDM—mid-diastolic murmur. PSM—presystolic murmur.

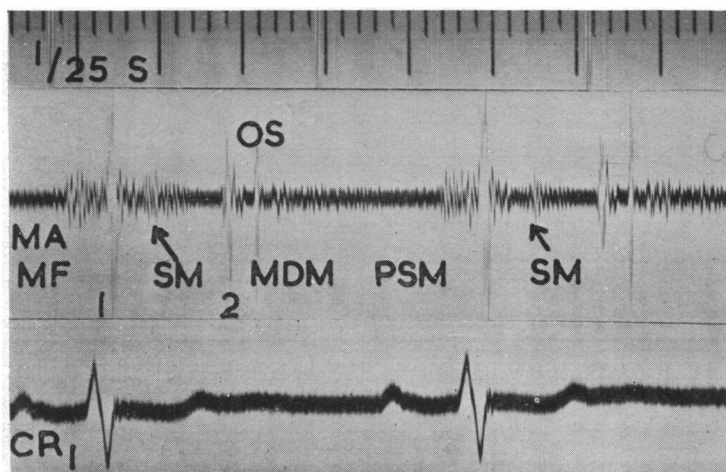


FIG. 3.—Apical systolic murmur, the bulk of which is in the first half of systole. MA=mitral area. MF=medium frequency filter. 1 and 2=first and second heart sounds. OS=opening snap. SM=systolic murmur. MDM=mid-diastolic murmur. PSM=presystolic murmur.

might easily be missed on casual auscultation, being partly obscured by a loud first heart sound or presystolic murmur, when present. No relationship was found between the presence or absence of a presystolic murmur and the systolic murmur.

The relationship between the presence and type of *apical systolic murmur and the operation finding of incidental mitral regurgitation* complicating dominant mitral stenosis is shown in Fig. 4. A pan-systolic apical murmur was always associated with some degree of regurgitation at operation, whether the murmur was loud or soft. The loudness of the pan-systolic murmur, on the other hand, although in general proportional to the degree of regurgitation found, was not always so and in one patient with a murmur of medium loudness tight mitral stenosis with only a small lateral regurgitant jet was found at operation.

MITRAL REGURGITATION AT OPERATION					APICAL SYSTOLIC MURMUR
NONE	SLIGHT	MODERATE	CONSIDERABLE		
●●●●● ●●●●● ●●●●●	●			NONE	FIRST HALF OF SYSTOLE
●●●●● ●●●●● ●●●●●	●●●●● ●●●●●				
	●●			SOFT	PAN-SYSTOLIC
	●	●●●●●		MEDIUM	
			●	LOUD	

FIG. 4.—The relationship in 50 patients between (a) the presence, the type, and the loudness of an apical systolic murmur, and (b) the operation finding of incidental mitral regurgitation.

The apical murmur in the first half of systole showed no direct relationship to the operation finding of incidental mitral regurgitation, which was present, though slight, in 8 out of 22 patients. Absence of an apical systolic murmur was, with one exception, associated with absence of regurgitation at operation.

Other Systolic Murmurs in Mitral Stenosis. A systolic murmur, present during episodes of right heart failure, was sometimes difficult to differentiate from the apical murmur of mitral regurgitation. It was met in four patients during congestive failure; it was loud, pan-systolic, best heard at the left sternal edge in the fourth and fifth intercostal spaces, but well conducted to the apex also; and after recovery from failure it either diminished or disappeared completely. One patient had two episodes of right heart failure, while awaiting mitral valvotomy in hospital, and on each occasion the murmur came with failure and went with recovery (Fig. 5). In another patient phasic variation in intensity of the murmur was noted with respiration, the murmur becoming louder during inspiration. This was in contrast to apical systolic murmurs on which respiration had little effect. This murmur was thought to be due to temporary tricuspid regurgitation and this is supported by recent hæmodynamic studies of tricuspid valve disease (Shillingford, 1953). Other signs of tricuspid incompetence, such as a ventricular systolic wave in the jugular venous pulse and a pulsating liver, were not present in our patients.

A mid-systolic murmur, loudest in the aortic area but conducted to the apex, was heard in three patients with slight aortic incompetence complicating the mitral stenosis. It was thought that the scarred incompetent aortic valve cusps gave rise to the systolic murmur in the absence of aortic stenosis.

DISCUSSION

Although only the systolic murmur has so far been discussed in relation to the operation finding of incidental mitral regurgitation, other signs of mitral regurgitation were carefully looked for in this series, but yielded no additional information. No patient with left ventricular enlargement

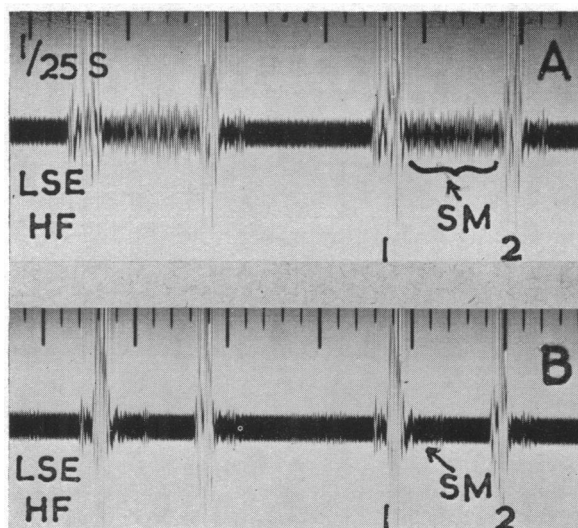


FIG. 5.—Pan-systolic murmur, present during right heart failure and disappearing after recovery. Both records were made at the left sternal edge (LSE) in the fourth intercostal space with a high frequency filter (HF). (A) recorded during right heart failure and (B) one week later after recovery from failure. The pan-systolic murmur has been replaced by a small murmur confined to the first half of systole.

was included in the series, with the exception of five, where slight enlargement was thought to be due to aortic incompetence, and so this important sign of significant mitral regurgitation was always absent. It has been suggested that great enlargement of the left auricle is often associated with mitral regurgitation (Baker *et al.*, 1952; and Ablemann *et al.*, 1953). In our series, from which patients with gross left auricular enlargement were excluded, no relationship was noted between minor variations in the size of the left auricle and the presence of incidental mitral regurgitation. Bilateral systolic expansion of the left auricle seen in the anterior view, which Brigden and Leatham (1953) found to be the only reliable radiological sign of pure mitral regurgitation, was never seen in this series. Marked backward movement of the posterior border of the left auricle, which is not a reliable sign of mitral regurgitation, was found to be associated with the operation finding of pure mitral stenosis as frequently as with stenosis complicated by regurgitation. Venner and Holling (1953), Wynn *et al.* (1952), and Ablemann *et al.* (1953) did not find the pulmonary capillary pressure curve a reliable guide to the presence of incidental regurgitation complicating mitral stenosis and in those of our patients on whom cardiac catheterization was performed the pulmonary capillary pressure curve did not give clear additional information about the presence of incidental mitral regurgitation.

It was thought that the loudness of the first heart sound and the finding of an opening snap might be of additional help in recognizing incidental mitral regurgitation complicating dominant mitral stenosis. Since in pure mitral stenosis the first heart sound is usually loud and the opening snap clear, and since in pure mitral regurgitation the first heart sound is not accentuated and the opening snap absent (Brigden and Leatham, 1953), it might be expected that in mitral valve disease these sounds would indicate whether stenosis or regurgitation predominated. Calcification of the mitral valve, however, is also associated with a soft first heart sound and a soft or absent opening snap (Wynn, 1953; Mounsey, 1953). In this series the association of a soft first heart sound and a soft or absent opening snap was related to valve calcification and only indirectly related to the

operation finding of incidental mitral regurgitation, owing to the relatively higher incidence of regurgitation in patients with valve calcification.

SUMMARY AND CONCLUSIONS

In a series of 50 patients with dominant mitral stenosis selected for mitral valvotomy, an apical pan-systolic murmur was found to be the most reliable guide to the operation finding of incidental mitral regurgitation. All patients with a pan-systolic apical murmur had mitral regurgitation, whether the murmur was loud or soft. The loudness of the murmur was not a reliable indication of the varying degree of regurgitation.

An apical murmur in the first half of systole was not constantly related to the operation finding of regurgitation, which was never more than of slight degree in these patients. Absence of an apical systolic murmur was, with one exception, associated with absence of regurgitation at operation.

A pan-systolic murmur, present in four patients during right heart failure and disappearing after recovery, was sometimes difficult to differentiate from the apical murmur of mitral regurgitation. It was thought to be caused by temporary tricuspid regurgitation.

The association of a soft first heart sound and a soft or absent opening snap was related to calcification of the mitral valve and only indirectly to incidental mitral regurgitation, owing to the relatively higher incidence of regurgitation in patients with valve calcification.

We wish to thank Dr. William Evans for his helpful advice and criticism in the preparation of this paper, and Mr. Vernon Thompson and Mr. Geoffrey Flavell for their co-operation. Thanks are also due to Mr. W. Dicks for technical assistance with the phonocardiograms.

REFERENCES

- Abelmann, W. H., Ellis, L. B., and Harken, D. E. (1953). *Amer. J. Med.*, **15**, 5.
 Baker, C., Brock, R. C., Campbell, M., and Wood, P. (1952). *Brit. med. J.*, **1**, 1043.
 Brigden, W., and Leatham, A. (1953). *Brit. Heart J.*, **15**, 55.
 Brockbank, E. M. (1910). *Quart. J. Med.*, **3**, 345.
 Dickinson, W. H. (1887). *Lancet*, **2**, 650 and 695.
 Fagge, C. H., (1870-71). *Guy's Hosp. Rep.*, 3rd ser., **16**, 247.
 Fauvel, S. A. (1843). *Arch. gén. Méd. Paris.*, ser. 4, **1**, 1.
 Froment, R., and Gravier, J. (1952). *Rev. Lyon. Méd.*, **1**, 317.
 Gairdner, W. T. (1861). *Edinb. med. J.*, **7**, 438.
 Laennec, R. T. H. (1819). *De l'Auscultation médiate ou Traité du Diagnostic des Maladies des Poumons et du Cœur, Fondé principalement sur ce nouveau Moyen d'Exploration*. Brosson et Chaudé, Paris.
 Leatham, A. (1949). *Post-grad. med. J.*, **25**, 568.
 Mounsey, J. P. D. (1953). *Brit. Heart J.*, **15**, 135.
 Ormerod, E. L. (1864). *Med. Times Gaz.*, **2**, 153.
 Sellors, T. H., Bedford, D. E., and Somerville, W. (1953). *Brit. med. J.*, **2**, 1059.
 Shillingford, J. P. (1953). Personal communication.
 Venner, A., and Holling, H. E. (1953). *Brit. Heart J.*, **15**, 205.
 Wynn, A. (1953). *Brit. Heart J.*, **15**, 214.
 —, Mathews, M. B., McMillan, I. K. R., and Daley, R. (1952). *Lancet*, **2**, 216.