

SOME VARIATIONS IN THE SHAPE OF THE PRESSURE CURVE IN THE HUMAN RIGHT VENTRICLE

BY

PETER HARRIS*

From the Cardiological Department, King's College Hospital

Received June 15, 1954

The curves of normal intraventricular pressure have been the subject of many studies in animals. Wiggers in 1928 gave what is now the standard description and explanation of these and summarized the extensive literature up to that date.

The purpose of this investigation is to study the curve of right ventricular pressure in man and how it may become modified under abnormal conditions. In particular, a comparison has been made between the right ventricular tracings in pulmonary hypertension and pulmonary stenosis—the two common situations in which right ventricular pressure is raised.

MATERIAL AND METHODS

Pressure tracings have been made during the course of routine cardiac catheterization. With one exception, therefore, the subjects have all had some cardiovascular abnormality. Adequate records have been available in 43 patients. Thirty-eight had intact ventricular septa, and these comprise the main study. They have been divided into three groups; those with normal pulmonary artery pressure (11); those with pulmonary hypertension (15); and those with pulmonary stenosis (12). In addition there have been three patients with an isolated ventricular septal defect, and two with Eisenmenger's complex.

Pressure readings have been made with a capacitance manometer using the apparatus devised by Bareham (1954). Tracings from the pulmonary artery have been taken within a short time of those from the right ventricle, but there have been no simultaneous recordings of pressure. Cardiograms have been recorded simultaneously with the pressure tracings, and, where pulmonary artery pressure curves have been drawn on top of those from the right ventricle, the time relationship of the two curves has been arrived at by superimposing the QRS complexes of the cardiogram.

Distortion of the tracings may be due to intermittent occlusion of the tip of the catheter by pulmonary (Lagerlöf and Werkö, 1949) or tricuspid (Lenègre and Maurice, 1946) valves, or by the ventricular wall itself. It may also arise owing to excessive damping when the catheter contains blood, and this is particularly found towards the end of the examination when, following the taking of a number of blood samples, a fine deposit of coagulum has presumably formed within the lumen of the catheter (Fig. 1). All tracings showing such distortions have been excluded.

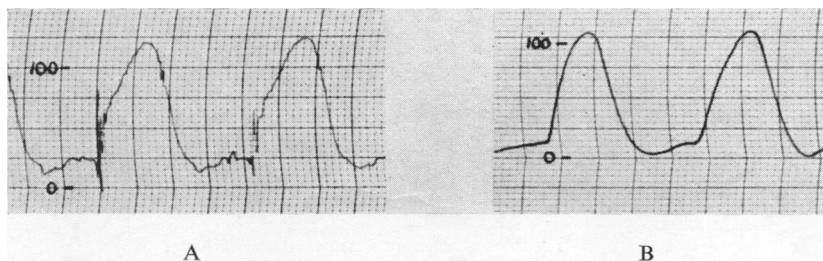


FIG. 1.—Right ventricular tracings from the same case to show the effect of excessive damping due to clogging of the catheter. (A) Catheter lumen free, (B) Catheter clogged. In this and all subsequent figures, the manometric scale refers to mm. Hg.

* Wiltshire Memorial Research Scholar.

Pressures have been measured from the level of the table on which the patient was lying. Different authors have used different points of reference for their level of zero, and some adjustment has to be made before their figures may be compared (Holling and Zak, 1950). When converted in this way to measurements from the level of the table, the upper limit of normal right ventricular systolic pressure found by various authors is 40 mm. Hg (Bloomfield *et al.*, 1946 ; Dexter *et al.*, 1947 ; Dexter *et al.*, 1950 ; Lagerlöf and Werkö, 1948). In the "normal" group of this study the right ventricular systolic pressure has been below 40 mm. Hg and in the group with pulmonary hypertension it has been above 50 mm. Hg.

Throughout this discussion, the term "systole" has been used to mean the whole of the major wave of the ventricular pulse and thus includes isometric contraction, ejection, and isometric relaxation.

RESULTS

Normal Right Ventricular Pressure. All except one of these cases have had some cardiac abnormality. Nevertheless, it has been thought justifiable to assume the function of the right ventricle to be normal where the pressure in the pulmonary artery is normal and the ventricular septum intact, whatever abnormalities might exist elsewhere in the heart.

Fig. 2 shows tracings from two such cases. Right ventricular systole starts with a sudden rise in pressure corresponding to the isometric phase of contraction. After this, the tracing alters its direction and follows the shape of the curve of pressure in the pulmonary artery. This, therefore, is the ejection phase. It occupies most of ventricular systole. Most often the tracing during this phase rises to a low summit very quickly and then declines gradually to the point of closure of the pulmonary valves. This, however, is not invariable. In one case it rose gradually to reach a gentle summit near its end, and in one case it was quite level. In another it was seen to vary according to the changing intrathoracic pressures during the respiratory

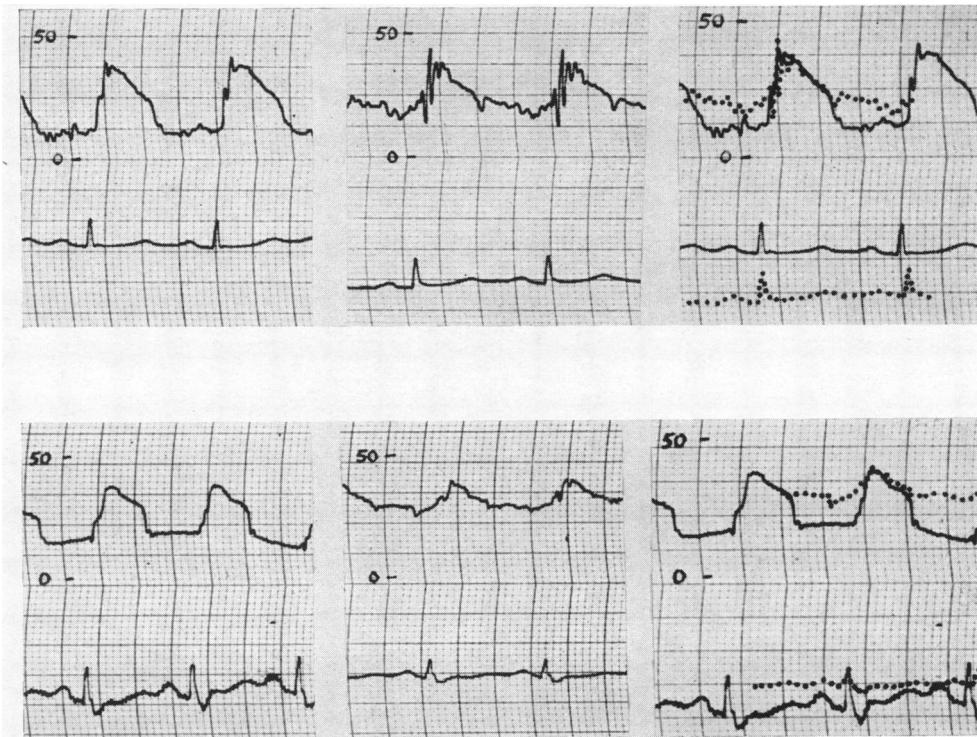


FIG. 2.—Tracings from two patients with normal right heart pressures. The left-hand column shows the right ventricular tracings ; the middle column shows the pulmonary artery tracing ; on the right hand the two are superimposed.

cycle (Fig. 3). The third phase of the pulse wave is a sudden decline of pressure corresponding to isometric relaxation. This occurs approximately at the incisura of the pressure curve in the pulmonary artery.

The initial rise of the ejection phase may be quite steep so that it appears to be a continuation of the isometric contraction phase, and the true point of demarcation between the two phases does not become apparent until the tracing from the pulmonary artery is superimposed. Although, therefore, in these cases the right ventricular curve is "squared off" into three distinct divisions, these do not strictly correspond with the three physiological phases of systole. Thus the upstroke consists of isometric contraction plus the beginning of ejection, the "plateau" is the last part of ejection, and the down stroke is isometric relaxation.

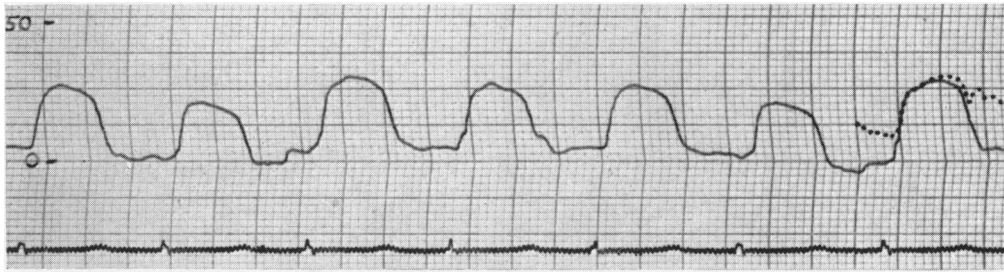


FIG. 3.—Right ventricular tracings from a child of two years with an atrial septal defect. The gross undulations in intrathoracic pressure due to respiration affect the shape of the ejection phase.

Pulmonary Hypertension. Seven of these patients were suffering from mitral stenosis. Four had "primary" pulmonary hypertension, two atrial septal defect, one pulmonary fibrosis, and one patent ductus arteriosus. The general shape of the recording from the right ventricle was the same in all these patients, no matter what the origin of the high pressure in the pulmonary artery.

As in the normals, the pressure tracing during ventricular systole comprises three distinct phases; isometric contraction, ejection, and isometric relaxation (Fig. 4). The abrupt rise and fall of the first and third phases is unchanged. The deflections are, however, naturally of greater amplitude, and the fall of pressure during isometric relaxation is increased disproportionately. Once again, the right ventricular curve in the ejection phase is seen to correspond with that of the pulmonary artery. But, instead of a quick rise and gradual fall, this part of the curve rises steadily and the summit is reached only towards the end of ejection. The more severe the pulmonary hypertension, the steeper is this rise. The descent from the summit usually passes imperceptibly into the phase of isometric relaxation. Hence, again, the three apparent divisions of the pulse wave usually do not correspond with the physiological phases of systole. In this case, however, the upstroke represents isometric contraction and the "plateau" the first part of the ejection, while the downstroke comprises the last part of ejection plus isometric relaxation.

Pulmonary Stenosis. Twelve cases were studied. Ten of these were of the valvular type and two infundibular. In no case was there any evidence of a ventricular septal defect. In two cases an atrial septal defect was shown.

Where the stenosis is valvular, the shape of the right ventricular systolic pulse is quite different from that in either of the two preceding groups (Fig. 5). No distinct divisions of systole are apparent and the tracing becomes a simple hump with its summit in mid-systole. This pattern was consistently found and held good even for the mildest cases with systolic pressures in the region of 50 mm. Hg. The pulse wave in this way sometimes approaches the shape of an isosceles triangle. A small notch on the upstroke may correspond with the first sound.

There is great similarity between the tracings from the main chamber of the right ventricle in the two patients with infundibular stenosis. The pulse wave, however, differs from that found where the obstruction is at the valve. Its shape approximates to that observed in patients with pulmonary hypertension (Fig. 6). There is an abrupt upstroke followed by a gently rising "plateau" which reaches its summit towards the end of systole and then descends rapidly towards the base line.

Patients with Ventricular Septal Defects. Adequate studies of patients with ventricular septal defects have been limited and will be given only brief consideration here. Three patients had an isolated ventricular septal defect and a large shunt of the type described by Wood (1950) and Joly *et al.* (1951). In all three, there was great similarity in the shape of the right ventricular pulse wave which

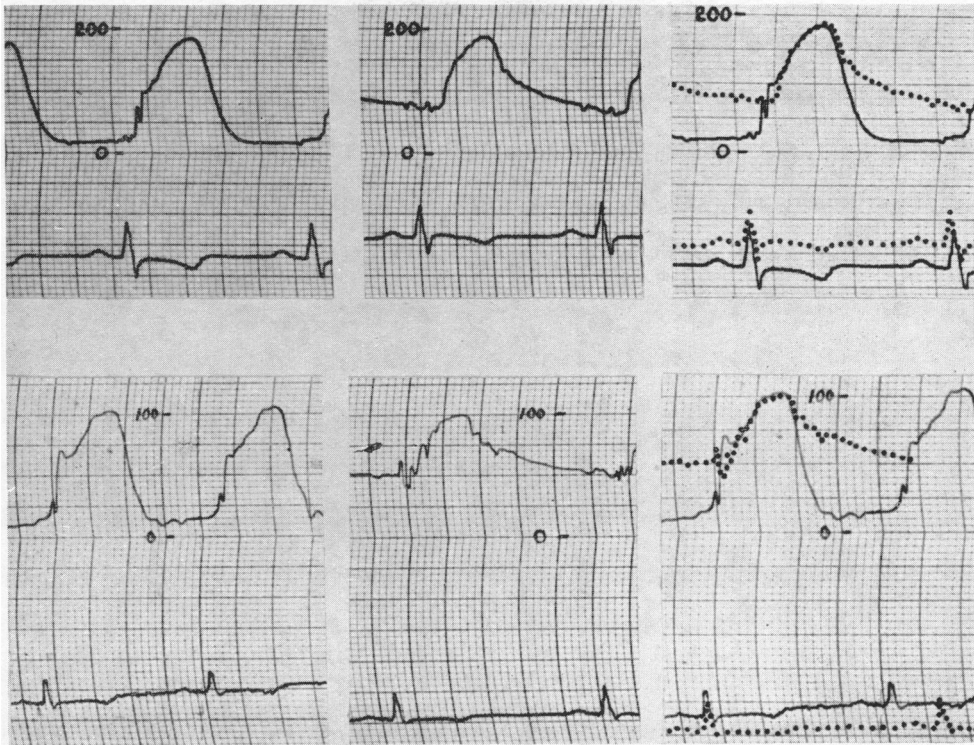


FIG. 4.—Tracings from two patients with pulmonary hypertension. The left-hand column shows the right ventricular tracings ; the middle column shows the pulmonary artery tracing ; and on the right hand the two are superimposed.

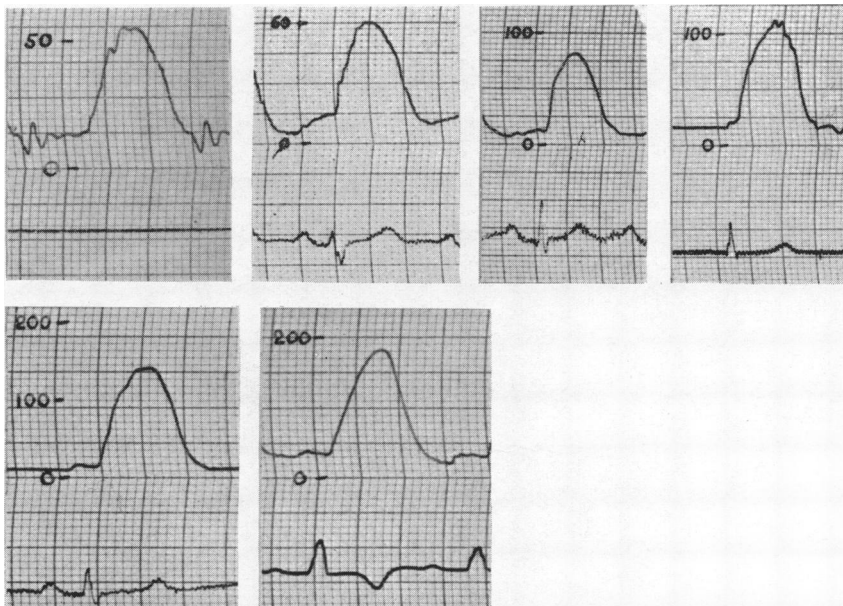

FIG. 5.—Right ventricular recordings from patients with pulmonary valvular stenosis of varying severity.

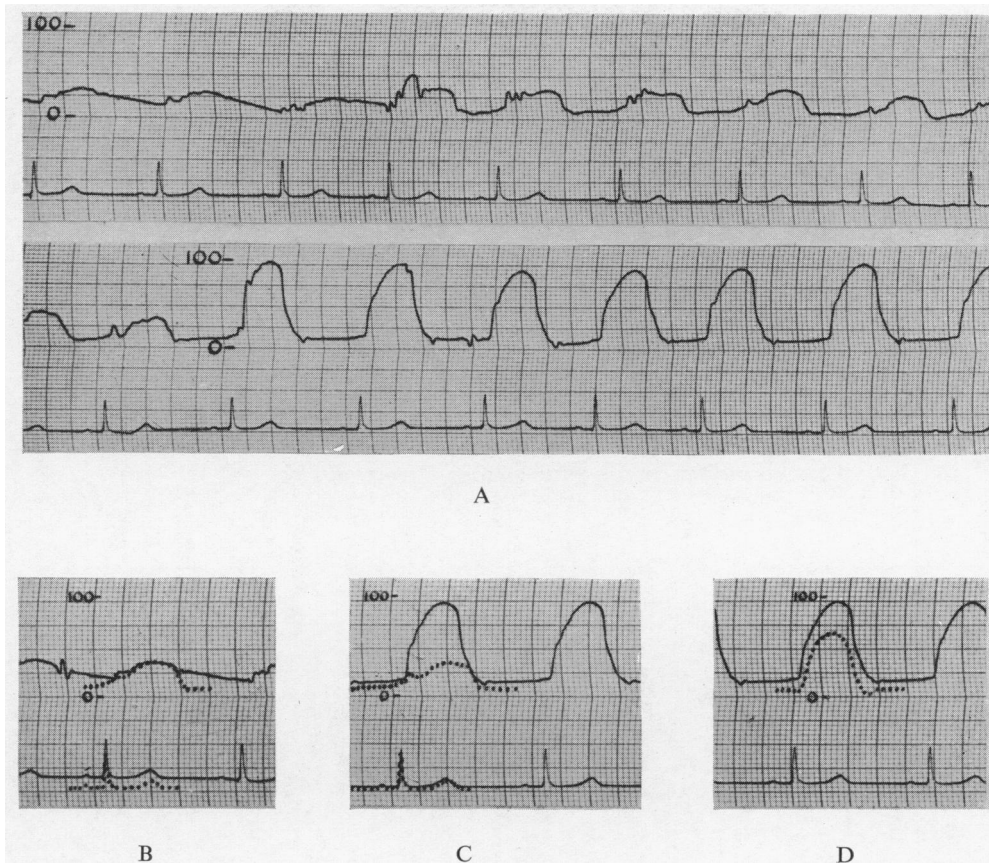


FIG. 6.—From a patient with isolated pulmonary infundibular stenosis. (A) Withdrawal of catheter from the pulmonary artery through the infundibulum to the right ventricle; (B) Pulmonary artery tracing with infundibular tracing superimposed; (C) Right ventricular tracing with infundibular tracing superimposed; (D) Right ventricular tracing. The dotted line here shows the curve that results when the infundibular tracing is subtracted from that in the right ventricle.

rose suddenly to an unusually high peak at the beginning of systole (Fig. 7). This peak, which thus initiated the phase of ejection, was not recorded in the tracings taken from the right or left main branches of the pulmonary arteries. When, therefore, the pulse wave in these vessels was superimposed upon that from the right ventricle, it was seen that, during the early part of ejection, the ventricular pressure was considerably the higher of the two (Fig. 7). Thereafter, the right ventricular pressure fell to join the curve of pressure in the pulmonary artery branch in the last half of the ejection phase. The shape of the tracing from the main trunk of the pulmonary artery was found to vary from case to case. In one patient, no recording was available from this site. In another, the tracing from the main trunk corresponded with that from the left branch. In the third, the tracing from the main trunk differed from that in the branches and corresponded with the recording from the right ventricle throughout the phase of ejection (Fig. 8). Thus the change in shape of the pulse wave during this phase did not necessarily occur at the level of the pulmonary valve and could take place further downstream in the pulmonary artery.

Two patients were thought to have Eisenmenger's complex. In both of these, high right ventricular systolic pressures were found and the systolic pulse consisted of three divisions as in the patients with pulmonary hypertension. In one patient the pressure in the pulmonary artery was recorded and appeared to correspond with the right ventricular curve during the ejection phase. In the other patient the catheter passed into the aorta where, again, the curve of the ejection phase was identical with that in the right ventricle (Fig. 9).

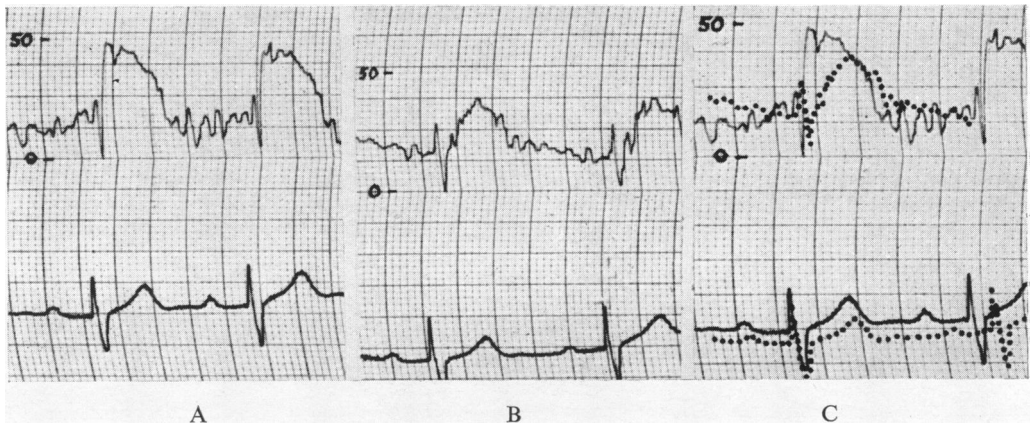


FIG. 7.—Recordings from a patient with a ventricular septal defect. (A) Right ventricular tracing; (B) Left pulmonary artery tracing; (C) Superimposed tracings.

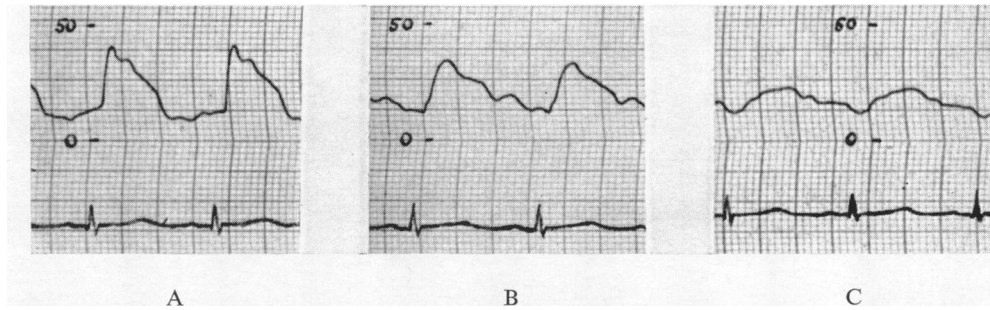


FIG. 8.—From a child with ventricular septal defect. (A) Right ventricle; (B) Main pulmonary artery; (C) Left pulmonary artery.

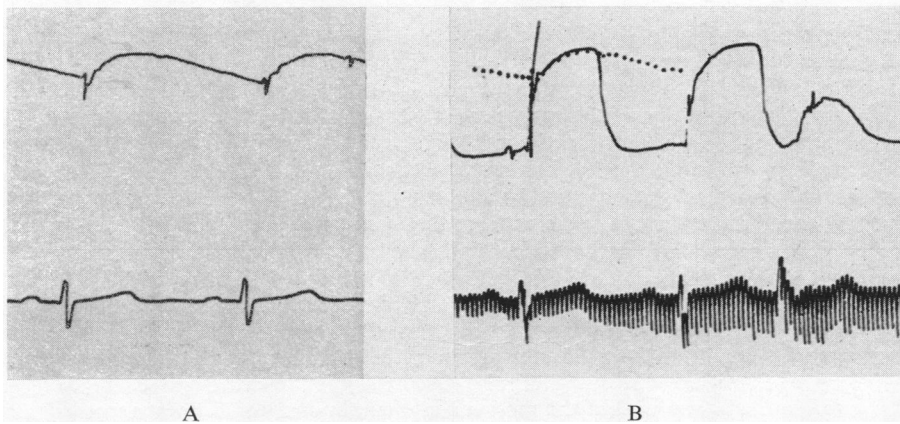


FIG. 9.—From a patient thought to have Eisenmenger's complex. (A) Aorta; (B) Right ventricle with aortic tracing superimposed. An "ineffective" ventricular premature beat is shown in the right ventricular tracing. The ejection phase of the tracings has probably been artificially flattened by limitation of excursion of the recording pens.

DISCUSSION

The interpolation of a cardiac catheter between the manometer and the origin of the pulse wave seriously interferes with the accuracy of the record. If, moreover, one adds to the inadequacies of the recording system the occurrence of artefacts in the tracings due to movements of the catheter at each heart beat, the distortion of the pulse wave may well be considerable. With these considerations in mind, therefore, the analysis of the pressure curves has been restricted entirely to the grosser changes in shape. In particular, no attempt has been made to analyse the tracings during diastole when the variations of pressure are less obvious and more certainly obscured by the inadequacies of the recording technique. Since, within these limits, clearly defined differences of contour have been found between the three main groups and since these differences have been constantly observed, it is thought that they must have a meaning. Indeed, if it be said that the peculiar shapes of the curves are due solely to "artefacts," it still has to be explained how, with a uniform technique, those artefacts vary so consistently between the three groups of patients.

Wiggers (1928) found that the curve of pressure most frequently recorded in the ventricles of animals was "characterised by a comparatively smooth contour and a rounded, arched summit." The shape of curve usually recorded in the patients with normal pulmonary valves in this series corresponds to a pattern that he found less commonly in animals. However, in manometric tracings taken during cardiac catheterization of the right ventricle in human subjects (Bloomfield *et al.*, 1946; Lenègre and Maurice, 1946; Sicot *et al.*, 1951) the shape of the curves in general corresponded to that described here. Often it is not possible to evaluate the shape of published pulse tracings where the scale of deflection is disproportionately large compared with the speed of the paper.

Wiggers (1927, 1928) has described the genesis of the pressure curve of ventricular contraction. Fundamentally it is due to the summation of a large number of minute contractions. If the semilunar valves were completely occluded one would therefore imagine that the resulting systolic curve in the ventricle would be a simple smooth hump such as is found in the isometric contraction of skeletal muscle, and this is in fact what is recorded during "ineffective" premature beats when the contraction of the ventricle is too feeble to open the valve (Wiggers, 1928) (Fig. 9 and 10). In a normal beat, this dome-shaped curve is modified by the opening and closing of the semilunar valves so that in the ejection phase the ventricle is no longer acting isometrically (Fig. 11). During this phase the right ventricle and pulmonary artery become a continuous chamber so that their curves of pressure are nearly identical. The shape of the curve during this part of ventricular contraction depends entirely upon the ratio between filling and emptying of the pulmonary arterial tree. Thus the pressure rises while the volume ejected by the right ventricle exceeds that which drains into the pulmonary capillaries.

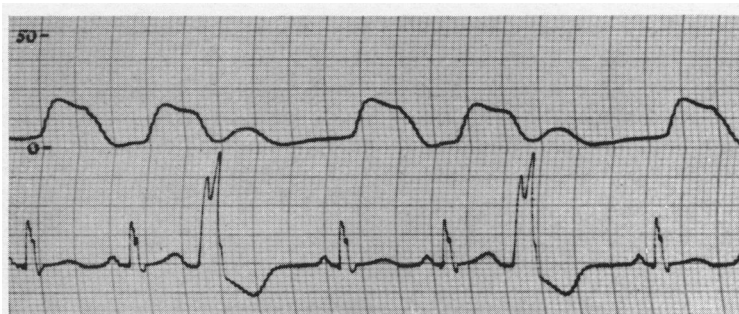


FIG. 10.—"Ineffective" ventricular premature beats. Tracings from the right ventricle of a child, aged eighteen months, with cardiomegaly of unknown ætiology.

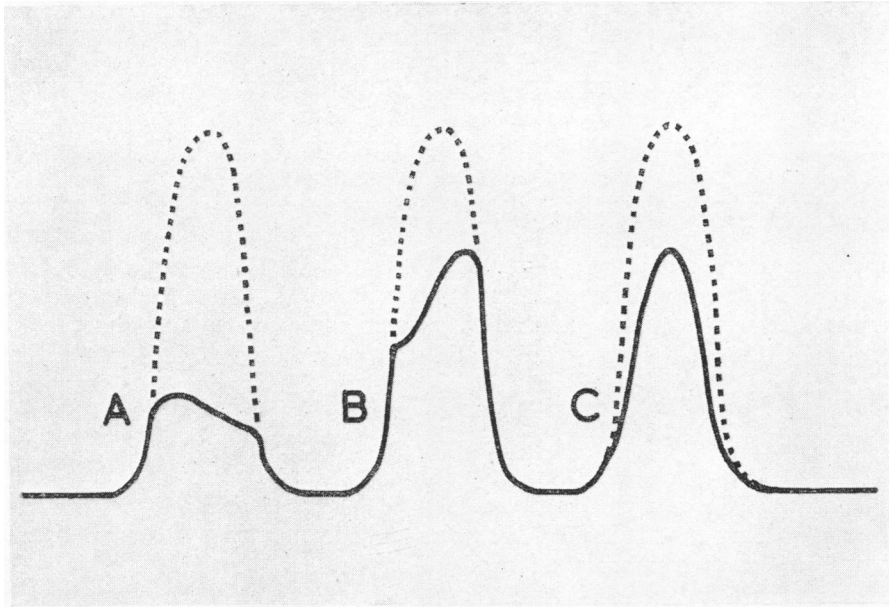


FIG. 11.—Diagram to show how the ideal isometric contraction curve of the right ventricle (represented by a dotted line) is modified by the presence of the pulmonary valves and by pulmonary stenosis. (A) Normal conditions; (B) Pulmonary hypertension; (C) Pulmonary stenosis.

Under normal conditions, pulmonary vascular resistance is low. This has a two-fold effect on the pressure curve of the right ventricle. In the first place it means that the pulmonary diastolic pressure is low and thus the isometric contraction phase of the right ventricle is of limited height. Secondly, it means that the rise in pulmonary artery pressure which follows the sudden rush of blood through the valve is rapidly high enough to cause pulmonary drainage to equal or exceed ventricular ejection. Thus, after a brief initial rise, the main slope of the ejection phase is usually slightly downward.

Conversely, when pulmonary vascular resistance is increased, the pulmonary diastolic pressure is high, so that the deflection of the isometric contraction phase of the right ventricular pulse is of greater amplitude. After the pulmonary valve has opened, the increased pulmonary vascular resistance impedes drainage from the pulmonary artery. Thus ventricular ejection comes to exceed pulmonary drainage for most of the ejection phase and the pressure mounts steadily in the right ventricle and pulmonary artery. As this phase continues, contraction gradually gives place to relaxation in the right ventricle so that the curve flattens to a summit and falls a little just prior to the closure of the pulmonary valve. The main slope of the ejection phase is therefore upward, and the summit comes towards the end, whereas in the normal group there is usually an early summit of low amplitude followed by a gradual slope downwards.

Wherever the pulmonary valve is normal, therefore, its opening and closing will cause sudden variations in the resistance to outflow of blood from the right ventricle and thus give rise to the angulations seen on the pressure tracings. When the valve is stenosed, however, the resistance to outflow from the right ventricle is constituted almost entirely by its rigid orifice. Pulmonary vascular resistance is low and can play only a negligible role since the pulse wave in the pulmonary artery becomes meagre and sometimes hardly distinguishable. Thus the resistance to outflow from the ventricle remains virtually constant throughout systole and the clear-cut divisions of the normal ventricular pulse wave are lost. The result is a smooth hump with its apex roughly central (Fig. 11). Such curves are shown by Mannheim (1949) and Soulié *et al.* (1952). In most of

the published tracings, however, the amplitude of the deflection is disproportionately great in relation to the speed of the recording paper so that a qualitative evaluation of the curves is difficult.

It is less easy to account for the type of curve found in the two cases of pulmonary infundibular stenosis. Clearly there is some variation in the resistance to the outflow of blood from the right ventricle. Where the stenosis is at the pulmonary valve this cannot occur, for the meatus is set in a diaphragm of rigid fibrous tissue. Here, however, the channel through the infundibulum is usually surrounded by muscle and it may be that it varies in calibre during contraction and relaxation of the heart. Alternatively, if the pulmonary valve is functioning normally, its opening and closing will cause wider variations of the pressure in the infundibulum. In this way a more pronounced and angular pulse wave will be formed in the infundibular chamber and this will be superimposed upon the curve of pressure in the main right ventricular chamber.

In one of the patients with infundibular stenosis the manometric tracings lend some support to this view (Fig. 6), although the accuracy of the recordings in the infundibulum must be more than ever doubtful. In this patient it seems likely that the pulmonary valve was functioning normally. It does not appear to be stenosed since the systolic pressure was found to average 14 mm. Hg equally in pulmonary artery and infundibulum. Moreover, the cusps seem to close efficiently, for the infundibular tracing leaves the pulmonary artery tracing abruptly in the vicinity of the second sound and rises to meet it again at the beginning of systole. In virtue of this, the pulse wave in the infundibular cavity is of sufficient dimensions to have a significant effect on the emptying pressures of the main right ventricular chamber. Fig. 6D shows that, if infundibular pressure is subtracted from right ventricular pressure from point to point throughout the cardiac cycle, the curve obtained is in fact of the type seen in pulmonary valvular stenosis. In other words, the right ventricular pulse wave due to the infundibular stenosis alone would be a smooth hump, but on top of this have to be added the variations of pressure in the infundibulum consequent on the presence of a functioning pulmonary valve. It is these variations that give the pulse wave its particular shape.

The observations made on patients with isolated ventricular septal defects permit of only tentative conclusions. Presumably the inter-ventricular communication allows the more vigorous beat of the left ventricle to be transmitted through to the right side. This may cause an increased acceleration of the blood expelled from the right ventricle in the early part of the systole. Such an increased acceleration acting against the inertia of the column of blood in the pulmonary arterial tree may account for the discrepancy between the right ventricular and pulmonary arterial pressures at this point of the cycle. It would also account for the fact that the change in the shape of the pulse wave during ejection may occur along the pulmonary artery and not necessarily at the pulmonary valve. Even with an intact septum the pulmonary artery pressure can often be seen to lag a little behind the right ventricular pressure for a brief moment following the opening of the pulmonary valves. This is more obvious in the cases with pulmonary hypertension. The discrepancy between the curves, however, has been nowhere so great as in these two cases. Dillon and Schreiber (1948) found an increase in right ventricular systolic pressure on opening an inter-ventricular shunt in animals but there was no alteration in the pressure curve. Joly *et al.* (1951) found the right ventricular systolic pressure to exceed the pulmonary artery systolic pressure by as much as 25 mm. Hg in two of their series of 21 patients with ventricular septal defect but do not mention whether this was associated with any particular contour of the pulse in the right ventricle. Similarly, one of the three patients with ventricular septal defect studied by Handelsman *et al.* (1948) had pressures of 72/3 and 49/20 mm. Hg in right ventricle and pulmonary artery respectively. It must be added, however, that Greene *et al.* (1949) found such a discrepancy in idiopathic dilatation of the pulmonary artery where there was no evidence of a ventricular septal defect.

In both of the patients with Eisenmenger's complex the right ventricular pulse wave was of the type seen in pulmonary hypertension. The ejection phase was found to correspond with the aortic tracing in one patient and with the pulmonary artery tracing in the other. Unfortunately in neither instance were both great vessels entered. In many previously published cases the systolic

pressures in pulmonary artery and right ventricle have been shown to be identical (Bing *et al.*, 1947; Dexter *et al.*, 1950; Soulié *et al.*, 1950; Cosby *et al.*, 1951; Goldberg *et al.*, 1951), while the systolic pressures in right ventricle and aorta were found to be identical by Cosby *et al.* (1951) and Voci *et al.* (1952). The case reported by the last authors is unique in the completeness of its physiological data and the systolic pressures in aorta, pulmonary artery, and both ventricles were shown to be the same. It seems probable, therefore, that in Eisenmenger's complex the shape of the pressure tracing during the ejection phase is identical in both great vessels and both ventricles. The right ventricular systolic pressure curves shown in the cases of Goldberg *et al.* (1951) and Voci *et al.* (1952) and in Fig. 23 of the paper of Soulié *et al.* (1950) all show the features here described as characteristic of pulmonary hypertension, and the ejection phase appears to be shaped by the curve of pressure in the great vessels.

Too few patients with Fallot's tetrad have been studied to warrant inclusion in this report, since the right ventricular pulse wave in this condition seems to vary in shape from case to case. Indeed, with all the varying degrees of dextroposition of the aorta and size of ventricular septal defect, and with the different types and degrees of pulmonary stenosis, one would hardly expect the curve to have a constant and characteristic appearance.

SUMMARY

A study has been made of the right ventricular systolic pulse wave recorded during cardiac catheterization.

Where the pulmonary valve is normal, the shape of the wave is modified during the ejection phase and corresponds with the curve of pressure in the pulmonary artery. Differences in this shape are noted between patients with normal and patients with high pressure in the pulmonary artery. The presence of pulmonary valvular stenosis converts the pulse wave into a smooth rounded hump. With pulmonary infundibular stenosis this is not so.

Similar studies on three patients with ventricular septal defects, and two with Eisenmenger's complex are described.

My thanks are due to the physicians of King's College Hospital who have kindly allowed me to study their patients. In particular I am grateful to Dr. Terence East and Dr. Samuel Oram for their advice and encouragement. I am also indebted to Dr. J. L. V. Summerhayes and Miss G. M. Maxted for their help.

REFERENCES

- Bareham, F. R. (1954). To be published.
 Bing, R. J., Vandam, L. D., and Gray, F. D., Jr. (1947). *Bull. Johns Hopk. Hosp.*, **80**, 323.
 Bloomfield, R. A., Lawson, H. D., Cournand, A., Breed, E. S., and Richards, D. W. (1946). *J. clin. Invest.*, **25**, 639.
 Cosby, R. S., Levinson, D. C., Griffith, G. C., Zinn, W. J., and Dimitroff, S. P. (1951). *Amer. J. Med.*, **11**, 31.
 Dexter, L., Dow, J. W., Haynes, F. W., Whittenberger, J. L., Ferris, B. G., Goodale, W. T., and Hellemers, H. K. (1950). *J. clin. Invest.*, **29**, 602.
 Dexter, L., Haynes, F. W., Burwell, C. S., Eppinger, E. C., Sagerson, R. P., and Evans, J. M. (1947). *J. clin. Invest.*, **26**, 554.
 Dillon, W. H., and Schreiber, H. (1948). *Amer. J. Physiol.*, **154**, 281.
 Goldberg, H., Silber, E. N., Gordon, A., and Katz, L. N. (1951). *Circulation* (N.Y.), **4**, 343.
 Greene, D. G., Baldwin, E., Baldwin, J., Himmelstein, A., Rob, C., and Cournand, A. (1949). *Amer. J. Med.*, **6**, 24.
 Handelsman, J. C., Bing, R. J., Campbell, J. A., and Griswold, H. E. (1948). *Bull. Johns Hopk. Hosp.*, **82**, 615.
 Holling, H. E., and Zak, G. A. (1950). *Brit. Heart J.*, **12**, 153.
 Joly, F., Carlotti, J., and Sicot, J. R. (1951). *Arch. Mal. Coeur*, **44**, 602.
 Lagerlöf, H., and Werkö, L. (1948). *Acta physiol. scand.*, **16**, 75.
 Lenègre, J., and Maurice, P. (1946). *Arch. Mal. Coeur*, **39**, 24.
 Mannheimer, E. (1949). *Arch. Dis. Childh.* **24**, 264.
 Sicot, J. R., Joly, F., and Carlotti, J. (1951). *Sem. Hôp. Paris*, **27**, 1653.
 Soulié, P., Joly, F., Carlotti, J., Sicot, J. R., and Voci, G. (1952). *Arch. Mal. Coeur*, **45**, 385.
 —, P., Nouaille, J., Schwaisguth, O., Joly, F., Carlotti, J., and Sicot, J.-R. (1950). *Bull. Soc. méd. Hôp. Paris*, **66**, 1147.
 Voci, G., Joly, F., and Carlotti, J. (1952). *Bull. Soc. méd. Hôp. Paris*, **68**, 636.
 Wiggers, C. J. (1927). *Amer. J. Physiol.*, **80**, 1.
 —, (1928). *The Pressure Pulses in the Cardiovascular System*. Longmans, Green and Company, London.
 Wood, P. (1950). *Brit. med. J.*, **2**, 639.