

# EISENMENGER'S COMPLEX

BY

JAMES W. BROWN, DONALD HEATH,\* AND WILLIAM WHITAKER

*From the Regional Cardio-Vascular Centre, City General Hospital and the University Department of Medicine,  
Royal Hospital, Sheffield*

Received November 4, 1954

Following the description by Eisenmenger in 1897 of a cyanosed man, aged 32, with a ventricular septal defect and dextroposition of the aorta without pulmonary stenosis, Abbott (1927) termed this the Eisenmenger type of congenital anomaly. Since that time a diagnosis of Eisenmenger's complex has become well established for those rare cases of cyanotic congenital heart disease with ventricular septal defect and dextroposition of the aorta without pulmonary stenosis. Although it may be difficult to differentiate this complex anatomically from ventricular septal defect with pulmonary hypertension and right ventricular hypertrophy on the one hand, and from partial transposition of the great vessels with overriding aorta on the other, it appears worthwhile preserving the term Eisenmenger's complex as a diagnosis in cyanosed patients with an overriding aorta but without pulmonary stenosis.

Clinical, electrocardiographic, and radiological findings in seven such patients are presented below together with the results of angiocardiography and cardiac catheterization. Autopsy findings were available in one patient. These patients were selected according to the criteria described above, but it became obvious from further examination that they all had in addition clinical evidence of pulmonary hypertension. Indeed, the clinical picture common to all patients with Eisenmenger's complex is one of cyanotic congenital heart disease with pulmonary hypertension.

TABLE I  
CLINICAL FEATURES OF 7 PATIENTS WITH EISENMENGER'S COMPLEX

Case No.	Age and sex	Systemic blood pressure (mm. Hg)	Central cyanosis*	Cardiac murmurs
1	16 F	110/70	On exertion*	Soft systolic murmur at apex and in tricuspid area
2	16 F	110/85	Slight	Basal diastolic murmur
3	14 F	115/90	Slight	Soft apical systolic murmur
4	50 M	155/125	Marked	None
5	26 M	140/100	Slight	None
6	26 F	115/75	Slight	None
7	26 M	110/60	Slight	None

\* The fingers were clubbed in all except Case 1.

*Symptomatology.* The dominant symptom in all seven patients was progressive breathlessness on exertion which usually appeared first during adolescence. In Case 7 dyspnoea on exertion was

\* Leverhulme Research Scholar, Royal College of Physicians.

first noticed when the patient was ten years old but there was a progressive increase in its severity from the age of eighteen years until his death at the age of twenty-four.

Blueness of the lips had been noticed in cold weather by all but one of the patients (Case 6) and Case 2 had observed the cyanosis to be worse on exertion. Only in Case 4 was the cyanosis present before adolescence and in this patient it was noted at birth.

Case 1 occasionally had syncopal attacks on standing. Two other patients (Cases 2 and 4) complained of giddiness but had not at any time had attacks of unconsciousness.

Hæmoptysis occurred in Cases 5, 6, and 7. In the latter this appeared at the age of seven years and when cough and breathlessness on exertion later developed he was suspected of having tuberculosis. He had further hæmoptyses at the age of twenty-one and one month before his death.

Cases 5, 6, and 7 had chronic unproductive coughs while Case 1 had a productive cough. Two patients (Cases 1 and 3) complained of aching, præcordial pain unrelated to exertion. Case 5 had noticed finger clubbing and complained of palpitation.

*Signs.* All the patients had clinical evidence of pulmonary hypertension judged from giant "a" waves in the jugular venous pulse, a palpable second pulmonary sound, a systolic lift over the right ventricular outflow tract, a right ventricular heave, and a loud split second pulmonary sound. The other clinical features are shown in Table I.

*Electrocardiography.* The cardiogram showed the ventricular pattern of right ventricular hypertrophy and clockwise rotation of a vertical heart (Fig. 1) in all except Case 4 where systemic hypertension was present and there was clockwise rotation of a horizontal heart but no cardiographic evidence of right or left ventricular dominance.

*Radiological Examination.* The postero-anterior telerradiograms of six of the present group of patients are reproduced in Fig. 2, 3, and 4. Right ventricular hypertrophy was present in all cases and the other radiological features are summarized in Table II.

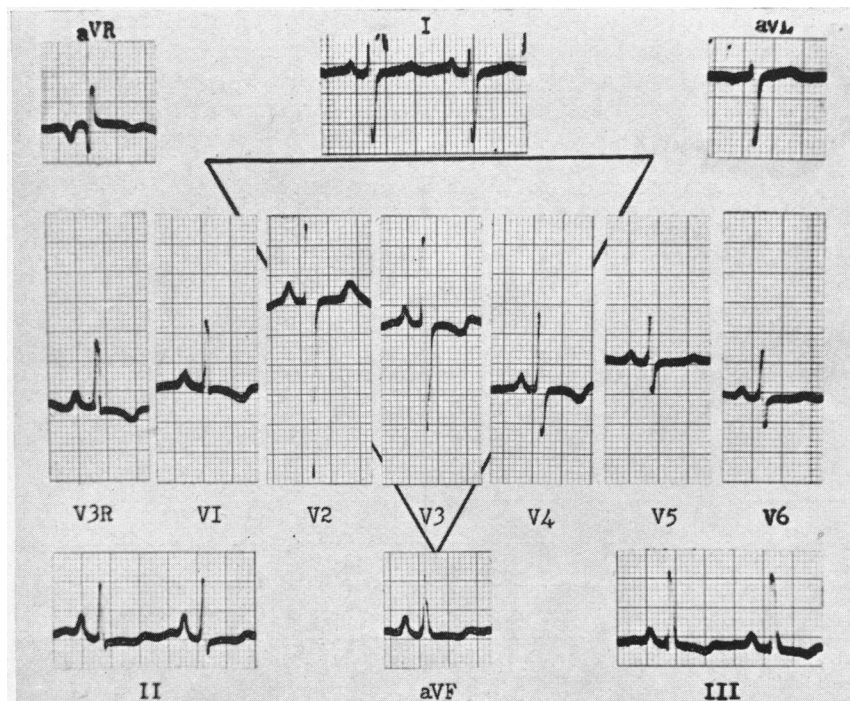


FIG. 1.—Case 6. Electrocardiogram showing ventricular pattern of right ventricular hypertrophy and clockwise rotation of a vertical heart. Similar electrocardiograms were recorded in the other cases with the exception of Case 4.

TABLE II  
RADIOLOGICAL FEATURES OF 7 PATIENTS WITH EISENMENGER'S COMPLEX

Case No.	Cardiac enlargement	Prominence of pulmonary artery and main branches	Increased pulsation of pulmonary arteries
1	Marked	Moderate	Absent
2	Slight	Moderate	Absent
3	None	Moderate	Present
4	Slight	Slight	Present
5	Moderate	Moderate	Present
6	Slight	Slight	Present
7	Slight	Moderate	Absent

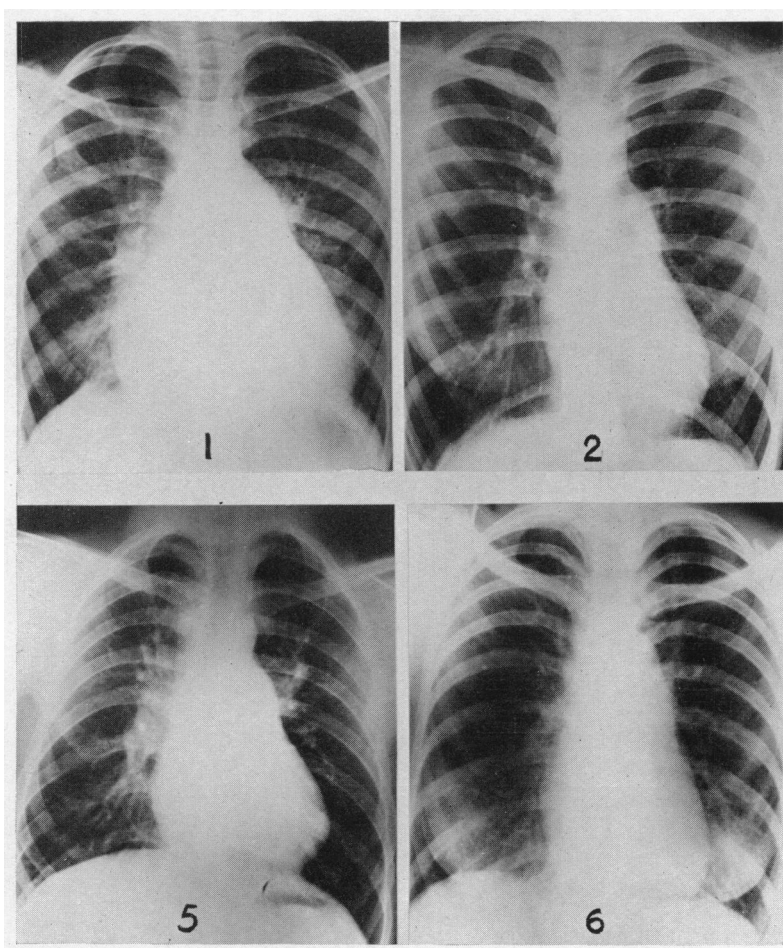


FIG. 2.—Postero-anterior teleradiograms of four patients (Cases 1, 2, 5, and 6) with Eisenmenger's complex.

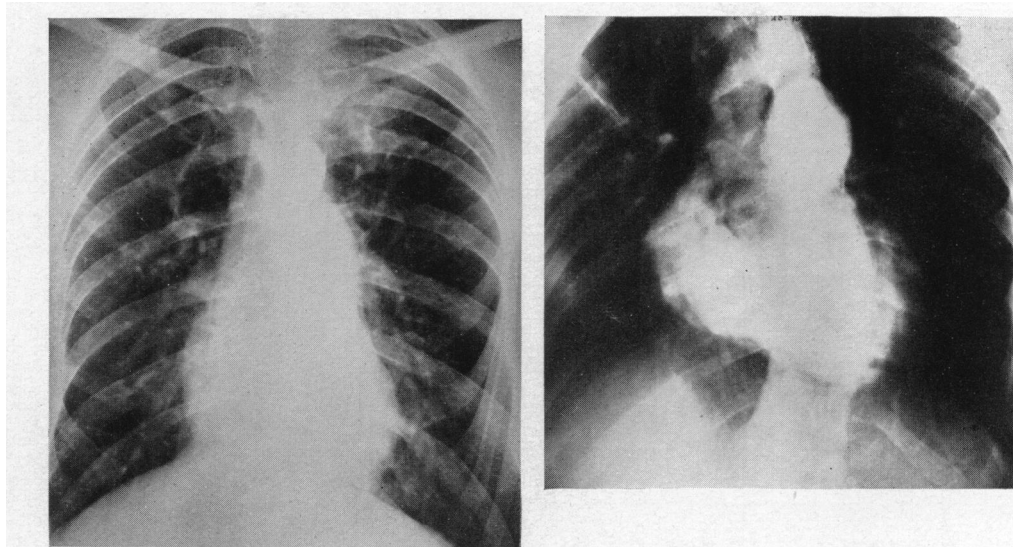


FIG. 3.—Case 7. The antero-posterior angiogram, reproduced on the right, shows simultaneous filling of the pulmonary arteries and the ascending aorta from the right ventricle 3 sec. after the injection of the contrast medium. The postero-anterior teleradiogram is shown on the left.

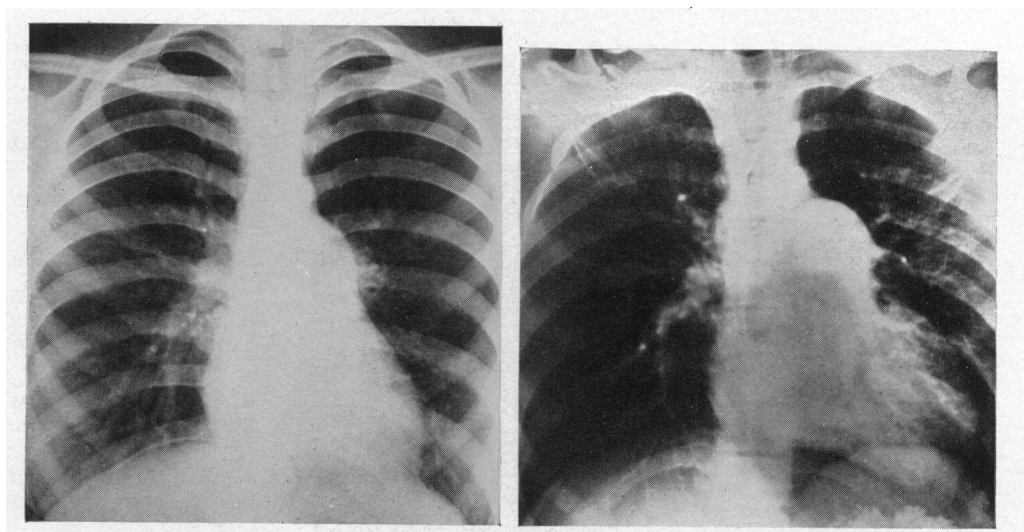


FIG. 4.—Case 3. The antero-posterior angiogram, reproduced on the right, shows simultaneous filling of the pulmonary arteries and the ascending aorta from the right ventricle 3 sec. after the injection of the contrast medium. The postero-anterior teleradiogram is shown on the left.

*Angiocardiography.* Angiocardiographic examination was carried out in all seven patients. In each one there was simultaneous early filling of the ascending aorta and pulmonary artery by contrast medium from the right ventricle, indicating that there was an overriding aorta (Fig. 3 and 4). In all, the pulmonary artery and its main branches were dilated and there was no evidence of pulmonary stenosis. A patent ductus arteriosus was subsequently demonstrated in Case 6 by cardiac catheterization. This patient has already been reported by Whitaker *et al.* (1955) as a case of patent ductus arteriosus with severe pulmonary hypertension associated with an overriding aorta, since it was considered that the density of the contrast medium in the ascending aorta was

too great to be due to regurgitation of dye entering the aorta through the patent ductus (Fig. 6, Whitaker *et al.*, 1955).

*Cardiac Catheterization.* Cardiac catheterization was carried out in six patients. In all these the tip of the catheter was passed into the pulmonary artery. Pressures were recorded and blood samples taken as the catheter was withdrawn through the cardiac chambers. Results of these observations are shown in Table III. In Case 6 the tip of the cardiac catheter passed through a patent ductus arteriosus into the descending aorta.

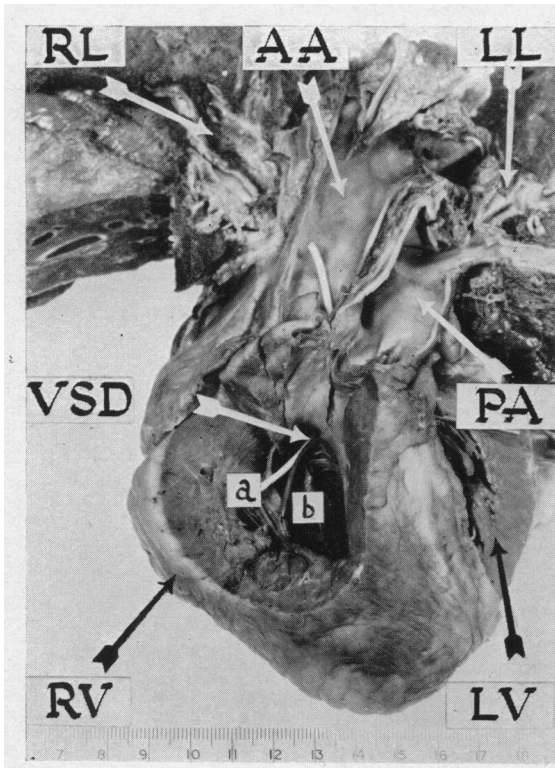


FIG. 5.—Case 7. The light indicator (*a*) has been passed from the hypertrophied right ventricle behind the crista supraventricularis into the overriding ascending aorta. The dark indicator (*b*) has been passed from the right ventricle through a ventricular septal defect in the membranous part of the septum into the left ventricle. RL=Right lung. LL=Left lung. AA=Ascending aorta. PA=Pulmonary artery. VSD=Ventricular septal defect. RV=Right ventricle. LV=Left ventricle.

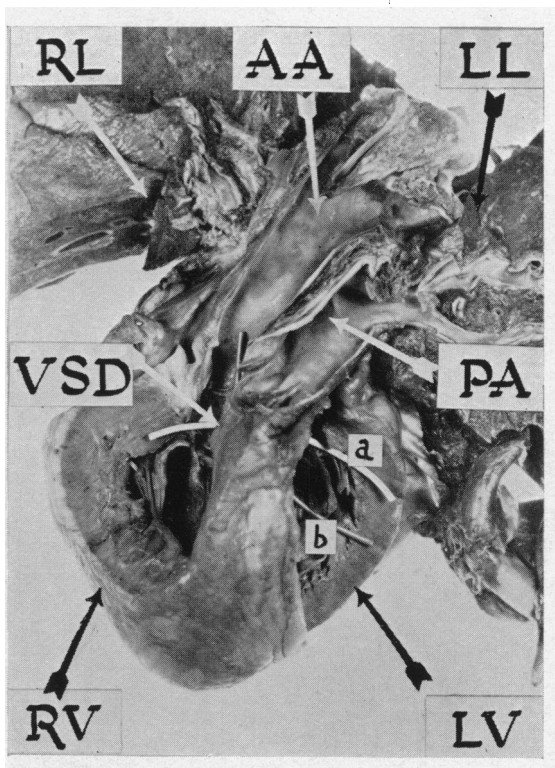


FIG. 6.—The light indicator (*a*) has been passed from the right ventricle through a ventricular septal defect in the membranous part of the septum into the left ventricle. The dark indicator (*b*) has been passed from the left ventricle into the ascending aorta and in this case the crista supraventricularis has been removed (Case 7). RL=Right lung. LL=Left lung. AA=Ascending aorta. PA=Pulmonary artery. VSD=Ventricular septal defect. RV=Right ventricle. LV=Left ventricle.

#### NECROPSY FINDINGS IN CASE 7

The heart was enlarged mainly due to hypertrophy of the right ventricle. The thickness of the right ventricular wall was 12 mm. and that of the left 8 mm. There was an overriding aorta and a high ventricular septal defect which was concealed behind a much hypertrophied crista supraventricularis. The aorta took origin from both ventricles. The origins of the coronary arteries were abnormal. The right arose from the anterior aortic cusp and the left from the right posterior cusp. There was no patent ductus arteriosus nor atrial septal defect and the aortic arch was left-sided. There were flecks of atheroma on the pulmonary artery (Fig. 5 and 6).

On histological examination of the elastic intrapulmonary arteries atheroma was noted in the

intima. The muscular pulmonary arteries (1–0.1 mm.) showed widespread severe changes consisting of medial hypertrophy and obliteration of the lumen by fibrous tissue which had proliferated from the sub-intimal region. The elastic laminæ were thick and wavy in appearance. The arterioles showed similar changes to these in the media and intima. The small pulmonary veins appeared to be normal with no evidence of thrombosis or sclerosis (Fig. 7 and 8).

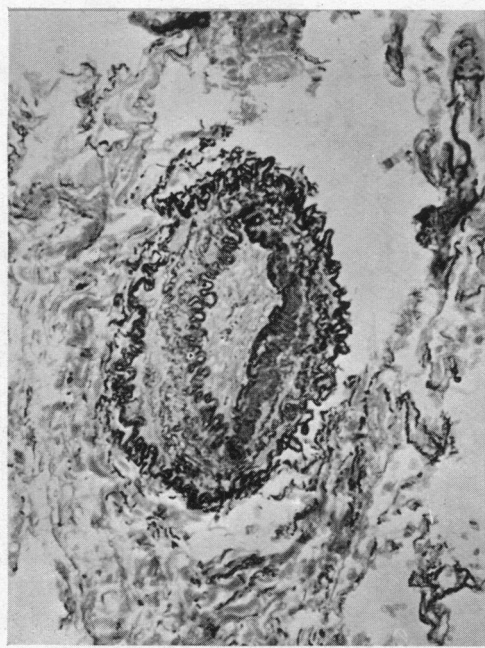


FIG. 7.—Transverse section of muscular pulmonary artery. There is proliferation of fibrous tissue in the intima. The media is hypertrophied and both elastic laminæ are thick. The lumen has been obliterated (Case 7). Stained with Verhoeff/Van Gieson. Magnification,  $\times 178$ .

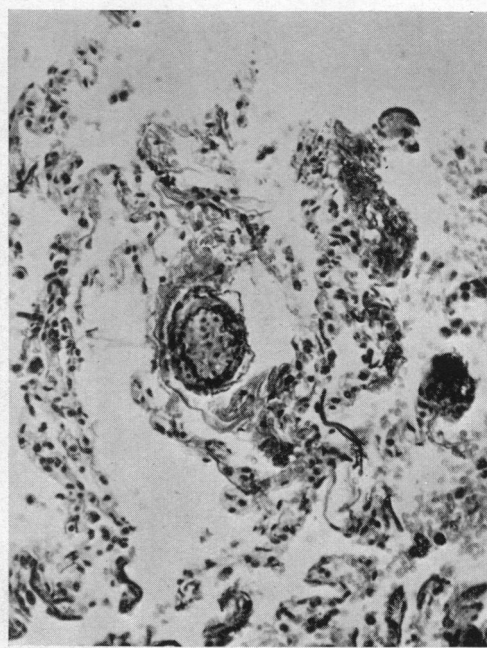


FIG. 8.—Transverse section of pulmonary arteriole. There is proliferation of intimal fibrous tissue, obliterating the lumen. The media is hypertrophied (Case 7). Stained with Verhoeff/Van Gieson. Magnification,  $\times 178$ .

#### DISCUSSION

*Symptomatology.* Progressive dyspnoea on exertion from adolescence is one of the major symptoms of this anomaly. In all our patients and in one reported by Hurst and Schemm (1948) the symptoms first appeared during adolescence but in another patient reported by Bond (1951) it was already present at the age of three and a half years. From a histological study of the pulmonary arteries in a child of eleven months with Eisenmenger's complex, Edwards (1954) believes that the onset of dyspnoea is related to the development of intimal changes in the pulmonary arteries from pulmonary hypertension.

In Bond's (1951) review of 18 patients with Eisenmenger's complex neither hæmoptysis nor cough were noted. This is unexpected since both are common complaints when pulmonary hypertension complicates other anomalies such as patent ductus arteriosus and mitral stenosis. However, three of the present patients had hæmoptysis and four had chronic cough, and these symptoms, which are probably manifestations of abnormally high pulmonary vascular blood pressures, appear to be characteristic but not diagnostic of Eisenmenger's complex.

Although syncopal attacks occurred in one of our patients they may have been coincidental since there appears to be no obvious explanation of these.

Hoarseness and aphonia were present in cases reported by Baumgartner and Abbott (1929)



and by Millman and Kornblum (1936) and were considered to be due to the pressure of the dilated pulmonary vessels on the recurrent laryngeal nerve. None of our patients had such symptoms and the explanation probably is that none of them had extreme dilatation of the pulmonary arteries such as has been noted by Campbell (1951) in Eisenmenger's complex.

*Signs.* Although Bing's (1947) observations show that pulmonary hypertension occurs in Eisenmenger's complex, it has not been stressed that the clinical manifestations of this state are a feature of the complex. However, since pulmonary hypertension was recognized from its classical clinical signs in all patients in the present series such signs must be considered characteristic but not diagnostic of Eisenmenger's complex.

All the patients in the present series had central cyanosis since it is by definition a feature of the anomaly. This had been present from birth in Case 4 and was marked in this patient. In the others, the cyanosis developed during adolescence and was always slight. Such a late onset of cyanosis appears to be a common feature of Eisenmenger's complex and has been noted previously by Stewart and Crawford (1933) and by Bond (1951). However, early onset of cyanosis does not exclude the diagnosis since it was present at birth in a patient reported by Glazebrook (1943) and in Case 4 of the present series. Abbott (1927) and Taussig and Semans (1940) diagnosed Eisenmenger's complex in patients who were not cyanosed. Although, as the present series shows, most patients who eventually fulfil the criteria for a diagnosis of Eisenmenger's complex are acyanotic for many years, it is difficult in the acyanotic phase to recognize an overriding aorta which is an essential component of the complex. Before the onset of cyanosis such cases are indistinguishable from patients with ventricular septal defect and pulmonary hypertension unless there is sufficient shunt into the aorta from the right ventricle for this to be evident on angiocardiology. The late onset of cyanosis is more probably related to the development of polycythæmia than to any great change in the magnitude of the shunt from right ventricle to aorta, since even in patients with frank central cyanosis there is not a severe degree of arterial oxygen unsaturation (Table III). Bond (1951) states that polycythæmia is uncommon in this condition but the present series indicates that there may be a severe degree of polycythæmia in some patients (Table III).

TABLE III  
RESULTS OF CARDIAC CATHETERIZATION IN 6 PATIENTS WITH EISENMENGER'S COMPLEX

Case No.	Blood hæmoglobin content (g. per 100 ml.)	Hæmatocrit	Blood oxygen percentage saturation						Pulmonary artery blood pressure (mm. Hg)
			Superior vena cava	Inferior vena cava	Right atrium	Right ventricle	Pulmonary artery	Arterial	
1	12.9	50	35	45	36	31	34	95	130/80
2	16.0	49	71	72	69	76	71	82	90/55
3	16.0	47	71	75	68	72	72	87	75/40
5	15.9	54	71	62	71	70	71	91	135/75
6	18.1	58	70	71	70	71	75		125/80
7	19.5	60	—	—	76	—	75	92	Mean 90

Case 4 was not investigated by cardiac catheterization. In this case, the blood hæmoglobin content was 17 g. per 100 ml. and the hæmatocrit 68 per cent. He has died since this paper was written and necropsy confirmed the diagnosis.

It was shown by Burwell (1942) that the arterial oxygen saturation increased when pure oxygen was breathed. This, they believed, indicated that cyanosis was in part produced by incomplete oxygenation of blood in the lungs due to a congenital abnormality of the pulmonary epithelium or capillaries. If incomplete æration of the blood in the lungs were a cause of the arterial blood

oxygen unsaturation it would be expected that there would also be carbon dioxide retention, of which Platts and Whitaker (1954) found no evidence. Voci *et al.* (1952) and Goldberg *et al.* (1951) obtained pulmonary venous blood samples in patients with Eisenmenger's complex and found that the oxygen saturation of the samples was normal. The former authors obtained these blood samples by passing a cardiac catheter through an associated atrial septal defect while the latter observers catheterized anomalous pulmonary veins entering the right atrium. It seems that the unsaturation of arterial blood is due entirely to mixed venous blood entering the aorta from the right ventricle.

Previous authors have emphasized the importance of a left parasternal systolic murmur in the diagnosis of Eisenmenger's complex. A systolic murmur, maximal in the second to fourth left intercostal spaces, was noted in 14 of the 18 cases reviewed by Bond (1951) who considered that a systolic murmur should be expected in every case. However, as 5 of the 7 patients in the present series had no systolic murmurs and 4 of these no murmurs at all, it is impossible to attach great diagnostic importance to a systolic murmur, especially as this was insignificant in the two patients where it was present (Table I). It must be emphasized that a parasternal systolic murmur is not an essential feature and not even a common feature of the clinical picture of Eisenmenger's complex. In view of this it seems relatively unimportant to discuss the radiation of such murmurs in their differentiation from the murmurs of Fallot's tetralogy as has been done previously by Bond (1951), who believes that the systolic murmur of Fallot's tetralogy radiates to the neck whereas that in Eisenmenger's complex does not. Such difference in radiation as exists is most probably related to the intensity of the murmur which is usually greater in the tetralogy. However, in cases such as that of Wood (1950), where there was a basal systolic murmur of such intensity as to produce a thrill in the third left intercostal space, any real difference in radiation would be of diagnostic importance.

*Electrocardiography.* Bond (1951) found left axis deviation in one case of Eisenmenger's complex and stated that the usual cardiographic findings are normal or left axis deviation or occasionally right axis deviation. However, more recently Wood (1950), Kaplan and Robinson (1954), and Edwards *et al.* (1954) have emphasized that cardiographic evidence of right ventricular hypertrophy is a feature of the anomaly. This latter view is in accord with the findings in the present series where all the patients except Case 4, who had systemic hypertension, showed cardiographic evidence of right ventricular hypertrophy and clockwise rotation of a vertical heart. Unless there is some obvious cause why there should not be a right ventricular dominance such as systemic hypertension the absence of electrocardiographic evidence of right ventricular hypertrophy excludes a diagnosis of Eisenmenger's complex.

*Radiological Examination.* In the present series dilatation of the pulmonary arteries has not been of the extreme degree usually considered characteristic of Eisenmenger's complex and in none of the patients was there gross prominence of the pulmonary arteries such as is seen occasionally in patients with atrial septal defect or mitral stenosis with severe pulmonary hypertension (Table II, and Fig. 2, 3, and 4). However, it cannot be questioned that Eisenmenger's complex may be associated with gross dilatation of the pulmonary arteries since Campbell (1951) found that patients with this anomaly had the largest pulmonary arteries.

Abnormal pulsation of the pulmonary arteries is not of diagnostic importance since three of the seven patients in the present series had normal pulsation while none of the others had a hilar dance (Table II).

*Angiocardiography.* Angiocardiography demonstrates the overriding aorta and allows Eisenmenger's complex to be differentiated from other abnormalities presenting with cyanosis and pulmonary hypertension and for this reason is probably the most important diagnostic investigation (Fig. 3 and 4). Although no patients were studied before the development of cyanosis, it appears possible to diagnose the lesion in the acyanotic phase if an overriding aorta is demonstrated by angiocardiography. If in such a phase there is insufficient shunting from the right ventricle into the ascending aorta for the contrast medium to show on the angiocardiogram it is impossible



to diagnose Eisenmenger's complex. Such patients will then probably be diagnosed as having pulmonary hypertension and ventricular septal defect from the results of cardiac catheterization.

*Cardiac Catheterization.* Severe pulmonary hypertension, with blood pressures similar to those in the systemic arteries, can be demonstrated by cardiac catheterization in Eisenmenger's complex (Table III). Patients with Fallot's tetralogy with loud or palpable second sounds in the pulmonary area, who, on clinical examination alone, may be thought to have pulmonary hypertension, can be easily diagnosed by this investigation. However, other congenital anomalies such as atrial septal defect, ventricular septal defect, and patent ductus arteriosus associated with pulmonary hypertension and reversal of flow may not be distinguished from Eisenmenger's complex by cardiac catheterization unless the catheter passes through the defect. Although Bing's (1947) findings at cardiac catheterization in patients with Eisenmenger's complex showed that there was usually evidence of some left-to-right flow through the ventricular septal defect, with mixing of the blood in the right ventricle, there was no evidence of this in the present series, where in every patient all the samples from the right side of the heart showed similar oxygen saturations (Table III). It is apparent from the results obtained at cardiac catheterization in this series that examination of blood oxygen saturations is of little diagnostic importance. Compared with angiocardiology cardiac catheterization is not such an important diagnostic procedure.

*Pathology.* The anatomical components of Eisenmenger's complex have been defined by Edwards (1954) as a high ventricular septal defect in the membranous part of the septum, dextro-position of the aorta so that it arises from both ventricles above the septal defect or from the right ventricle alone, absence of pulmonary stenosis with a normal or dilated pulmonary artery, and characteristic changes in the pulmonary vascular tree. The pathological features that may occur in a patient fulfilling the criteria for a diagnosis of Eisenmenger's complex in life are not capable of more rigid definition although this includes at one extreme a ventricular septal defect with pulmonary hypertension, right ventricular hypertrophy, and an overriding aorta and at the other extreme a moderate degree of transposition of the great vessels. Lev (1953), recognizing this, subdivides Eisenmenger's complex anatomically into Eisenmenger's complex with overriding aorta and the Eisenmenger's type of transposition, as in Case 7 of the present series where there was an abnormal origin of the coronary arteries.

The pulmonary artery always arises from the right ventricle distinguishing this condition from more severe degrees of transposition. The pulmonary valves are usually normal in structure and number although Lavenne *et al.* (1954) have described associated pulmonary insufficiency due to an absence of the pulmonary valves. The pulmonary arteries are usually larger than the aorta and this is probably due to pulmonary hypertension. Such dilatation of the pulmonary arteries was noted at autopsy examination in Case 7. Calcification of the pulmonary cusps may occur (Stewart and Crawford, 1933) and infective endocarditis of the pulmonary valves has been described (Abbot, 1927; Millman and Kornblum, 1936; and Bedford and Parkinson, 1936).

The aorta may be hypoplastic although in Case 7 of this series it was normal. The aortic valves are usually normal in number but may be deformed (Eisenmenger, 1897; and Hurst and Schemm, 1948) and this may lead to aortic incompetence. The aorta may arise from both ventricles or preponderantly from the right ventricle (Barlow, 1876; Schramm, 1929; and Saphir and Lev, 1941).

Other congenital abnormalities of the heart may be associated with this complex. Bond (1951) in a review of lesions associated with Eisenmenger's complex pointed out that the following had been reported: atrial septal defect, patent ductus arteriosus, right-sided aorta, anomalous origin of vessels from the aortic arch, patent foramen ovale, coarctation of the aorta, and anomalous coronary artery distribution. In Case 6 of the present series an associated patent ductus arteriosus was demonstrated at cardiac catheterization. Brown (1950) thought that the general appearance of the heart in Eisenmenger's complex suggested that the conus and the pulmonary artery had developed normally and that the endocardial cushions of the atrial canal had, in the main, fulfilled their correct function. Rosedale (1935) considered that failure of the lower part of the bulbar arches to fuse and consequent failure of the aortic vestibule to be shifted to the left resulted in dextroposition

of the aorta. Edwards (1954) pointed out that when a probe is passed from the right ventricle through the membranous part of the ventricular septum in a normal heart it enters the ascending aorta and with any defect of the membranous septum the aorta would consequently override both ventricles. It seems probable that right ventricular hypertrophy accentuates the overriding and is largely responsible for the dextroposition of the aorta in those cases where there is no evidence of abnormal rotation of the great vessels. Right ventricular hypertrophy also produces in Eisenmenger's complex a well marked crista supraventricularis, which in Case 7 of the present series separated the conus of the right ventricle from the ventricular septal defect and origin of the aorta (Fig. 5).

The extensive changes that occurred in the muscular pulmonary arteries and the arterioles in Case 7 of this series (Fig. 7 and 8) are typical of those reported by previous observers. The combination of medial hypertrophy and intimal proliferation was noted as early as 1933 by Stewart and Crawford but their patient was aged sixty and was suffering from syphilis and it was difficult to be sure of the aetiology of the changes. Civin and Edwards (1950) noted medial hypertrophy in a child, aged eleven months, who had Eisenmenger's complex. They postulated that the medial hypertrophy was due to a persistently increased muscular tone in the pulmonary vessels and considered that this was a protective function to diminish the excessive blood flow to the lungs, which they compared to the state present in the foetus where the right ventricle pumps blood into both systemic and pulmonary circulations and where the resistance to flow in the latter is high to prevent flooding of the lungs. They believe that the muscular hypertrophy leads to a diminution in diameter of the pulmonary vessels with a resultant increase in pulmonary pressure. The induced pulmonary hypertension brings about further intimal proliferation with a still greater reduction in the diameter of the lumen of the vessel and a still greater increase in pulmonary artery pressure. Edwards (1954) noted that the same problems were involved in cor triloculare biatriatum, persistent runcus arteriosus with big pulmonary arteries, and coarctation of the aorta with a patent ductus arteriosus in which the ductus enters the aorta distal to the coarctation. Old and Russell (1950) described similar histological findings in a boy, aged eleven, without Eisenmenger's complex but also noted the presence of arterial necrosis.

#### DIFFERENTIAL DIAGNOSIS

The differential diagnosis of the present anomaly is from other cyanotic conditions associated with pulmonary hypertension. A long history of recurrent pulmonary infection and signs of pulmonary hypertension and cyanosis may suggest a diagnosis of chronic pulmonary heart disease but, as pointed out by Platts and Whitaker (1954), the absence of carbon dioxide retention will exclude this.

Patients with an atrial septal defect complicated by pulmonary hypertension and reversal of the flow through the defect, will have more marked cardiac enlargement and larger pulmonary arteries than the patients in the present series, but may be confused with those patients with Eisenmenger's complex having extreme dilatation of the pulmonary arteries. Angiocardiography will clearly demonstrate the septal defect for, when there is reversal of flow, there is early filling of the left atrium by contrast medium. In such cases the cardiac catheter usually passes with ease through the septal defect.

The differentiation of the present anomaly from ventricular septal defect with pulmonary hypertension where the defect is in the membranous part of the septum is a problem of definition. Where the right ventricular pressures are sufficiently high to cause blood to pass from the right ventricle into the aorta, which may be evident on angiocardiographic examination or from the presence of cyanosis, such patients fulfil the criteria for a diagnosis of Eisenmenger's complex. When there is a ventricular septal defect in the muscular part of the septum complicated by pulmonary hypertension so that the dominant flow is from the right to the left ventricle, it may be possible to recognize that such patients have not an overriding aorta from early filling of the left ventricle on angiocardiography.

Patent ductus arteriosus with severe pulmonary hypertension and reversal of the flow can be differentiated from the present anomaly by angiocardiology and cardiac catheterization. Angiocardiograms in patients with Eisenmenger's complex show early filling of the overriding aorta while in patients with patent ductus arteriosus and severe pulmonary hypertension there is usually early filling of the descending aorta from the pulmonary artery. On cardiac catheterization it is usually possible to pass a catheter through the ductus when this is associated with severe pulmonary hypertension and reversal of flow. The problem of differentiation may, however, be impossible since it is apparent that an overriding aorta and patent ductus arteriosus may co-exist in cyanotic patients with pulmonary hypertension as in Case 6 in the present series.

Since the majority of patients with Eisenmenger's complex develop cyanosis during adolescence, there is rarely any difficulty in differentiating this anomaly from transposition of the great vessels where cyanosis is present from birth. However, in those patients with Eisenmenger's complex who are cyanosed from birth such a differentiation is necessary and can usually be made from the lateral angiocardiology when the diagnosis of transposition is made if the pulmonary artery appears to arise from the left ventricle.

Since many of the patients with Eisenmenger's complex present no sign other than those of cyanosis and pulmonary hypertension they may be regarded from clinical, electrocardiographic, and radiological examination as cases of primary pulmonary hypertension. The true nature of the congenital anomaly will become apparent when an overriding aorta is demonstrated by angiocardiology.

Patients with Fallot's tetralogy with loud and even palpable sounds in the pulmonary area may be considered, on clinical examination, to have cyanotic congenital heart disease and pulmonary hypertension and, possibly, Eisenmenger's complex. Such patients, however, are decisively differentiated by measurement of the pulmonary artery blood pressure.

#### SUMMARY

A description is given of seven patients with Eisenmenger's complex. This is a clinical rather than an anatomical diagnosis appropriate for patients with cyanotic congenital heart disease with pulmonary hypertension and an overriding aorta.

The symptoms and signs associated with this anomaly are characteristic but not diagnostic of it since they occur in other forms of cyanotic congenital heart disease with pulmonary hypertension. Breathlessness on exertion, hæmoptysis, and chronic cough were the common symptoms. Hoarseness and aphonia did not occur in the present series.

The only physical signs common to this group of patients, other than cyanosis which was present by definition, were those of pulmonary hypertension. Cyanosis developed during adolescence except in one patient where it was present from birth. Four patients had no murmurs. A parasternal systolic murmur is not an essential feature and in this series was not even a common feature of the clinical picture.

On electrocardiographic examination there was evidence of right ventricular dominance in all patients except one who had also systemic hypertension.

On radiological examination there was evidence of right ventricular hypertrophy and dilatation of the pulmonary arteries which was not of the extreme degree usually considered characteristic of Eisenmenger's complex. Angiocardiography was the most important diagnostic investigation in this anomaly since it demonstrated the overriding aorta. Cardiac catheterization confirmed the presence of pulmonary hypertension.

The anatomical features that may occur in patients fulfilling the criteria for a clinical diagnosis of Eisenmenger's complex are discussed.

On histological examination medial hypertrophy and intimal changes in the pulmonary arteries and arterioles, which occur in other forms of congenital heart disease with pulmonary hypertension, are characteristic of this anomaly.

We are grateful to Miss E. K. Abbott, Consultant Radiologist, for facilities in the Radiological Department, City General Hospital, Sheffield. We would like to thank Mr. Nichols and Miss N. Hardy for technical assistance, Mr. A. S. Foster, Artist to the United Sheffield Hospitals, and Mrs. Rose of the Photographic Department, Royal Hospital, Sheffield.

The patient referred to as Case 4 has died and necropsy has confirmed the diagnosis of Eisenmenger's complex.

## REFERENCES

- Abbott, M. E. (1927). Congenital Cardiac Disease in *Osler's Modern Medicine*, 4, 612.
- Barlow, T. (1876). Congenital Heart Disease. *Trans. Path. Soc. London*, 27, 140.
- Baumgartner, E. A., and Abbott, M. E. (1929). *Amer. J. med. Sci.*, 177, 639.
- Bedford, D. E., and Parkinson, J. (1936). *Brit. J. Radiol.*, 9, 776.
- Bing, R. J., Van Dam, L. D., and Gray, F. D. Jnr. (1947). *Bull. Johns Hopkins Hosp.*, 80, 323.
- Bond, V. F. (1951). *Amer. Heart J.*, 42, 424.
- Brown, J. W. (1950). *Congenital Heart Disease*. 2nd ed. Staples Press, London.
- Burwell, C. S. (1942). *Trans. and Stud. Physicians Philadelphia*, 10, 82.
- Campbell, M. (1951). *Brit. Heart J.*, 13, 438.
- Civin, W. H., and Edwards, J. E. (1950). *Circulation*, 2, 545.
- Edwards, J. E., Dry, T. J., Parker, R. L., Burchell, H. B., Wood, E. H., and Bulbulian, A. H. (1954). *Atlas of Congenital Anomalies of the Heart and Great Vessels*. Blackwell Scient. Publications, Oxford, p. 328.
- Eisenmenger, V. (1897). *Ztschr. klin. Med.*, 32, 1.
- Glazebrook, A. J. (1943). *Brit. Heart J.*, 5, 147.
- Goldberg, H., Silber, E. N., Gordon, A., and Katz, L. N. (1951). *Circulation*, 4, 343.
- Hurst, W. W., and Schemm, F. R. (1948). *Amer. Heart J.*, 36, 144.
- Kaplan, H. J., and Robinson, S. J. (1954). *Congenital Heart Disease*. New York.
- Lavenne, F., Tyberghein, J., Brasseur, L., and Meersseman, F. (1954). *Acta Cardiologica*, 3, 249.
- Lev, M. (1953). *Autopsy Diagnosis of Congenitally Malformed Hearts*. Thomas Press, Springfield, Illinois. Page 92.
- Millman, S., and Kornblum, D. (1936). *J. Tech. Methods*, 15, 147.
- Old, J. W., and Russell, W. O. (1950). *Amer. J. Path.*, 26, 789.
- Platts, M. M., and Whitaker, W. (1954). *Amer. Heart J.*, 48, 77.
- Rosedale, R. S. (1935). *Amer. J. Path.*, 11, 33.
- Saphir, O., and Lev, M. (1941). *Amer. Heart J.*, 21, 31.
- Schramm, H. G. (1929). *Beitr. path. Anat. allg. Path.*, 82, 153.
- Stewart, H. L., and Crawford, B. L. (1933). *Amer. J. Path.*, 9, 637.
- Taussig, H. B., and Semans, J. H. (1940). *Bull. Johns Hopkins Hosp.*, 66, 156.
- Voci, G., Joly, F., and Carlotti, J. (1952). *Bull. mem. Soc. méd. hôp. Paris*, 18, 636.
- Whitaker, W., Heath, D., and Brown, J. W. (1955). *Brit. Heart J.*, 17, 121.
- Wood, P. (1950). *Brit. med. J.*, 2, 639 and 693.