

# PRÆCORDIAL BALLISTOCARDIOGRAPHY

BY

PATRICK MOUNSEY

*From the Cardiac Department of the London Hospital*

Received May 26, 1956

Palpation of the heart beat has long been recognized to yield important information in heart disease. Many studies of graphic recording of the apex beat have been made (Marey, 1878; Mackenzie, 1902; Volhard, 1904; Weitz, 1917; and Dressler, 1937). More recently electronic methods have been used to record this movement (Johnston and Overy, 1951; Luisada and Magri, 1952). Recording of movement of the chest wall relative to a fixed point instead of to the surrounding chest wall was carried out by Eddleman *et al.* (1953), who used a metal bellows applied to the chest wall as a pick-up device.

In this investigation pulsation of the chest wall has been recorded by a new method, using an accelerometer. The accelerometer was kindly presented by Dr. Elliott. By means of this instrument it has been possible to record and study præcordial acceleration ballistocardiograms in health and disease.

## THE INVESTIGATION DESCRIBED

The accelerometer described by Elliott *et al.* (1954) is an electrokinetic device that registers electrical effects produced at a mercury-sulphuric acid interface. It consists of a glass capillary tube containing alternate layers of metallic mercury and sulphuric acid, thereby creating multiple interfaces of mercury and electrolyte solution. Movement of the tube produces changes at the surfaces of the mercury and electrolyte solution and these in turn give rise to variations in electrical potential that are proportional to the rate of change of velocity imparted to the tube. The instrument is most sensitive to acceleration in its longitudinal axis and was found by Elliott *et al.* to be capable of a flat response from 0 to 3000 cycles per second. The theory of the mercury-sulphuric acid interface phenomenon or so-called "U effect" was given by Ueda *et al.* (1950 and 1951) and was further discussed by Yeager and Hovorka (1953) in a review of acousto-electrokinetic phenomena.

In the present investigation the instrument used was a metal tube shielding the glass capillary tube and mounted on a light wooden bar (Fig. 1). The instrument was strapped to the chest by two rubber bands in such a way as to respond to movement in an axis at right angles to the body surface. The areas selected for recording were the site of the apex beat or apical area, the upper sternal area at the level of the second intercostal space, and the lower sternal area at the level of the fourth intercostal space. The subject lay resting on a steady couch, which was covered with a firm mattress, with the upper part of the body raised to an angle of 45°. The output from the accelerometer was fed into the electrocardiograph amplifier of a Sanborn Twin-Viso recorder.

The apparatus was so arranged that acceleration of the chest wall in an outward direction produced a downward deflection in the record.

*Standardization* of 0.5 cm. per millivolt was adopted, being found to give a convenient sized tracing in most subjects. No exact quantitative estimation of acceleration due to the heart beat was attempted, since a number of extraneous factors influenced the voltage of the ballistocardiogram. These included the tightness of the rubber bands strapping the instrument to the chest, the amount of subcutaneous tissue, the build of the chest, and lastly the varying angle, that the long axis of the accelerometer tube subtended with the direction of gravity.

Twenty healthy subjects were studied. There were 14 men and 6 women and their ages varied

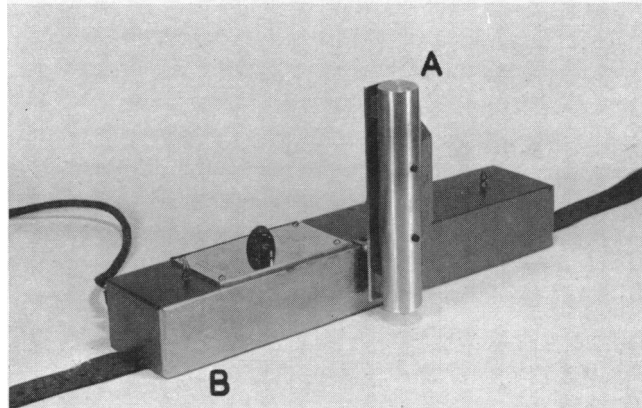


FIG. 1.—The accelerometer. The vertical metal tube (A) shields the glass capillary tube containing the mercury and sulphuric acid interfaces. The horizontal cross-piece (B) is a light wooden block which is strapped to the chest wall.

between 23 and 60 years. In addition, examples of some common heart diseases were investigated; these included seven patients with systemic hypertension, seven with pulmonary hypertension, three with atrial septal defect, three with constrictive pericarditis, twenty with mitral stenosis, three with dominant mitral incompetence, two with aortic stenosis, three with severe aortic incompetence, one with tricuspid stenosis, four with tricuspid incompetence, and six with left heart failure due to hypertension, cardiac infarction, or aortic incompetence.

As *reference tracings* a simultaneous electrocardiogram and a low-frequency phonocardiogram were recorded. In the study of the 20 healthy subjects a simultaneous low-frequency phonocardiogram was recorded in all, and both a phonocardiogram and an electrocardiogram in 12.

*Interpretation of the Acceleration Ballistocardiogram.* Acceleration bears no direct relationship to either displacement or velocity, although both may be derived from it mathematically. It is, however, closely related to motive force. Thus, in the ballistocardiogram the same deflection may mean either acceleration in one direction or deceleration in the opposite direction, but the direction of the motive force required to produce these changes in velocity would in either case be the same. Hence, although the direction of motion is not at once discernible from the record, the direction of motive force is clearly seen. In analysing the acceleration ballistocardiogram, therefore, the main deflections have been related as far as possible to the successive forces acting during the cardiac cycle.

#### THE PRÆCORDIAL BALLISTOCARDIOGRAM IN HEALTH

In the healthy subject the direction of the main deflections in the ballistocardiogram is similar, whether the recording is made at the apex, the upper sternal or lower sternal areas. The relative amplitude of the deflections, however, and also their exact timing differ according to the area selected for recording. In addition, in late systole and early diastole the direction of certain deflections is reversed in some patients in the upper sternal as compared with the apical area. In this paper the analysis of the ballistocardiogram in health will be confined to the study of records from the apical area, although brief mention will be made of the record in the upper sternal area, where this differs significantly from that in the apical area.

The præcordial ballistocardiogram may be conveniently divided into eight periods adopting a modification of the classification of Wiggers (1939) and Eddleman *et al.* (1953): atrial systole, ventricular proto-systole, ventricular isometric contraction, ventricular maximum ejection, ventricular reduced ejection, isometric relaxation, diastolic rapid inflow, and diastasis.

In *atrial systole* the ballistocardiogram showed an initial downward deflection AS<sup>1</sup> followed by an upward deflection AS<sup>2</sup> (Fig. 2 and 3). These deflections corresponded with forces generated

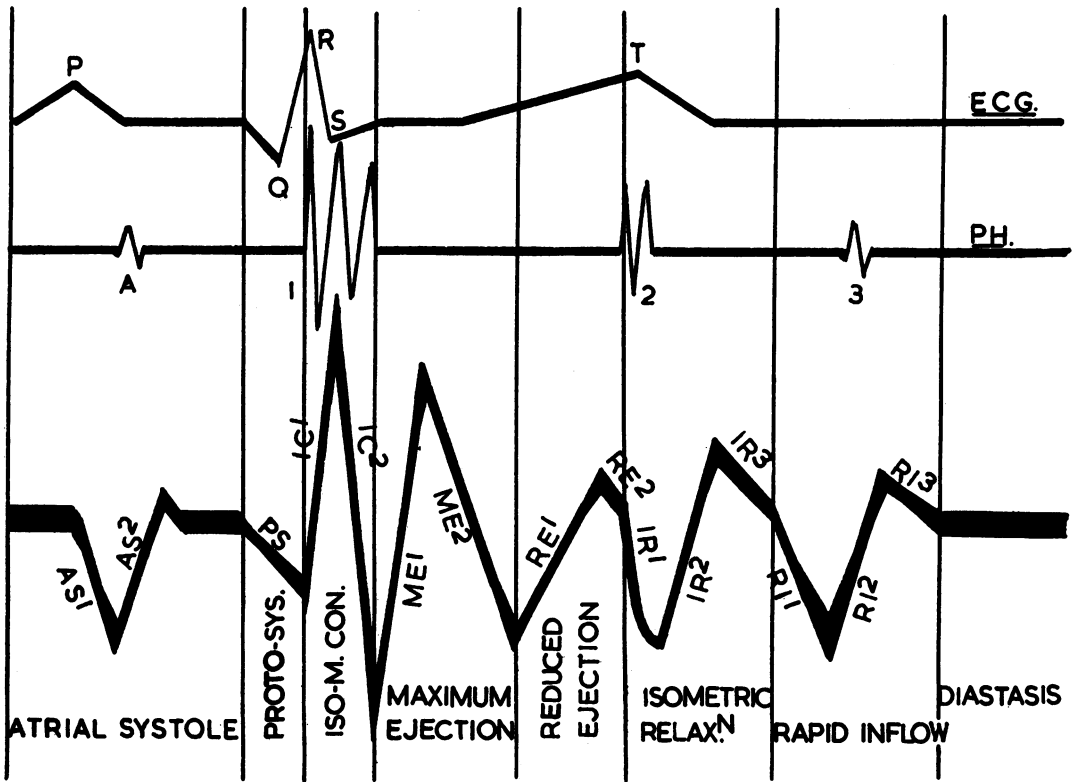
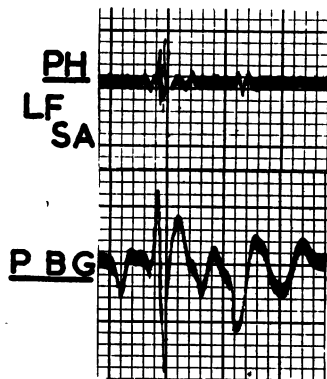
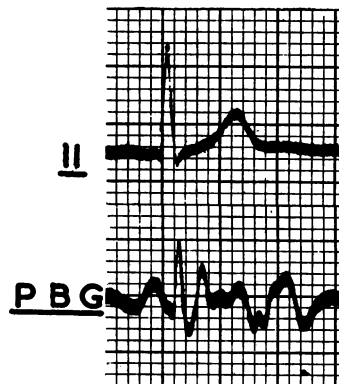


FIG. 2.—Diagram of the normal præcordial ballistocardiogram in the apical area. Simultaneous electrocardiogram and phonocardiogram as reference tracings. The præcordial ballistocardiogram is subdivided into eight periods: atrial systole, ventricular protosystole, ventricular isometric contraction, maximum ejection, reduced ejection, isometric relaxation, diastolic rapid inflow, and diastasis. The deflections in the ballistocardiogram bear two initials indicating the period in which they occur, followed by a number indicating their order of sequence: e.g. in the period of maximum ejection, the deflections are marked ME<sup>1</sup> and ME<sup>2</sup>.

NORMAL



APICAL AREA



UPPER STERNAL AREA

FIG. 3.—The normal præcordial ballistocardiogram in the apical and upper sternal areas.

by atrial contraction, causing initial outward acceleration followed by retardation in the second half of atrial systole. The average time interval between the beginning of the P wave in the electrocardiogram and the beginning of the atrial downward deflection in the ballistocardiogram was 0.08 sec. in the 12 subjects in whom a simultaneous electrocardiogram was recorded.

*Ventricular proto-systole* is here defined as the period between the beginning of the Q wave in the electrocardiogram and closure of the auriculo-ventricular valves, as indicated by the first heart sound in the phonocardiogram. In this period the initial deflection PS in the ballistocardiogram was downwards in seven of the twelve subjects. In the remaining five subjects it was preceded by a small upward deflection. The average time interval between the beginning of the Q wave in the electrocardiogram and the trough of the downward deflection PS in the ballistocardiogram was 0.05 sec., the mean heart rate for the twelve subjects being 85 a minute. The downward deflection PS and the inconstant upward deflection preceding it corresponded with forces due to ventricular contraction preceding closure of the auriculo-ventricular valves. The PS deflection was independent of atrial systole, since it was seen in the presence of atrial fibrillation.

*In the ventricular isometric contraction period* there was an abrupt upward deflection IC<sup>1</sup>, which coincided with the first heart sound in the phonocardiogram. The average intervals between the Q wave in the electrocardiogram and the beginning and the peak of the upward deflection were 0.05 and 0.08 sec. respectively. The IC<sup>1</sup> deflection was thought to be due to inward directed forces resulting from closure of the auriculo-ventricular valves. The upward deflection was followed by a downward deflection IC<sup>2</sup>. This deflection corresponded with a period of continued isometric contraction between closure of the auriculo-ventricular valves and opening of the semilunar valves and indicated outward-directed forces due to ventricular contraction.

*In the period of maximum ventricular ejection* the first deflection ME<sup>1</sup> was large and upward. The beginning of the deflection measured on an average 0.11 sec. from the Q wave in the electrocardiogram and its peak 0.15 sec. This deflection corresponded with inward-directed forces at the beginning of ventricular ejection into the aorta and pulmonary artery. The beginning of the deflection probably coincided with the opening of the semilunar valves and in a patient with pulmonary hypertension the ejection sound (Leatham and Vogelpoel, 1954) was seen to occur at this time (Fig. 4). The upward deflection was succeeded by a downward deflection ME<sup>2</sup>: this deflection indicated a period of lessening acceleration of ejection following the initial period of increasing acceleration at the beginning of ventricular ejection.

*The period of ventricular reduced ejection* is here defined as beginning at the trough of the ME<sup>2</sup> deflection, which measured 0.23 sec. from the Q wave in the electrocardiogram. In this period an upward deflection RE<sup>1</sup> was seen in six out of twelve healthy subjects, while in the remaining six the tracing remained at the base-line throughout this period. Whether this inconstant deflection originated primarily from forces in the heart or the great vessels seemed uncertain. The RE<sup>1</sup> deflection was followed by an inconstant small downward deflection RE<sup>2</sup>.

*In the isometric relaxation period*, in records from the apical area the initial deflection IR<sup>1</sup> was downwards and its beginning coincided with the sound of closure of the semilunar valves in the phonocardiogram. In records from the upper sternal area the direction of the IR<sup>1</sup> deflection was reversed, being upwards. This reversal in the two records could be explained by an inward force over the great vessels and a simultaneous outward force over the apex of the heart at the time of closure of the semilunar valves. Where splitting of the second heart sound was wide in the phonocardiogram the IR<sup>1</sup> deflection had a double trough. The average interval between the beginning of the second heart sound in the phonocardiogram and the trough of the IR<sup>1</sup> deflection was 0.03 sec.

A second deflection, IR<sup>2</sup>, followed the IR<sup>1</sup> deflection. It was upward at the apical area, although reversed in sense at the upper sternal area. The average time interval between the second heart sound and the peak of the IR<sup>2</sup> deflection was 0.08 sec. This deflection appeared to indicate inward forces over the apex of the heart accompanied by outward forces over the base of the heart, during the period of ventricular relaxation prior to opening of the auriculo-ventricular valves. These forces may possibly be explained by the alteration of the general position of the heart during this

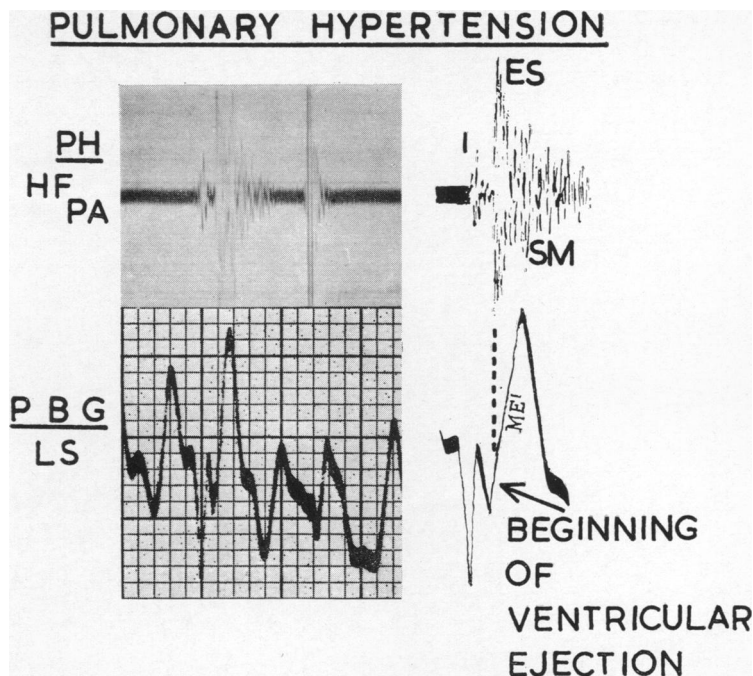


FIG. 4.—Pulmonary hypertension. Coincidence of the ejection sound (ES) with the start of ventricular ejection, as indicated by the beginning of the ME<sup>1</sup> deflection in the præcordial ballistocardiogram. ME<sup>1</sup> = first deflection in the maximum ejection period. SM = systolic murmur.

period. The IR<sup>2</sup> deflection was followed by a small downward deflection IR<sup>3</sup> of variable duration, which ended with the downward deflection of the rapid inflow period.

The *period of diastolic rapid inflow* is defined as beginning with a relatively sharp downward deflection RI<sup>1</sup> and ending with the return of the succeeding upward deflection RI<sup>2</sup> to the base-line. An inconstant small downward deflection RI<sup>3</sup> following the RI<sup>2</sup> deflection was sometimes seen. The onset of the downward deflection RI<sup>1</sup> averaged 0.13 sec., and its trough 0.16 sec. from the beginning of the second heart sound. The return to the base-line of the succeeding upstroke RI<sup>2</sup> averaged 0.23 sec. from the second heart sound.

The beginning of the downward deflection RI<sup>1</sup> probably coincided with the opening of the auriculo-ventricular valves and in mitral stenosis was found to be simultaneous with the opening snap (Fig. 9). The downward deflection RI<sup>1</sup> was due to the outward forces of early acceleration of ventricular filling. The succeeding upward deflection RI<sup>2</sup> was due to gradual lessening of acceleration of filling. A third heart sound was recorded in one young healthy subject and was seen to coincide with the upward deflection RI<sup>2</sup>.

In *diastasis*, or the period of reduced filling, the tracing remained on the base-line and did not show any significant deflection. This flat tracing was compatible with slow even filling of the ventricle during this period.

#### THE PRÆCORDIAL BALLISTOCARDIOGRAM IN DISEASE

In order to assess the possible value of the ballistocardiogram as an ancillary diagnostic aid examples of some common heart diseases were investigated.

The *heaving apex beat* in a patient with left heart failure due to *systemic hypertension* was examined in the ballistocardiogram (Fig. 5). An abnormally large downward deflection was recorded in the

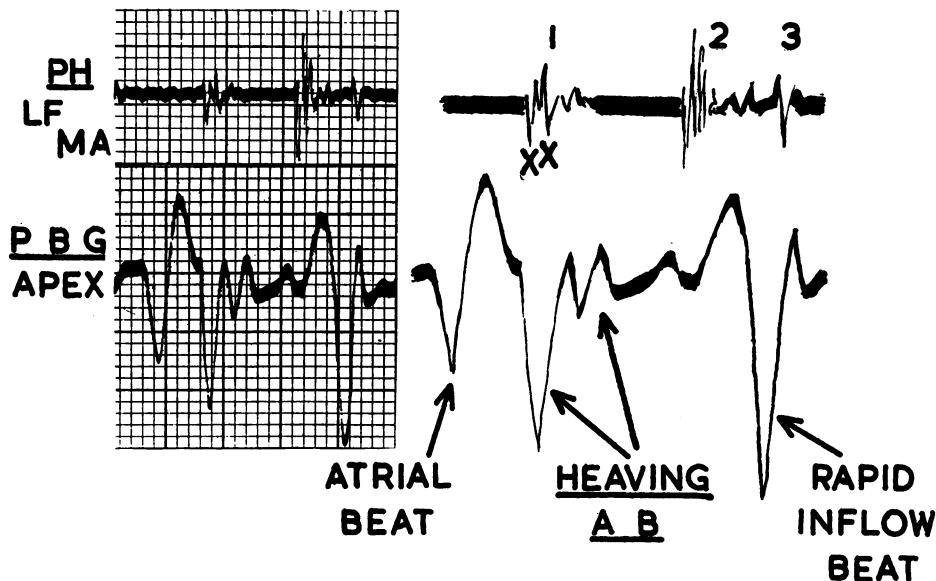
**HYPERTENSIVE HEART FAILURE**

FIG. 5.—Systemic hypertension and left heart failure (B.P. = 250/140 mm. Hg). Heaving apex beat. Quadruple rhythm, due to the addition of atrial and diastolic rapid inflow beats. 1, xx = split first heart sound.

apical area during the beginning of ventricular systole, which was followed by a large, but only moderately abrupt, upward deflection. The first heart sound was split in the phonocardiogram and the upward deflection in the ballistocardiogram was seen to coincide with its second component, thought to be due to closure of the mitral valve which was delayed and followed closure of the tricuspid valve. The downward deflection in the ballistocardiogram indicated large outward forces at the beginning of ventricular systole, followed by large, but only moderately abrupt, inward forces at the time of closure of the mitral valve. The succeeding deflections during the period of ventricular ejection were not abnormally large. This abnormal series of forces and their smooth, as opposed to abrupt, succession reflected the heaving quality of the apex beat felt by the hand.

The palpable quadruple rhythm in the same patient with hypertensive heart failure was reflected in large deflections in the ballistocardiogram during the period of atrial systole and of diastolic rapid inflow. These deflections indicated outward forces of unusual magnitude, which formed the third and fourth components of palpable quadruple rhythm and coincided with the atrial and third heart sounds.

For comparison the ballistocardiogram of a second patient with systemic hypertension of the same order (250/140 mm. Hg) was studied. This patient had few symptoms, no triple rhythm, a normal-sized heart on screening, an electrocardiogram showing slight left ventricular preponderance only and a ballistocardiogram that appeared normal. In four other patients with systemic hypertension differing patterns of ballistocardiogram were seen, which mirrored the wide variation in character of the apex beat.

Examples of left ventricular enlargement due to aortic incompetence and stenosis have been studied. In a patient with free aortic incompetence there was an abnormally large downward deflection at the beginning of ventricular systole. This was followed by an abnormally large and abrupt upward deflection, which was thought to coincide with closure of the mitral valve which was delayed and followed closure of the tricuspid valve. This upward deflection was partly fused with the succeeding upward deflection in the period of maximum ejection (Fig. 6). These deflections

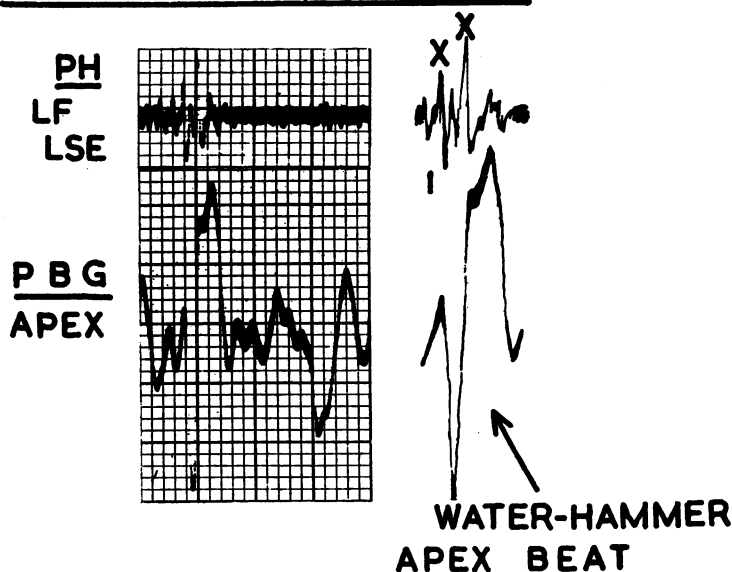
**AORTIC INCOMPETENCE**

FIG. 6.—Free aortic incompetence. Water-hammer apex beat. 1, xx = split first heart sound.

indicated increased outward forces at the beginning of ventricular systole, followed by abnormally large and abrupt inward forces at the time of closure of the mitral valve and at the beginning of ventricular ejection, the latter reflecting the water-hammer quality of the pulse.

In *aortic stenosis* the abnormally large and abrupt fused upward deflections at the time of closure of the mitral valve and at the beginning of ventricular ejection were not seen in the patients studied.

In a patient with *atrial septal defect* and *pulmonary hypertension* the tapping beat and left parasternal lift were studied in the ballistocardiogram. The *tapping beat* was characterised by an abnormally large downward deflection during protosystole, followed by an abrupt and large upward deflection at the time of closure of the auriculo-ventricular valves. This deflection in turn was followed by a large upward deflection at the beginning of ventricular ejection, which was sometimes partially fused with the preceding upstroke (Fig. 7). These deflections indicated an initial outward force in protosystole, followed by abnormally abrupt and large inward forces both at the time of closure of the auriculo-ventricular valves and at the beginning of right ventricular ejection. This sequence of forces was appreciated by the hand as an abrupt tapping beat.

The left *parasternal lift* was characterized in the ballistocardiogram by an abnormally large upward deflection during the period of reduced ejection. The resultant M-shaped figure inscribed in the ballistocardiogram during the period of maximum and reduced ejection was found to be characteristic of this lifting movement of the præcordium.

In two patients with *acquired pulmonary hypertension* and no intracardiac shunt, in one due to pulmonary vein obstruction by granulation tissue and in the other to recurrent pulmonary embolism, the ballistocardiogram showed in general a normal pattern, although the amplitude of the deflections during the period of ventricular systole was increased in both and in one the atrial beat was greatly augmented. Apart from the palpable atrial beat neither patient showed clinically the characteristic pulsations associated with right ventricular hypertrophy.

The *palpable triple rhythm of constrictive pericarditis* was well demonstrated in the ballistocardiogram and this offered confirmatory evidence that abrupt halting of rapid ventricular filling was the cause of the added early diastolic sound (Mounsey, 1955). During the period of diastolic rapid inflow the initial downward deflection was abruptly terminated by a steep upstroke, which in turn was followed by a downward deflection with return to the base-line (Fig. 8). The diastolic sound in

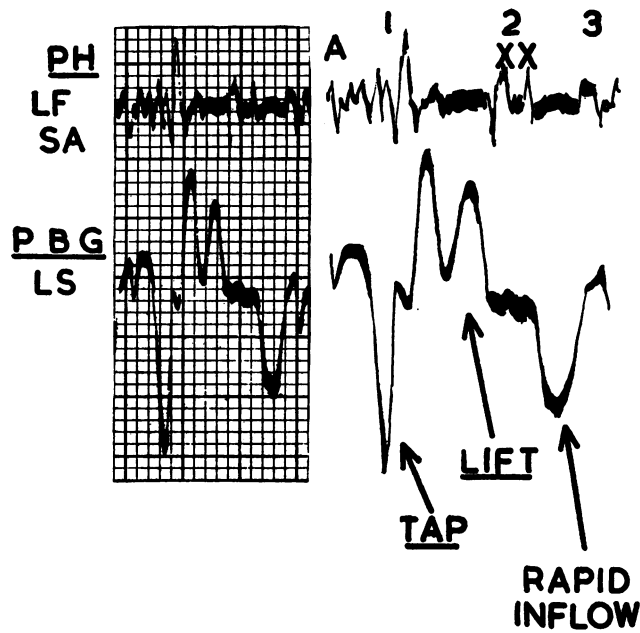


FIG. 7.—Atrial septal defect and pulmonary hypertension. Tapping beat and left parasternal lift. Large rapid inflow deflections. 2, xx = split second heart sound. At cardiac catheterization pulmonary artery pressure at 70/35 mm. Hg; evidence of left-to-right shunt in right atrium.

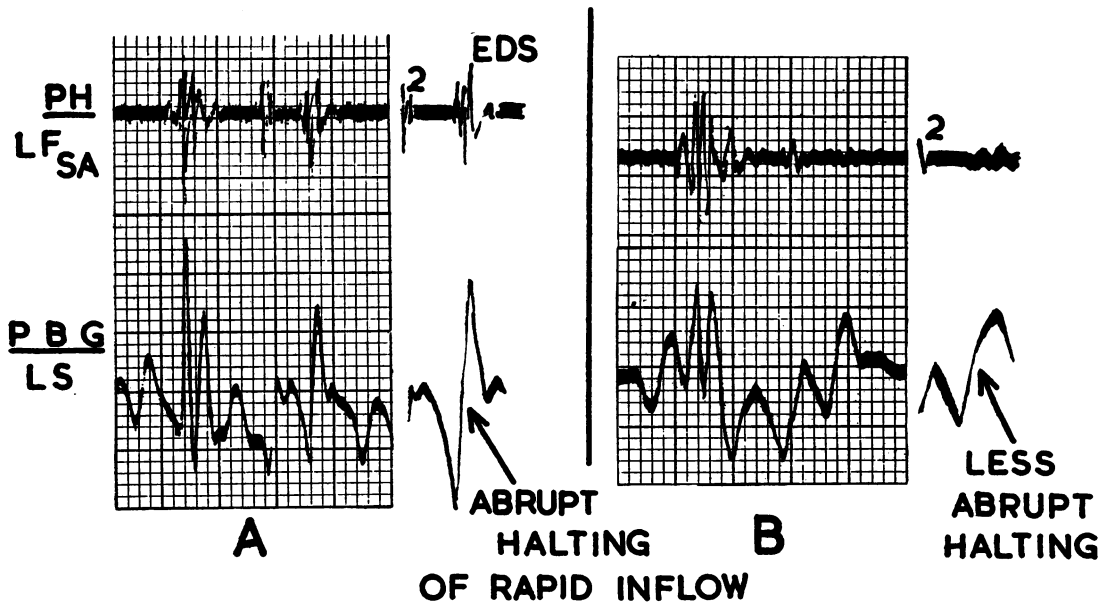


FIG. 8.—Constrictive pericarditis. Abruptness of halting of rapid ventricular filling decreased after successful operation. A = before operation. B = the same patient after operation. EDS = early diastolic sound.



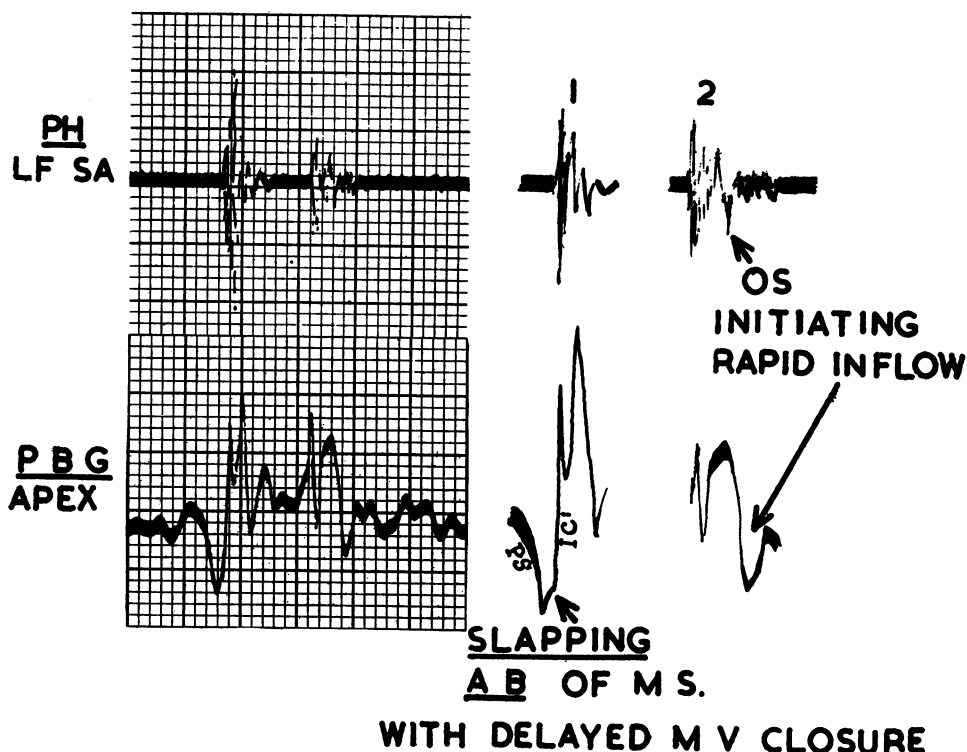
**MITRAL STENOSIS**

FIG. 9.—Tight mitral stenosis and atrial fibrillation. Slapping apex beat with delayed mitral valve closure, which coincides with the  $IC^1$  deflection in the præcordial ballistocardiogram. Opening snap (OS) initiating premature and abbreviated diastolic rapid inflow period. PS = protosystolic deflection.  $IC^1$  = first deflection in the isometric contraction period.

the phonocardiogram was seen to coincide with the steep upstroke in the ballistocardiogram. The initial downward deflection indicated outward forces due to rapid ventricular filling, as a result of the high venous pressure. The steep upstroke indicated abrupt halting of the outward forces of ventricular filling, which results from constriction of the expanding ventricle by the rigid pericardial casing. After successful operation the ballistocardiogram remained abnormal, although the steepness of the upstroke in the period of diastolic rapid inflow diminished, indicating that halting of ventricular filling was less abrupt.

In *mitral stenosis* the delay in mitral valve closure and the slapping apex beat were reflected in a characteristic pattern in the ballistocardiogram in the apical area. In the proto-systolic period there was an abnormally large downward deflection (PS), which was unrelated to atrial systole, since it was seen both in patients with sinus rhythm and atrial fibrillation. This was followed by a delayed large and steep upstroke ( $IC^1$ ), coinciding with closure of the mitral valve, as indicated by the timing of the first heart sound in the simultaneous phonocardiogram (Fig. 9). The delay of the first heart sound, which is well known in mitral stenosis and usually measured in relation to the Q wave in the electrocardiogram, was immediately apparent in the ballistocardiogram in the abnormally wide and deep downward wave in the proto-systolic period, which measured 0.10 sec., as compared with 0.05 sec. in the normal subject. During ventricular proto-systole, the downward deflection PS indicated initial outward forces accompanying ventricular contraction. When left ventricular pressure finally

exceeded left atrial pressure, the mitral valve closed abruptly, giving rise to large inward forces, registered in the ballistocardiogram by the tall steep upstroke IC<sup>1</sup>. This sequence of forces was appreciated by the hand as a slapping beat.

The opening snap, as already described, coincided with the beginning of the downward deflection in the diastolic rapid inflow period. This downward deflection, often only clearly shown in records from the upper sternal area, was small and abnormally early. It was followed by an upward deflection, after which the tracing returned to the base-line. This sequence reflected early acceleration of ventricular filling, due to the high left atrial pressure, an acceleration that is then rapidly checked

## MITRAL INCOMPETENCE

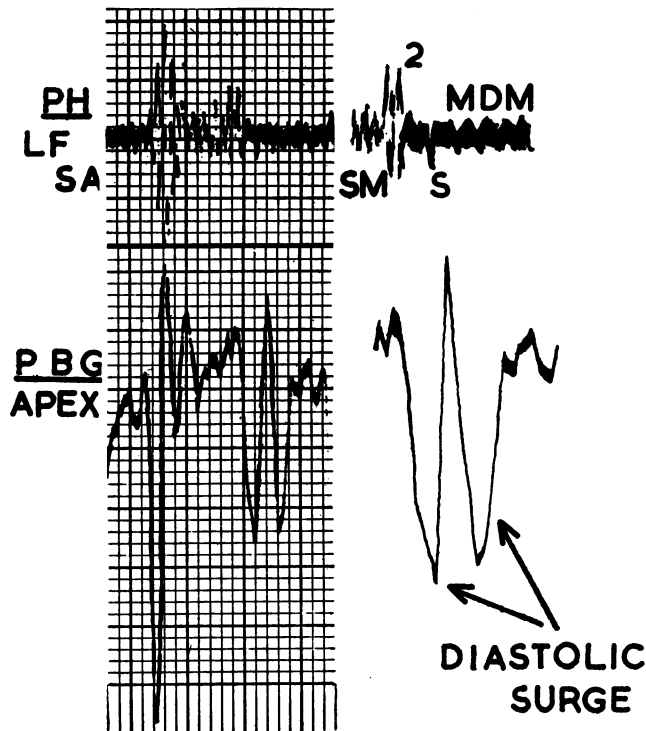


FIG. 10.—Dominant mitral incompetence of severe degree. Diastolic surge in rapid inflow period. SM = systolic murmur. S = snap. MDM = mid-diastolic murmur. At autopsy long diameter of mitral valve = 3 cm.; great left ventricular hypertrophy.

owing to the reduced maximum possible flow through the valve as a result of its stenosed orifice.

In severe *mitral incompetence* the salient feature of the ballistocardiogram was a very large bifid downward deflection in the diastolic rapid inflow period (Fig. 10). This was thought to result from large outward forces during the early diastolic surge of blood into the left ventricle, due to the high pressure in the left atrium at the end of systole. This diastolic surge was easily recognizable on palpation and was noted by Weitz (1917). It is the counterpart of the third heart sound in mitral incompetence, described by Brigden and Leatham (1953). The ballistocardiogram illustrated was of a patient with dominant mitral incompetence of severe degree, in whom the diagnosis was confirmed at autopsy.

In view of the striking difference in the ballistocardiogram in these examples of mitral stenosis

and incompetence, it is possible that the ballistocardiogram may provide an ancillary aid, helping to distinguish between dominant stenosis and incompetence.

In *tricuspid stenosis* the most marked features in the ballistocardiogram at the sternal area were the large deflections in atrial systole, coinciding with a palpable præcordial atrial beat, and the small amplitude of the deflection in the diastolic rapid inflow period (Fig. 11). In marked contrast to this were the large downward deflections in the rapid inflow period in *tricuspid incompetence* (Fig. 11).

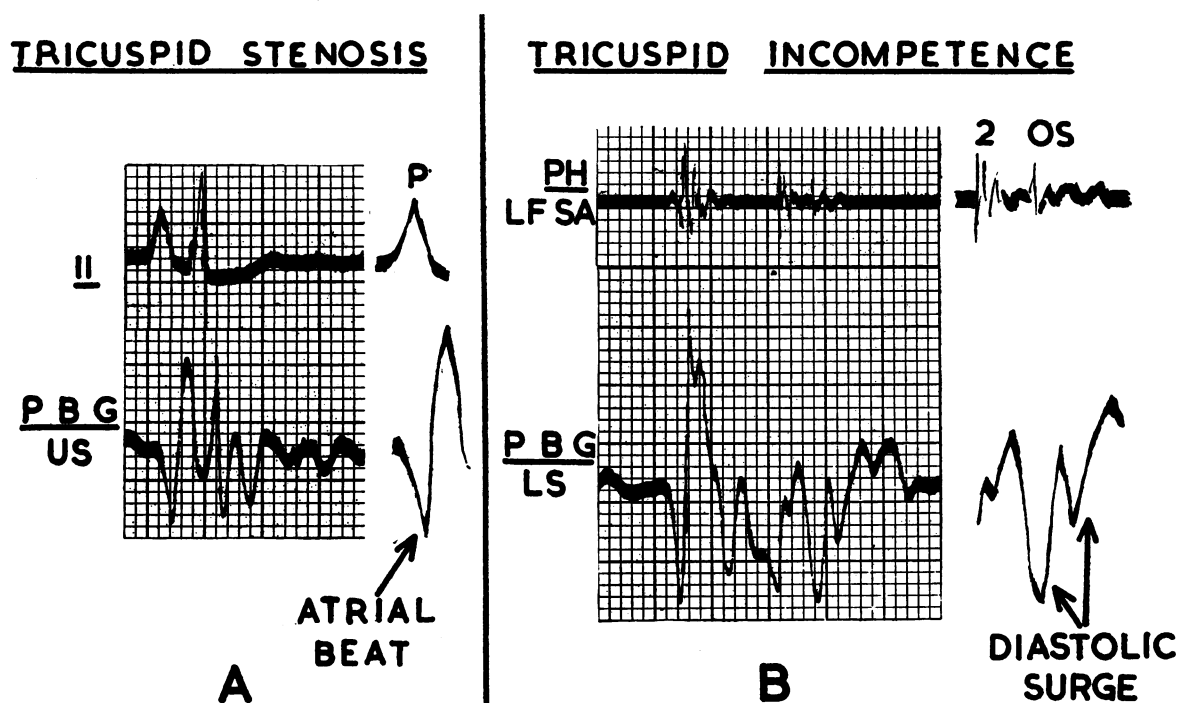


FIG. 11.—(A) Tricuspid stenosis. Large atrial beat. Right auricular P wave augmented in electrocardiographic lead 2. (B) Tricuspid incompetence, complicating mitral stenosis. Diastolic surge of tricuspid incompetence. OS = opening snap of mitral valve.

This difference between the ballistocardiogram of tricuspid stenosis and incompetence was thought to be due to the same factors operating in the right heart as operated in the left heart in mitral valve disease. As in mitral incompetence, the diastolic surge of tricuspid incompetence was readily palpable, being most marked in this condition at the left sternal edge, a physical sign noted by Volhard (1904). In contrast to mitral incompetence, on the other hand, in which the downward deflection in the diastolic rapid inflow period tended to decrease on inspiration, in tricuspid incompetence inspiration greatly increased the amplitude of this deflection.

#### SUMMARY AND CONCLUSIONS

Pulsation of the chest wall has been recorded by a new method using the accelerometer described by Elliott *et al.* (1954). By means of this instrument it has been possible to record acceleration ballistocardiograms at selected areas of the præcordium and to study their characteristics. Acceleration ballistocardiograms were studied in 20 healthy subjects. The direction of the main deflections was in general similar, whether the recording was made at the apical, upper sternal, or lower sternal areas, although the direction of certain deflections in late systole and early diastole was reversed at the upper sternal as opposed to the apical area.

The præcordial ballistocardiogram was found to give information about the sequence, direction and relative magnitude of the cardiovascular forces acting during the cardiac cycle and appeared to reflect to a large extent local forces in the heart superimposed upon the more general cardiovascular forces recorded in conventional ballistocardiography.

In order to assess the possible value of the ballistocardiogram as an ancillary diagnostic aid, a study was also made of this in examples of common diseases. In a patient with left heart failure due to hypertension, the heaving apex beat and quadruple rhythm were clearly seen in the ballistocardiographic pattern. The water-hammer apex beat of free aortic incompetence, the tapping beat and parasternal lift of atrial septal defect, and the slapping apex beat of mitral stenosis were also clearly reflected. The premature halting of diastolic rapid inflow of mitral stenosis contrasted with the diastolic surge of mitral incompetence, while similar information was obtained in disease of the tricuspid valve. In constrictive pericarditis halting of rapid ventricular filling was shown to become less abrupt after successful operation.

From this preliminary survey of examples of common diseases, the præcordial ballistocardiogram was seen to afford added information about the abnormal cardiovascular dynamics in each condition. In general it appeared to reflect the reaction of the heart to each disease rather than the disease itself. In addition, although not recording movement directly, it reflected the abnormal physical signs appreciated on inspection and palpation of the præcordium.

In conclusion præcordial ballistocardiography contributes to our knowledge of cardiovascular dynamics in health and disease, relates cardiovascular dynamic events to other phenomena, such as the heart sounds, depicts graphically information about the forces responsible for præcordial pulsation, and may prove of value, as an ancillary diagnostic aid, in helping to assess the relative degree of stenosis and incompetence in valvular disease of the heart.

I should like to express my sincere thanks to Dr. Robert V. Elliott, who generously presented the accelerometer with which this work was carried out, and also Dr. John R. Braunstein for his interest in this project and for introducing me to Dr. Elliott.

I should like to thank Dr. William Evans and Dr. Wallace Brigden for their help and criticism of this paper and to thank Dr. Catherine Neill for reading the manuscript.

Thanks are also due to Mr. William Dicks, Mr. Fredrick Harrison and Mr. Albert Gallup for their technical help, and to those blood donors and members of the lay staff at the London Hospital who kindly volunteered for investigation as normal subjects.

#### LEGENDS

The illustrations have been retouched in places owing to the faintness of the more rapid deflections in the original Sanborn records.

##### *General Key to Legends*

- PBG = præcordial ballistocardiogram.  
 LS and US=lower and upper sternal areas.  
 11 = electrocardiographic lead II.
- PH = phonocardiogram.  
 LF and HF=low and high frequency.  
 MA, SA and PA=mitral, supramammary and pulmonary areas.  
 1, 2 and 3=first, second and third heart sounds.  
 A=atrial sound.

#### REFERENCES

- Brigden, W., and Leatham, A. (1953). *Brit. Heart J.*, **15**, 55.  
 Dressler, W. (1937). *Arch. intern. Med.*, **60**, 225, 437, 441, 654, and 663.  
 Eddleman, E. E., Willis, K., Reeves, T. J., and Harrison, T. R. (1953). *Circulation*, **8**, 269.  
 Elliott, R. V., Packard, R. G., and Kyrakis, D. T. (1954). *Circulation*, **9**, 281.  
 Johnston, F. D., and Overy, D. C. (1951). *Circulation*, **3**, 579.  
 Leatham, A., and Vogelpoel, L. (1954). *Brit. Heart J.*, **16**, 21.  
 Luisada, A. A., and Magri, G. (1952). *Amer. Heart J.*, **44**, 545.  
 Mackenzie, Sir J. (1902). *The Study of the Pulse, Arterial, Venous and Hepatic, and of the Movements of the Heart*. Pentland, Edinburgh, and London.

- Marey, E. J. (1878). *La Méthode graphique dans les Sciences expérimentales*. Masson, Paris.
- Mounsey, J. P. D. (1955). *Brit. Heart J.*, **17**, 143.
- Ueda, S., Watanabe, A., and Tsuji, F. (1950). *Mem. Coll. Agric., Kyoto*, **57**, 22.
- (1951). *Mem. Coll. Agric., Kyoto*, **60**, 1.
- Weitz, W. (1917). *Dtsch. Arch. klin. Med.*, 124, 134, and 155.
- Volhard, F. (1904). *Berl. klin. Wschr.*, **41**, 522.
- Wiggers, C. J. (1939). *Physiology in Health and Disease*. 3rd. ed., Kimpton, London.
- Yeager, E., and Hovorka, F. (1953). *J. acoust. Soc. Amer.*, **25**, 443.