

AUSCULTATORY AND PHONOCARDIOGRAPHIC SIGNS OF PULMONARY STENOSIS

BY

AUBREY LEATHAM AND DAVID WEITZMAN

From the Institute of Cardiology, National Heart Hospital

Received September 12, 1956

The course and management of pulmonary stenosis depends on two main factors, the degree of obstruction to right ventricular outflow and the presence and extent of an over-riding aorta with a ventricular septal defect. This investigation was undertaken to determine how accurately these points could be decided by study of the heart sounds and murmurs. The pulmonary systolic murmur has long been recognized as the most important sign (Peacock, 1866), but the significance of its duration and graphic form has not been widely appreciated. Little attention has been paid to the first heart sound since Petit in 1902 commented on its snapping quality at the base in some cases. The second heart sound at the pulmonary area has been variously described as accentuated, normal, diminished, or absent: this has been due to failure to differentiate between aortic and pulmonary components of the second sound at the pulmonary area as pointed out by Abrahams and Wood (1951). The present investigation shows that the presence or absence of the pulmonary component and its delay in relation to the aortic component are of considerable help in diagnosis.

METHOD

Seventy patients with pulmonary valvular or infundibular stenosis were studied. The clinical diagnosis was confirmed by cardiac catheterization or angiocardiology in all, and also by operation in thirty-five and by necropsy in three cases.

Auscultation was always carried out by one of us and the intensity of heart sounds and murmurs was graded, the classification of Freeman and Levine (1933) being used for systolic murmurs. Special attention was paid to the first and second heart sounds, and to the intensity and length of the systolic murmur. High-frequency phonocardiograms corresponding to auscultation (Leatham, 1952) were taken in every case, and were repeated in six after operation. Simultaneous recordings were made from the pulmonary and mitral areas together with an electrocardiogram and an indirect carotid pulse tracing in every case, and synchronously with a pressure pulse from the pulmonary artery and right ventricle in eleven cases. The mitral and tricuspid components of the first sound and the ejection sound were identified by methods already described (Leatham, 1954). The aortic component of the second sound was identified by its relation to the dicrotic notch of the carotid tracing allowing for a delay of from 0.02 to 0.04 second. The pulmonary component was identified by its maximum intensity at the pulmonary area and by its synchrony with the dicrotic notch of the tracing from the pulmonary artery when this was obtained simultaneously. The two components of the second heart sound were also identified by taking synchronous phonocardiograms from the pulmonary and mitral areas, since only the aortic component is transmitted to the apex (Leatham, 1954).

The duration of right ventricular systole was estimated by measuring the time interval between the tricuspid component of the first sound and the pulmonary component of the second. In the same way left ventricular systole was estimated, using the mitral and aortic components of these sounds. In many patients the first sound was single and both measurements were taken from the onset of the major deflections of the first sound. The time interval between the onset of QRS and the onset of right ventricular systole (Q-RV time) was measured in the 64 patients who were catheterized. Time intervals were measured from the onset of all deflections whether pressure pulse, electrocardiogram, or phonocardiogram.

A full electrocardiogram was always taken and the degree of right ventricular hypertrophy was estimated without knowledge of the right ventricular systolic pressure.

The patients fell into three groups each with distinctive clinical, auscultatory, phonocardiographic, and hæmodynamic findings.

- (1) Mild pulmonary stenosis with intact ventricular septum (11 cases).
- (2) Moderate or severe pulmonary stenosis with intact ventricular septum (33 cases).
- (3) Fallot's tetralogy (26 cases).

MILD PULMONARY STENOSIS

These patients had no significant symptoms and were often referred following mass X-ray examination which had disclosed dilatation of the pulmonary artery: none had any enlargement of the heart radiologically. Cyanosis and clubbing were absent and there was no clinical or electrocardiographic evidence of right ventricular hypertrophy. The right ventricular systolic pressure ranged from 15 to 40 mm. Hg, and there was a pressure gradient across the pulmonary valve of 6 to 26 mm. Hg. In no case was there evidence of an infundibular chamber or of a left-to-right shunt. These small pressure gradients might have been produced by dilatation of the pulmonary artery alone (Greene *et al.*, 1949) and we were unable to distinguish between this condition and mild pulmonary stenosis, especially as none of these patients came to operation or necropsy. Lack of

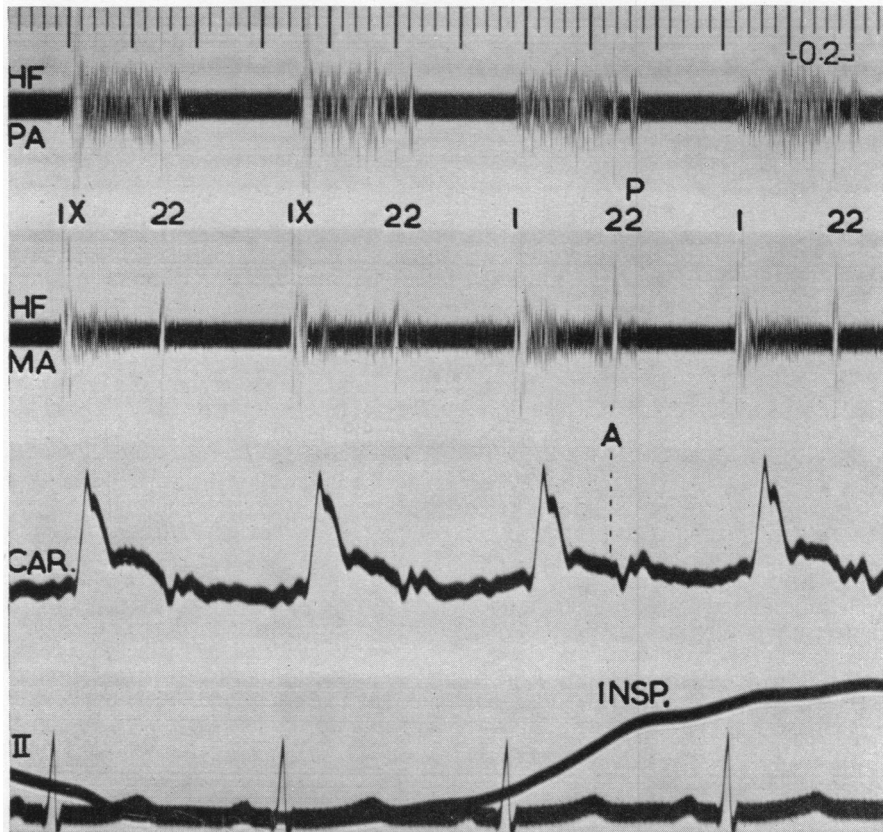


FIG. 1.—Mild pulmonary valve stenosis (RV P mean. 19 mm. Hg, PA P mean. 10 mm. Hg). Simultaneous high-frequency phonocardiograms (HF) from the pulmonary (PA) and mitral (MA) areas with indirect carotid tracing (CAR) and electrocardiogram. Pulmonary early systolic ejection sound (X) maximal at the pulmonary area and disappearing on inspiration (INSP). Splitting of second heart sound with aortic component (A, identified by carotid tracing) preceding pulmonary component (P) by 0.05 sec. Ejection systolic murmur maximal at pulmonary area. The time intervals in this and subsequent records are 0.20 and 0.04 sec.

appreciable stenosis was demonstrated in one case by passing a double loop of the catheter through the valve. The dilatation of the main pulmonary artery seemed greater in this group than in the more severe cases, but the appearance of dilatation was perhaps exaggerated by absence of hypertrophy of the adjacent outflow tract of the right ventricle in mild cases.

The first sound was normal and was followed in every case by an extra sound at an interval of 0.02 to 0.06 sec. (mean 0.04). This gave the impression of wide splitting of the first heart sound, but the extra sound was clicking in quality, and maximal at the pulmonary area and in expiration (Fig. 1). These features are characteristic of a pulmonary ejection sound (Leatham and Vogelpeol, 1954) and in four cases we were able to confirm this by recording both mitral and tricuspid components of the first sound preceding the extra sound (Fig. 2). The exact relation of this sound to

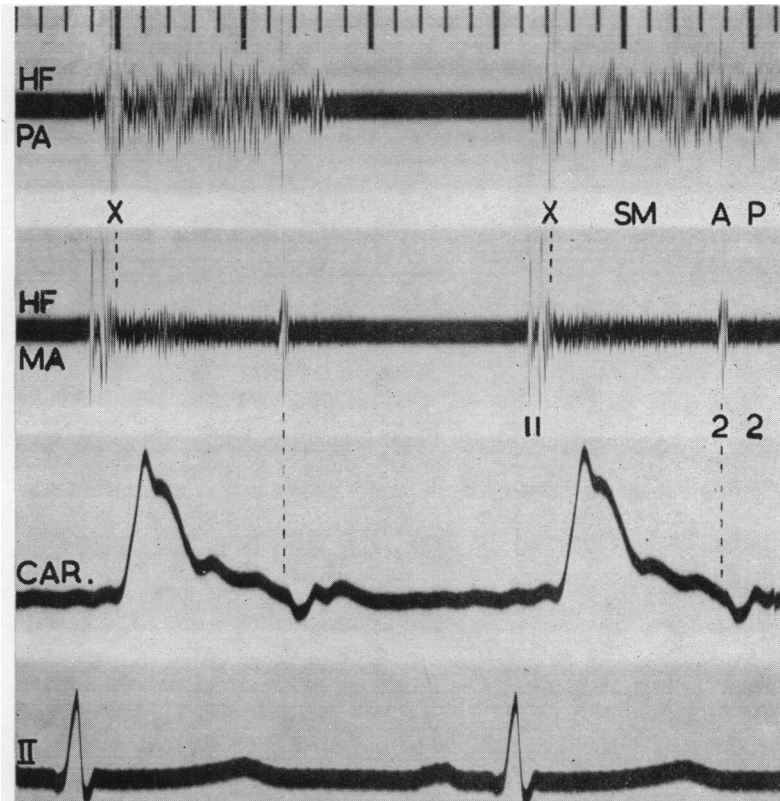


FIG. 2.—Mild pulmonary valve stenosis (same patient as Fig. 1). Both components of the first sound recorded at mitral area, preceding ejection sound at pulmonary area. Pulmonary component of second sound identified by its localization to pulmonary area.

the pulmonary artery pressure pulse could not be demonstrated because of the difficulty of obtaining good pressure records from the pulmonary artery in pulmonary stenosis, but it was shown to occur after the onset of rise of pressure in the right ventricle (Fig. 3).

In every case there was abnormally wide splitting of the second heart sound in the expiratory phase of respiration. The earlier component was shown to be due to aortic, and the later to pulmonary valve closure (Fig. 2 and 4), and the interval between the two components in expiration was 0.03–0.06 sec. (normal 0.01–0.03 sec.), increasing to 0.04–0.07 sec. during inspiration as in normal subjects. The intensity of the pulmonary component was judged to be normal by auscultation

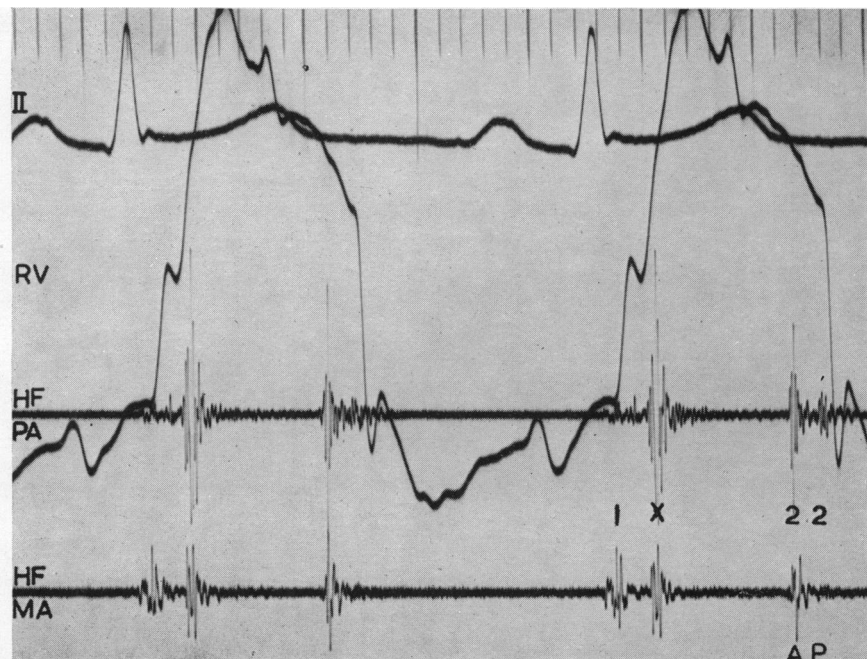


FIG. 3.—The relation of the right ventricular pressure pulse (RV) to the first heart sound and pulmonary early systolic sound in a patient with mild pulmonary valve stenosis. The major components of the first heart sound are approximately coincident with the rise of pressure in the right ventricle and the extra sound occurs 0.06 sec. later, showing that it has no connection with closing of the tricuspid valve.

and this was confirmed by the ratio of the amplitude of the two components of the second sound on the phonocardiogram. The pulmonary component was never less than one-third of the aortic and was about equal in four cases. There was invariably a systolic murmur maximal in the pulmonary area (Table, p. 307). The intensity of the murmur varied from soft (grade 1) to moderately loud (grade 3) and was increased by exertion. The murmur started immediately after the ejection sound, occupied early and mid systole, sometimes reaching the aortic component of the second sound, and finished before the pulmonary component. Pulmonary diastolic murmurs were never heard or recorded, showing that there was no pulmonary incompetence, even with great dilatation of the pulmonary artery.

MODERATE OR SEVERE PULMONARY STENOSIS WITH INTACT VENTRICULAR SEPTUM

All these patients had clinical and cardiographic evidence of right ventricular hypertrophy. Five showed cyanosis from a reversed inter-atrial shunt. The right ventricular systolic pressure ranged from 50 to 160 mm. Hg. The stenosis appeared to be valvular in 29 cases (confirmed by operation or necropsy in 15), infundibular in 4, and both valvular and infundibular in one (necropsy confirmation). This group corresponds to those with normal aortic root described by Abrahams and Wood (1951).

The first sound was normal and was preceded by an auricular sound in two cases with severe stenosis. An ejection sound, with the same timing as in the first group was heard or recorded in only 5 cases, all with moderate stenosis (RV P. 75 mm. or less). In one other patient the sound appeared for the first time after operation when the right ventricular systolic pressure had fallen from 110 to 55 mm. The second heart sound was abnormally widely split with a soft late pulmonary

TABLE
SUMMARY OF FINDINGS

	Simple pulmonary stenosis		3. Fallot's tetralogy
	1. Mild	2. Moderate or severe	
Electrocardiogram	Normal	Right ventricular hypertrophy	Right ventricular hypertrophy
Right ventricular systolic pressure	Under 40 mm. Hg	50-160 mm. Hg	70-115 mm. Hg
Ejection sound—			
Pulmonary	Invariably present	Uncommon	Absent
Aortic	Absent	Absent	Occasional
Second sound—			
Aortic component	Normal	Normal but may be masked by murmur at pulmonary area	Normal or accentuated
Pulmonary component	Normal	Present (85%) but intensity reduced	Absent
Degree of splitting	Increased (0.03-0.06 sec. in expiration)	Greatly increased (0.05-0.14 sec. in expiration)	—
Pulmonary systolic murmur	Soft	Loud and long, may extend past aortic component	Variable in intensity and duration

component which was heard and recorded in 28 (85%) cases (Fig. 5 and 6). Sometimes the splitting was difficult to hear, because the earlier (aortic) component was drowned in the loud systolic murmur at the pulmonary area, or because the later (pulmonary) component was very soft. The splitting was often heard more easily in the third or fourth left space where the systolic murmur was less loud. The time interval between the two components of the second sound in the expiratory phase of respiration varied from 0.05 to 0.14 sec. and was closely related to the severity of the stenosis as judged by the right ventricular systolic pressure (Fig. 10). Following a successful valvotomy, with a fall in right ventricular systolic pressure, the time interval shortened, e.g. from 0.14 to 0.07 sec. with a fall in RV systolic pressure from 150 to 55 mm., and from 0.12 to 0.06 sec. with a fall from 150 to 50 mm. The wide splitting was found to be due to delay in pulmonary valve closure caused by prolongation of right ventricular systole, there being no delay in onset of right ventricular systole (Q—RV time of 0.07 sec., identical with that found in normal subjects by Coblenz *et al.*, 1949), and no shortening of left ventricular systole (average 0.31 sec., identical with that found in 10 normal subjects). The duration of right ventricular systole ranged from 0.36 to 0.41 and averaged 0.39 sec. The pulmonary component of the second sound was always reduced in intensity on auscultation, and this was confirmed on the phonocardiogram. When both components were clearly recorded the pulmonary was always less than half the aortic in amplitude (no measurement of the absolute intensity of heart sounds and murmurs was possible). Following valvotomy the pulmonary component tended to increase in intensity.

In the five patients in whom the pulmonary component of the second sound was absent the pulmonary stenosis was more severe (average right ventricular systolic pressure 115 mm., compared with 80 mm. in the remainder). In one of them a late pulmonary component appeared for the first time after operation when the right ventricular systolic pressure fell from 150 to 55 mm.

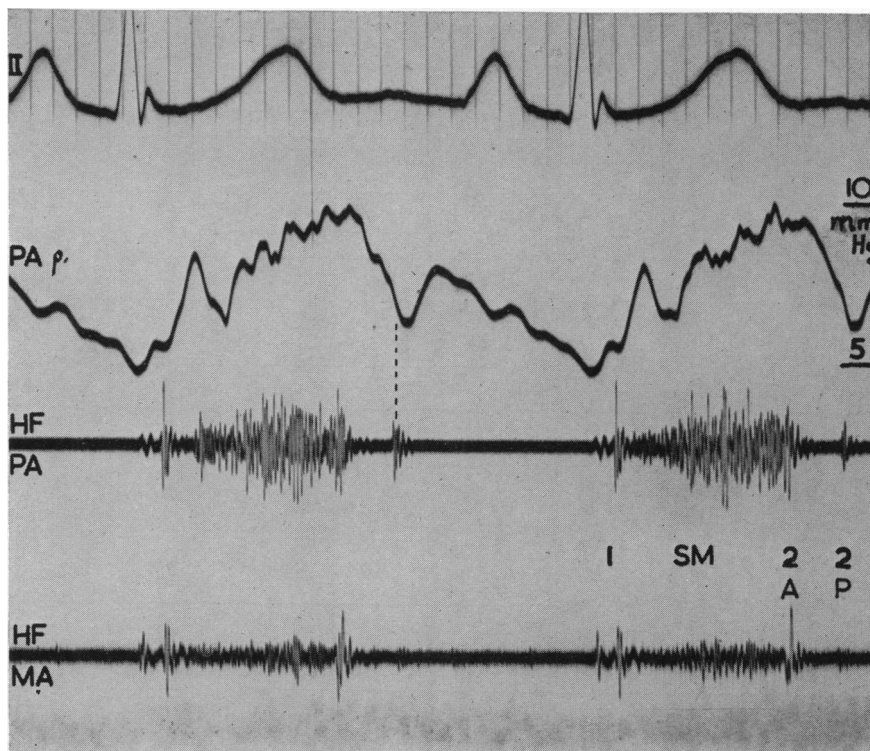


FIG. 4.—Pulmonary valve stenosis (RV P. 70/5, PA P. 10/5 mm. Hg). Later component (P2) of second sound coincides with dicrotic notch of pressure pulse from pulmonary artery (PA P.) allowing for delay of 0.02 sec.

The intensity of the pulmonary systolic murmur varied from moderately loud (grade 3) to very loud (grade 6) and was grade 4 or 5 in 28 out of 33 patients. The murmur started soon after the first sound and tended to be long. It frequently extended up to or even past the aortic component of the second sound, making this sound difficult to identify at the pulmonary area, although easily heard and recorded at the apex. The murmur always ended before the delayed pulmonary component and its maximum intensity was about mid-way between this and the first heart sound (Fig. 5 and 6).

In the four patients with pure infundibular stenosis, as judged by cardiac catheterization, the systolic murmur and second heart sound showed no consistent difference from the valvular cases (Fig. 5 and 6).

An auricular systolic murmur of low intensity was recorded in three patients, of whom two had valvular and one infundibular stenosis, but was heard only in the patient with infundibular stenosis (Fig. 7). A giant *a* wave was seen in the neck of each of these patients. An early diastolic murmur of very low intensity was also recorded in one patient with valve stenosis, but no cause was found at operation.

FALLOT'S TETRALOGY

Ventricular septal defect with a right-to-left shunt was demonstrated in every case by catheterization or angiocardiology. All had cyanosis and clinical and electrocardiographic evidence of right ventricular hypertrophy. The right ventricular systolic pressure ranged from 70 to 115 mm. Hg, and was about the same as the systemic pressure in the 18 patients who were catheterized. The

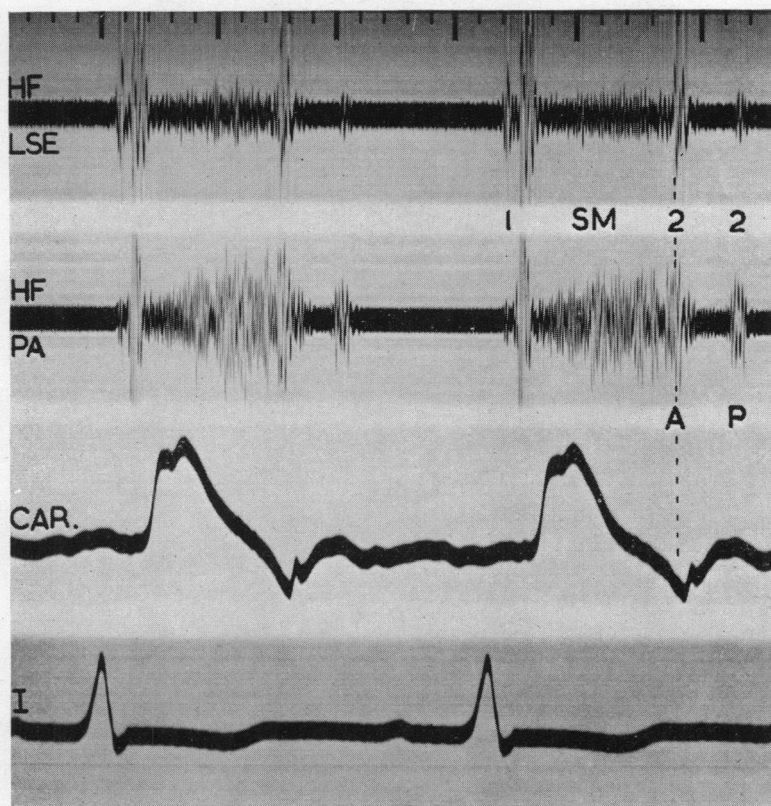


FIG. 5.—Severe pure pulmonary valve stenosis (RV P. 125/0 mm. Hg). Splitting of second sound with pulmonary component in pulmonary area 0.10 sec. after aortic component recorded from lower left sternal edge (LSE). Ejection systolic murmur extends past aortic component of second sound and stops before pulmonary component.

stenosis as seen at operation or necropsy was described as infundibular in nine cases, valvular and infundibular in five, and predominantly valvular in five. In seven cases the site of the stenosis has not yet been established.

The first sound was normal and was followed in two patients by an early systolic sound (Fig. 8). This sound was maximal at the aortic and mitral areas, uninfluenced by respiration, and 0.07 sec. after the first heart sound, i.e. later than the ejection sound in mild pulmonary stenosis (mean 0.04 sec. after the first sound). The lateness of this sound made it unlikely to be due to ejection into the pulmonary artery, which must be early in severe pulmonary stenosis with a low pulmonary artery pressure, and this was confirmed in one case where the onset of the pulmonary systolic murmur preceded the extra sound. In the same patient the extra sound followed the onset of rise of pressure in the aorta by 0.04 sec. (calculated). These findings strongly suggested that this sound was related to aortic ejection, and this belief was supported by the presence of a similar sound with identical timing in two patients with pulmonary atresia.

The second sound was always single before operation and was attributed to aortic valve closure from its relation to the dicrotic incisura of the carotid tracing (Fig. 9). No pulmonary component was recorded in any patient before operation, but in three who were studied after it the pulmonary component of the second sound became audible for the first time and was recorded. In one patient the pulmonary component first appeared 0.11 sec. after the aortic, following a Blalock operation (Fig. 11A): after valvotomy this interval decreased to 0.06 sec. (Fig. 11B).

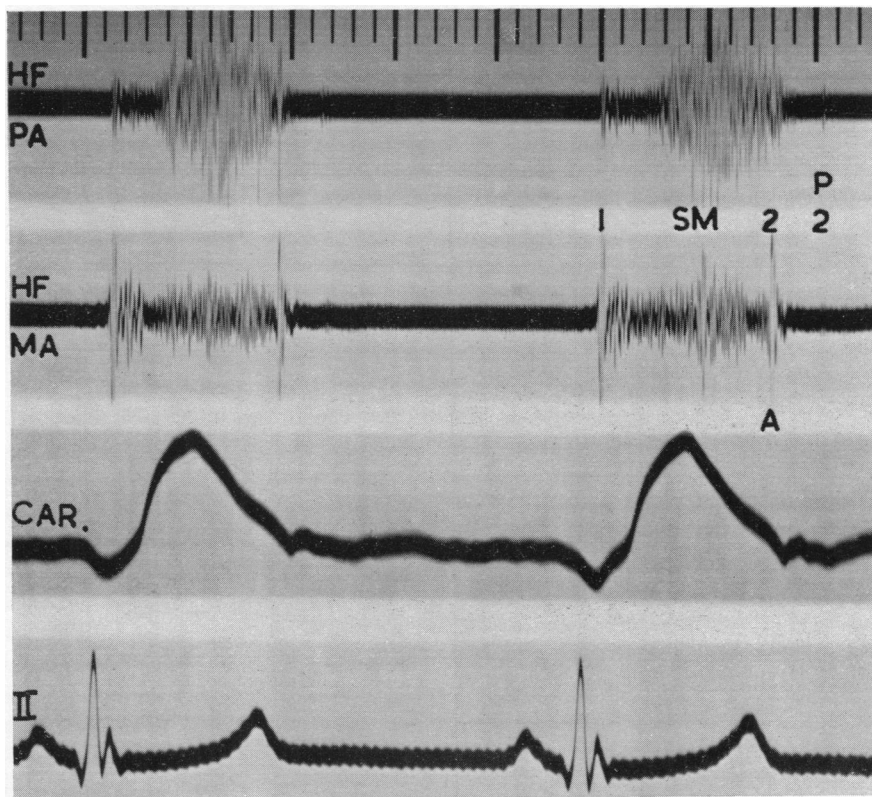


FIG. 6.—Pure infundibular stenosis (RV P. 65/5, infundibular chamber 23/5, PA P. 23/10 mm. Hg). Loud ejection systolic murmur and wide splitting of second sound (0.09 sec.) as in cases of valve stenosis.

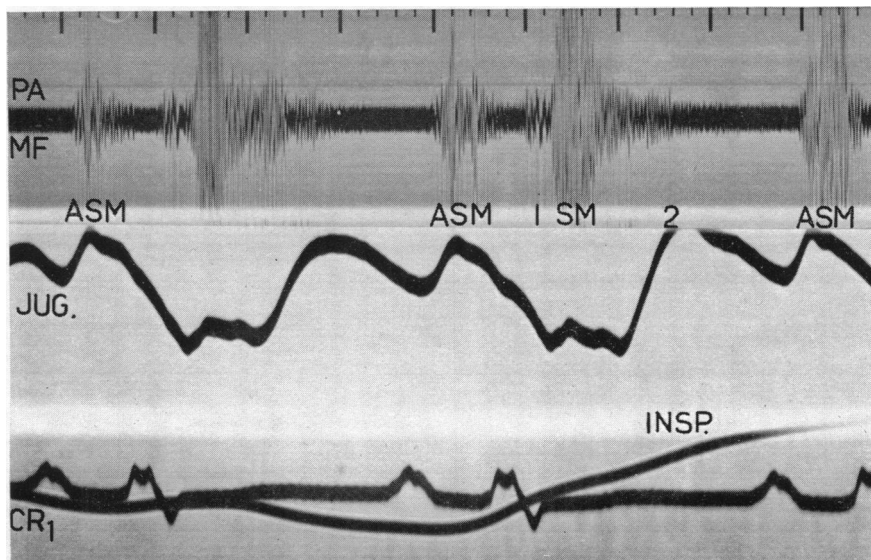


FIG. 7.—Pure infundibular stenosis (RV P. 60/4, infundibular chamber 25/4, PA P. 21/1 mm. Hg). with auricular systolic murmur (ASM), showing inspiratory increase in intensity usual in right-sided murmurs.

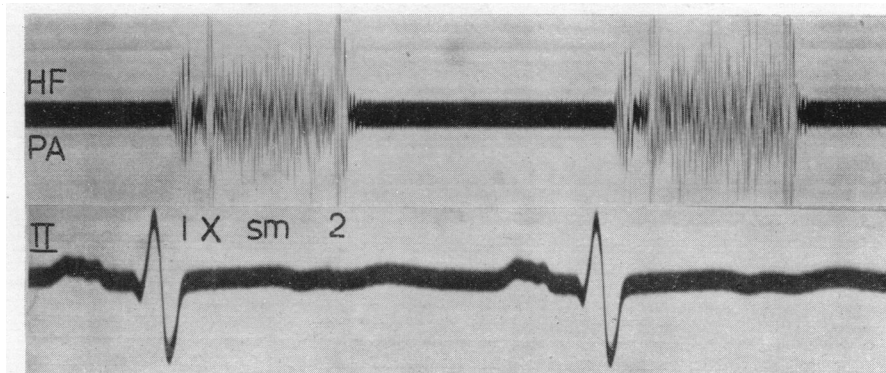


FIG. 8.—Fallot's tetralogy. Aortic early systolic ejection sound (X). Single second sound.

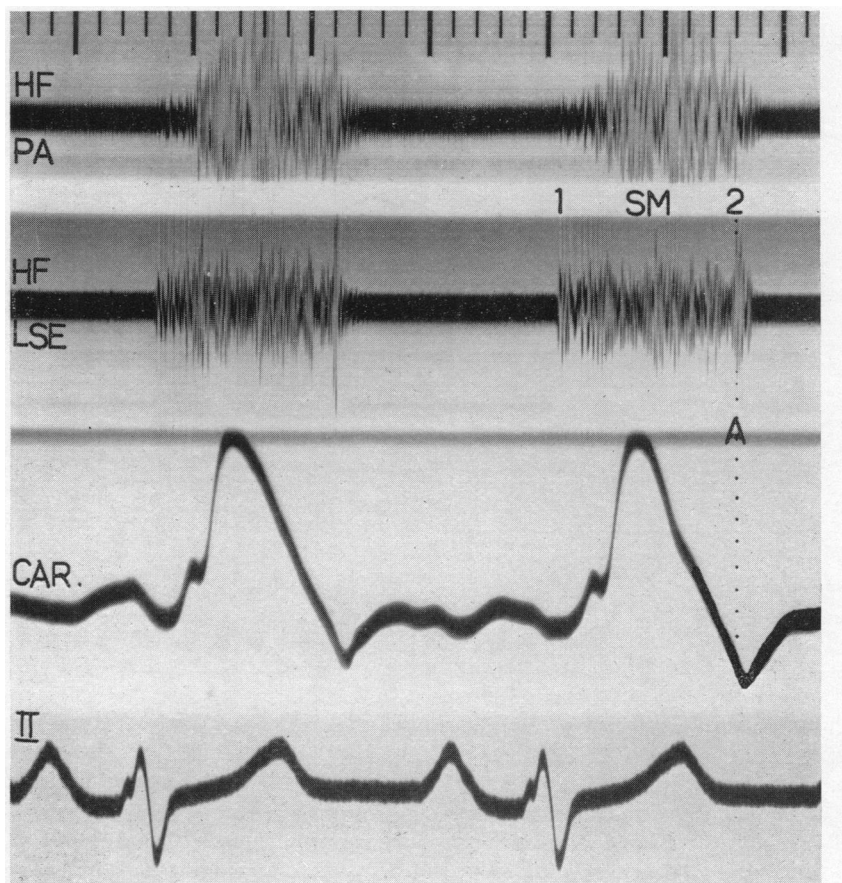


FIG. 9.—Fallot's tetralogy. Single second sound due to aortic closure; absent pulmonary component. Ejection systolic murmur extends up to aortic closure.

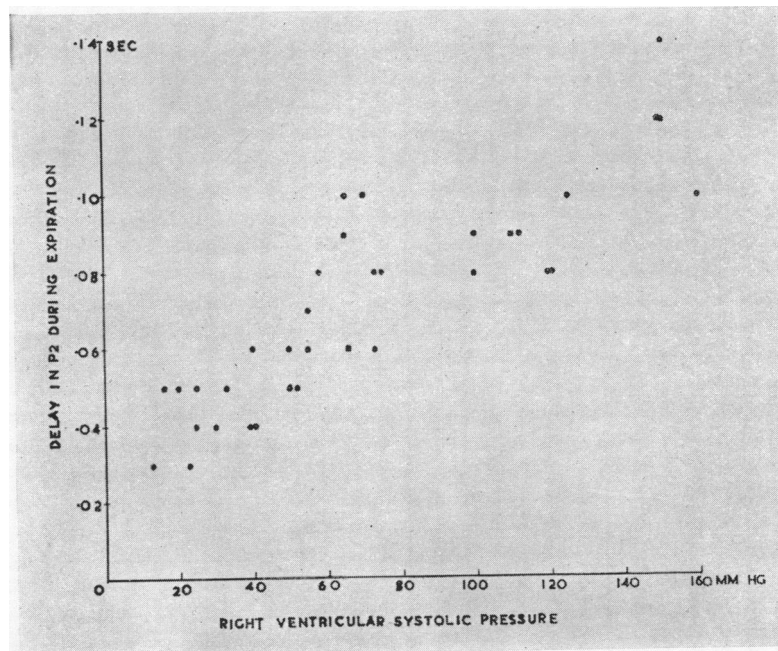


FIG. 10.—Relation of delay in pulmonary valve closure (width of splitting of second sound) to right ventricular systolic pressure in all cases in which a pulmonary component was recorded (Groups 1 and 2).

The intensity of the pulmonary systolic murmur in the patients with Fallot's tetralogy varied from grade 2 to grade 6, but was usually less loud (grade 3 or 4) than in the second group (grade 4 or 5). In seven patients the murmur was short, finishing before aortic closure, with a crescendo in mid-systole (Fig. 12, top channel), but in the majority the murmur (Fig. 9) was as long as in many patients in the second group (Fig. 5 and 6). An auricular systolic murmur of low intensity was recorded in two cases, both with dominant *a* waves in the neck. Early diastolic murmurs developed after operation in three cases (Fig. 11B), and were attributed to pulmonary incompetence, but insufficient studies were made for the incidence of this complication to be determined. The findings in the three groups are summarized in the table.

DISCUSSION

The anatomical and hæmodynamic features of pulmonary stenosis produce characteristic changes in the heart sounds. Dilatation of the pulmonary artery is associated with a pulmonary early systolic ejection sound in mild cases. The obstruction to right ventricular discharge prolongs right ventricular systole resulting in late closure of the pulmonary valve (Leatham, 1951, 1952; Borges *et al.*, 1952; Kjellberg *et al.*, 1955; Vogelpoel and Schrire, 1955) and produces an ejection type of systolic murmur (Leatham, 1955).

The pulmonary early systolic sound was present in all patients with mild stenosis including five of the mildest cases in the second group. It was always associated with a pressure change at valve level and obvious enlargement of the pulmonary artery. This sound was probably responsible for the impression of accentuation of the first sound mentioned by other authors, and Lian and Welti (1937) had described a protosystolic sound in cases of "congenital dilatation of the pulmonary artery". A pulmonary early systolic sound also occurs with dilatation of the pulmonary artery

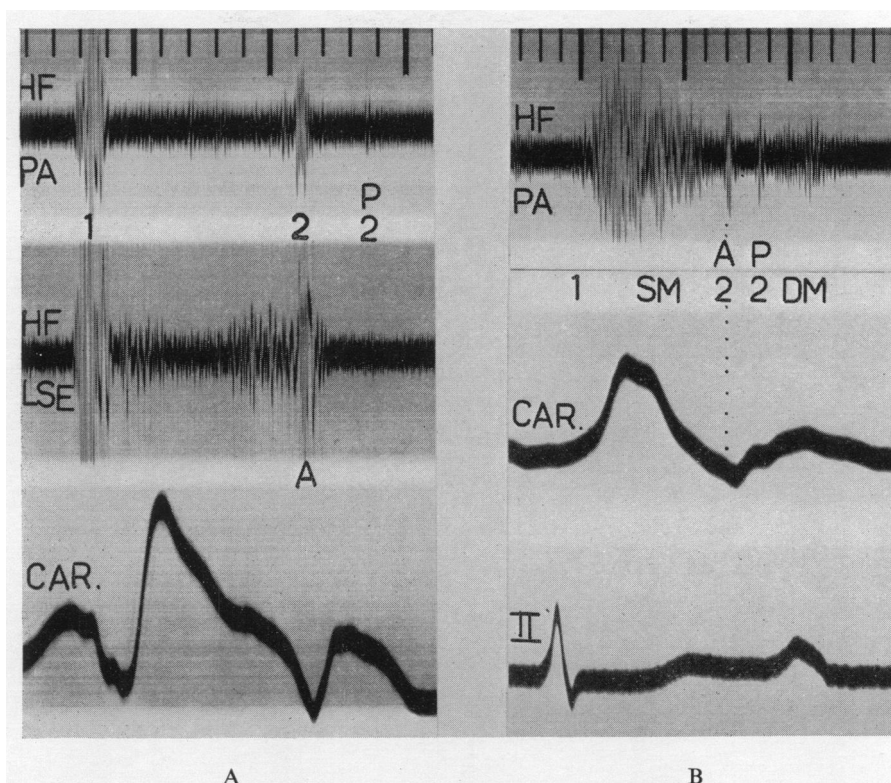


FIG. 11.—Fallot's tetralogy after operation. (A) After a Blalock operation pulmonary component of second sound appeared, 0.11 sec. after aortic component. (B) After subsequent valvotomy interval decreased to 0.06 sec. and there was an early diastolic murmur (DM).

from pulmonary hypertension and has been shown to fall in the ejection phase (Leatham and Vogelpoel, 1954). The early systolic sound in pulmonary stenosis has the same quality, site of maximum intensity, and relation to respiration; it also is, therefore, considered to be a pulmonary ejection sound. The sound was earlier in pulmonary stenosis (av. 0.05 sec. after first sound) than in pulmonary hypertension (av. 0.07 sec.) because the isometric time was shorter with the low diastolic pressure in the pulmonary artery. It was a sign of slight or moderate valve stenosis and was never found in severe cases or with infundibular stenosis in this series. The ejection sound is presumably caused by sudden distension of the dilated pulmonary artery and its absence in severe pulmonary stenosis may be related to slow rise of pulmonary artery pressure, and in infundibular stenosis to lack of dilatation of the pulmonary artery.

The dilated aorta found in Fallot's tetralogy and in pulmonary atresia was sometimes associated with an aortic ejection sound. This sound can usually be differentiated from the pulmonary sound by its site, lateness, and lack of variation with respiration. In practice, however, the need to differentiate between them does not arise since the pulmonary ejection sound occurs only in mild cases without cyanosis, and the aortic only in severe cyanotic cases when it indicates over-riding of the aorta rather than an inter-atrial shunt as the cause of the cyanosis. The aortic sound is seldom audible in Fallot's tetralogy, because it tends to be drowned by the loud systolic murmur. Conversely the sound is clearly heard in pulmonary atresia because a pulmonary systolic murmur is absent.

The second heart sound in the pulmonary area consists of aortic and pulmonary components. In healthy subjects the two components are about equal in intensity and are fused or closely split in expiration, separating during inspiration from delay in the pulmonary component. The interval

between the two components does not normally exceed 0.03 second in the expiratory phase of continuous respiration (Leatham, 1954).

The aortic component of the second sound can be heard in all patients with pulmonary stenosis, as clearly stated by Abrahams and Wood (1951), and may even be accentuated in Fallot's tetralogy. The pulmonary component was heard and recorded in all our cases with mild pulmonary stenosis and was of normal intensity. In 85 per cent of the more severe cases with pure pulmonary stenosis the pulmonary component was also present, though of reduced intensity. In assessing the severity of the stenosis, however, diminution of the intensity of the pulmonary component was less significant than its separation from the aortic component, which was always greater than normal in the expiratory phase of respiration. Of the possible causes for the increased separation of the two components, shortening of left ventricular systole and late activation of the right ventricle were excluded. It was found to be due to delay of pulmonary valve closure from prolongation of right ventricular systole and was a feature of all cases of pulmonary stenosis.

The time interval between aortic and pulmonary closure is a particularly accurate measure of the severity of the stenosis since the prolongation of right ventricular systole is measured in relation to left ventricular systole in the same patient and in the same cardiac cycle. This time interval is a useful guide to the right ventricular systolic pressure to which it generally bears a surprisingly close relation, considering that phonocardiography and catheterization were usually carried out at different times.

In contrast to this finding, the degree of right ventricular hypertrophy on the electrocardiogram was less closely related to the right ventricular systolic pressure. In eight patients with right ventricular systolic pressures of 120 mm. or more, the degree of right ventricular preponderance varied from slight to great, and in nine patients with moderate preponderance the right ventricular systolic pressures ranged from 50 to 160 mm. Where pulmonary valve closure can be recorded the phonocardiogram is a more reliable method of assessing severity than the electrocardiogram, especially in children in whom the normal right ventricular dominance makes the cardiographic assessment of right ventricular hypertrophy difficult.

While the soft late pulmonary component of the second sound could usually be discerned by careful auscultation, the aortic component, though clear at the apex, was frequently obscured at the pulmonary area by the loud long systolic murmur. Between the apex and pulmonary area both components could sometimes be heard, but phonocardiograms taken synchronously from the two areas were often needed to appreciate this sign and to obtain the exact time interval between the two components.

The frequency with which the pulmonary component can be heard in pure pulmonary stenosis contrasts with its rarity in Fallot's tetralogy, where it was absent in all our cases before operation because of the greater diminution of pulmonary artery flow in Fallot's tetralogy (Leatham, 1954). This was also found by Vogelpoel and Schrire (1955) whose clear recordings showed a pulmonary component in only 3 (heard in one) of their 18 cases of Fallot's tetralogy. In our cases, the average pulmonary artery flow was 2.7 litres a minute in the Fallot group compared with 5.4 litres in pure pulmonary stenosis, confirming the findings of Soulié *et al.* (1951a). The greater diminution of pulmonary flow in Fallot's tetralogy is probably due more to the easier outlet offered by the over-riding aorta and ventricular septal defect than to any greater degree of stenosis.

An alternative explanation for the inaudibility of the pulmonary component in Fallot's tetralogy, is that the aortic and pulmonary valves close simultaneously. This is impossible since the ventricular pressure in Fallot's tetralogy at the time of aortic valve closure must be only just below the systemic diastolic pressure, and still greatly above the low pulmonary artery pressure, making it impossible for the pulmonary valve to close at this point. Hence right ventricular systole must be prolonged as in pure pulmonary stenosis. This was confirmed by the first appearance of a delayed pulmonary component (0.11 sec. after aortic closure) in one of our cases after a Blalock's operation, and in two others after valvotomy (delay 0.05 and 0.12 sec.). It follows that the presence of the pulmonary component of the second sound (recorded or heard) in rare cases of Fallot's tetralogy

should indicate a greater pulmonary flow than usual and this has been shown in one case by Vogelpoel and Schrire (1955). Similarly the absence of the pulmonary component in a few cases of severe pure pulmonary stenosis was always associated with an unusually small pulmonary flow.

With these reservations we found that the presence or absence of a pulmonary component of the second sound was of great help in differentiating between Fallot's tetralogy and pure pulmonary stenosis with cyanosis due to a reversed inter-atrial shunt.

In every patient with pulmonary stenosis there is a systolic murmur due to the ejection of blood through the narrowed infundibulum or pulmonary valve. This murmur rises to a crescendo about the mid point of right ventricular systole. Because right ventricular systole is prolonged, the murmur may go up to or past aortic closure but always finishes before pulmonary closure. In pure pulmonary stenosis the entire output of the right ventricle must be discharged through the obstructed outlet, while in Fallot's tetralogy the over-riding aorta offers an alternative pathway. Hence the pulmonary flow tends to be greater, and the systolic murmur louder, in pure pulmonary stenosis than in Fallot's tetralogy with the same degree of obstruction. This difference in intensity of the murmur is well known (Soulié *et al.*, 1951*b*). When there is considerable over-riding the pulmonary flow may be so reduced that only the maximum flow in mid-systole is sufficient to produce audible vibrations, but increased amplification shows that the murmur is longer, going at least as far as aortic closure (Fig. 12). This probably accounts for the fact that in severe cases with a short murmur the diagnosis always proved to be Fallot's tetralogy, as stated by Vogelpoel and Schrire (1955). Conversely a murmur sufficiently long to extend past aortic closure was always associated with a closed ventricular septum. In many of our patients, however, whether the diagnosis was Fallot's tetralogy or pure pulmonary stenosis, the murmur was of intermediate length extending up to but not beyond aortic closure, and was of no help in differentiating the two conditions.

The site of the obstruction, valvular or infundibular, did not appear to influence the sounds and murmurs. In four patients with normal aortic root there was good evidence from cardiac catheterization and angiocardiography that the stenosis was low infundibular rather than valvular, although operation or necropsy proof was lacking. The systolic murmur and second heart sound showed the same characteristic features as in valvular stenosis. Mannheim and Jonsson (1954) found an earlier crescendo in two of their cases diagnosed by selective angiocardiography. We confirmed this in one case (Fig. 7), but not in others (Fig. 6). The rarity of pure infundibular stenosis and lack of proof of the diagnosis in our cases prevents definite conclusions.

Diastolic murmurs were seldom obvious. In five patients in the second and third groups auricular systolic murmurs were recorded, usually of low intensity and inaudible. In one patient with low infundibular stenosis this murmur was loud in the pulmonary area, increased on inspiration, and *a* waves were found on the pressure tracing from the pulmonary artery. All these patients had giant *a* waves in the neck and the atrial systolic pressure exceeded the pulmonary diastolic pressure. It seems reasonable to conclude that the atrial systolic murmur is caused by flow through the pulmonary valve as a result of atrial contraction.

DIFFERENTIAL DIAGNOSIS

Other possible causes for a pulmonary systolic murmur are increased pulmonary flow and dilatation of the pulmonary artery. The characteristics of the second sound are of considerable help in differentiating these conditions. In atrial septal defect the increased pulmonary flow causes a short ejection systolic murmur, of similar pattern to that found with mild pulmonary stenosis, and wide splitting of the second heart sound which has come to be recognized as an obvious physical sign (Barber *et al.*, 1950). The pulmonary component is then of normal or increased intensity (often transmitted to the apex) and the separation of the two components does not alter with respiration and does not exceed 0.05 sec. (Leatham and Gray, 1956), unlike pulmonary stenosis.

In dilatation of the pulmonary artery without increased flow, as in pulmonary hypertension,

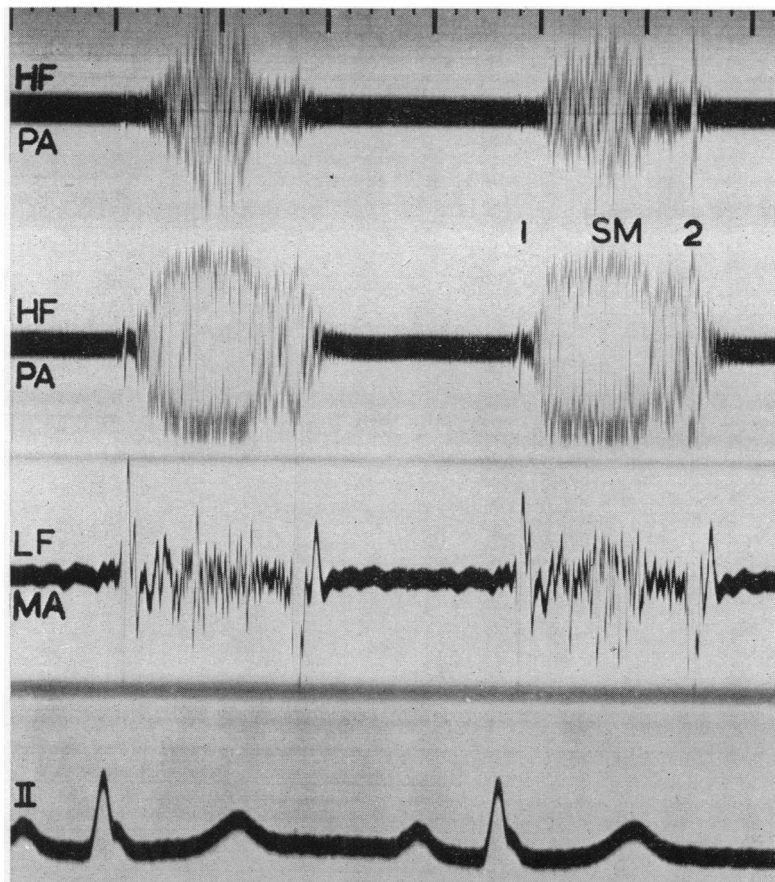


FIG. 12.—Fallot's tetralogy. Ejection systolic murmur with crescendo in early or mid-systole dwindling before single second sound (top channel). Increased amplification (with voltage limitation) shows that murmur continues past aortic closure (second channel).

there may be a soft or moderately loud ejection systolic murmur, but there is normal close splitting of the second sound with accentuation of the pulmonary component and frequently a pulmonary diastolic murmur.

Where there is increased flow, without dilatation of the pulmonary artery, in anæmia, thyrotoxicosis, pregnancy, and other high output states, the systolic murmur is seldom loud, and splitting of the second sound is normal and confined to the inspiratory phase of respiration since the high flow is affecting both sides of the heart equally. The pulmonary component is of normal intensity. The innocent pulmonary ejection murmur so commonly found in healthy young people is also associated with normal splitting of the second sound.

The harsh pansystolic murmur of ventricular septal defect may closely resemble the murmur of pulmonary stenosis, but its site of maximum intensity is lower, and splitting of the second sound is normal or only slightly increased in width with no diminution of the pulmonary component. Attention to the second heart sound is thus of great importance in deciding the cause of a pulmonary systolic murmur. Only in pulmonary stenosis is the pulmonary component of reduced intensity (or even absent) and separated from the aortic component by more than 0.05 sec.

SUMMARY

A graphic analysis of the heart sounds and murmurs has been made in 70 patients with pulmonary stenosis. The diagnosis has been confirmed by cardiac catheterization or operation in all. The patients fell into three groups each with typical auscultatory and phonocardiographic findings.

In the first group the stenosis was mild and isolated, the electrocardiogram normal, and the right ventricular systolic pressure less than 40 mm. Hg. The first heart sound was invariably followed by an early systolic ejection sound giving the impression of wide splitting of the first sound at the pulmonary area. Splitting of the second heart sound was abnormally wide. The pulmonary component was delayed and was of normal intensity. There was a soft mid-systolic ejection murmur.

In the second group the stenosis was moderate or severe (right ventricular pressure 50–150 mm.) with a normal aortic root. In some there was cyanosis from an inter-atrial shunt. A pulmonary ejection sound was found only in the milder cases. The pulmonary component of the second sound was present in 85 per cent and was soft and greatly delayed. The interval between aortic and pulmonary components was closely related to the right ventricular systolic pressure. The pulmonary component was absent only in the most severe cases. The loud ejection systolic murmur extended up to, and sometimes beyond, the aortic component of the second sound.

The third group consisted of patients with Fallot's tetralogy. The greater reduction of pulmonary flow was associated with a shorter and softer systolic murmur in some cases, and with absence of the pulmonary component of the second sound except following operation.

We would like to express our gratitude to the Physicians to the Heart Hospital for encouraging us to study their cases and to Dr. William Evans and Dr. Paul Wood for much helpful advice. We are also indebted to the technical staff of the Institute of Cardiology for help with the recordings.

REFERENCES

- Abrahams, D. G., and Wood, P. (1951). *Brit. Heart J.*, **13**, 519.
 Barber, J. M., Magidson, O., and Wood, P. (1950). *Brit. Heart J.*, **12**, 277.
 Borges, S., Yunes, A., Nicolai, A., Ramos, O., Portugal, O., and Medanar, H. (1952). *Arqu. Brasil Cardiol.*, **5**, 399.
 Coblenz, B., Harvey, R. M., Ferrer, M. I., Cournand, A., and Richards, D. W. (1949). *Brit. Heart J.*, **11**, 1.
 Freeman, A. R., and Levine, S. A. (1933). *Ann intern. Med.*, **40**, 521.
 Greene, D. G., Baldwin, E. de F., Baldwin, J. S., Himmelstein, A., Roh, C. E., and Cournand, A. (1949). *Amer. J. Med.*, **6**, 24.
 Kjellberg, S. R., Mannheimer, E., Rudhe, U., and Jonsson, B. (1955). *Diagnosis of Congenital Heart Disease*. Year Book Publishers, Chicago.
 Leatham, A. (1951). *Brit. Heart J.*, **13**, 153.
 — (1952). *Brit. med. Bull.*, **8**, 333.
 — (1954). *Lancet*, **2**, 607.
 — (1955). *Brit. Heart J.*, **17**, 574 (Proc.).
 — and Vogelpoel, L. (1954). *Brit. Heart J.*, **16**, 21.
 — and Gray, I. (1956). *Brit. Heart J.*, **18**, 193.
 Lian, C., and Welti, J. J. (1937). *Arch. Mal. Cœur.*, **30**, 847.
 Mannheimer, E., and Jonsson, B. (1954). *Acta Pædiatrica.*, **43** (Supp. 100), 167.
 Peacock, T. B. (1866). *On Malformations of the Human Heart*. 2nd ed. Churchill, London: p. 113.
 Petit, A. (1902) in *Traité de Médecine de Charcot, Bouchard, et Brissaud*. (vol. 8). 2nd ed. Masson et Cie, Paris.
 Soulié, P., Joly, F., Carlotti, J., and Sicot, J. R. (1951a). *Arch. Mal. Cœur.*, **44**, 577.
 —, Nouaille, J., Schweisguth, O., Joly, F., Carlotti, J., and Sicot, J. R. (1951b). *Bull. Soc. méd. Hôp. Paris*, **13**, 495.
 Vogelpoel, L., and Schrire, V. (1955). *Circulation*, **11**, 714.