

## FAMILIAL CARDIOMEGALY

BY

G. GARRETT,\* W. J. HAY, AND A. G. RICKARDS

*From the Royal Lancaster Infirmary, Lancaster*

(RECEIVED FOR PUBLICATION SEPTEMBER 18, 1957)

In 1949 William Evans gave the name of familial cardiomegaly to what he believed to be a "distinct syndrome having a definite clinical, cardiographic, and pathological pattern." The essential features were the familial incidence of cardiomegaly without obvious cause and a marked tendency to arrhythmia and heart block with associated palpitation, giddiness, and syncope. Death may be sudden or rapid due to the development of left ventricular failure. In the electrocardiogram the QRS complexes are often exceptionally wide and the T waves inverted. Conspicuous myocardial fibrosis and hypertrophy of the remaining muscle fibres are the striking pathological findings. Both the degree of conduction defect and the prognosis seem to depend on the extent of myocardial fibrosis and cardiac enlargement.

Evans referred to two previous accounts of obscure cardiomegaly occurring in members of the same family published in the case records of the Massachusetts General Hospital in 1942 and by Addarii (1943) and Addarii, Martini, Mahaim, and Winston (1946). Subsequently cases have been published by Davies (1952), Parsons (1952), De Matteis and Ozzano (1954), Campbell and Turner-Warwick (1956), Gaunt and Lecutier (1956), and Paulley, Jones, Green, and Kane (1956). Among these, however, are included cases of cardiomegaly with no supporting family history and others where there is good reason to believe that the cardiac hypertrophy was secondary to acquired valvular disease, congenital cardiac malformations, or toxoplasmosis. In our view the diagnosis of familial cardiomegaly should only be made when other causes of cardiac enlargement have been excluded and when there is a clear supporting family history. Moreover, in the present state of knowledge, it seems wise only to include those cases where the diagnosis has been established by necropsy study in at least one affected member of the family. The reports of seven affected families (15 cases) comply with

these criteria and include eight necropsy studies. Only these cases are included in Table I and the subsequent discussion.

The purpose of this paper is to present a further example of a family with cardiomegaly, the three affected members of which died suddenly. Post-mortem studies were made in all three cases although in one details of the necropsy findings are no longer available.

### Case Histories

**Case 1.**—G. D., a man aged 30 years at death, came home from work one evening in April, 1956, in his usual good health, and while playing with his children in the garden suddenly collapsed and died. There was no history of rheumatic fever or other serious illness in the past. Eight months before his death he sustained a slight injury to the right groin with haematoma formation in the spermatic cord. His wife thought that he was slow to pick up after that accident, but he eventually recovered, and his mother, who was with him on the day before he died, remarked that she thought he was in excellent health. At no time was he heard to complain of dyspnoea, chest pain, faintness, or palpitation.

Necropsy performed by one of us (A. G. R.) on the instructions of the coroner 21 hours after death revealed the following abnormalities.

The body was that of a well-built young male with a previous appendectomy scar; significant macroscopic findings were confined to the thoracic cavity. The heart was markedly enlarged (weight 500 g.), the hypertrophy mostly affecting the left ventricle, which in parts was nearly 2 cm. thick and appeared at first sight to be of the usual hypertensive type. On closer inspection it was seen that the outer part of the myocardium consisted of pale fibrous tissue almost giving the impression of an outer shell surrounding the inner layer (Fig. 1). Strands of fibrous tissue could be seen penetrating the deeper aspects of the myocardium, but the predominantly peripheral distribution was striking. The compact outer rim was well demarcated from the rest of the myocardium except in the region of the interventricular septum where its discrete pattern became replaced by diffuse fibrotic mottling. The trabeculae carnae, papillary muscles, and chordae tendineae showed no evidence of fibrosis. The right ventricle and both auricles

\*Present address: Department of Clinical Pathology, Manchester Royal Infirmary.

TABLE I  
MAIN CLINICAL FEATURES

No.	Author	Author's Case No.	Age ( )—Age at Death	Sex	Family Relationship	Main Symptoms	Arrhythmias	Heart Block	Length of History from Onset of Symptoms	Necropsy Findings
1	Case records of M.G. Hosp. (1942)	1	(21)	M	Brother with congestive failure. Sister with cardiomegaly A-V block and congestive failure	Dyspnoea, fatigue, congestive failure		Complete A-V block	6 months	Yes
2	Addarii <i>et al.</i> (1943)	1	(?)	M	Brother of Case 3	Dyspnoea, syncope	Auricular fibrillation	Complete A-V block, branch bundle block	?	..
3	Addarii <i>et al.</i> (1946)	1	(21)	M	Brother of Case 2. Mother died C.C.F. and syncope	Dyspnoea, fatigue, syncope, congestive failure	Auricular fibrillation, paroxysmal tachycardia	Complete A-V block, branch bundle block	15 years	..
4	Evans (1949)	1	(18)	M	Son of Case 6. Brother of Case 5	Giddiness, paroxysmal tachycardia	Paroxysmal tachycardia, extrasystoles	Branch bundle block	2 months	..
5	.. ..	2	20	M	Son of Case 6. Brother of Case 4	Giddiness	Auricular fibrillation, paroxysmal auricular tachycardia	.. ..	6 ..	—
6	.. ..	3	43	F	Mother of 4 and 5. Three of her siblings believed affected	Syncope	Auricular fibrillation, extrasystoles	—	12 years	—
7	.. ..	8	(16)	M	Son of Case 8	..	Sinus bradycardia	—	4½ ..	Yes
8	.. ..	App.	42	F	Mother of Case 7	Paroxysmal, tachycardia with occasional syncope	Paroxysmal tachycardia	Prolonged P-R interval, branch bundle block	2 months	—
9	Gaunt and Lecutier (1956)	1	(51)	M	Brother of Case 11	Dyspnoea, syncope	Auricular fibrillation	Complete A-V block	20 ..	Yes
10	.. ..	2	23	F	Daughter of Case 11	Arthralgia, slight dyspnoea	—	—	3 ..	—
11	.. ..	3	(53)	F	Mother of Case 10. Sister of Case 9	Syncope, dyspnoea	—	Complete A-V block, branch bundle block	4 years	—
12	Campbell and Turner-Warwick (1956)	1	(23)	M	Son of Case 13	Syncope, palpitation, dyspnoea, severe chest pain	Paroxysmal tachycardia, ventricular extrasystoles	Prolonged P-R, branch bundle block	3 years	Yes
13	.. ..	2	(29)	F	Mother of Case 12. Eight of her 12 siblings died of heart disease under 40 years	Dyspnoea, congestive failure, syncope	—	Branch bundle block	1 year	—
14	.. ..	3	(36)	M	Son of Case 15	Syncope	Sinus and nodal bradycardia, nodal or ventricular extrasystoles	Varying degrees of A-V block, branch bundle block	6 months	Yes
15	.. ..	4	66	F	Mother of Case 14. Her sister, mother, three aunts, and grandmother died of heart disease	Faintness, fatigue, dyspnoea	Paroxysmal auricular flutter, sinus bradycardia	Branch bundle block	40 years	—

appeared unaffected, and the pericardium and endocardium were also macroscopically normal. The aorta merely showed slight atheroma of its first part, and there was no evidence of coarctation. The lungs were engorged and the trachea and bronchi contained a large amount of mucus; all the other organs, including the brain and spinal cord, appeared normal to the naked eye.

Microscopic examination of the left ventricle showed marked hypertrophy of individual muscle fibres associated with gross fibrosis of the

myocardium distributed peripherally and corresponding to the area seen with the naked eye. The fibrous strands tended to separate the muscle fibres into bundles (Fig. 2) and many of these isolated lobules of muscle showed degenerative changes similar to those seen in early cell death following ischaemia (Fig. 3); slight infiltration with lymphocytes was seen in occasional areas of fibrosis (Fig. 4). The right ventricle showed a similar pattern of interstitial fibrosis, although of lesser extent, and its distribution was more irregular and was not confined to the

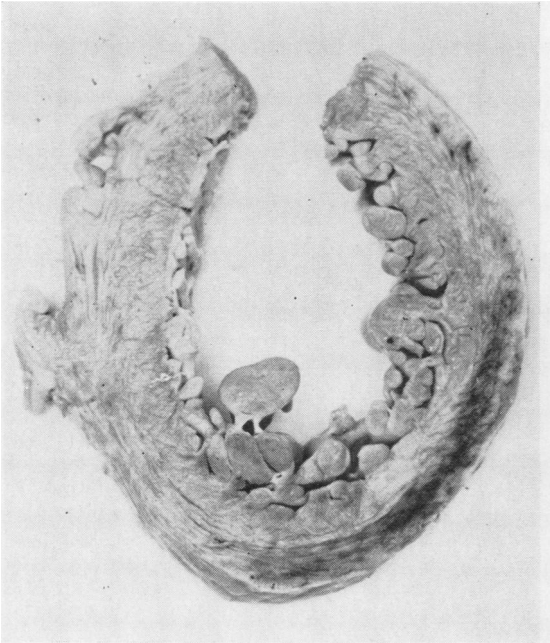


FIG. 1

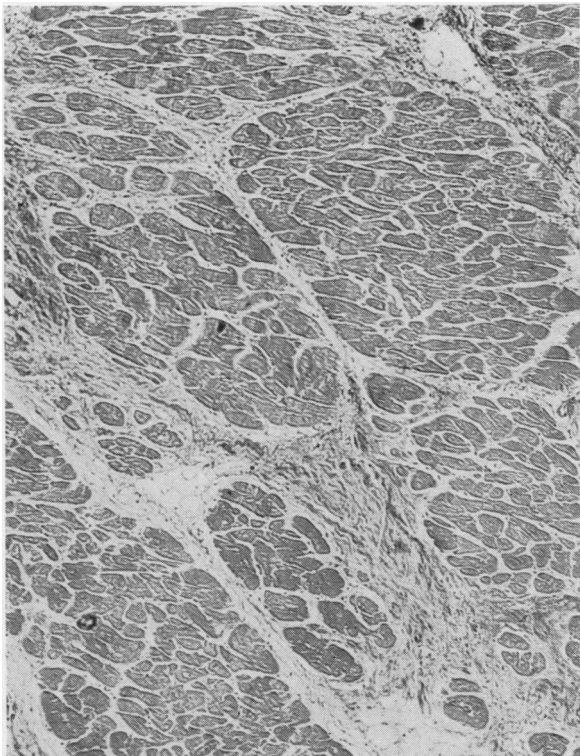


FIG. 2

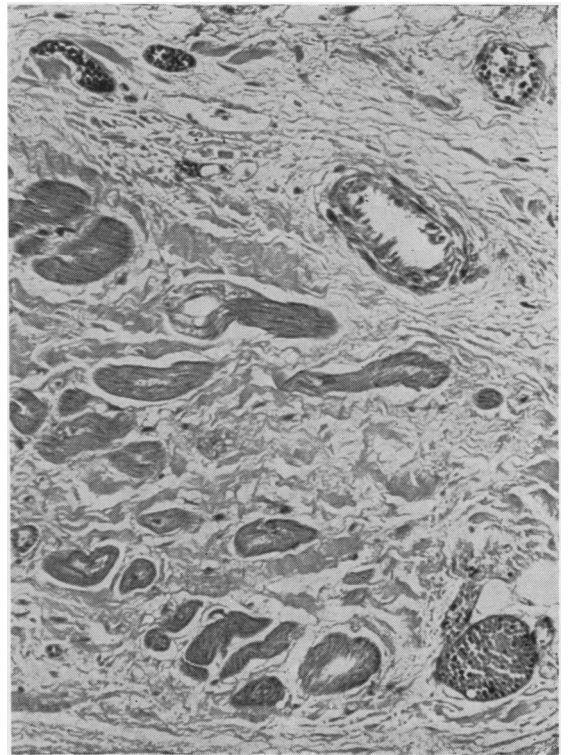


FIG. 3

FIG. 1.—Cross section of left ventricular wall showing peripheral fibrotic mottling in Case 1.

FIG. 2.—Trabeculated fibrosis of the left ventricle in Case 1. Haematoxylin and eosin,  $\times 60$ .

FIG. 3.—Degenerative change in muscle fibres surrounded by fibrous tissue in Case 1. Haematoxylin and eosin,  $\times 150$ .

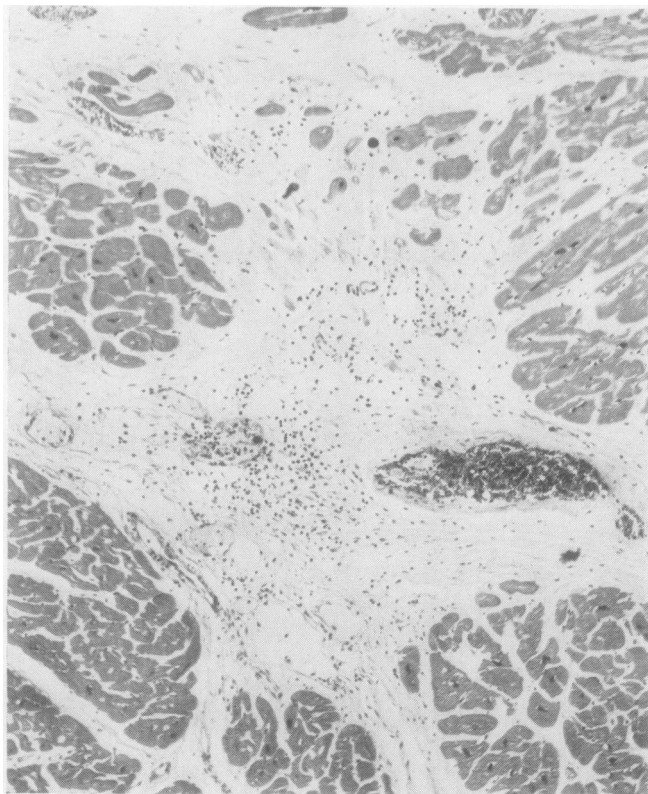


FIG. 4.—Slight lymphocytic infiltration in fibrotic areas in Case 1. Haematoxylin and eosin,  $\times 80$ .

peripheral areas; the left auricle was normal, but slight fibrotic changes were present in the wall of the right chamber. There was no histological evidence of amyloidosis and stains for amyloid were negative. The endocardium was normal and the coronary arteries and arterioles showed no evidence of disease. Histological examination of the thyroid, testes, kidneys, thymus, pancreas, liver, adrenal glands, pituitary, spleen, brain, spinal cord, and voluntary muscle revealed no significant abnormality. The lungs showed basal venous engorgement and the aorta some soft atheroma.

**Case 2.**—K. D., the sister of Case 1, died suddenly at the age of 18 years on December 26, 1946. There was no history of previous ill-health. The day before her death was spent working, as usual, as a telephonist at the Post Office. Next morning she felt off-colour, became pale and faint, and complained that her legs were numb. She developed increasing shortness of breath with frothy sputum, white at first but later tinged with pink. She died shortly before midnight.

Her death was the subject of a coroner's inquiry, and the necropsy report gave as the main findings cardiac enlargement and pulmonary oedema. The heart was said to show "a little fibrosis of the

papillary tips," but unfortunately the myocardium was not examined histologically. The coronary arteries were recorded as being normal. Various organs were examined for a wide variety of chemical poisons with negative results, death being eventually attributed to "acute pulmonary oedema precipitated by streptococcal pneumonia." From the description of the lungs and heart it seems clear that in fact death was due to left ventricular failure.

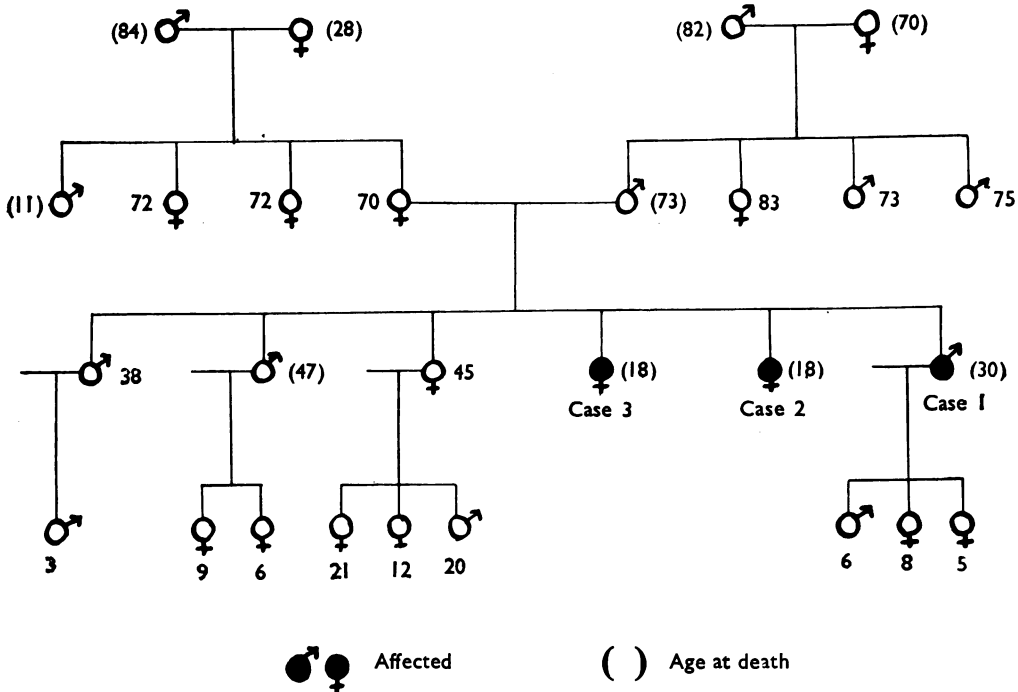
**Case 3.**—P. D., the sister of Cases 1 and 2, also died suddenly at the age of 18 years on December 26, 1939, exactly seven years before the death of her sister. In this case also there was no history of previous ill-health. She was dancing without distress until after midnight, when she returned home and retired to bed. A few minutes later her parents went in to see her and found her dead. Her case was also the subject of a coroner's inquiry, but copies of the post-mortem findings are no longer available although it appears from the records that the precise cause of death was never established.

**Other Relatives.**—The antecedents of these three cases (Table II) on both male and female sides have in general been long-lived, but, of the exceptions, their mother's only brother died at the age of 11 years from pneumonia, and her mother died at the age of 28 years during childbirth. One of their brothers committed suicide but was known to be physically well. Their mother is an obese, arthritic woman, with a blood pressure of 170/100 mm. Hg, slight dyspnoea on exertion, and occasional swelling of the ankles. Radiographs of the chest showed no cardiac enlargement and an electrocardiogram was normal. The surviving siblings and all the nine members of the next generation, with the exception of one young man in the Navy, have been examined clinically and radiologically without finding any evidence of cardiomegaly. Electrocardiograms have been taken of five members of the family and show no abnormality.

### Discussion

Study of the pathological appearances of the heart in these cases and in the eight previous necropsy reports referred to in Table I reveals no uniform pattern and indeed the variability of the post-mortem findings suggests that the cases listed here as examples of familial cardiomegaly may have had more than one cause. For descriptive purposes they may be separated into those in which the muscle hypertrophy was the main or only abnormal finding and those in which hypertrophy was accompanied by widespread interstitial fibrosis.

TABLE II  
FAMILY TREE



Only two cases fall into the first category, namely, Cases 1 and 14 (Table I). In the former case the heart weighed 600 g. and was grossly dilated, being described by Dr. Tracy Mallory as "one of the largest hearts from the point of view of capacity that we have ever seen." All the chambers shared in the hypertrophy, but there was no other microscopic abnormality of the myocardium. In Campbell and Turner-Warwick's case the heart weighed 1,050 g., chiefly due to hypertrophy of the left ventricle which measured up to 25 mm. in thickness. Histologically there was simple hypertrophy of muscle fibres some of which showed central vacuolation; the nature of the vacuolar material was not established, but stains for fat and glycogen were negative.

The remaining cases belong to the second fibrotic group (Cases 2, 3, 4, 7, 9, and 12 in Table I and our own Case 1). Moderate or marked cardiac hypertrophy was present in all, the lowest heart weight recorded being 737 g. (Case 9) and the highest 1,134 g. (Case 4). Extensive myocardial fibrosis was present in all cases although the precise distribution of the fibrous tissue is not always recorded. In most the fibrosis affected both right and left ventricular walls, but in few was there any reference to the histological

appearance of the auricles. In no case has there been found any macroscopic or microscopic evidence of disease of the coronary arteries. Occasional focal collections of chronic inflammatory cells have been noted in two cases (Cases 12 and 3) similar to the occasional foci present in the first case described here; Case 3 also showed patchy necrosis of muscle fibres similar to that occurring in our Case 1. Two of the cases in this fibrotic group (4 and 9) have shown unusually marked deposits of glycogen within the muscle fibres, although similar in other respects to the remainder of the group.

Consideration of these pathological types suggests a fundamental difference between those showing extensive myocardial fibrosis and those in which the pathological picture is one of simple hypertrophy. Despite the not dissimilar clinical features it seems unlikely that these are different stages of the same disease process or indeed that they have any aetiological relationship. The two types have not been found in the same family.

The picture of the fibrotic type appears to be that of replacement fibrosis and survival hypertrophy. Previous episodes of myocarditis which might account for this picture have naturally been sought in case histories. Rheumatic infection is recorded in only three cases (11, 12, and 13), in

two of which the diagnosis was doubtful; Aschoff nodes were not found in the only case which came to necropsy. In the remaining cases there is no history of illness suggesting Fiedler's or other non-rheumatic myocarditis.

Paulley, Jones, Green, and Kane (1956) have, however, described several cases of fibrotic cardiomegaly which they attributed, on the basis of positive serological reactions, to toxoplasmosis. In one family, at least three of the four cases coming to necropsy showed a fibrotic cardiomegaly similar to that described above, although atypical in that the left ventricle was not predominantly affected and mural thrombus and embolism was a marked feature. Moreover, two of the four cases had enlarged firm spleens. Clinically their cases bore less resemblance to familial cardiomegaly, the absence of syncope being particularly noteworthy. Paulley *et al.* (1956) were unable to demonstrate toxoplasma bodies in the myocardium of their cases and positive serological reactions cannot be considered as conclusive evidence of active toxoplasma bodies from a case of obscure myocarditis in which evidence of generalized toxoplasmosis was lacking, but toxoplasma infection may well have been the aetiological factor in the cases of Paulley *et al.* In view of their findings we obtained samples of serum for toxoplasma antibody titration from a brother, son, and wife of our Case 1 and in no instance was a significant antibody titre recorded.

The finding of glycogen deposits in the muscle fibres in Cases 4 and 9 raises the question as to whether some cases of familial cardiomegaly may be due to a disorder of glycogen metabolism. In a few cases of Von Gierke's disease, glycogen infiltration has been confined to the heart, so-called "cardiomegalia glycogenica," but di Sant'Agnes, Andersen, and Mason (1950), who have recently reviewed this subject, consider that a fatal termination within the first year of life is invariable in this condition, and, moreover, those cases of glycogen storage disease in which the heart is involved do not progress to myocardial fibrosis. Russell (1948), in trying to assess the significance of the presence of muscle glycogen deposits in post-mortem tissue, examined specimens of muscle from 11 necropsy cases taken at varying intervals after death; although she was able to demonstrate glycogen in the muscle fibres the infiltration was scanty compared with that found in the first case described by Evans (1949). The exact significance of these glycogen deposits is obscure, but the mere presence of glycogen within the myocardium does not provide a basis

for the diagnosis of glycogen disease. In the light of our present knowledge it seems more reasonable to regard the deposits as a non-specific infiltration which may complicate the pathological pattern of the fibrotic form of familial cardiomegaly.

A further possible aetiological factor is the curious association between cardiomegaly and two familial neurological conditions, Friedreich's ataxia and progressive muscular dystrophy. The association of myocarditis with Friedreich's ataxia was first recorded by Pitt (1886-7). Several reports later appeared in the Continental literature and in 1946 Russell reported four examples of the condition with post-mortem details; not infrequently the neurological lesion is accompanied by a chronic progressive myocarditis of fibrotic type which closely resembles that found in the fibrotic form of familial cardiomegaly. It was Russell's opinion that the heart muscle is destroyed through a focal, piecemeal, coagulative necrosis as a result of which the fibres are ultimately replaced by collagenous tissue, the surviving muscle undergoing a compensatory hypertrophy. This description could well be applied to the histological appearances in the cases of familial cardiomegaly now described, although, as Evans (1949) comments, "the relation of this condition to Friedreich's disease would be more definitely established if instances of each were met with in one family." Roth (1948) described a family affected by Friedreich's disease and peroneal muscular dystrophy in which there was a high incidence of heart disease, but there was no evidence to suggest that they were cases of familial cardiomegaly. Some 30 cases of cardiac involvement have been reported in progressive muscular dystrophy and the subject has recently been reviewed by Bevans (1945) and Storstein and Austarheim (1955). The post-mortem appearances of the heart in these cases seem to show a very variable picture; sometimes the hearts are atrophic and in other cases marked hypertrophy is found. Macroscopically fatty infiltration and intracellular vacuolation of the fibres has been described; in several cases a patchy fibrosis, often maximal in the outer myocardium, has been present. This association of hereditary neuropathies and fibrotic cardiomegaly has suggested to some that the cardiopathies in the familial and neuropathic varieties may have a common aetiology which may lie in an as yet undetected inborn error of metabolism. Support for this "chemical theory" of diffuse cardiac fibrosis is reinforced by the knowledge that diffuse

myocarditis may follow the ingestion of a variety of chemical compounds including arsenicals, sulphur, and sulphonamides (Elster, Horn, and Tuchman, 1955), and recently McAllen (1955) has observed severe myocardial changes, including widespread fibrosis, supervene in two cases in which there was prolonged depletion in potassium absorption. These human lesions were strikingly similar to the cardiac lesions found in potassium-deficient animals.

In conclusion it must be admitted that in spite of the numerous theories of origin, the aetiology of familial cardiomegaly still remains obscure.

### Summary

A family with cardiomegaly is described in which the three affected members died suddenly when apparently in good health and were submitted to necropsy.

The clinical and pathological features of these and previously published cases of familial cardiomegaly are discussed and the possible aetiology of the condition considered.

Our thanks are due to Mr. L. G. Powell, H.M. Coroner for South Westmorland, for making available previous post-mortem reports.

### REFERENCES

- Addarii, F. (1943). *Boll. Sci. med.*, **21**, 41.  
 — Martini, L., Mahaim, I., and Winston, M. (1946). *Cardiologia (Basel)*, **11**, 36.  
 Bevans, M. (1945). *Arch. Path. (Chicago)*, **40**, 225.  
 Campbell, M., and Turner-Warwick, M. (1956). *Brit. Heart J.*, **18**, 393.  
 Case Records of Massachusetts General Hospital (1942). *New Engl. J. Med.*, **226**, 158.  
 Davies, L. G. (1952). *Brit. Heart J.*, **14**, 206.  
 De Matteis, F., and Ozzano, T. (1954). *Minerva med. (Torino)*, **45**, (1), 1549.  
 di Sant'Agnese, P. A., Andersen, D. H., and Mason, H. H. (1950). *Pediatrics*, **6**, 607.  
 Elster, S. K., Horn, H., and Tuchman, L. R. (1955). *Amer. J. Med.*, **18**, 900.  
 Evans, W. (1949). *Brit. Heart J.*, **11**, 68.  
 Gaunt, R. T., and Lecutier, M. A. (1956). *Ibid.*, **18**, 251.  
 McAllen, P. M. (1955). *Ibid.*, **17**, 5.  
 Parsons, P. J. (1952). *Med. J. Aust.*, **2**, 435.  
 Paulley, J. W., Jones, R., Green, W. P. D., and Kane, E. P. (1956). *Brit. Heart J.*, **18**, 55.  
 Pitt, G. N. (1887). *Guy's Hosp. Rep.*, **44**, 369.  
 Roth, M. (1948). *Brain*, **71**, 416.  
 Russell, D. S. (1946). *J. Path. Bact.*, **53**, 739.  
 — (1948). Quoted by Evans (1949).  
 Storstein, O., and Austarheim, K. (1955). *Acta med. scand.*, **150**, 431.