

Intestinal Duplication Cyst Misdiagnosed as Meckel's Diverticulum

Yee-Suk Kim¹, Dong-Ju Kim², Seung-Uk Bang¹, Jun-Jae Park¹

¹Department of Anesthesiology and Pain Medicine, College of Medicine, The Catholic University of Korea, Seoul, Republic of Korea

²Department of Surgery, College of Medicine and Medical Research Institute, The Chungbuk National University, Chungbuk, Republic of Korea

Key words: Duplication Cyst; Gastrointestinal Hemorrhage; Meckel's Diverticulum

An intestinal duplication cyst is a very rare congenital anomaly, with symptoms including abdominal pain, abdominal distention, intestinal bleeding, and hematochezia. Hematochezia can be caused by ectopic gastric mucosa, although there are other causes of infantile hematochezia; hence, an intestinal duplication cyst can be misdiagnosed as bowel intussusception or Meckel's diverticulum. Here, a case of an intestinal duplication cyst that was misdiagnosed as Meckel's diverticulum is reported.

A 6-month-old girl was admitted to our hospital with recurrent and massive hematochezia. She was born at 39 + 1 weeks by cesarean section and weighed 4200 g. She had no underlying disease except for nonspecific tachypnea and cephalhematoma. She had experienced recurrent melena for 20 days 2 months earlier, but the hospital at which she was treated was unable to detect any specific abnormalities, and she was managed conservatively. She was admitted to the emergency department after experiencing massive hematochezia 3 times in a single day. Her diaper was wet with fresh blood with an estimated volume of 50 cc. She was pale, irritable, and inactive, and was found to have anemic conjunctiva and an initial hemoglobin level of 61 g/L. However, her vital signs were stable, and all other laboratory results were within the normal limits. Physical examination revealed no specific abnormality. A blood transfusion was administered, and detailed examinations were performed. Intussusception was suspected, so ultrasonography was performed, which failed to reveal any specific abnormality. When her condition had further stabilized, examinations to determine the cause of hematochezia were performed, starting with Meckel's scan. Five minutes after injection of Tc-99m, continuous uptake was observed in the right mid-abdomen, consistent with Meckel's diverticulum [Figure 1a], and

computed tomography revealed a suspicious enhancing cystic structure at the ileum, which was also consistent with Meckel's diverticulum [Figure 1b]. By these findings, Meckel's diverticulum was diagnosed and surgery was performed during which intestinal duplication was discovered [Figure 1c]. The duplication was a tubular structure about 10 cm long and located in the terminal ileum, 30 cm above the cecum [Figure 1d]. It contained a 2 cm sized cystic mass surrounded by multiple lymph node enlargements. Small bowel resection and anastomosis were performed. Water intake was permitted on the 1st postoperative day, milk and baby food intake were gradually allowed. She was discharged without any complications, and no problems were noted during the 6-month follow-up period.

Gastrointestinal bleeding of unknown cause is very difficult to treat, and sometimes, massive bleeding can be life threatening. The causes of gastrointestinal bleeding in children are difficult to distinguish and include Meckel's diverticulum, intussusception, gastroduodenal ulcer and, rarely, an intestinal duplication cyst, which is a congenital anomaly that can occur anywhere in the gastrointestinal tract. An intestinal duplication cyst was first described in 1733, and most commonly develops in the ileum on the mesenteric margin or the contralateral side.^[1] Pathologically, a duplication cyst is a structure that is closely adhered to the

Address for correspondence: Dr. Dong-Ju Kim,
410 Seongsong-ro, Heungduk-gu, Cheongju,
Chungbuk 361-711, Republic of Korea
E-Mail: reallydong@hanmail.net

This is an open access article distributed under the terms of the Creative Commons Attribution-NonCommercial-ShareAlike 3.0 License, which allows others to remix, tweak, and build upon the work non-commercially, as long as the author is credited and the new creations are licensed under the identical terms.

For reprints contact: reprints@medknow.com

© 2016 Chinese Medical Journal | Produced by Wolters Kluwer - Medknow

Received: 19-09-2015 **Edited by:** Yi Cui

How to cite this article: Kim YS, Kim DJ, Bang SU, Park JJ. Intestinal Duplication Cyst Misdiagnosed as Meckel's Diverticulum. Chin Med J 2016;129:235-6.

Access this article online

Quick Response Code:



Website:
www.cmj.org

DOI:
10.4103/0366-6999.173544

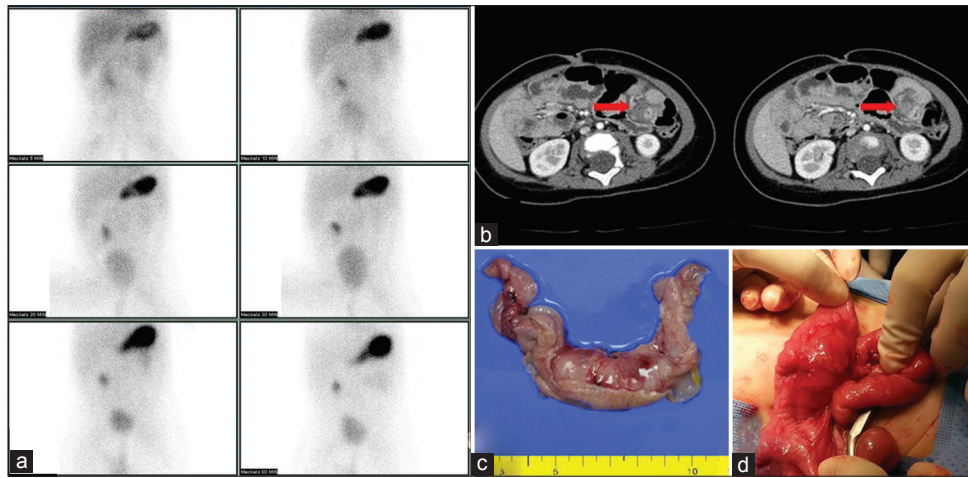


Figure 1: (a) Tc-99m scan of a 6-month-old female, (b) abdominal computed tomographic scan, (c) gross finding of the duplication cyst, and (d) operative finding at surgery.

original intestine and surrounded by smooth muscle with an epithelial lining.^[2] The etiology of intestinal duplications is unknown, although more than 80% occur in children aged < 2 years.^[3] The chief complaints include an abdominal mass, intestinal obstruction, and hematochezia.^[4] Small lesions can act as a leading point of intussusception. About 10% of duplication cysts have ectopic gastric mucosa, usually at the wall of the duplications, which can cause hematochezia.^[2] It has therefore been suggested that Tc-99m pertechnetate scintigraphy should be the first test used to diagnose intestinal duplication cysts. The findings of this examination need to be differentiated from those indicative of Meckel's diverticulum, although the preoperative diagnosis is often uncertain. In our case, the hematochezia and Tc-99m pertechnetate scintigraphy findings were initially thought to be indicative of Meckel's diverticulum.

There are currently no drugs available to manage lower gastrointestinal bleeding, although Jacques *et al.* reported that high-dose proton pump inhibitor therapy had a depletive effect on lower gastrointestinal duplication bleeding.^[5] Surgical removal of intestinal duplication cysts achieves better results, even when these cysts are found incidentally, as untreated patients often develop further complications. In addition, 23% of intestinal duplication cysts in adults were found to be ileal cancer.^[4] As discussed above, there are

multiple causes of hematochezia and it is, therefore, critical to determine the cause and the site of bleeding, which will allow the development of an appropriate care plan. Accurate preoperative diagnosis is particularly important. Intestinal duplication cysts are a rare cause of hematochezia, but must be considered in its differential diagnosis.

Financial support and sponsorship

Nil.

Conflicts of interest

There are no conflicts of interest.

REFERENCES

1. Kim SK, Lim HK, Lee SJ, Park CK. Completely isolated enteric duplication cyst: Case report. *Abdom Imaging* 2003;28:12-4. doi: 10.1007/s00261-001-0138-0.
2. Macpherson RI. Gastrointestinal tract duplications: Clinical, pathologic, etiologic, and radiologic considerations. *Radiographics* 1993;13:1063-80. doi: 10.1148/radiographics.13.5.8210590.
3. Iyer CP, Mahour GH. Duplications of the alimentary tract in infants and children. *J Pediatr Surg* 1995;30:1267-70. doi: 10.1016/0022-3468(95)90482-4.
4. Johnson JA 3rd, Poole GV. Ileal duplications in adults. Presentation and treatment. *Arch Surg* 1994;129:659-61.
5. Jacques J, Projetti F, Legros R, Valguelasse V, Sarabi M, Carrier P, *et al.* Obscure bleeding colonic duplication responds to proton pump inhibitor therapy. *World J Gastroenterol* 2013;19:5940-2. doi: 10.3748/wjg.v19.i35.5940.