

MISERICORDIA HOSPITAL
BOOKS NOT TO BE TAKEN
OUT OF THE LIBRARY.

RETICULO-ENDOTHELIAL SARCOMA ARISING IN THE NOSE AND PALATE (GRANULOMA GANGRENESENS)

BY

E. W. WALTON

From the Department of Pathology, Queen's College, Dundee, University of St. Andrews

(RECEIVED FOR PUBLICATION JANUARY 12, 1960)

Granuloma of the nose which does not heal is a tripartite disease, including classical malignant granuloma, Wegener's granulomatosis, and a third group with neoplastic characteristics (granuloma gangrenescens). Five cases of this third type are described and 20 others from the literature are tabulated. The primary lesion is in the nasal or palatal region; after a latent period, metastases develop in many organs. The histological features are those of malignancy. Reasons are given for regarding the condition as a sarcoma of the reticulo endothelial system.

A recent survey of 23 cases of nasal granuloma which did not heal (Walton, 1959) has shown that this disease is a tripartite one including cases of non-specific granulomatous inflammation (malignant granuloma), others associated with polyarteritis nodosa (Wegener's granulomatosis), and others more closely resembling a neoplasm (granuloma gangrenescens). In this third and least common group, a prolonged nasal or palatal ulceration is usually followed by the development of metastatic lesions throughout the body.

Five cases in which sarcomatous tissue was found are described.

Case Reports

Case 1.—A labourer, aged 49, was admitted to hospital in November, 1954, with pain and ulceration in the mouth for five weeks. The whole of the right side of his face, nose, and upper lip was swollen. An ulcer on the hard palate, 3 cm. in diameter, had necrotic bone in the base. The nasal mucosa was red and thickened. He was febrile but otherwise well. Bacteriological and serological tests were negative. Biopsy of the palatal ulcer showed necrotic granulation tissue but no evidence of malignancy. He was treated with antibiotics, iodine, and arsenicals, but the ulcer enlarged until the hard palate and floor of the nose were destroyed. The diagnosis of malignant granuloma was made and a course of x-ray therapy was begun two months after admission. The improvement was dramatic and three months later the lesion had healed.

The patient remained well for eight months, when the right testis enlarged and became painful and the vision in the right eye began to fail. On examination the right retina was detached, and ulceration in the upper nasal cavity and a mass in the ethmoid sinuses

were seen. The palatal lesion was still healed. The right testis was firm and slightly enlarged. Orchidectomy was performed and the testis found to be infiltrated with greyish tissue. Despite x-ray therapy to the sinuses and right orbit, the loss of vision increased and became bilateral. He developed small ulcers in the skin of the arms and trunk, lapsed into coma, and died, 16 months from the onset of the illness.

Summary of Necropsy.—The body was emaciated and numerous small red spots, some superficially ulcerated, were present on the skin of the arms and trunk. The hard palate and alveolar process of the maxillae were almost completely destroyed. The nasal mucosa was diffusely thickened and ulcerated. The right eye showed almost complete detachment of the retina and haemorrhage behind it; the orbits were not examined. The thyroid gland was enlarged, irregular on section, and showed a white nodule in the right upper pole. There was a bilateral bronchopneumonia and extensive fibrosis of the myocardium. Numerous acute ulcers, shallow but with heaped-up edges, were present in the stomach and proximal ileum. The capsular and cut surfaces of the liver showed numerous tumour nodules measuring up to 1 cm. The pancreas was diffusely fibrotic but contained no tumour. The right kidney was enlarged (210 g.) and diffusely infiltrated by neoplastic tissue, mottled and yellow-brown. Similar tissue was present in the left epididymis. There was no lymphadenopathy. All other organs and tissues appeared normal.

Case 2.—A storekeeper, aged 56, developed swelling of the right side of the nose in the summer of 1956. Despite antibiotic treatment it persisted and by October there was an extensive nasal ulcer with erosion of the septum, the right lateral nasal wall, and the turbinate bones. Repeated biopsies showed granulation tissue but no evidence of neoplasia. Bacteriological and serological tests were negative.

By February, 1957, the right face and jaw were swollen and there was a 2½ cm. ulcer above the right nasal fold which penetrated deeply into the nasal cavity. A radiograph of the skull showed partial destruction of the nasal septum. After a course of x-ray therapy the ulcer began to heal by granulation and by June it had decreased in size. The next month, however, the left side of the nose swelled and the facial ulcer began to enlarge. On his admission in August, the external ulcer measured 4½ cm. in diameter; the palate was eroded, and he had gross foetor oris. A radiograph of the skull showed destruction of the medial walls of both maxillary antra. He slowly became confused and dyspnoeic, developed tremor of the facial muscles and tongue, and died on August 19, 14 months after the onset of the illness.

Summary of Necropsy.—The body was emaciated. A large perforating ulcer had destroyed much of the right nostril and the nasal septum, turbinate bones, palate, and both maxillary antra were eroded. The frontal, ethmoidal, and sphenoidal sinuses and the base of the skull appeared healthy. The brain (1,350 g.) appeared externally normal but on section showed three areas of haemorrhage, each about 1 cm. in diameter, in the pons, left cerebellar lobe, and the left post-central gyrus. The lungs showed a bilateral lower lobe bronchopneumonia. There was moderately severe atheroma of the aorta, its main branches and the coronary arteries. All other organs and tissues appeared normal.

Case 3.—A mentally defective spinster, aged 30, was admitted to hospital in July, 1956, having had a "carbuncle" of the left nostril for five weeks. On examination the only abnormality found was a granulating ulcer involving the left nostril, the nasal septum, and the upper lip; biopsy of this showed granulomatous inflammation with no evidence of neoplasia. Treatment with antibiotics had little effect on the course of the disease. Five months later the lesion had progressed and now affected the upper lip, nose, and both cheeks (Fig. 1). The eyes were swollen, the left being almost closed. Shortly afterwards she became comatose and died, six months after the onset of the illness.

Summary of Necropsy.—The body was emaciated. A large fungating tumour replaced the nose and upper lip. There was ulceration in both nostrils, with some erosion of the bony skeleton. The upper gum and palate were swollen and indurated. The lower air passages were normal. The lungs (right 700 g., left 680 g.) were oedematous and patchily consolidated. The liver and spleen were congested and there was a haemorrhagic cystitis. The brain was not examined. All other organs and tissues were normal, there being nothing to suggest metastases.

Case 4.*—A housewife, aged 37, was admitted to hospital in March, 1958; for 10 months she had had

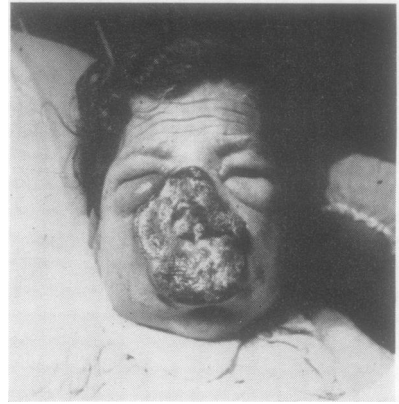

FIG. 1.—Case 3, five months after the onset. A fungating mass has destroyed the nose and the remainder of the face is greatly swollen.

right-sided nasal obstruction and one week previously had developed swelling of the right side of the face and gum. On examination the right nostril was found to be blocked by a granulomatous mass and numerous small nodules were noted in the skin of the forearms and thighs. A nasal biopsy showed infiltration by sarcomatous tissue. After deep x-ray and steroid therapy the swelling of the face and nasal granuloma both diminished. In June, however, she developed a sore throat, a painful cough, cervical and axillary lymphadenopathy, and more skin nodules. In August, peritonitis supervened and at laparotomy a perforation in the distal ileum was closed. A week later she died in peripheral circulatory failure.

Summary of Necropsy.—The body was well nourished: numerous firm nodules were present in the skin of the arms, chest, and thighs. A granulomatous ulcer covered the right lateral wall of the nasal cavity and extended medially on to the nasal septum. The lungs were both oedematous (2,300 g.) and each contained several round nodules, firm greyish-yellow, sharply defined, and about 2 cm. in diameter. There was a healing peritonitis and the small bowel, throughout its length, contained multiple firm nodules in the submucosa, each pale grey and measuring up to 2.5 cm. in diameter. The liver was pale but otherwise normal. The other organs and tissues examined, including the brain, showed no significant abnormality.

Case 5.—A labourer, aged 67, developed pain and swelling of the left cheek with blockage of the nose, in the spring of 1958. He was otherwise well. On examination one month later there was extensive ulceration of the lateral wall of the nose, over the turbinate bones and the septum. As antibiotics did not improve his condition, a biopsy was taken. This was diagnosed as being infiltrated by a sarcoma of the reticulo-endothelial system. A course of radiotherapy resulted in apparent healing of the lesion: when last seen nine months later he was well.

*This case is to be published in detail elsewhere (Dawes and Wort, 1960).

Summary of Clinical Features and Macroscopic Appearances at Necropsy

The disease in each case followed a constant pattern. The initial lesion, an ulcer of the nose or palate, persisted despite chemotherapy or antibiotic treatment, but x-ray therapy in each case produced a retrogression or even apparent cure. The original biopsies were nearly always non-specific. Bacteriological and serological tests were negative and the blood picture was always normal. Cases 1, 2, and 3 were originally regarded as examples of the so-called malignant granuloma, but further study of the reported cases of this non-specific granulomatous inflammation made it obvious that the present cases belonged to the truly neoplastic group (in the past called granuloma gangrenosens), and this enlightenment allowed a provisional clinical diagnosis in Cases 4 and 5, confirmed in both by nasal biopsy.

The local lesion in each case produced erosion of the cartilaginous and bony framework of the nose and palate, and, in the cases that came to necropsy, neoplastic tissue was found here. Spread to the skin of the face occurred only in

Cases 2 and 3, in the latter a large fungating tumour mass developing. In Cases 1, 2, and 4, metastases were found in many organs and tissues, usually the lymph nodes, skin, liver, kidney, spleen, and lung. More unusual sites for metastatic growth were also involved, namely, heart, gonad, thyroid. The tumour deposits were usually diffuse infiltrates of homogeneous pale tissues, less frequently discrete nodules. Sometimes areas of necrosis or haemorrhage were present as in the cerebral lesions in Case 2.

Histological Features

These are based on the biopsy material from the initial nasal or palatal lesions in each case, and necropsy tissue from Cases 1 to 4. Unfortunately, the nasal material was usually small and fragmented, consisting largely of ulcerated granulation tissue, with areas of necrosis. Nevertheless, in the depths of the tissue, neoplastic infiltrations were identified in each case. In brief, these consist of sheets of quite uniform cells with round or oval hyperchromatic nuclei and little cytoplasm. Mitotic figures are fairly frequent, up to 1 or 2 per high-power field.

TABLE I
CLINICAL AND PATHOLOGICAL FEATURES OF 24 NECROPSIED CASES OF RETICULO-ENDOTHELIAL SARCOMA ARISING IN THE NOSE AND PALATE

Case No.	Author	Sex	Age	Primary Lesion	Duration (Months)	Metastases
1	Kraus (1929), Case 2	M	30	Nose	23	—
2	Bonne and Lodder (1929), Case 1	M	42	Palate, nose	—	Liver, spleen, lung, heart, adrenal, stomach, ileum, pituitary, pia mater
3	" " " " 2	F	46	Nose	6	Lymph nodes, liver, pancreas, stomach, ileum
4	Derischanoff (1931)	F	62	"	—	—
5	Berendes (1934)	F	31	"	3	—
6	Hall (1934)	F	32	Palate, nose	4	Skin, lymph nodes, kidney, lung, voluntary muscle
7	Kanas (1936)	M	47	Palate	3½	Lymph nodes, pharynx
8	Tischnenko, Kroitschik, and Kusnetz (1936)	M	37	Nose	12	—
9	Bergqvist and Koch (1949), Case 2	M	27	Nose, palate	4	Skin, lymph nodes, lung, voluntary muscle
10	Rasmussen (1948)	M	29	Palate, nose	—	Skin, voluntary muscle, ? liver, kidney, spleen, lung
11	Thielemann and Pieczewski (1950)	M	47	Palate	3	Lymph nodes, heart
12	Vogel (1952)	M	30	Nose, palate	9	Skin, lymph nodes, liver
13	Corréa and Elisabethy (1954), Case 1	M	17	Palate	7	—
14	" " " " 2	F	27	Nose	—	—
15	Calás and Bonneau (1958)	M	38	Palate	24	Salivary gland, ? intestine
16	Richmond, Weir, and Philip (1956)	F	44	Nose	11	Lung, ovary, ? brain, colon
17	Spear and Walker (1956)	M	43	"	15	Skin, lymph nodes, larynx, trachea
18	Hultberg, Koch, Moberger, and Mårtensson (1957), Case 2	F	42	"	13	Lymph nodes, liver, kidney, spleen, adrenal, uterus, pituitary
19	Lopes de Faria <i>et al.</i> (1957), Case 1	F	36	"	20	Lymph nodes, liver, kidney, heart, uterus
20	Baker <i>et al.</i> (1958)	M	29	Nose, nasopharynx	10	Lymph nodes, liver, spleen, lung
21	Walton, Case 1	M	49	Palate	15	Skin, lymph nodes, liver, stomach, kidney, spleen, testis, thyroid
22	" " 2	M	56	Nose	14	Lymph nodes, lung, brain
23	" " 3	F	30	"	6	—
24	" " 4	F	40	"	6	Skin, lymph nodes, liver, kidney, spleen, lung, heart, ileum, ovary, adrenal, thyroid

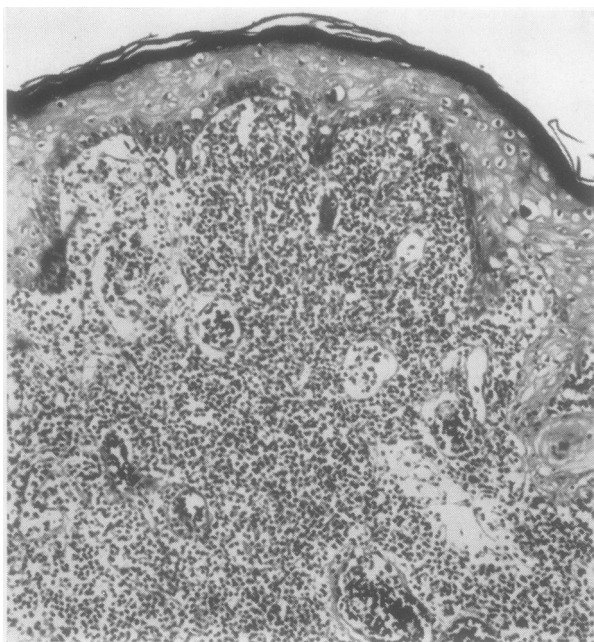


FIG. 2

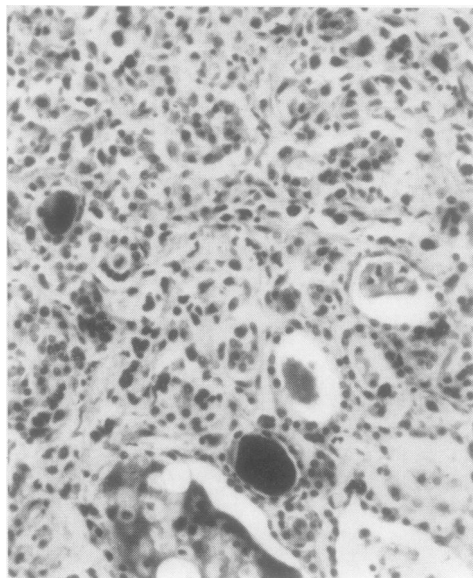


FIG. 3

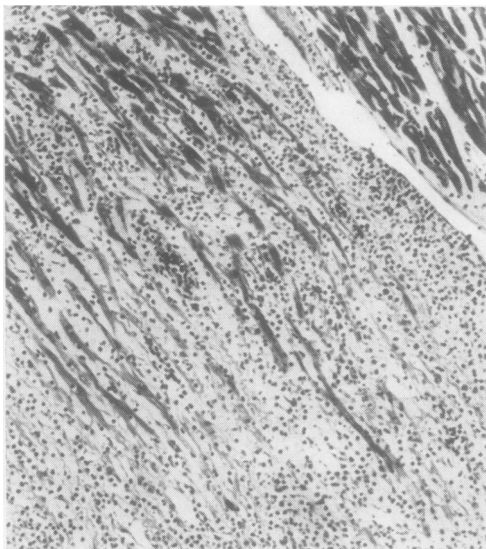


FIG. 4

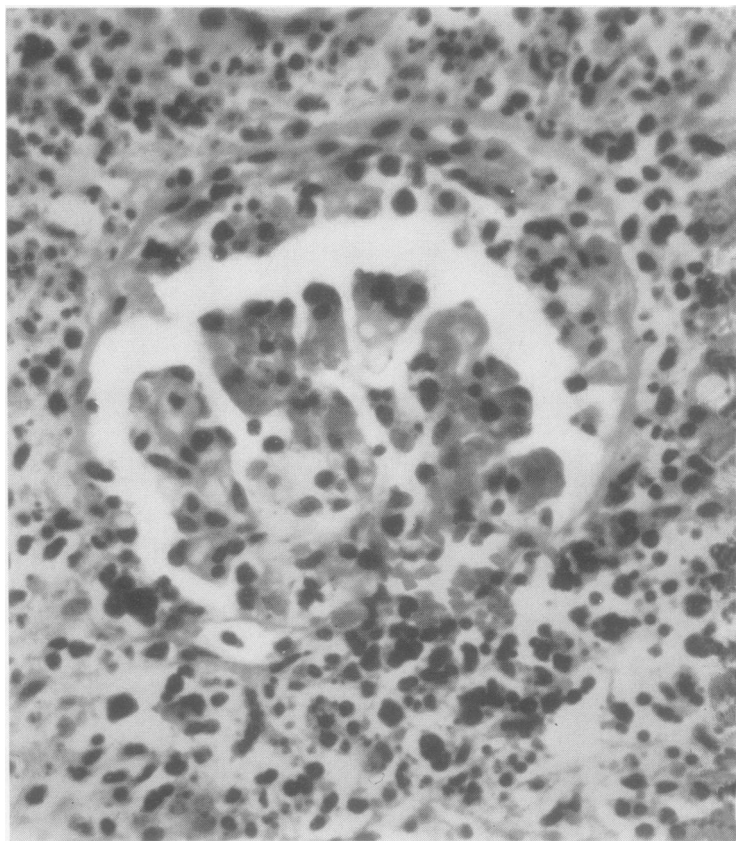


FIG. 5

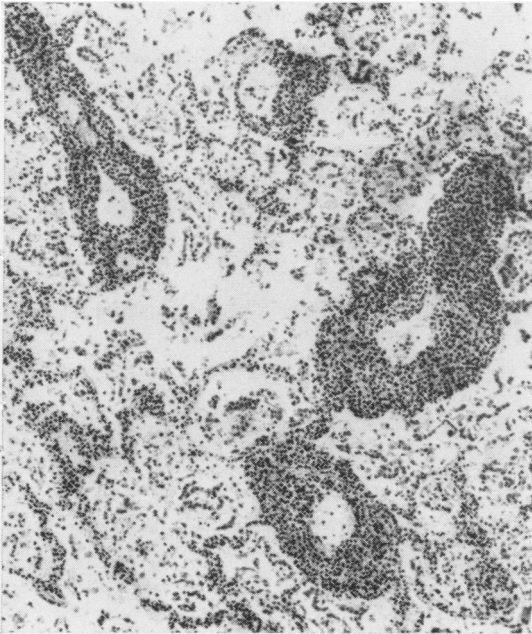


FIG 6

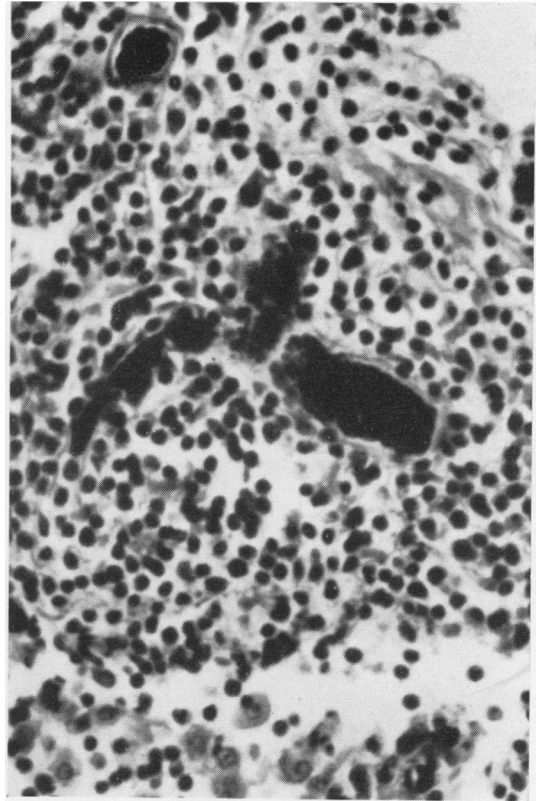


FIG. 7

FIG. 2.—Case 4, skin $\times 95$. The corium is infiltrated by tightly packed hyperchromatic cells of uniform size.

Except where otherwise stated, all photomicrographs are from sections stained by haematoxylin and eosin.

FIG. 3.—Case 1, thyroid $\times 185$, showing replacement of parenchyma and neoplastic cells in between surviving acini.

FIG. 4.—Case 4, heart $\times 90$. Infiltration in between myocardial fibres and myocardial necrosis.

FIG. 5.—Case 1, kidney $\times 450$. Tumour cells are present in the glomerular tuft and capsule and in the periglomerular tissue.

FIG. 6.—Case 4, lung $\times 70$. Neoplastic cells surround small vessels and bronchioles and are present in alveolar walls.

FIG. 7.—Case 4, lung $\times 240$, showing peribronchiolar infiltration. At the bottom right neoplastic cells are lying free within alveoli.

FIG. 8.—Case 2, brain $\times 270$. Distension of Virchow-Robin space by neoplastic cells.

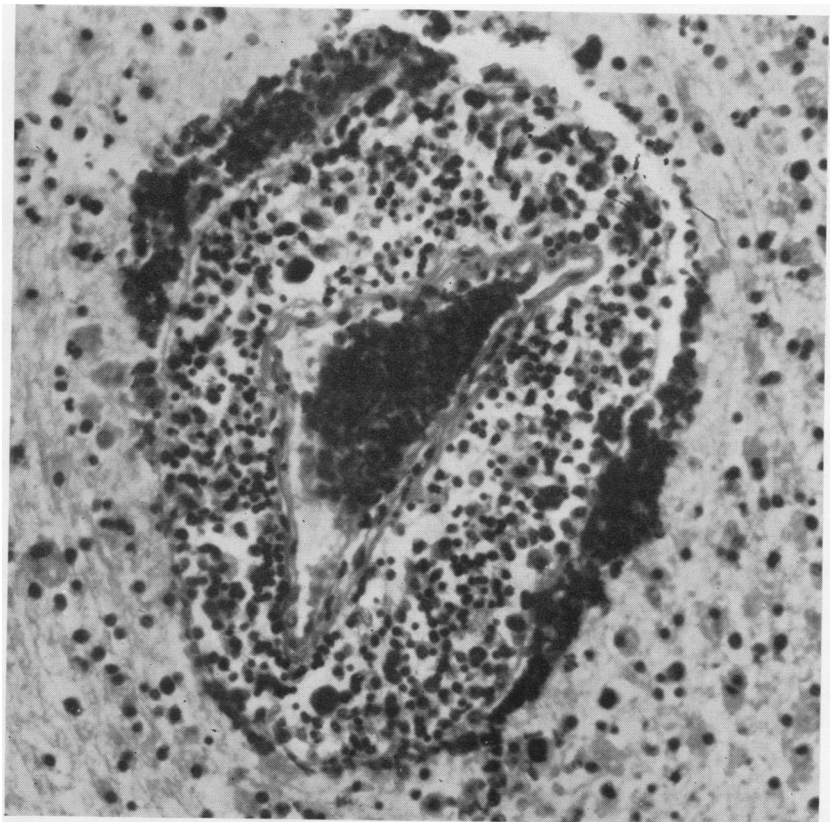


FIG. 8

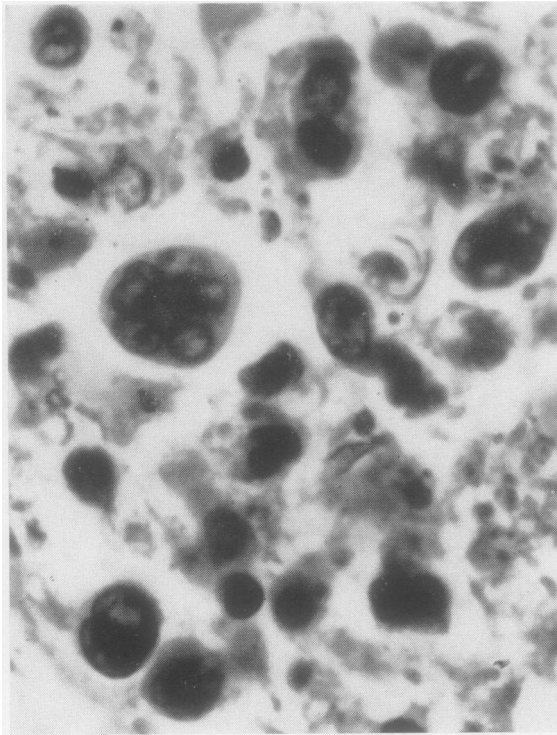


FIG. 9

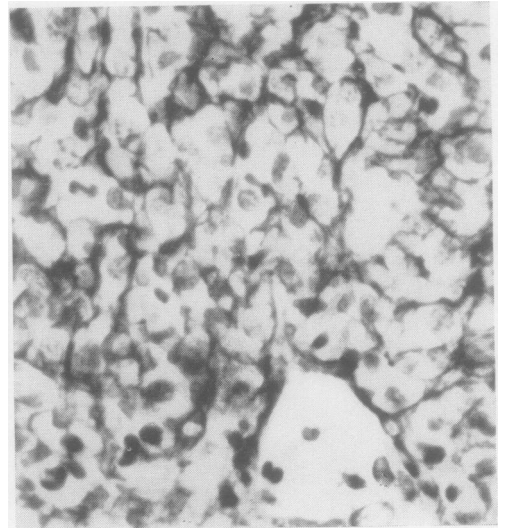


FIG. 10

FIG. 9.—Case 2, brain $\times 680$. The infiltrate is here polymorphic and includes multinucleate cells.

FIG. 10.—Case 3, nasal biopsy stained to show reticulin fibres, $\times 500$. A delicate reticulin meshwork encircles groups of cells.

Similar neoplastic tissue is present in slides from the macroscopic lesions of other organs, as indicated in Table I, in Cases 1, 2, and 4. In Case 3, examination of slides from eight blocks from the viscera and lymph nodes fails to reveal any neoplastic infiltration. The pattern of the infiltrates is similar in each case. Under low-power magnification the areas are pale and ill-defined. In the centre the cells are tightly packed (Fig. 2), without alveolar or other pattern, but towards the edge groups of cells are irregularly placed between the parenchymal structures. Thus in the thyroid (Fig. 3) the tumour cells extend between and around surviving acini, in the heart (Fig. 4) between surviving myocardial fibres, in the kidney (Fig. 5) into and around glomeruli. The picture in the lungs (Figs. 6 and 7) is that of diffuse perivascular and peribronchial infiltration, with extension of neoplastic cells into and often through the alveolar walls. In the liver, the portal tracts are mainly affected, with infiltration also between columns of parenchymal cells and around the central veins. Of particular interest are the cerebral metastases; from the main neoplastic masses the cellular infiltration extends

outwards as a perivascular growth, causing great distension of the Virchow-Robin spaces (Fig. 8). Thence tumour cells have penetrated into the substance of the brain to form daughter tumours at a distance from the main centre. Unfortunately, the lymph nodes available show only advanced involvement, with replacement of much of the gland architecture by neoplasm: as in other sites necrosis in the centre of the infiltrates is common.

The cytology of the various infiltrates is remarkably characteristic, both from case to case and organ to organ, though the degree of polymorphism varies. The cells have medium-sized, round, oval, or lobed nuclei with a moderately dense chromatin network and a well-defined nuclear membrane. They have little cytoplasm. Sometimes the cells have a more vesicular nucleus and multinucleate forms occasionally occur (Fig. 9). Mitotic figures are easily found. Evidence of lymphatic permeation is absent and neoplastic cells are not seen within blood vessels. In some of the affected areas there is a moderate degree of fibrosis with patchy groups of lymphocytes and plasma cells at the periphery of the tumour

masses. Reticulin stains (Fig. 10) show a fine meshwork of fibres encircling groups and pockets of three or four tumour cells. No necrotizing vascular lesions or focal granulomas of the kind common in Wegener's granulomatosis are present.

Discussion

In the abundant literature on nasal granulomas which do not heal there are at least 32 cases similar to those in this paper. Most were called granuloma gangrenescens. Twenty of these, confirmed by necropsy, are summarized in Table I. Five others have been excluded from the table for various reasons. Thus, for example, there was a co-existent lymphosarcoma of the stomach in the cases reported by Schütz (Case 1, 1938) and Leroux-Robert (1957): in that described by Knapp (1949) a vaginal sarcoma was probably the primary: in Greifenstein's (1937) case the nasal lesion was preceded by mycosis fungoides in the skin: Kowalczykova and Sokolowski (1955) were not certain that their case was neoplastic. In the seven other cases sarcomatous tissue was found in biopsy from the nasal and/or palatal region of patients still alive at the time of the report (Hesse, 1941; Pirodda and Guenzi, 1950; Eigler, 1951; Vilanova and Pinol, 1954; Guns, Marquet, and Gillain, 1956; and Hunger, 1956).

The neoplastic and malignant character of this lesion is certainly suggested by the clinical sequence of initial lesion, latent period, metastases, and fatal end. The histological picture is that of malignancy. It has from time to time been

suggested that granuloma gangrenescens is not a neoplasm from the beginning but is a neoplastic transformation of classical malignant granuloma. One recent case (Hunger, 1956) in particular suggests this: in this patient, nasal ulceration continued for 15 years before malignant tissue was demonstrated and metastases developed. Furthermore, one of Woods' early cases died from sarcoma several years after the initial report (Woods, 1921). On the other hand, the average duration of the fatal cases summarized in the present report was just under one year, and, in several, malignant tissue was demonstrated in the nose at an early stage. It, therefore, appears likely that the condition is indeed neoplastic, and is so from the beginning.

The naming of this neoplasm has varied with fashion, and no doubt also with the quality of the histological technique, but it is hardly justifiable to state that the lymphosarcoma described by Kanas (1936) or the sarcoma described by Hall (1934) and by Baker, Thompson, and Arnold (1958) were misdiagnoses, even though the clinical picture was similar to the cases described as reticulum-cell sarcoma by Lopes de Faria, Cutin, Morgante, and Ferri (1957) and others. My own cases certainly showed none of the classical features of Hodgkin's disease, and, although the bone marrow was not examined in any, the absence of haematological abnormality during life and of atypical cells in the blood vessels in tissue sections supports the view that the condition is not a leukaemia. The cytological characteristics in all the sections examined conform to the majority opinion that the condition is a sarcoma of the reticulo-endothelial system, the "*retothelsarcom*" of German authors, and the close resemblance of the cerebral lesions in Case 2 to the cases of microgliomatosis described by Russell, Marshall, and Smith (1948) supports this view. Following Russell's example, I have not used the term reticulum-cell sarcoma, preferring to reserve this term for the rare tumour that gives evidence of its ability to form reticulin, a feature that was not seen in any of my cases. Tumours of the reticulo-endothelial system, apart from those which simulate non-healing granuloma, are apparently rare in the nose, only two having been mentioned by Devine in his exhaustive review of neoplasms in the upper air passages reported from 1953 to 1956. Nevertheless, it seems reasonable to accept the view that the granuloma gangrenescens of the earlier writers is in fact a reticulo-endothelial sarcoma and, in most cases at least, is a neoplasm from the beginning and not a complication of a local pre-existing granuloma.

TABLE II
SUMMARIZED FEATURES OF 24 NECROPSIED CASES

Sex:		
Males		14
Females		10
Age:		
Range		17-62
Mean		37
Course:		
Average	10 months	
Initial Lesion:		
Nose		15
Palate		5
Both		4
Metastases		17
Lymph nodes		13
Liver		9
Skin		7
Lung		7
Kidney		6
Spleen		6
Heart		4
Ileum		4
Brain		3
Adrenal		3
Voluntary muscle		3

I am indebted Dr. W. Stewart, Dr. J. S. Faulds, and Dr. A. J. Wort for necropsy reports; to Dr. W. Ross for permission to publish Cases 1 and 2; to Mr. J. D. K. Dawes for permission to publish Case 4, and to Mr. J. W. Corkhill for the illustrations. It is a pleasure to acknowledge the assistance and encouragement given by Professor A. C. Lendrum, Professor J. B. Duguid, and Dr. W. W. Park.

REFERENCES

- Baker, R. D., Thompson, F., and Arnold, R. (1958). *Sth med. J. (Bgham, Ala)*, **51**, 591.
- Berendes, J. (1934). *Münch. med. Wschr.*, **81**, 2005.
- Bergqvist, B., and Koch, H. (1949). *Acta oto-laryng. (Stockh.)*, **37**, 405.
- Bonne, C., and Lodder, J. (1929). *Beitr. path. Anat.*, **83**, 521.
- Calas, E., and Bonneau (1958). *Bull. Soc. franç. Derm. Syph.*, **65**, 66.
- Corrêa, A., and Elisabetsy, M. (1954). *Rev. bras. Oto-rino-laring.*, **22**, 63.
- Dawes, J. D. K., and Wort, A. J. (1960). To be published.
- Derischanoff, S. (1931). *Arch. Derm. Syph. (Berl.)*, **164**, 756.
- Devine, K. D. (1958). *A.M.A. Arch. Otolaryng.*, **67**, 716.
- Eigler, G. (1951). *Arch. Ohr., Nas., u. Kehlk.-Heilk.*, **159**, 411.
- Greifenstein, A. (1937). *Ibid.*, **143**, 315.
- Guns, P., Marquet, J., and Gillain, A. (1956). *Acta oto-rhino-laryng. belg.*, **10**, 385.
- Hall, I. S. (1934). *J. Laryng.*, **49**, 35.
- Hesse, B. (1941). *Arch. Ohr., Nas., u. Kehlk.-Heilk.*, **150**, 175.
- Hultberg, S., Koch, H., Moberger, G., and Mårtensson, G. (1957). *Acta radiol. (Stockh.)*, **47**, 229.
- Hunger, H. (1956). *Arch. Ohr., Nas., u. Kehlk.-Heilk.*, **168**, 466.
- Kanas, S. (1936). *Acta otolaryng. (Stockh.)*, **23**, 429.
- Knapp, E. (1949). *H.N.O. (Berl.)*, **1**, 320.
- Kowalczykowa, J., and Sokolowski, S. (1955). *Otolaryng. pol.*, **9**, 189.
- Kraus, E. J. (1929). *Verh. dtsh. path. Ges.*, **24**, 43.
- Leroux-Robert, M. (1957). *Ann. Oto-laryng. (Paris)*, **74**, 554.
- Lopes de Faria, J., Cutin, M., Morgante, A. P., and Ferri, R. G. (1957). *A.M.A. Arch. Otolaryng.*, **65**, 255.
- Pirodda, E., and Guenzi, G. (1950). *Oto-rinolaring. ital.*, **19**, 81.
- Rasmussen, H. (1948). *Nord. Med.*, **38**, 1037.
- Richmond, H. G., Weir, C. D., and Philip, J. F. (1956). *Brit. J. Surg.*, **44**, 291.
- Russell, D. S., Marshall, A. H. E., and Smith, F. B. (1948). *Brain*, **71**, 1.
- Schütz, W. (1938). *Z. Hals., Nas., -u. Ohrenheilk.*, **44**, 244.
- Spear, G. S., and Walker, W. G., Jr. (1956). *Bull. Johns Hopk. Hosp.*, **99**, 313.
- Thielemann, M., and Pieczewski, H. (1950). *Z. Laryng. Rhinol.*, **29**, 302.
- Tischenko, A., Kroitschik, A., and Kusnetz, M. (1936). *Ann. Derm. Syph. (Paris)*, **7**, 763.
- Vilanova, X., and Pinol, J. (1954). *Dermatologica (Basel)*, **109**, 14.
- Vogel, G. (1952). *Z. Krebsforsch.*, **58**, 698.
- Walton, E. W. (1959). *J. Laryng.*, **73**, 242.
- Woods, R. (1921). *Brit. med. J.*, **2**, 65.