

Surgical treatment of peripheral ulcerative keratitis and necrotizing scleritis in granulomatosis with polyangiitis

Cheng-Wei Lu, MD, PhD, Dan-Dan Zhou, MD, Jiao Wang, MD, Ji-Long Hao, MD, PhD.

ABSTRACT

نستعرض فعالية الإدارة الجراحية عند معالجة مضاعفات العيون الحرارية في الأوعية الملتهبة بالتورم الحبيبي (GPA) والتي تهدد حاسة البصر. قَدِمَ رجل يبلغ من العمر 70 عاماً مع تزايد تدريجي في الألم واحمرار في العين اليمنى خلال الـ 6 أشهر السابقة وانخفاض في حدة البصر التي بدأت قبل شهر. كانت قد سُخِصت خطأً في مستشفيات أخرى وأُعتقِدَ بأنها التهاب في القرنية، ولكن الألم لم يخف. تم تشخيص التهاب الصلبة الميت بالتهاب القرنية التقرحية الطرفية في GPA وذلك في قسمنا في المستشفى. تم إجراء العملية الجراحية مع إزالة النسيج الميت، مع العلاج بالتبريد وعملية تغطية الملتهمة. خفت الأعراض بعد الجراحة، وبالتالي ظلت حالة عين المريض مستقرة. توضح هذه الحالة إمكانية علاج التهاب الأوعية بالتورم الحبيبي المحدود بنجاح (مثل PUK والتهاب الصلبة الميت) والتي لم تكن حساسة أو كانت نتيجة تفاعل لأساليب علاج تقليدية وذلك بواسطة تدخلات جراحية مجتمعة.

The efficacy of surgical management of refractory ophthalmic complications of granulomatosis with polyangiitis (GPA), which is a sight threatening was reported. A 70-year-old man presented with a progressively worsening pain and redness in his right eye during the previous 6 months, and decreasing visual acuity that started one month earlier. He was misdiagnosed and treated as keratitis elsewhere, but the pain has not decreased. The diagnosis of necrotizing scleritis with peripheral ulcerative keratitis (PUK) in GPA was made in our department. Surgery was performed with necrotic tissue removal, combined with cryotherapy and a conjunctival flap covering surgery. The symptom was relieved after surgery, and the patient's ocular condition remained stable thereafter. This case first demonstrates limited ophthalmic GPA (such as, PUK and necrotizing scleritis) that was not sensitive or aggravated for traditional methods can be successfully treated by combined surgical interventions.

Saudi Med J 2016; Vol. 37 (2): 205-207
doi: 10.15537/smj.2016.2.13390

From the Departments of Ophthalmology (Lu, Wang, Hao), and Radiology (Zhou), The First Hospital of Jilin University, Changchun City, Jilin Province, China.

Received 20th September 2015. Accepted 25th November 2015.

Address correspondence and reprint request to: Dr. Ji-Long Hao, Department of Ophthalmology, The First Hospital of Jilin University, Changchun, Jilin, China. E-mail: 289736582@qq.com

Granulomatosis with polyangiitis (GPA), previously known as Wegener's granulomatosis (WG), is a systemic, necrotizing, granulomatous vasculitis of unknown etiology. In 50% of patients, ocular symptoms were observed as the initial sign before GPA was diagnosed.¹ The initial symptoms may be obscure and may vary from one patient to another. Although the respiratory tract and renal involvement are most commonly seen, ocular involvement occurs in up to 60% of patients with GPA, and is potentially sight-threatening.² In the limited form of GPA, ocular manifestations may be the only presenting manifestation of disease. When eye disease is the only clinical manifestation, diagnosis and initiation of appropriate therapy are often delayed. We present an old male with refractory ophthalmic complications of GPA who had limited responses to conventional treatment, and had been successfully treated combined by cryotherapy and conjunctival flap covering surgery. This is the first case of peripheral ulcerative keratitis (PUK) and necrotizing scleritis treated by cryotherapy and conjunctival flap covering surgery in GPA reported in the literature. Our objective in presenting this particular case is to highlight the importance of timing in combined surgical interventions for such refractory cases to avoid severe visual impairment.

Disclosure. Authors have no conflict of interest, and the work was not supported or funded by any drug company.

Case Report. A 70-year-old man presented with a progressively worsening pain and redness in his right eye during the previous 6 months, and gradually decreasing visual acuity that started one month earlier. In his history, there was no evidence of systemic diseases. He had been treated as keratitis elsewhere for one month, however, the pain and redness has not decreased. Visual acuity was 4/10 in his right eye. The diagnosis of necrotizing scleritis with PUK of GPA in the right eye was carried out on the basis of characteristic examination. The slit lamp revealed deep violaceous episcleral injection, dilated perilimbal vessels with limbal edema, and a corneal epithelial defect associated with an area of corneal thinning (Figure 1A). There was no evidence of posterior segment involvement. Tissue scrapings for bacteria and fungus were negative. Computed tomography of the chest and the results of renal function tests were normal. A tuberculosis skin test was negative, but laboratory testing for both anti-neutrophilic cytoplasmic antibody (c-ANCA) and anti-protease 3 were positive. The positive c-ANCA and ophthalmic complications were suggestive of GPA.

Treatment was initiated with pulse methylprednisolone, tapering oral prednisone, and cyclophosphamide. Tobramycin and dexamethasone eye drops, tacrolimus eye drops, and autologous serum eye drops were also instilled. Because he had made little progress with the treatment and perforation seemed possible, he was taken to the surgery room for removal of the necrotic tissue combined with cryotherapy and conjunctival flap covering surgery on the sixth hospital day. Topical anesthesia was given before the surgery. A 4 mm wide perilimbal strip of affected conjunctiva was resected between the 10 and 2 o'clock meridians adjacent to the stromal melt in the right cornea. The center and edge within one mm of the ulcer were carefully removed to expose the stroma of the ulcer and healthy tissue using a sterilized scalpel under a stereomicroscope. The corneal and scleral lesions were then treated with cryotherapy for 7 dots, and covered with a conjunctival flap, and sutured with 10-0 nylon sutures. Condensation lasted for 20 seconds each time at -70°C using a CO_2 dry freezer. Antibiotic ointment was applied and the eye was patched. Medication was administered as described above after the surgery. The symptom was relieved after surgery 5 days later (Figure 1B). Seven days later the stitches were removed (Figure 1C). At the 2-month follow-up, the titers of c-ANCA returned to normal, and the patient's ocular condition remained stable thereafter (Figure 1D).

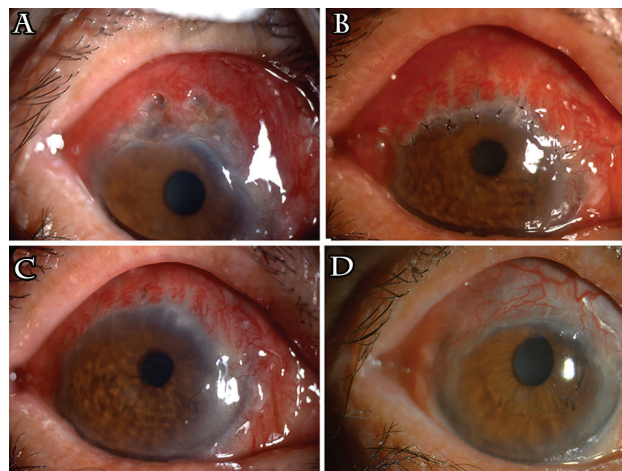


Figure 1 - The evaluation in the right eye showing: A) the slit lamp reveals necrotizing scleritis with peripheral ulcerative keratitis of granulomatosis with polyangiitis in the right eye presurgery; B) 5 days after surgery, the symptom was relieved; C) 7 days after surgery, the stitches were removed; and D) 2-month after surgery, the patient's ocular condition remained stable.

Discussion. Ocular disease may be the presenting or dominant symptom in a patient with WG. The largest long-term cohort of GPA patients in the literature found 52% of patients developing ophthalmologic disease, with 8% of patients suffering disease-related vision loss. Necrotizing scleritis, signified by scleral thinning and a bluish appearance from the underlying choroid, may lead to scarring, infection, and in advanced cases, perforation and phthisis bulbi. Conjunctivitis in GPA may be ulcerative and necrotic, and results in marked cicatricial changes of the ocular surface. Corneal involvement is often seen as an associated adjacent corneal infiltrate in active scleritis, and has also been described as an isolated phenomenon. Corneal disease may also manifest as PUK.

Necrotizing scleritis and peripheral ulcerative keratitis often have a poor visual outcome, and may herald an underlying systemic vasculitis. Thus, the ophthalmologist should have a high index of suspicion and inquire regarding other disease-associated features, which may be symptomatic or asymptomatic. The diagnosis in cases of limited ophthalmic GPA can be difficult. Early identification of the limited ophthalmic variant has been based on a combination of positive immunolabeling with c-ANCA and characteristic disease manifestations in the form of retro-orbital granulomas or necrotizing scleritis.^{3,4} Conjunctival biopsy may be a valuable method for diagnosing systemic GPA.⁵ The role of interdisciplinary approach with a rheumatologist must be emphasized.

Conventional therapy with cyclophosphamide and high-dose corticosteroids remains the preferred treatment for severe disease, but uncertainty remains about the most appropriate rescue therapy in patients with refractory disease. The PUK in GPA is associated with the presence of autoantibody and inflammatory cells. The inflammatory cells and circulating antibodies implicated in GPA's ulceration possibly reach the sclera and cornea through the limbal blood vessels. Combination of conjunctivectomy with cryotherapy is effective for the treatment of Mooren's ulcer. The aim is to reduce the antibody-producing inflammatory cells present in the conjunctiva adjacent to the ulcer.⁶ Thus, we decided to perform those surgeries in our case. The underlying mechanism of this combined therapy may be explained by the following points: 1) elimination of necrotic tissue is aimed at reducing the antibody-producing inflammatory cells present adjacent to the ulcer, and improve the effect of cryotherapy and absorption of anti-inflammatory and immune modulatory agents;⁷ 2) along with removing pathological tissue, cryotherapy could also reduce inflammation caused by the central area of ulcer and neovascularization. Rapid cooling could form intracellular ice crystals and disrupt the cell membrane. The re-warming process after surgery could damage the cell membrane again;⁸ 3) freezing could remove part of the antigen-antibody complexes and reduce the effect of toxins, as well as protein lysozymes;⁹ 4) during the re-warming process, the immune system is stimulated. This results in production of interferon by the affected cells, thereby regulating the body's immune system, promoting the growth of healthy tissue and significantly shortening the duration of healing,⁹ and 5) the conjunctival flap is beneficial through the increased vascularity to the site of infection and also by providing a stable ocular surface.¹⁰ The tension of conjunctival flap should be as small as possible to prevent postoperative conjunctival flap back.

In conclusion, the ophthalmologist should have a high index of suspicion and inquire regarding disease-associated features to make the diagnosis in cases of limited ophthalmic GPA. Our case was successfully treated for refractory necrotizing scleritis and PKU associated with GPA that was not sensitive, or aggravated for traditional methods. Surgical intervention for such refractory case is very important to avoid severe visual impairment.

References

1. Pahor D, Gracner B, Gracner T, Pahor A. [Ocular symptoms as the initial signs of Wegener's granulomatosis] *Klin Monbl Augenheilkd* 2009; 226: 409-413. German
2. McCluskey PJ, Watson PG, Lightman S, Haybittle J, Restori M, Branley M. Posterior scleritis: clinical features, systemic associations, and outcome in a large series of patients. *Ophthalmology* 1999; 106: 2380-2386.
3. Hellmich B, Flossmann O, Gross WL, Bacon P, Cohen-Tervaert JW, Guillevin L, et al. EULAR recommendations for conducting clinical studies and/or clinical trials in systemic vasculitis: focus on anti-neutrophil cytoplasm antibody-associated vasculitis. *Ann Rheum Dis* 2007; 66: 605-617.
4. Soukiasian SH, Foster CS, Niles JL, Raizman MB. Diagnostic value of anti-neutrophil cytoplasmic antibodies in scleritis associated with Wegener's granulomatosis. *Ophthalmology* 1992; 99: 125-132.
5. Ursea R, De Castro D, Bowen TJ, Chan CC. The role of conjunctival biopsy in the diagnosis of granulomatosis with polyangiitis. *J Ophthalmic Inflamm Infect* 2015; 5: 1.
6. Fasina O, Ogundipe A, Ezichi E. Mooren's ulcer in Ibadan, southwest Nigeria. *J West Afr Coll Surg* 2013; 3: 102-119.
7. Genvert G, Sakaue C, Arentsen J. Treatment of marginal corneal ulcer with cryotherapy and conjunctival recession or resection. *Cornea* 1984-1985; 3: 256-261.
8. Gage AA, Baust JG. Mechanisms of tissue injury in cryosurgery. *Cryobiology* 1998; 37: 171-186.
9. Qiao Z. Physical therapy pandect. Beijing (China): Scientific and Technic Literature Press; 2001. pg. 866-868.
10. Gundersen JH, Mannis MJ, Holland EJ. Cornea: Surgery of the Cornea and Conjunctiva. 2nd ed. St. Louis (MO): Mosby-Year Book; 2005. pg. 1763-1771.