

Primary carcinoma multiplex

J. MALCOLM CAMERON, A. LITTON, AND D. S. LYON

From the Department of Pathology and Surgery, Southern General Hospital, Glasgow

SYNOPSIS During the past 11 years almost 4,000 necropsies have been performed at the Southern General Hospital, Glasgow, and of these, 924 showed malignancy of which 45 were of primary carcinoma multiplex. Two cases showed triple and one quadruple malignancy, and the remainder two primary malignant tumours.

Primary cancer occurring in more than one organ or in more than one site in a single organ is no rarity. Slaughter (1944) reviewed the literature and collected 1,868 such cases. There are, however, few British references.

The idea of a unicentric origin of carcinoma is gradually giving place to the view that a multicentric origin is not uncommon, and that cancer, so far from being a local disease, is more of the nature of a general condition.

Billroth (1879) was the first to record multiple malignancy. He described two cases and suggested that certain conditions had to be satisfied before a diagnosis of multiple primary tumours could be established. Not only must tumours arise in different situations but they should have an independent histological appearance and each tumour should be capable of producing its own metastases.

It is thought that similar growths occurring in the same tissue or in bilateral organs, such as the breast and kidney, should be debarred and counted as one. The skin should also be regarded as a single organ except where the tumours are of obviously different histogenesis.

MATERIAL

Between January 1950 and December 1960 3,771 necropsies were performed at the Southern General Hospital, Glasgow. In 924 patients malignant disease

was found (Table I). Of these, 879 showed one primary neoplasm, 42 showed two, two showed three, and one showed four (Table II), an incidence

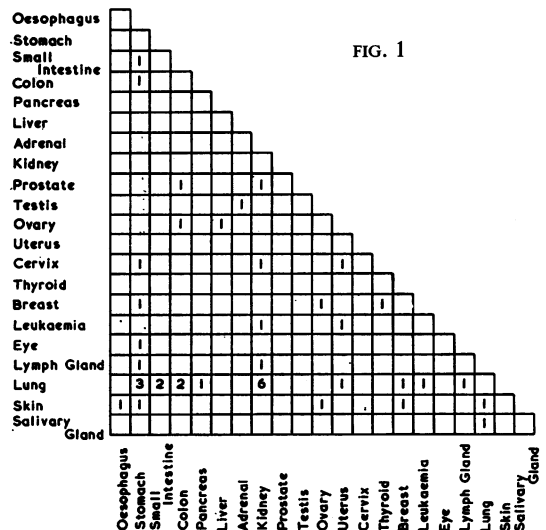
TABLE II
INCIDENCE OF MULTIPLE PRIMARY TUMOURS

<i>No. of Primary Tumours</i>	<i>Male</i>	<i>Female</i>	<i>Total</i>
Single	513	366	879
Double	18	24	42
Triple	2	—	2
Quadruple	—	1	1
Total	533	391	924

of 4.87% with multiple carcinoma. The site distribution of tumours in the 42 patients with two primary malignant tumours is shown in Fig. 1. The sex distribution, although differing slightly from

TABLE I
SEX DISTRIBUTION

<i>Sex</i>	<i>Necropses Showing Cancer</i>	<i>No. of Primary Tumours</i>
Male	533	555
Female	391	418
Total	924	973



the previous American series, shows, as did Pennell (1958), a slight predominance in females (24 females as to 18 males).

The case reports of the three cases of primary carcinoma multiplex will be given more fully.

CASE REPORTS

CASE 1 A 78-year-old retired cobbler was admitted to hospital (October 1959) in very poor general condition, complaining of general weakness, anorexia, and diarrhoea. He was found to have obvious weight loss and pressure sores over the sacrum. Abdominal examination revealed a palpable epigastric mass suggesting a tumour of the alimentary tract. He was not fit for detailed investigation, and steady deterioration continued till his death two weeks later.

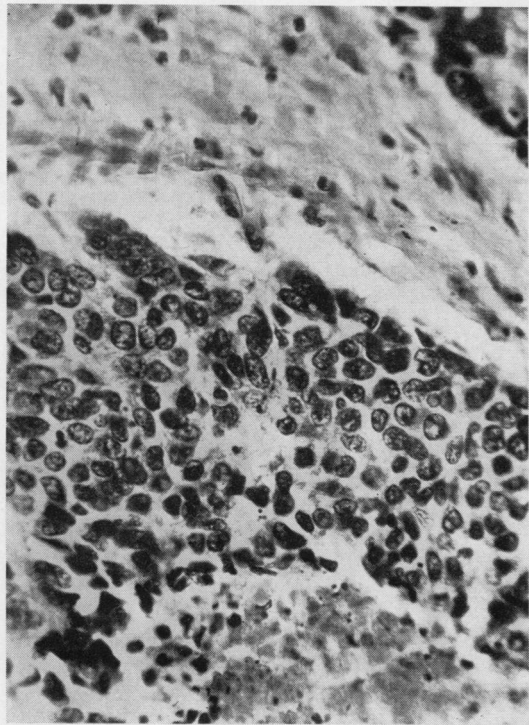


FIG. 2. *Histological examination of the oesophageal tumour in Case 1 confirms the presence of a poorly differentiated squamous cell carcinoma. Haematoxylin and eosin $\times 480$.*

Relevant necropsy findings The oesophagus showed, 4 in. from the cardia, a fungating neoplasm stretching from that point to within 1 in. of the cardia. Histologically, this was a poorly differentiated squamous cell carcinoma (Fig. 2).

The upper abdominal mass was found to be a carcinoma of the head of the pancreas (Fig. 3) and histological examination revealed an adenocarcinoma of

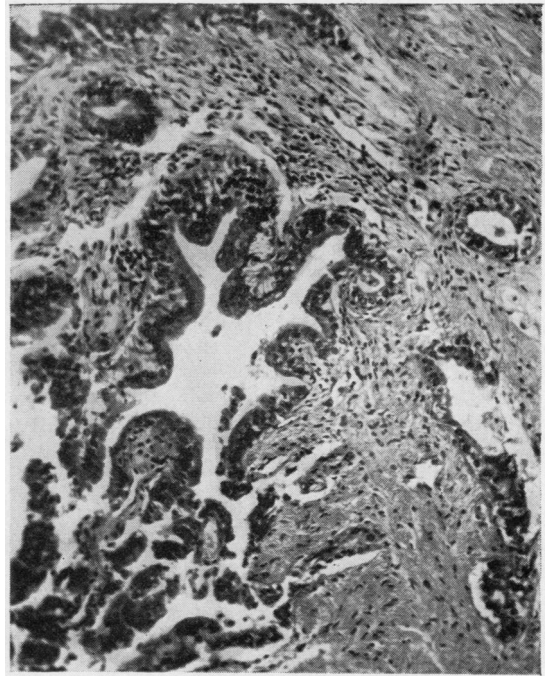


FIG. 3. *The pancreas of Case 1 shows extensive infiltration with adenocarcinoma of ductal origin. Haematoxylin and eosin $\times 140$.*

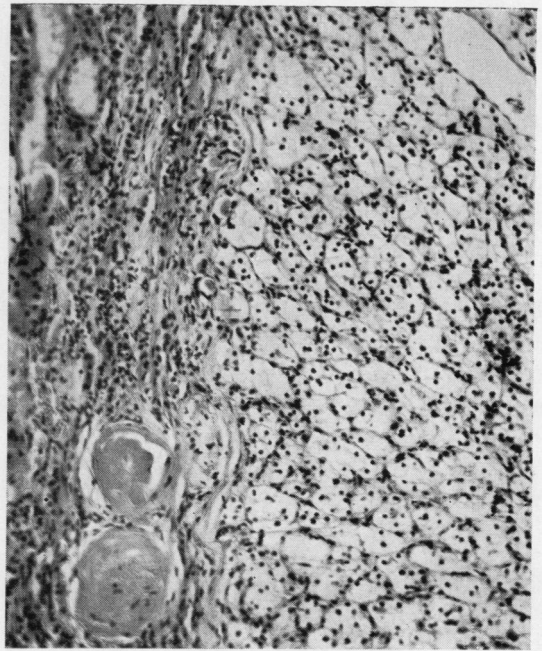

FIG. 4. *A renal carcinoma of clear cell type in Case 1. Haematoxylin and eosin $\times 68$.*

ductal origin. On the cortical surface of the right kidney there appeared to be a small adrenal rest, but histologically (Fig. 4) this was found to be a clear cell renal carcinoma.

CASE 2 A 77-year-old, healthy looking man was admitted to hospital in July 1958 on account of increased frequency of micturition associated with painless haematuria of seven months' duration. The bladder was not distended and there were no abnormal palpable masses. Rectal examination disclosed a smooth firm enlargement of the prostate with one hard nodule. The blood urea was 65 mg. %. An intravenous pyelogram showed no radio-opaque renal calculi and that both kidneys were excreting satisfactorily. The urinary bladder did not fill completely and was thought to be due to extrinsic causes. Cystoscopy, however, revealed widespread papillomata of the bladder, biopsy of which showed malignant change. The patient collapsed and died suddenly 12 days later.

Necropsy At necropsy the cause of death was found to be multiple small bilateral pulmonary emboli. At the upper pole of the left kidney there was a firm white tumour 3 cm. in diameter. Histologically this was a clear cell renal carcinoma. Microscopic examination of the prostate revealed primary adenocarcinoma and of the bladder papillary carcinoma of transitional cell type.

CASE 3 In October 1957 a 65-year-old woman had a right hemicolectomy performed for a primary carcinoma of

caecum (Fig. 5). In December 1957 a left radical mastectomy was carried out for a primary carcinoma of breast; the mastectomy was followed by radiotherapy. In February 1960, a rodent ulcer at the inner canthus of the left eye was treated by radiotherapy. In March 1960 she returned with symptoms of intestinal obstruction. Laparotomy was performed shortly after her admission. The lower colon was the site of an extensive tumour causing the obstruction and a transverse colostomy was performed. Suddenly on the eighteenth post-operative day she developed acute chest pain, collapsed, and died in a few moments.

Necropsy At necropsy, the primary cause of death was pulmonary embolism. There was a soundly healed left mastectomy scar and post-irradiation scarring of the left inner canthus at the site of the previously treated rodent ulcer. A simple colloid adenoma was found in the right lobe of the thyroid. The pelvic tumour mass was a large, fungating, well-differentiated primary adenocarcinoma of the rectum (Fig. 6). Secondary adenocarcinoma was found in the pelvic lymph glands but there was no other intra-abdominal secondary tumour. Apart from six simple jejunal diverticulae, there was no other abnormality of the alimentary tract. The uterus, on section, showed two simple fundal leiomyomata. On section of the brain, a small circular tumour, 1.5 cm. in diameter, was situated in the posterior commissure. Histologically this nodule showed secondary infiltration

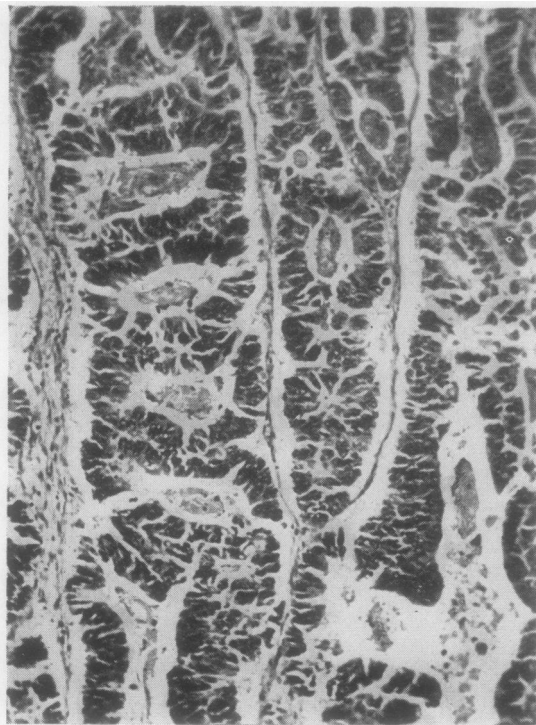


FIG. 5. An adenocarcinoma of caecum in Case 3. Haematoxylin and eosin $\times 140$.

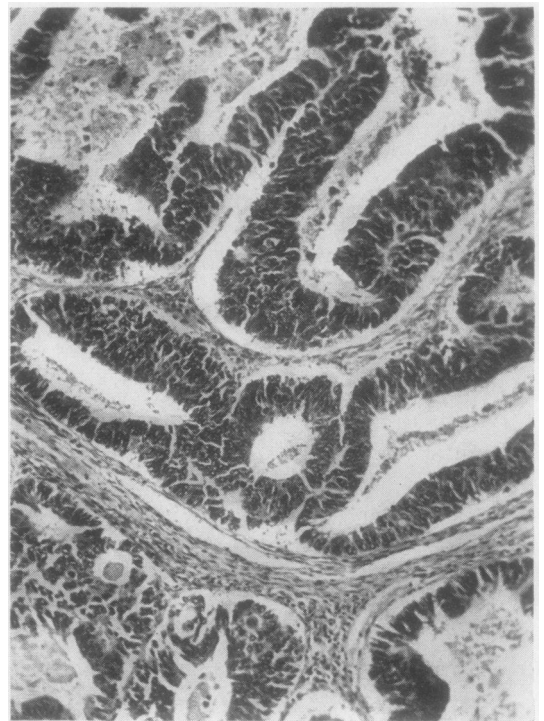


FIG. 6. A well-differentiated adenocarcinoma of the rectum in Case 3. Haematoxylin and eosin $\times 140$.

TABLE IV

COMPARISON OF FIGURES FOR CARCINOMA MULTIPLEX FROM VARIOUS CENTRES

Centre	Date	Total Malignant Tumours	Multiple Primary Malignant Tumours	Author
Leningrad	1931	1,238	23 (1.8%)	Goriainowa and Schabad
Harvard University	1932	1,078	40 (3.7%)	Warren and Gates
Mayo Clinic	1933	2,124	71 (3.3%)	Hurt and Broders
Michigan University	1934	983	30 (3.1%)	Bugher
Wisconsin University	1936	583	46 (7.8%)	Burke
London	1957	3,096	299 (9.7%)	Wallace
Glasgow	1961	973	94 (9.6%)	Present series

with a spheroidal cell carcinoma suggesting an origin from breast.

There was quite clear evidence in the section that there was a cribriform intraduct carcinoma as well as multiple papillomata throughout the ducts. The mammary tumour showing these duct changes demonstrated their local origin.

DISCUSSION

Pathologists have been interested for many years in the study of multiple malignant primary neoplasms (Table IV). This subject is of considerable importance to surgeons and was discussed by them in London in 1930 (Norbury) and again in 1944 (Whigham). These, together with the publications of Williamson (1950), Wallace (1957), and Pennell (1958), appear to be the only reviews in the British literature. Innumerable isolated cases have, however, been described in all parts of the world during this and the last century. Our own results are compared in Table IV with those from other centres, the Glasgow figure of 9.6% being paralleled by the London percentage.

Thomas, Dockerty, and Waugh (1948) concluded that multiple primary carcinoma is a reflection of an inherent constitutional susceptibility to cancer which is present in some individuals. Ewing (1928) suggested that one malignant growth in an individual provides fertile soil for the development of a second tumour. This implies that the risk of developing cancer is not evenly spread over the population, and that some individuals are more susceptible than others or are more exposed to influences bringing about its development.

Mider, Schilling, Donovan, and Rendall (1952) suggested that the probability that an individual with one primary neoplasm is more likely to develop a second one, than could be accounted for by mere chance, is favoured by Warren and Gates (1932),

Mider *et al.* (1952), and Barrett, Miller, and Fessenmeyer (1949). Watson (1953), on the other hand, came to the conclusion that there was no evidence of a tendency to develop a second growth, nor was there any evidence that one growth conferred a relative immunity against plurality.

The occurrence of multiple cancers is becoming an increasingly important clinical fact because an ageing population has a higher incidence of carcinoma. Already facilities for early diagnosis, modern radiotherapy and chemotherapy, and safer anaesthesia have encouraged a more radical approach to treatment, and with initial tumours thus ablated, or held in check, even more cases of multiple malignancy may occur.

We are indebted to Dr. A. Dick and Mr. R. B. Wright for their criticism and advice during the preparation of this paper, and to Mr. G. F. Hadden for technical and photographic assistance.

REFERENCES

- Barrett, W. D., Miller, K. T., and Fessenmeyer, C. R. (1949). *Surg. Gynec. Obstet.*, 89, 767.
- Billroth, C. A. T. (1879). *Chirurgische Klinik Wien, 1871-1876*, p. 258.
- Hirschwald, Berlin. Cited by Eisenstaedt, J. S. (1938). *J. Amer. med. Ass.*, 110, 2056.
- Bugher, J. C. (1934). *Amer. J. Cancer*, 21, 809.
- Burke, M. (1936). *Ibid*, 27, 316.
- Ewing, J. (1928). *Neoplastic Diseases*, 3rd ed., p. 37. Saunders, Philadelphia.
- Goriainowa, R. W., and Schabad, L. M. (1931). *Z. Krebsforsch.*, 33, 594.
- Hurt, H. H., and Broders, A. C. (1933). *J. Lab. clin. Med.*, 18, 765.
- Mider, G. B., Schilling, J. A., Donovan, J. C., and Rendall, E. S. (1952). *Cancer (Philad.)*, 5, 1104.
- Norbury, L. E. C. (1930). *Proc. roy. Soc. Med.*, 24, 198.
- Pennell, V. (1958). *Brit. J. Surg.*, 46, 108.
- Slaughter, D. P. (1944). *Int. Abst. Surg.*, 79, 89., *Surg. Gynec. Obstet.* (1954), 99, 770.
- Thomas, J. F., Dockerty, M. B., and Waugh, J. M. (1948). *Cancer*, 1, 564.
- Wallace, A. F. (1957). *Brit. J. Surg.*, 45, 165.
- Warren, S., and Gates, O. (1932). *Amer. J. Cancer*, 16, 1358.
- Watson, T. A. (1953). *Cancer (Philad.)*, 6, 365.
- Whigham, J. R. M. (1944). *Proc. roy. Soc. Med.*, 37, 233.
- Williamson, T. B. (1950). *Brit. med. J.*, 1, 648.