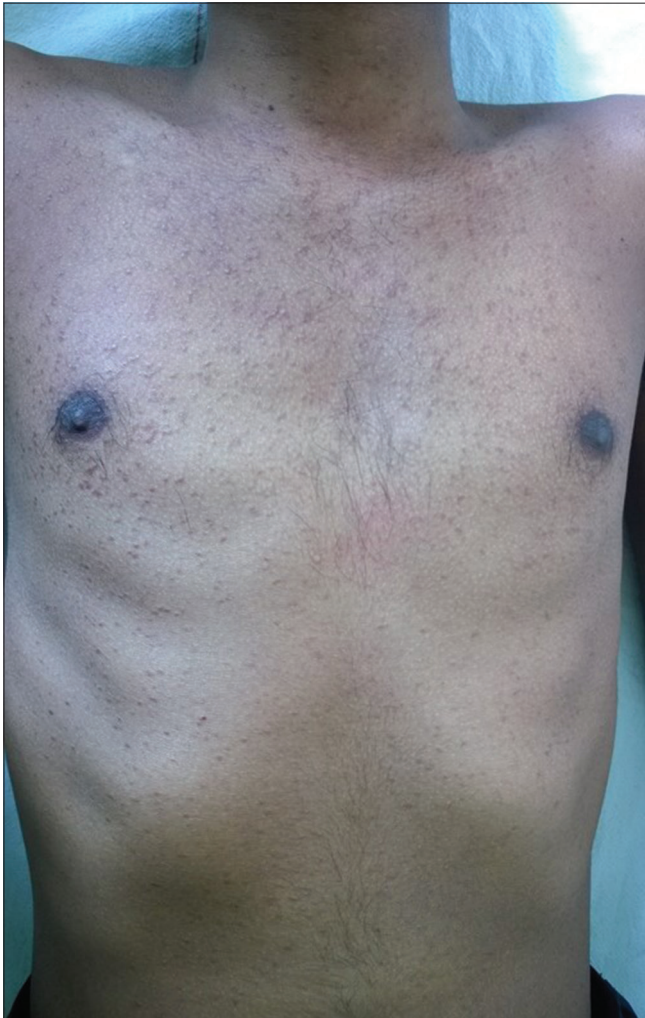

## Generalized eruptive syringoma: A clinical dilemma

Sir,

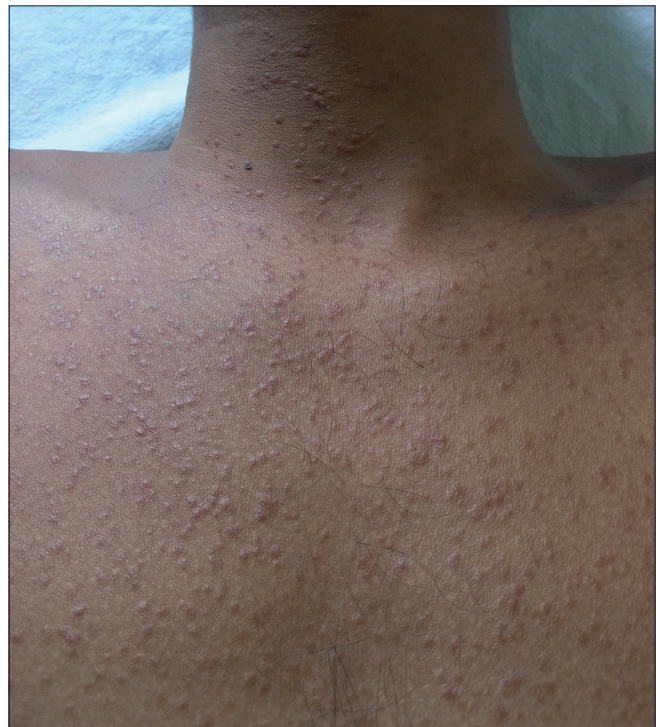A 23-year-old man presented with mildly pruritic, small erythematous papules mainly on the face, neck, and trunk. The lesions first appeared on the forehead five years back and progressed to involve other areas of the body. There was no history of prolonged drug intake and family history was noncontributory. On examination, multiple skin-colored to erythematous nonfollicular and follicular papules were seen on the face, neck, and trunk regions [Figures 1-3]. The differential diagnoses of eruptive syringoma, acneiform eruption, and sebaceous hyperplasia were considered. Skin biopsy was done from a lesion on the upper chest. Histopathologic examination revealed mature sweat ducts lined by two layers of cuboidal cells and few having an epithelial elongation of the ducts, the



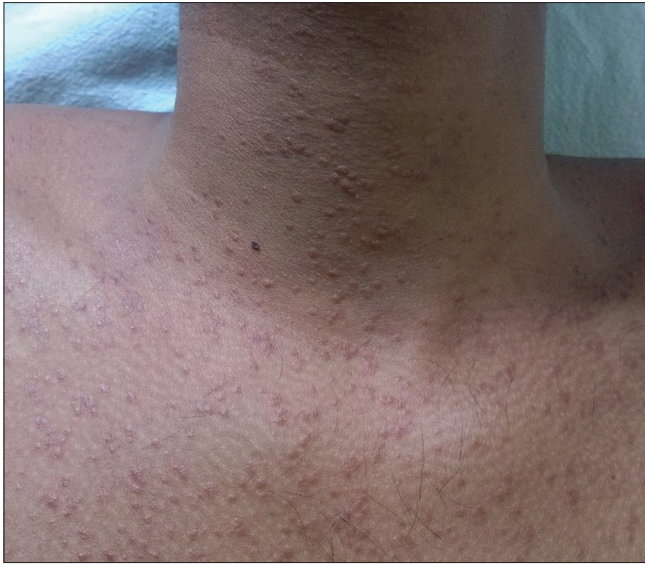**Figure 1:** Multiple skin-colored follicular and nonfollicular papules

so-called “tadpole” appearance [Figure 4]. Consequently, a diagnosis of generalized eruptive syringoma was made. The patient was started on oral isotretinoin (20 mg/day).

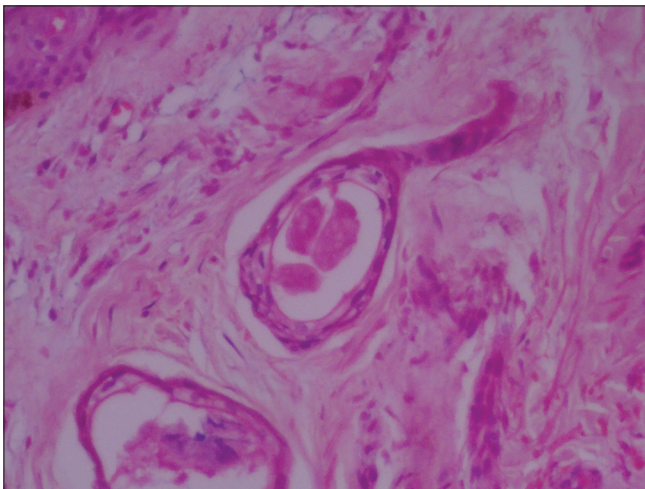
First described by Kaposi,<sup>[1]</sup> syringomas are benign tumors derived from intraepidermal portion of the eccrine sweat ducts.<sup>[1,2]</sup> Generalized eruptive syringoma is a rare entity and is seen in women mainly during puberty or later. Jacquet and Darier in 1987 first described this variant. Friedman and Butler classified four principal clinical variants of syringoma: A localized form, a familial form, a form associated with Down syndrome, and a generalized form that encompasses multiple and eruptive syringomas.<sup>[3]</sup> Although several theories have been proposed, the pathogenesis of eruptive syringoma still remains unclear. They usually appear as multiple skin-colored, yellow, brown or pink papules ranging from 1 to 3 mm in size. Most commonly seen on the eyelid and upper cheek, but in the eruptive variant they can appear on axilla, trunk, and genital areas. Some authors have reported the occurrence of syringomas after waxing in the pubic areas. Familial cases of syringomas are also seen. Differential diagnosis includes acneiform eruptions, sebaceous hyperplasia, hidrocystoma, eruptive xanthomas. Histopathological findings are distinct and confirmatory. Treatment is often unsatisfactory; electrodesiccation, dermabrasion, CO<sub>2</sub> laser, topical adapalene, topical tretinoin, and oral retinoids have been used with varied success. Very rarely, tumors may regress later in life. Itchy eruptive syringomas have been reported from India by Verma *et al.*<sup>[4]</sup> We report a case of mildly pruritic generalized eruptive syringoma in a 23-year-old man, which could be misdiagnosed



**Figure 2:** Multiple papules on the neck and upper chest



**Figure 3:** Close-up view of the erythematous papules



**Figure 4:** Sweat duct lined by two layers of cuboidal cells and having an epithelial elongation of the ducts, the so-called tadpole appearance (H and E,  $\times 40$ )

as acneiform eruption. Hence eruptive syringoma should be kept in the list of differential diagnosis in such cases.

#### Financial support and sponsorship

Nil.

#### Conflicts of interest

There are no conflicts of interest.

**Abhijeet Kumar Jha, Rajesh Sinha,  
Smita Prasad, Ruchi Sinha<sup>1</sup>**

Departments of Dermatology, STD and Leprosy and <sup>1</sup>Pathology and Lab Medicine, All India Institute of Medical Sciences, Patna, Bihar, India

#### Address for correspondence:

Dr. Abhijeet Kumar Jha,  
Department of Dermatology, STD and Leprosy,  
All India Institute of Medical Sciences, Patna,  
Bihar, India.

E-mail: drabhijeetjha@gmail.com

#### REFERENCES

1. Kaposi M. Lymphangioma tuberosum multiplex. In: Fagge CH, editor. Hebra on Diseases of the Skin. Vol. 3. London: New Sydenham Society; 1872. p. 386.
2. Hashimoto K, DiBella RJ, Borsuk GM, Lever WF. Eruptive hidradenoma and syringoma. Histological, histochemical, and electron microscopic studies. Arch Dermatol 1967;96:500-19.
3. Friedman SJ, Butler DF. Syringoma presenting as milia. J Am Acad Dermatol 1987;16:310-4.
4. Verma SB. An unusual case of eruptive syringomas presenting as itchy symmetrical lesions on both forearms in a patient of hyperkeratotic eczema. Indian Dermatology Online J 2011;2:104-6.

This is an open access article distributed under the terms of the Creative Commons Attribution-NonCommercial-ShareAlike 3.0 License, which allows others to remix, tweak, and build upon the work non-commercially, as long as the author is credited and the new creations are licensed under the identical terms.

Access this article online	
Quick Response Code:	Website: <a href="http://www.idoj.in">www.idoj.in</a>
	DOI: 10.4103/2229-5178.178082

**Cite this article as:** Jha AK, Sinha R, Prasad S, Sinha R. Generalized eruptive syringoma: A clinical dilemma. Indian Dermatol Online J 2016;7:127-8.