



Modulatory potentials of aqueous leaf and unripe fruit extracts of *Carica papaya* Linn. (*Caricaceae*) against carbon tetrachloride and acetaminophen-induced hepatotoxicity in rats

Olufunsho Awodele¹, Omoniyi Yemitan², Peter Uduak Ise¹, Victor Olabowale Ikumawoyi¹

¹Department of Pharmacology, Therapeutics and Toxicology, College of Medicine, University of Lagos, Lagos, Nigeria, ²Department of Pharmacology, College of Medicine, Lagos State University, Lagos, Nigeria

Address for correspondence: Olufunsho Awodele, Department of Pharmacology, Therapeutics and Toxicology, College of Medicine, University of Lagos, Lagos, Nigeria. E-mail: awodeleo@gmail.com

Received: November 07, 2015

Accepted: January 18, 2016

Published: January 27, 2016

ABSTRACT

Introduction: *Carica papaya* Linn is used in a traditional medicine for hepatobiliary disorders. This study investigated the hepatomodulatory effects of aqueous extracts of *C. papaya* leaf (CPL) and unripe fruit (CPF) at doses of 100 and 300 mg/kg on carbon tetrachloride (CCl₄) and acetaminophen (ACM)-induced liver toxicities in rats. **Materials and Methods:** Rats were administered CCl₄ (3 ml/kg in olive oil, i.p.) followed by oral administration of CPL and CPF at 2, 6 and 10 h intervals. The ACM model proceeded with the same method but inclusive of animals treated with *N*-acetyl cysteine (3 ml/kg i.p). At the end of the study, serum levels of liver biomarkers and antioxidant enzymes were assessed and histology of the liver tissues determined. **Results:** There was a significant ($P < 0.05$) reduction in CCl₄ and ACM-induced increases in serum levels of alanine aminotransferase, aspartate aminotransferase, alkaline phosphatase and direct bilirubin at 100 and 300 mg/kg, respectively. The levels of catalase (CAT), superoxide dismutase and reduced GSH were decreased in both models with corresponding significantly ($P < 0.05$) elevated level of malondialdehyde. However, these antioxidant enzymes were significantly ($P < 0.05$) increased in CPL and CPF-treated rats. Histopathological assessment of the liver confirmed the protective effects of CPL and CPF on CCl₄ and ACM-induced hepatic damage evidenced by the normal presentation of liver tissue architecture. **Conclusion:** These results indicate that aqueous extracts of *C. papaya* may be useful in preventing CCl₄ and ACM-induced liver toxicities.

KEY WORDS: Acetaminophen, antioxidant, carbon tetrachloride, *Carica papaya*, hepatotoxicity, histopathological assessment

INTRODUCTION

Hepato-biliary disorders especially those induced by drugs are a worldwide problem [1]. More than a thousand drugs of the modern pharmacopoeia can induce liver injury with different clinical presentations [2,3]. In the most severe cases, drug-induced liver injury (DILI) can require liver transplantation or lead to the death of the patient [4] and can lead to the withdrawal of drugs from the market or earlier during clinical trials, thus causing huge financial losses [5].

In Nigeria, there is presently very little data about the etiology of DILI, but popular over-the-counter medications (OTC)

especially acetaminophen (ACM), is a frequent culprit. Thus, the study of hepatotoxicants as well as the search for hepatoprotectants is on the rise.

Carbon tetrachloride (CCL₄) has been proven to induce toxic effects in various organs on exposure to it. It is actively metabolized in the body tissues to its highly reactive halogenated metabolites (.CCl₃ and .Cl) and its metabolic activation is accompanied by the release of reactive oxygen species [6]. The reactive species and the free radicals released subsequently result in the induction of lipid peroxidation leading to array of organ toxicities such as hepatotoxicity, nephrotoxicity, neurotoxicity, cardiotoxicity, and hematotoxicity [7,8].

Carica papaya Linn (Pawpaw plant) is a perennial, herbaceous plant with copious milky latex, broad leaves and grows to heights reaching 6-10 m with large succulent fruits and a complicated means of reproduction [9]. The anti-sickling [10], antihelminthic [11], anti-diabetic [12], and anti-cancer [13] properties of the Pawpaw plant have been demonstrated in previous works.

The boiled leaves of *C. papaya* are used in African traditional medicine in combination with leaves of *Azadirachta indica*, *Cymbopogon citratus*, *Psidium guajava*, and stem bark of *Alstonia boonei* boiled together and the hot infusion drunk as one wine glass full thrice daily in the treatment of malaria [11]. Its fresh leaves are also efficacious in the treatment of gonorrhoea, syphilis and amoebic dysentery [11]. The milky juice of the unripe fruit is a powerful abortifacient, antihelminthic for roundworms, stomach disorders and enlargement of liver and spleen [11]. The seeds are also used as a vermifuge [11].

The present study was carried out to investigate the hepatoprotective effects of aqueous extracts of unripe fruit pulp and leaves of *C. papaya* as well as elucidate its possible mechanism of hepatoprotection in rats.

MATERIALS AND METHODS

Plant Material

Collection and identification of plant parts

Freshly harvested leaves and mature, but unripe fruits of *C. papaya* were purchased from the Mushin Market in Lagos, Nigeria. Plant identification was carried out by Oyebanji and authenticated by Odewo, both of the Department of Botany, University of Lagos, Lagos, Nigeria and stored at the University Herbarium with LUH 5748 assigned as the reference number.

Drugs and Chemicals

CCl_4 (JHD chemicals, China), KCl (GPR, Germany), phosphate buffer (BDH, Germany), Sodium carbonate buffer, hydrogen peroxide (Sigma-Aldrich, Germany), Dichromate-acetic reagent, polyethylene glycol (PEG) (Sigma-Aldrich, Germany), Normal saline (Unique pharmaceuticals, Lagos), ACM (May and Baker pharmaceuticals, Nigeria), N-acetyl cysteine (Zhangjiagang Huachang pharmaceuticals, China). All other reagents used were of analytical grade.

Extract Preparation

Leaves of *C. papaya* were air-dried at room temperature ($24 \pm 2^\circ\text{C}$) for 3 weeks to remove moisture. The dried leaves were weighed, ground into powder and macerated in distilled water in the ratio: 1:2 (200 g of leaf:400 ml of water). The mixture was then boiled in a beaker placed on a hot plate for 1 h, forming a brownish solution in the process. Percentage yield was found to be 12.5%.

Yield = weight of dry crude extract obtained (g)/weight of initial dry leaves (g) \times 100%

Also fresh, mature but unripe fruits of *C. papaya* were washed, peeled, cut to small pieces and soaked in 1 L of distilled water at a ratio of 1:1 (100 g fruit:100 ml water) at room temperature of 25°C , covered with a glass lid according to the method of Oduola *et al.* [10].

After 72 h, the solution was filtered using a clean piece of muslin cloth and filter paper. For the leaf and fruit extracts, the filtrate was oven-dried at 40°C in pre-weighed beakers and the concentrate refrigerated at 4°C until needed.

Experimental Animals

Sprague-Dawley rats of both sexes weighing between 150 g and 180 g were purchased from the Laboratory Animal Centre of the Lagos State University College of Medicine and were acclimatized to the laboratory conditions for 2 weeks. They were housed in clean propylene cages and fed with standard rodent pellets (Nigeria Institute of Medical Research, Yaba) and water was provided *ad libitum*. The experimental protocol adopted in this study was approved by the Experimentation Ethics Committee on Animal Use of the College of Medicine, University of Lagos, Nigeria and was in accordance with the United States National Institutes of Health Guidelines for Care and Use of Laboratory Animals in Biomedical Research [14].

Experimental Design

CCl_4 hepatotoxicity

Rats (6 groups, 6 per group) were randomly allotted to several groups: Groups I and II served as controls. Group I was administered 10 ml/kg olive oil (vehicle i.p.) plus 1 ml/kg normal saline orally at 2, 6 and 10 h. Rats in Group II were administered 3 ml/kg CCl_4 (20% v/v in olive oil i.p.) plus oral administration of normal saline at 2, 6 and 10 h. Group III were administered 3 ml/kg CCl_4 (20% v/v in olive oil i.p.) plus an oral dose of 100 mg/kg *C. papaya* leaf (CPL) extract at 2, 6 and 10 h. Group IV; 3 ml/kg CCl_4 (20% v/v in olive oil i.p.) plus oral administration of 300 mg/kg CPL extract at 2, 6 and 10 h. Group V; 3 ml/kg CCl_4 (20% v/v in olive oil i.p.) plus oral administration of fruit extract at 100 mg/kg in 2, 6 and 10 h. Group VI; 3 ml/kg CCl_4 (20% v/v in olive oil i.p.) plus oral administration of the fruit extract at 300 mg/kg in 2, 6 and 10 h.

ACM-induced Hepatotoxicity

ACM was dissolved in an equal volume of PEG 400 and normal saline solution. Rats (7 groups, 6 per group) were allotted randomly as follows: Groups I and II served as control. Group I rats were administered 10 ml/kg PEG (400/NS solution, per oral) plus 1 ml/kg NS at 2, 6 and 10 h. Group II; 600 mg/kg ACM per oral, plus 3 ml/kg NS at 2, 6 and 10 h. Groups III and IV were administered 600 mg/kg ACM per oral plus oral administration

of 100 mg/kg and 300 mg/kg leaf extract of *C. papaya* at 2, 6 and 10 h, respectively. Groups V and VI were administered 600 mg/kg ACM a oral plus oral administration of 100 mg/kg and 300 mg/kg fruit extract of *C. papaya* at 2, 6 and 10 h, respectively. Rats in Group VII were administered 10 ml/kg of PEG (400/NS solution, per oral) plus 3 ml/kg *N*-acetyl cysteine intraperitoneally at 2, 6, and 10 h.

All animals were restricted from feeding for 24 h after oral administration of CCl_4 and ACM solution before being sacrificed for assessment of liver histology, as well as serum biochemical and oxidative stress markers.

Collection of Liver for Hepatic Tissue Antioxidant Enzyme Assay

After blood collection through the cardiac puncture, a deep longitudinal incision was made into the ventral surface of the rat abdomen. The livers were identified and carefully dissected out from each rat. The right lobe of the liver was rinsed in ice-cold 1.15% KCl solution and stored in a clean sample bottle in ice.

Homogenization of Liver Tissue

The liver was washed in an ice cold 1.15% KCl solution blotted and weighed. It was then homogenized with 0.1 M phosphate buffer (pH 7.2) and blended with laboratory sand (acid washed sand) in a mortar. The resulting homogenate was centrifuged at 2500 rpm for 15 min and the supernatant decanted and stored at -20°C until used.

Assessment of Serum Hepatic Biomarkers

At 24 h post- CCl_4 or ACM administration, experimental rats were anaesthetized by putting each one in a glass jar containing ether-soaked cotton wool for about the 30s. Blood was obtained retroorbitally, through a heparinized capillary tube into a sample bottle. Each sample was centrifuged at 2500 G for 20 min to separate sera.

Samples were analyzed for alkaline phosphatase (ALP), alanine aminotransferase (ALT), aspartate aminotransferase (AST), direct bilirubin (DB), and uric acid level. The activity of serum ALP was determined at 405 nm using a standard method [15], serum ALT at 340 nm [16]. Uric acid levels were measured using the urease cleavage Berthlot's reaction [17]. The colorimetric method of Malloy and Evelyn [18], (Sulfanilic acid method) was used for the estimation of serum bilirubin.

Serum AST and ALT Determination

The method of Reitman and Frankel [16] was used. Into a test tube, 0.1 ml substrate (D, L-aspartate, 0.2 mol/L and α -ketoglutaric acid, 1.8 mmol/L in phosphate buffer, pH 7.5) solution was pipetted and placed in a 37°C water bath to warm. 0.2 ml plasma was added and shaken gently to mix. Exactly 1 h after adding plasma, 1.0 ml color reagent (2, 4-dinitrophenylhydrazine approximately 20 mg/100 ml,

in 10% HCl solution) was added and mixed gently and left at room temperature ($18-26^\circ\text{C}$). 20 min after adding color reagent, 10 ml 0.40 N sodium hydroxide solution was added and mixed by inversion. 5 min after, absorbance was read at 340 nm using water as a reference. AST activity in Sigma-Frankel units/ml was determined from the calibration curve. The same procedure was carried out for ALT except that procedures were started 30 min after starting AST. Substrate for ALT was L-alanine (0.2 mol/L) and α -ketoglutaric acid (1.8 mmol/L) in phosphate buffer, pH 7.5.

Serum ALP Determination

ALP was determined using the colorimetric endpoint method of Tietz *et al.* [15] and adapted by Teco Diagnostic Kits. The principle is based on the fact that ALP acts on the AMP-buffered sodium thymolphthalein monophosphate. The addition of an alkaline reagent stops enzyme activity and simultaneously develops a blue chromogen, which is measured photometrically. For each sample 0.5 ml of ALP substrate was dispensed into labeled test tubes and equilibrated to 37°C for 3 min. At timed intervals 0.5 ml of standard, control and sample were added to their respective test-tube and mixed gently deionized water was used as blank. The samples were incubated for exactly 10 min at 37°C following the same sequences, 2.5 ml of ALP color developer at timed intervals were added. The wavelength of the spectrometer was set at 590 nm.

Assessment of Serum and Tissue Antioxidant Enzymes

The reduced glutathione (GSH) content of liver tissue as non-protein sulphhydryls was estimated according to the method described by Sedlak and Lindsay [19]. Superoxide dismutase (SOD) activity was determined using the methods of Sun and Zigma [20]. Serum catalase (CAT) activity was determined according to the method of Beers and Sizer as described by Kakker *et al.* [21] and Ushoh *et al.* [22]. CAT activity was determined by adopting the methods of Aksenes and Njaa [23]. Malondialdehyde (MDA) production was estimated using the methods as described by Buege and Aust [24].

Determination of Liver Tissue SOD Activity

SOD activity was determined by its ability to inhibit the auto-oxidation of epinephrine by the increase in absorbance at 480 nm as described by Sun and Zigma [20]. The reaction mixture (3 ml) contained 2.95 ml 0.05 M sodium carbonate buffer pH 10.2, 0.02 ml of liver homogenates, and 0.03 ml of epinephrine in 0.005 N HCl was used to initiate the reaction. The reference cuvette contained 2.95 ml buffer, 0.03 ml of substrate (epinephrine), and 0.02 ml of water. Enzyme activity was calculated by measuring the change in absorbance at 480 nm for 5 min.

Determination of Liver Tissue CAT Activity

Hepatic tissue CAT activity was determined according to Kakkar *et al.* [21] by measuring the decrease in absorbance at

240 nm due to the decomposition of H₂O₂ in UV recording spectrophotometer. The reaction mixture (3 ml) contained 0.1 ml of serum in phosphate buffer (50 mM, pH 7.0) and 2.9 ml of 30 mM of H₂O₂ in the phosphate buffer pH 7.0. An extinction coefficient for H₂O₂ at 240 nm of 40.0 M⁻¹ cm⁻¹ according to Aebi [25] was used for calculation. The specific activity of CAT was expressed as moles of H₂O₂ reduced per minute per mg protein.

Determination of Liver Tissue Reduced GSH Activity

The reduced GSH content in the liver tissue was estimated according to the method described by Sedlak and Lindsay [19]. To the homogenate 10% TCA was added and centrifuged. About 1 ml of the supernatant was treated with 0.5 ml of Ellman's reagent (19.8 mg of 5,5-dithiobisnitro benzoic acid in 100 ml of 0.1% sodium nitrate) and 3.0 ml of phosphate buffer (0.2 M, pH 8.0). The absorbance was read at 412 nm.

Determination of Liver Tissue MDA Activity

MDA an index of lipid peroxidation was determined using the method of Buege and Aust [25]. 1 ml of supernatant was added to 2 ml of (1:1:1 ratio) tricarboxylic acid (TCA)-thiobarbituric acid (TBA)-HCl reagent (TBA 0.37%, 0.24 N HCl and 15% TCA) TCA, TBA, reagent boiled at 100°C for 15 min, and allowed to cool. The flocculent material was removed by centrifuging at 3000 rpm for 10 min. The supernatant was removed, and the absorbance was read at 532 nm against a blank. MDA was calculated using the molar extinction for MDA TBA complex of 1.56 × 10⁵/m/cm.

Histopathological Assessment

The method of Baker and Silverston [26] was employed for the preparation of liver tissue before examination under the light microscope at a magnification of ×40.

Statistical Data Analysis

Data were calculated as mean ± standard error of mean. The mean of each treated group was compared for significance at P < 0.05, using analysis of variance, followed by Dunnett's *post hoc* multiple comparison tests. The Graph pad prism 6.0 was used for all statistical analysis.

RESULTS

Effects of Leaf and Fruit Extracts of *C. papaya* L. on Serum Hepatic Enzymes in CCl₄-Induced Hepatotoxicity in Rats

The results obtained with the intraperitoneal administration of 3 ml/kg, 20% v/v CCl₄ and aqueous preparations of plant extracts CPL and CPF showed significant (P < 0.05) decrease in all the serum enzymes in comparison with the control (CCl₄ alone). There was a decrease in ALT (126±11.92), AST (55.6±1.7), ALP (54.0±10.80), uric acid (138.7±21.80), and DB (1.5±0.20)

at 100 mg/kg CPL compared with the control, indicative of attenuation in hepatocyte destruction. However, at 300 mg/kg CPL, serum liver markers did not change significantly for ALT (128.3±1.80), AST (61.6±7.20), ALP (94.8±3.30), uric acid

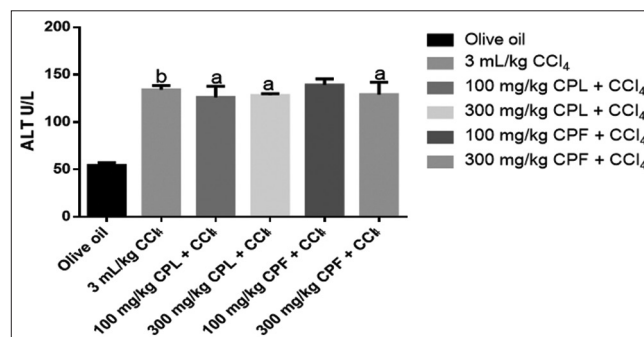


Figure 1: Effects of leaf and fruit extracts of *Carica papaya* L. on levels of alanine aminotransferase in carbon tetrachloride-induced hepatotoxicity in rats. Values are mean±SEM (n=5). ^ap < 0.05 vs CCl₄, ^bp < 0.05 vs olive oil (One Way ANOVA followed by Dunnett's posthoc multiple comparison test)

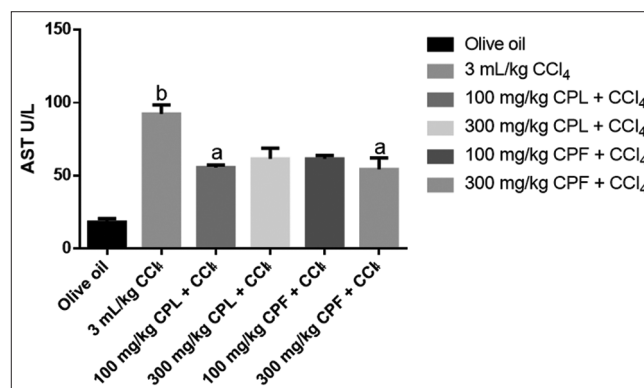


Figure 2: Effects of leaf and fruit extracts of *Carica papaya* L. on levels of aspartate aminotransferase in carbon tetrachloride-induced hepatotoxicity in rats. Values are mean±SEM (n=5). ^ap < 0.05 vs CCl₄, ^bp < 0.05 vs olive oil (One Way ANOVA followed by Dunnett's posthoc multiple comparison test)

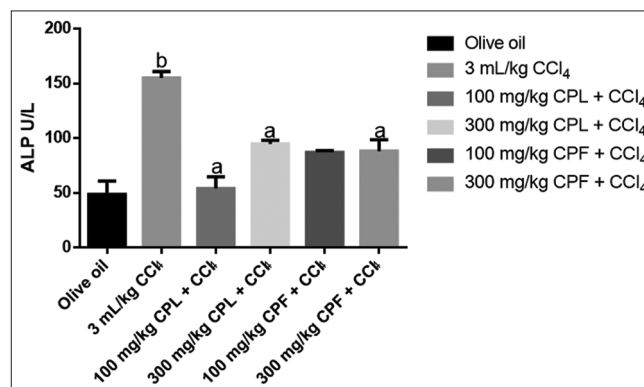


Figure 3: Effects of leaf and fruit extracts of *Carica papaya* L. on levels of alkaline phosphatase in carbon tetrachloride-induced hepatotoxicity in rats. Values are mean±SEM (n=5). ^ap < 0.05 vs CCl₄, ^bp < 0.05 vs olive oil (One Way ANOVA followed by Dunnett's posthoc multiple comparison test).

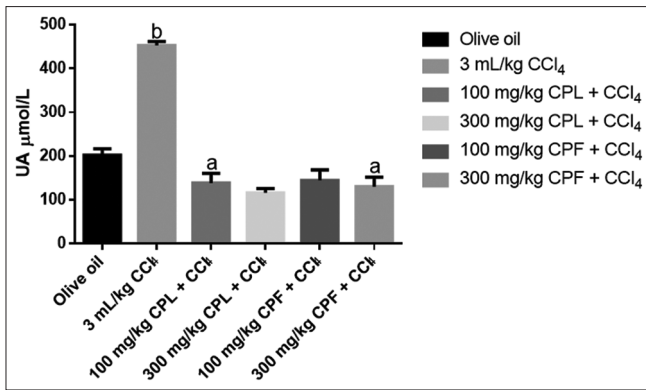


Figure 4: Effects of leaf and fruit extracts of *Carica papaya* L. on levels of uric acid in carbon tetrachloride-induced hepatotoxicity in rats. Values are mean±SEM (n=5). ^ap < 0.05 vs CCl₄, ^bp < 0.05 vs olive oil (One Way ANOVA followed by Dunnett's posthoc multiple comparison test)

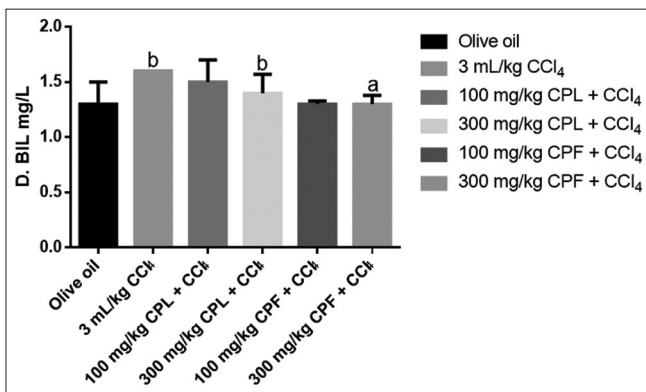


Figure 5: Effects of leaf and fruit extracts of *Carica papaya* L. on levels of direct bilirubin in carbon tetrachloride-induced hepatotoxicity in rats. Values are mean±SEM (n=5). ^ap < 0.05 vs CCl₄, ^bp < 0.05 vs olive oil (One Way ANOVA followed by Dunnett's posthoc multiple comparison test)

(115.9±10.20), and DB (1.3±0.08). There was no significant difference in serum enzyme levels between aqueous leaf extract (CPL) and unripe fruit extract (CPF) of *C. papaya* at all the doses (100 mg/kg and 300 mg/kg) however, at each of the doses, serum enzymes were slightly lower with the leaf extract (CPL) for serum liver markers ALT, AST, ALP, and DB when compared with the fruit extract (CPF) [Figures 1-5].

Effects of Leaf and Fruit Extracts of *C. papaya* L. on Serum Antioxidant Enzymes in CCl₄-Induced Hepatotoxicity in Rats

The results obtained with CCl₄ administration at 3 ml/kg intraperitoneally showed a significant ($P < 0.05$) reduction in serum levels of GSH, SOD and CAT but increased levels of MDA when compared with olive oil treated rats. At 100 mg/kg, CPL showed significant ($P < 0.05$) increase in GSH (1.52 ± 0.20) compared with CCl₄ treated (0.59 ± 0.10), SOD (3.87 ± 1.26) compared with CCl₄ treated (2.53 ± 0.40) as well as lower levels of MDA (0.04 ± 1.50) also compared with CCl₄ treated (0.07 ± 0.00) rats. However, there were no significant ($P < 0.05$) changes in serum antioxidant enzymes in rats treated with leaf

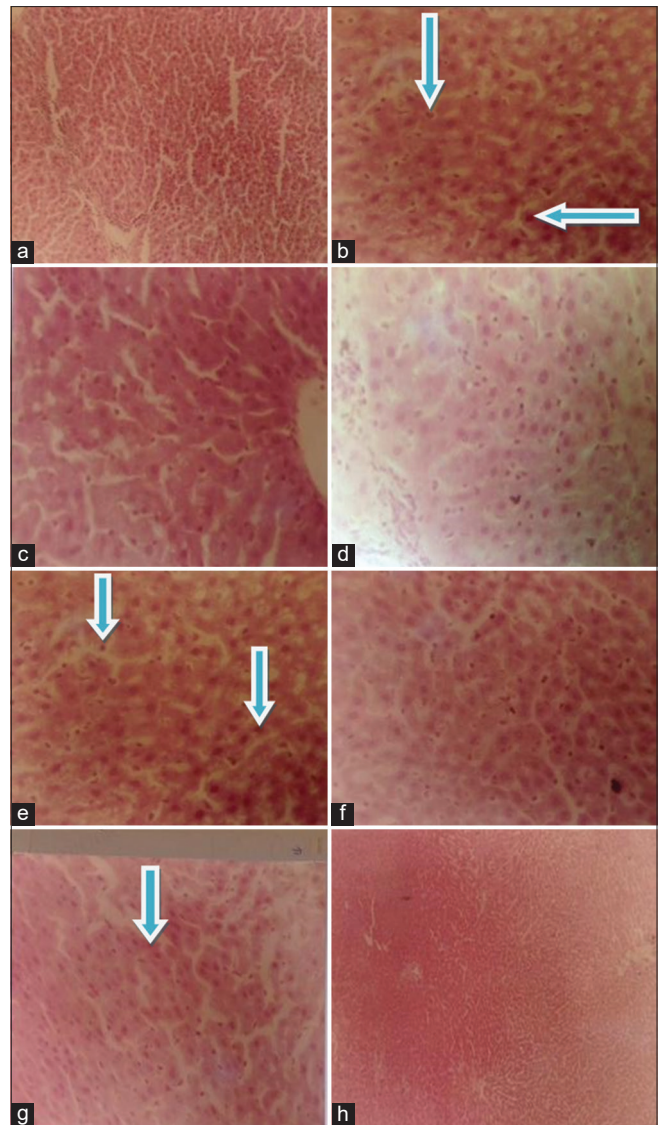


Figure 6: (a). Olive oil with no cellular abnormalities (b). CCl₄ showing congested vascular channels, fatty lesions and necrotic formation (c). 300 mg/kg CPL and 20% CCl₄ with no cellular abnormalities (d). 300 mg/kg CPF + CCl₄ with no cellular abnormalities (e). 600 mg/kg ACM showing fatty lesions and necrotic formation (f). NAC with no cellular abnormalities (g). 600 mg/kg ACM + 300 mg/kg CPL showing mild necrosis (h). 600 mg/kg ACM + 300mg/kg CPF with no cellular abnormalities

(CPL) and fruit extracts (CPF) at 100 mg/kg and 300 mg/kg respectively compared to those that were given CCl₄ alone.

Effects of Leaf and Fruit Extracts of *C. papaya* L. on Liver Antioxidant Enzymes in CCl₄-Induced Hepatotoxicity in Rats

The rats treated with 3 ml/kg CCl₄ in olive oil alone showed significant reductions ($P < 0.05$) in GSH, SOD, CAT but an increase in levels of MDA when compared with olive oil treated rats. At 300 mg/kg, CPL showed significant ($P < 0.05$) increase in GSH (4.7 ± 0.6) compared with CCl₄ treated (1.52 ± 0.17), SOD (3.03 ± 3.17) compared with CCl₄ treated (1.65 ± 0.33)

and CAT (16.05 ± 1.65) also compared with CCl_4 treated rats (3.40 ± 0.81). The same trend was also observed for the fruit extract CPF with GSH compared with CCl_4 treated, SOD compared with CCl_4 treated and CAT compared with CCl_4 treated rats.

Effects of Leaf and Fruit Extracts of *C. papaya* L. on Serum Hepatic Enzymes in ACM-Induced Hepatotoxicity in Rats

The rats administered with 600 mg/kg, p.o. ACM showed significant ($P < 0.05$) increases in serum enzymes ALT, ALP, AST as well as DB when compared to rats who received no extracts. At 300 mg/kg CPL, serum liver markers were less expressed with ALT (53 ± 3.53), AST (15.25 ± 2.62), ALP (79.83 ± 26.40) and DB (1.60 ± 0.07). There was also significant ($P < 0.05$) reduction in serum enzymes in animals treated with the highest dose (300 mg/kg) of CPF with ALT (52.25 ± 5.26), AST (18.0 ± 2.34), ALP (50.41 ± 11.42) and DB (1.47 ± 0.16) compared to the control. There was no significant difference ($P > 0.05$) between rats treated with N-acetyl cysteine and the rats who received no extracts [Table 1].

Effects of Leaf and Fruit Extracts of *C. papaya* L. on Serum Antioxidant Enzymes in ACM-Induced Hepatotoxicity in Rats

ACM at 600 mg/kg, caused significant ($P < 0.05$) reduction in the levels of GSH, CAT, and SOD, but increases in MDA when compared with the rats who received no extracts. However, there was no significant difference ($P > 0.05$) in serum oxidative markers in groups treated with plant extracts of *C. papaya* CPL and CPF. However, at 300 mg/kg CPL, there was a slight

increase in SOD (3.33 ± 0.13) and CAT (10.78 ± 0.57). These slight elevations were, however, lower compared with the N-acetyl cysteine-treated group with GSH (0.52 ± 0.05), SOD (2.32 ± 0.13) and CAT (10.06 ± 0.56) [Table 2].

Effects of Leaf and Fruit Extracts of *C. papaya* L. on Liver Antioxidant Enzymes in ACM-Induced Hepatotoxicity in Rats

ACM at 600 mg/kg, p.o., significantly ($P < 0.05$) decreased organ levels of GSH, SOD, CAT as well as increased MDA in treated rats compared with the rats who received no extracts. N-acetylcysteine and CPL and CPF, both at 100 mg/kg and 300 mg/kg reversed this effect significantly ($P < 0.05$). There was, however, no significant difference ($P > 0.05$) between N-acetylcysteine-treated rats and the rats who received no extracts. However, the N-acetyl cysteine-treated group showed slightly higher values of both GSH (9.71 ± 1.12) and CAT (14.70 ± 4.07) compared with those treated with plant extracts CPL and CPF at all doses [Table 3].

Histology

The histology results revealed the hepatoprotective effect of the liver architecture at all doses in comparison with control (CCl_4) [Figure 6 and Table 4].

DISCUSSION

ACM, a common OTC drug, widely used for its analgesic and antipyretic purposes is a common cause of acute hepatocellular damage which could be lethal if not treated. It is one of the common causes of poisoning worldwide [27]. Oxidative necrosis

Table 1: Effects of leaf and fruit extracts of *C. papaya* on serum hepatic enzymes in ACM-induced hepatotoxicity in rats

Treatment	ALT (U/L)	AST (U/L)	ALP (U/L)	Uric acid ($\mu\text{mol/L}$)	DB ($\mu\text{mol/L}$)
PEG	54.25 ± 3.09	18.00 ± 2.61	48.54 ± 12.37	202.00 ± 15.08	1.37 ± 0.22
600 mg/kg ACM	82.50 ± 4.97^b	31.5 ± 1.32^b	87.34 ± 2.52^b	186.20 ± 15.31^b	24.90 ± 7.44^b
100 mg/kg CPL+ACM	60 ± 10.29	17.7 ± 1.43	68.22 ± 6.90	173.60 ± 7.94	1.82 ± 0.37
300 mg/kg CPL+ACM	53.00 ± 3.53^a	15.25 ± 2.62^a	79.83 ± 26.46^a	131.30 ± 27.28^a	1.60 ± 0.07^a
100 mg/kg CPF+ACM	56.00 ± 7.14^a	17.75 ± 1.10^a	58.56 ± 4.9^a	120.30 ± 21.15^a	1.25 ± 0.20^a
300 mg/kg CPF+ACM	52.25 ± 5.26^a	18.00 ± 2.34^a	50.41 ± 11.42^a	126.20 ± 17.64^a	1.47 ± 0.16^a
3 ml/kg NAC	54.00 ± 3.87^a	17.00 ± 3.18^a	67.00 ± 12.58^a	120.30 ± 9.62^a	1.47 ± 0.22^a

Values are expressed as mean \pm SEM ($n=6$); ($^aP < 0.05$) versus ACM, ($^bP < 0.05$) versus PEG, (one-way ANOVA followed by Dunnett's post hoc multiple comparison tests), SEM: Standard error of mean, PEG: Polyethylene glycol, ACM: Acetaminophen, CPL: *Carica papaya* leaf, CPF: *Carica papaya* fruit, ALP: Alkaline phosphatase, ALT: Alanine aminotransferase, AST: Aspartate aminotransferase, DB: Direct bilirubin, *C. papaya*: *Carica papaya*

Table 2: Effects of leaf and fruit extracts of *C. papaya* on serum antioxidant enzymes in ACM-induced hepatotoxicity in rats

Treatment	GSH (U/mg protein)	SOD (U/mg protein)	CAT (U/mg protein)	MDA (U/mg protein)
PEG	0.57 ± 0.05	3.22 ± 0.27	16.03 ± 2.01	0.02 ± 0.00
600 mg/kg ACM	0.10 ± 0.03^b	1.4 ± 0.12^b	4.2 ± 0.00^b	0.09 ± 0.00^b
100 mg/kg CPL+ACM	0.34 ± 0.06^a	2.38 ± 0.23^a	10.51 ± 0.99^a	0.047 ± 0.01^a
300 mg/kg CPL+ACM	0.10 ± 0.07^a	1.43 ± 0.12^a	4.29 ± 0.35^a	0.09 ± 0.00^{aa}
100 mg/kg CPF+ACM	0.28 ± 0.08	3.33 ± 0.13	10.78 ± 0.57	0.03 ± 0.00
300 mg/kg CPF+ACM	0.17 ± 0.02^a	1.93 ± 0.00^a	7.02 ± 0.24^a	0.02 ± 0.00^a
3 ml/kg NAC	0.52 ± 0.05^a	2.32 ± 0.13^a	10.06 ± 0.56^a	0.03 ± 0.00^a

Data are expressed as mean \pm SEM ($n=6$); ($^aP < 0.05$) versus ACM, ($^bP < 0.05$) versus PEG, (One Way ANOVA followed by Dunnett's post hoc multiple comparison tests), SEM: Standard error of mean, PEG: Polyethylene glycol, ACM: Acetaminophen, CPL: *Carica papaya* leaf, CPF: *Carica papaya* fruit, CAT: Catalase, SOD: Superoxide dismutase, MDA: Malondialdehyde, GSH: Glutathione, *C. papaya*: *Carica papaya*

Table 3: Effects of leaf and fruit extract of *C. papaya* on liver antioxidant enzymes in ACM-induced hepatotoxicity in rats

Treatment	GSH (U/mg protein)	SOD (U/mg protein)	CAT (U/mg protein)	MDA (U/mg protein)
PEG	10.31±1.26	7.07±1.72	18.96±0.05	0.05±0.02
600 mg/kg ACM	1.98±0.16 ^b	0.86±0.40 ^b	11.50±0.85 ^b	0.16±0.85 ^b
100 mg/kg CPL+ACM	3.00±0.49 ^a	2.28±0.61 ^a	13.71±2.75 ^a	0.11±0.03 ^{a,b}
300 mg/kg+ACM	5.17±1.26 ^a	3.32±0.80 ^a	15.83±2.57	3.11±1.52
100 mg/kg CPF+ACM	4.14±0.73 ^a	3.03±0.41 ^a	11.58±2.20	0.09±0.01 ^{a,b}
300 mg/kg CPF+ACM	4.76±0.14	3.877±0.50	19.48±2.40 ^b	0.08±0.01
3 ml/kg NAC	9.71±1.12 ^a	6.3±14.70 ^a	14.70±4.07 ^a	0.05±0.016 ^a

Values are expressed as mean±SEM (n=6); (^aP<0.05) versus ACM, (^bP<0.05) versus PEG, one-way ANOVA followed by Dunnet's post hoc multiple comparison tests, SEM: Standard error of mean, PEG: Polyethylene glycol, ACM: Acetaminophen, CPL: *Carica papaya* leaf, CPF: *Carica papaya* fruit, CAT: Catalase, SOD: Superoxide dismutase, MDA: Malondialdehyde, GSH: Glutathione, *C. papaya*: *Carica papaya*

Table 4: Histological presentations of the liver

Olive oil, 10 mL/kg	CCl ₄ , 3 mL/kg	CPL, 300 mg/kg+ CCl ₄ 3 mL/kg	CPF, 300 mg/kg+ CCl ₄ , 3 mL/kg
Normal	Congested vascular channels, fatty lesions and necrotic formation	Mild necrosis	Normal
ACM, 600 mg/kg	NAC	ACM, 600 mg/kg+ CPL, 300 mg/kg	ACM, 600 mg/kg+ CPF, 300 mg/kg
Fatty lesions and necrotic formation	Normal	Mild necrosis	Normal

ACM: Acetaminophen, CPL: *Carica papaya* leaf, CPF: *Carica papaya* fruit, CCl₄: Carbon tetrachloride

and depletion of liver stores of GSH have been implicated in the mechanism of action of ACM poisoning [27-29].

It is important, therefore, to evaluate plant extracts that can be used for the improved treatment of hepatic failure caused by severe oxidative stress and necrosis [30,31]. A estimation of serum enzymes is a useful quantitative marker of the extent and type of hepatocellular damage. Increases in serum AST, ALT, ALP, and lactate dehydrogenase (LDH) levels have been attributed to damage of the structural integrity of the liver because these enzymes are cytoplasmic in location and are released into the circulation after autolytic breakdown or cellular necrosis. Marked release of AST, ALT, ALP, and LDH into the circulation indicates severe damage to hepatic tissue membranes during CCl₄ intoxication [32].

Tarkang *et al.* [33] reported the oral LD₅₀ of *C. papaya* aqueous leaf extract as >5 g/kg. Oduola *et al.* [34] had also reported the oral LD₅₀ of the unripe fruit extract of *C. papaya* to be 2.52 g/kg. This suggests that the extracts are safe on acute exposure. In this study, extracts of *C. papaya* (leaf and unripe fruits) decreased the serum level of hepatic biomarkers in rats pre-treated with CCl₄ compared to control animals administered CCl₄ alone, indicating the hepato-protective potential of the extracts. This is in agreement with the findings by Adeneye *et al.* [35].

In ACM toxicity, the metabolite NAPQI is known to deplete GSH levels, thereby inducing hepatic necrosis [36]. More so, oxidative stress and lipid peroxidation which are early events of free radical generation have been implicated in ACM metabolism [37]. Extracts of *C. papaya* (CPL and CPF) reversed the depletion of GSH, SOD, CAT induced by ACM toxicity

and significantly decreased CCl₄-induced elevation in levels of MDA compared to the control. It has been stated that SOD and CAT are the most important enzymes involved in ameliorating the effects of oxygen metabolism [38,39].

Treatment with the extracts led to significant increases in GSH, SOD and CAT compared to ACM treated rats. Current evidence suggests that intracellular GSH plays an essential role in ACM detoxification and in the prevention of ACM-induced toxicity in the liver and the kidney [40]. The effect of the raised antioxidant enzymes may be responsible for the prevention of tissue damage seen with the presentation of normal architecture in the liver of ACM treated rats. Treatment with *N*-acetyl cysteine, which is the standard for treating ACM toxicity [41,42] showed no significant difference compared to the extracts of *C. papaya* indicating the potential of the extracts (CPL and CPF) in conferring hepatoprotection against ACM toxicity.

Several medicinal plants have been found to inhibit xenobiotic-induced hepatotoxicity as well as nephrotoxicity due to their potent anti-oxidant or free radical scavenging effects [43,44]. The leaves of the pawpaw plant have been shown to contain many active components such as papain, chymopapain, cystatin, α -tocopherol, ascorbic acid, flavonoids, cyanogenic glucosides, and glucosinolates that can increase the total antioxidant power in blood and reduce lipid peroxidation level [45]. Furthermore, alkaloids have been reported to strongly inhibit lipid peroxidation induced in isolated tissues *in-vitro* via their antioxidant activity [46]. The leaves and unripe fruits of *C. papaya* have been found to contain saponins, tannins, flavonoids, cardiac glycosides, alkaloids and anthraquinones [47,48]. The protection offered by the extract may also be due to its high content of flavonoids, ascorbic acid and alkaloids contained in the extract which may account for the reducing and free radical scavenging properties of the extract. The liver protective activity elicited by the extract might be due to its ability to activate antioxidant enzymes suppressed by ACM-induced toxicity [49,50]. The results from this study indicate that extracts of *C. papaya* have hepatoprotective properties which could be harnessed in the treatment of the acute liver injury.

In CCl₄ toxicity, there was marked increase of hepatic enzymes; ALT, AST ALP and uric acid concentration as well as DB [51]. There is a link between hyperuricemia and some hepatic disorders. Serum uric acid level is significantly associated with

non-alcoholic fatty liver disease and elevated serum uric acid level has been shown to be an independent risk factor for non-alcoholic fatty liver disease [52-54]. Rats treated with CCl₄ showed significant increases in ALT, ALP and AST compared to control. The increased serum levels of hepatic biomarkers have been attributed to liver injury because these enzymes are found in the cytoplasmic area of the cell and are released into circulation in the event of cellular damage [55,56]. Zimmerman *et al.* [57] stated that CCl₄ induced the increase of serum ALT and AST levels as a result of cell membrane and mitochondrial damage in liver cells. Khan *et al.* [58], Wang *et al.* [59], Mehmetcik *et al.* [60], Arici and Cetin, [61] had all reported that these enzyme activities were significantly elevated after CCl₄ treatment.

Histological examination of liver tissue in rats treated with CCl₄ alone expressed hepatocellular necrosis, fatty cell accumulation, inflammatory cell infiltration and other manifestations that are consistent with acute liver damage. This is in agreement with the findings of Khan and Al-Zohairy [62]. Extracts of *C. papaya* significantly reversed the increased levels of liver biomarkers at 100 mg/kg and 300 mg/kg compared to animals treated with CCl₄ alone. This hepatoprotective effect, however, was not dose-dependent.

SOD, GSH, CAT were significantly decreased with MDA significantly increased in CCl₄ treated rats when compared with untreated animals. However, in rats treated with aqueous plant extracts of *C. papaya*, there was a significant increase in the levels of these antioxidant enzymes, especially in the liver. This effect is also in coherence with the findings by Wang *et al.* [59] and Slater [63]. The depletion of antioxidant enzymes is an indicator of liver damage in CCl₄ toxicity. Further examination of histological slides prepared from rats treated with CCl₄ confirmed hepatic damage with hepatocellular necrosis and inflammatory lesions compared to animals treated with extracts of *C. papaya* which were seen to be of remarkably less severity with regards to hepatocellular necrosis.

CONCLUSION

Decreased concentration of liver serum biomarkers such as ALP, ALT and AST and increased activities of various antioxidant enzymes indicates that the aqueous extracts of *C. papaya* Linn may be able to protect against drug and chemical induced acute liver pathologies through improvement of antioxidant indices. This may explain its use in traditional medicine for the treatment of hepato-biliary disorders. A further study is required to elucidate the fraction and constituents of the extract that produces this hepatoprotective effect.

REFERENCES

1. Nilesh M, Ozick LA, Gbadehan E. Drug-Induced Hepatotoxicity, 2012. Available from: <http://www.emedicine.medscape.com/article/169814-overview>.
2. Larrey D. Drug-induced liver diseases. *J Hepatol* 2000;32:77-88.
3. Biour M, Ben Salem C, Chazouillères O, Grangé JD, Serfaty L, Poupon R. Drug-induced liver injury; fourteenth updated edition of the bibliographic database of liver injuries and related drugs.

- Gastroenterol Clin Biol 2004;28:720-59.
4. Björnsson E. The natural history of drug-induced liver injury. *Semin Liver Dis* 2009;29:357-63.
5. Friedland SE, Grendell JH, McQuaid KR. In: *Current Diagnosis and Treatment in Gastroenterology*. New York: Lang Medical Books/McGraw Hill; 2003. p. 664-79.
6. Slater TF. Free-radical mechanisms in tissue injury. *Biochem J* 1984;222:1-15.
7. Charbonneau M, Brodeur J, du Souich P, Plaa GL. Correlation between acetone-potentiated CCl₄-induced liver injury and blood concentrations after inhalation or oral administration. *Toxicol Appl Pharmacol* 1986;84:286-94.
8. Ozturk F, Ucar M, Ozturk IC, Vardi N, Batcioglu K. Carbon tetrachloride-induced nephrotoxicity and protective effect of betaine in Sprague-Dawley rats. *Urology* 2003;62:353-6.
9. Chay-Prove P, Ross P, O'Hare P, Macleod N, Kernot I, Evans D, *et al.* Agrilink Series: Your Growing Guide to Better Farming. Nambour, Queensland: Queensland Horticulture Institute; 2000. p. 20-7.
10. Oduola T, Adeniyi AA, Ogunyemi EO, Bello IS, Idowu TO. Anti-sickling agent in an extract of unripe pawpaw (*Carica papaya* L.): Is it real? *Afr J Biotech* 2006;5:1947-9.
11. Gill LS. *Carica papaya* L. In: *Ethnomedical Uses of Plants in Nigeria*. Nigeria, Benin-City: Uniben Press; 1992. p. 155.
12. Olagunju JA, Adeneye AA, Fagbonyinka BS, Bisoga NA, Okekitu AO, Benebo AS, *et al.* Nephroprotective activities of aqueous seed extracts of *Carica papaya* L. in carbon tetrachloride injury in Wistar rats: A dose dependent study. *Biol Med* 2009;1:11-9.
13. Otsuki N, Dang NH, Kumagai E, Kondo A, Iwata S, Morimoto C. Aqueous extract of *Carica papaya* Leaves exhibits anti-tumor activity and immunomodulatory effects. *J Ethnopharmacol* 2010;127:760-7.
14. Guide for the Care and Use of Laboratory Animals, NIH Publication No. 85-23, Revised 1996.
15. Tietz NW, Rinker AD, Shaw LM. International Federation of Clinical Chemistry. IFCC methods for the measurement of catalytic concentration of enzymes. Part 5. IFCC method for alkaline phosphatase (orthophosphoric-monoester phosphohydrolase, alkaline optimum, EC 3.1.3.1). IFCC document stage 2, draft 1, 1983-03 with a view to an IFCC recommendation. *Clin Chim Acta* 1983;135:339-67.
16. Reitman S, Frankel SA. Colorimetric method for the determination of glutamic oxaloacetic and glutamic pyruvic transaminases. *Am J Clin Pathol* 1957;28:56-66.
17. Fawcett JK, Scott JE. A rapid and precise method for the determination of urea. *J Clin Pathol* 1960;13:156-9.
18. Malloy HT, Evelyn KA. The determination of bilirubin with the photoelectric colorimeter. *J Biol Chem* 1937;119:481-90.
19. Sedlak J, Lindsay RH. Estimation of total, protein-bound, and nonprotein sulfhydryl groups in tissue with Ellman's reagent. *Anal Biochem* 1968;25:192-205.
20. Sun M, Zigma S. An improved spectrophotometric assay of superoxide dismutase based on epinephrine antioxidation. *Anal Biochem* 1978;90:81-9.
21. Kakkar P, Das B, Viswanathan PN. A modified spectrophotometric assay of superoxide dismutase. *Indian J Biochem Biophys* 1984;21:130-2.
22. Usoh IF, Akpan EJ, Etim EO, Farombi EO. Antioxidant actions of dried flower extract of *Hibiscus sabdariffa* L. on sodium, arsenite-induced oxidative stress in rats. *Pak J Nutr* 2005;4:135-41.
23. Aksenes A, Njaa L. Determination of catalase activity in fish. *Comp Biochem Physiol* 1981;69:893-6.
24. Buege JA, Aust SD. Microsomal lipid peroxidation. *Methods Enzymol* 1978;52:302-10.
25. Aebi H. Catalase *in vitro*. In: Colowick SP, Kaplan NO, editors. *Methods Enzymol*. Vol. 105. New York: Academic Press; 1984. p. 121-6.
26. Baker J, Silverstone RE. *Introduction to Medical Laboratory Technology*. 6th ed. London: Butterworth and Co. Ltd.; 1985. p. 172-221.
27. Larson M, Polson J, Fontana J, Davern J, Lalani E, Hynan S, *et al.* Acute liver failure study group. Acetaminophen-induced acute liver failure: Results of a United States multicenter, prospective study. *Hepatology* 2005;42:1364-72.
28. Heard K. Acetylcysteine for acetaminophen poisoning. *N Engl J Med* 2008;359:285-92.

29. Corcoran GB, Ray SD. The role of the nucleus and other compartments in toxic cell death produced by alkylating hepatotoxicants. *Toxicol Appl Pharmacol* 1992;113:167-83.
30. Toklu HZ, Tunali Akbay T, Velioglu-Ogunc A, Ercan F, Gedik N, Keyer-Uysal M, et al. Silymarin, the antioxidant component of *Silybum marianum*, prevents sepsis-induced acute lung and brain injury. *J Surg Res* 2008;145:214-22.
31. Greenhough S, Hay DC. Stem cell-based toxicity screening: Recent advances in hepatocyte generation. *J Pharmacol Med* 2012;26:85-9.
32. Lin HM, Tseng HC, Wang CJ, Lin JJ, Lo CW, Chou FP. Hepatoprotective effects of *Solanum nigrum* Linn extract against CCl₄-induced oxidative damage in rats. *Chem Biol Interact* 2008;171:283-93.
33. Tarkang PA, Agbor GA, Armelle TD, Yamthe TL, David K, Ngadema YS. Acute and chronic toxicity studies of the aqueous and ethanol leaf extracts of *Carica papaya* Linn in Wistar rats. *J Nat Prod Plant Resour* 2012;2:617-27.
34. Oduola T, Adeniyi FA, Ogunyemi EO, Bello IS, Idowu TO, Subair HG. Toxicity studies on an unripe *Carica papaya* aqueous extract: Biochemical and haematological effects in wistar albino rats. *J Med Plants Res* 2007;1:1-4.
35. Adeneye AA, Olagunju JA, Benebo AS, Elias SO, Adisa AO, Idowu BO. Nephroprotective effects of the aqueous root extract of *Harungana madagascariensis* L. in acute and repeated dose acetaminophen renal injured rats. *Intl J Appl Res* 2008;1:6-14.
36. Mitchell JR, Jollow DJ, Potter WZ, Gillette JR, Brodie BB. Acetaminophen-induced hepatic necrosis. IV. Protective role of glutathione. *J Pharmacol Exp Ther* 1973;187:211-7.
37. Somani SM, Husain K, Whitworth C, Trammell GL, Malafa M, Rybak LP. Dose-dependent protection by lipoic acid against cisplatin-induced nephrotoxicity in rats: Antioxidant defense system. *Pharmacol Toxicol* 2000;86:234-41.
38. Pande M, Flora SJ. Lead induced oxidative damage and its response to combined administration of alpha-lipoic acid and succimers in rats. *Toxicology* 2002;177:187-96.
39. Linares V, Bellés M, Albina ML, Sirvent JJ, Sánchez DJ, Domingo JL. Assessment of the pro-oxidant activity of uranium in kidney and testis of rats. *Toxicol Lett* 2006;167:152-61.
40. Newton JF, Hoefle D, Gemborys MW, Mudge GH, Hook JB. Metabolism and excretion of a glutathione conjugate of acetaminophen in the isolated perfused rat kidney. *J Pharmacol Exp Ther* 1986;237:519-24.
41. Brok J, Buckley N, Gluud C. Interventions for paracetamol (acetaminophen) overdose. *Cochrane Database Syst Rev* 2006;CD003328.
42. Piperno E, Berssenbruegge DA. Reversal of experimental paracetamol toxicosis with N-acetylcysteine. *Lancet* 1976;2:738-9.
43. Devpriya S, Shyamaladevim CS. Protective effect of quercetin in cisplatin induced cell injury in the rat kidney. *Indian J Pharmacol* 1999;31:422-6.
44. Annie S, Rajagopal PL, Malini S. Effect of *Cassia auriculata* Linn. root extract on cisplatin and gentamicin-induced renal injury. *Phytomedicine* 2005;12:555-60.
45. Seigler DS, Pauli GF, Nahrstedt A, Leen R. Cyanogenic allosides and glucosides from *Passiflora edulis* and *Carica papaya*. *Phytochemistry* 2002;60:873-82.
46. Kumaran A, Karunnakaran RJ. *In vitro* antioxidant activities of methanol extract of *Phyllanthus amarus* species from India. *LWT-Swiss Soc Food Sci Tech* 2007;40:344-52.
47. Ikeyi AP, Ogbonna AO, Eze FU. Phytochemical analysis of paw-paw (*Carica papaya*) Leaves. *Int J Life Sci Bt Pharm Res* 2013;2:2250-3137.
48. Eke ON, Augustine AU, Ibrahim HF. Qualitative analysis of phytochemicals and antibacterial screening of extracts of *Carica papaya* fruits and seeds. *Int J Mod Chem* 2014;6:48-56.
49. Abdel-Zaher AO, Abdel-Rahman MM, Hafez MM, Omran FM. Role of nitric oxide and reduced glutathione in the protective effects of aminoguanidine, gadolinium chloride and oleanolic acid against acetaminophen-induced hepatic and renal damage. *Toxicology* 2007;234:124-34.
50. Ghosh T, Maity TK, Das M, Bose A, Dash DK. *In-vitro* antioxidant and hepatoprotective activity of ethanolic extract of *Bacopa monnieri* Linn. aerial parts. *Iran J Pharmacol Ther* 2007;6:77-85.
51. Althnaian T, Albokhadaim I, El-Bahr S. Biochemical and histopathological study in rats intoxicated with carbon tetrachloride and treated with camel milk. *Spring Open J Res* 2013;2:57.
52. Lee K. Relationship between uric acid and hepatic steatosis among Koreans. *Diabetes Metab* 2009;35:447-51.
53. Li Y, Xu C, Yu C, Xu L, Miao M. Association of serum uric acid level with non-alcoholic fatty liver disease: A cross-sectional study. *J Hepatol* 2009;50:1029-34.
54. Lee YJ, Lee HR, Lee JH, Shin YH, Shim JY. Association between serum uric acid and non-alcoholic fatty liver disease in Korean adults. *Clin Chem Lab Med* 2010;48:175-80.
55. Recknagel RO, Glende EA Jr, Dolak JA, Waller RL. Mechanisms of carbon tetrachloride toxicity. *Pharmacol Ther* 1989;43:139-54.
56. Brent JA, Rumack BH. Role of free radicals in toxic hepatic injury. II. Are free radicals the cause of toxin-induced liver injury? *J Toxicol Clin Toxicol* 1993;31:173-96.
57. Zimmerman HJ, Kodera Y, West M. Effects of carbon tetrachloride poisoning on the plasma levels of cytoplasmic and mitochondrial enzymes in animals with nutritional fatty metamorphosis. *J Lab Clin Med* 1965;66:324-33.
58. Khan MR, Rizvi W, Khan GN, Khan RA, Shaheen S. Carbon tetrachloride-induced nephrotoxicity in rats: Protective role of *Digera muricata*. *J Ethnopharmacol* 2009;122:91-9.
59. Wang PY, Kaneko T, Tsukada H. Time courses of hepatic injuries induced by chloroform and by carbon tetrachloride: Comparison of biochemical and histopathological changes. *Arch Toxicol* 1997;71:638-45.
60. Mehmetçik G, Ozdemirler G, Koçak-Toker N, Cevikbas U, Uysal M. Effect of pretreatment with artichoke extract on carbon tetrachloride-induced liver injury and oxidative stress. *Exp Toxicol Pathol* 2008;60:475-80.
61. Arici OF, Cetin N. Protective role of ghrelin against carbon tetrachloride (CCl₄)-induced coagulation disturbances in rats. *Regul Pept* 2011;166:139-42.
62. Khan AA, Alzohairy M. Hepatoprotective effects of camel milk against CCl₄-induced hepatotoxicity in rats. *Asian J Biochem* 2011;6:171-81.
63. Slater TF. Free radical mechanisms in tissue injury. *Ciba Foundation Symposium 65-Oxygen Free Radicals and Tissue Damage*; 2008. p. 9: DOI 10.1002/9780478047015413.

© SAGEYA. This is an open access article licensed under the terms of the Creative Commons Attribution Non-Commercial License (<http://creativecommons.org/licenses/by-nc/3.0/>) which permits unrestricted, noncommercial use, distribution and reproduction in any medium, provided the work is properly cited.

Source of Support: Nil, Conflict of Interest: None declared.