



## Original Article

# Reconstruction of the medial patellofemoral ligament using autologous graft from quadriceps tendon to treat recurrent patellar dislocation<sup>☆</sup>



Constantino Jorge Calapodopulos<sup>a,b</sup>, Marcelo Corvino Nogueira<sup>c,\*</sup>,  
José Martins Juliano Eustáquio<sup>b</sup>, Constantino Jorge Calapodopulos Júnior<sup>b</sup>,  
Oreston Alves Rodrigues<sup>a</sup>

<sup>a</sup> Department of Orthopedics and Traumatology, Universidade Federal do Triângulo Mineiro (UFTM), Uberaba, MG, Brazil

<sup>b</sup> Department of Orthopedics and Traumatology, Universidade de Uberaba (UNIUBE), Uberaba, MG, Brazil

<sup>c</sup> Hospital Regional de Sobradinho, Brasília, DF, Brazil

## ARTICLE INFO

## Article history:

Received 17 February 2014

Accepted 29 May 2015

Available online 6 February 2016

## Keywords:

Patellofemoral ligament

Quadriceps tendon

Patellar dislocation

## ABSTRACT

**Objective:** The objective of this study was to evaluate the efficacy of the surgical technique using the quadriceps tendon as a graft in static reconstruction of the medial patellofemoral ligament.

**Methods:** This was a prospective case series study in which the participants were 22 patients with a diagnosis of recurrent patellar dislocation without any other anatomical alterations that required surgical treatment. The functional results from the technique were evaluated using clinical data and the Lysholm questionnaire, one year after the operation.

**Results:** It was observed that the patients were predominantly female (86%) and under 21 years of age (73%), just like in the literature. At the first annual return after the surgery, there was no significant pain on medium efforts, no loss of range of motion and a positive apprehension test. According to the questionnaire used, the results were graded as good. The patients who reported having severe pain on greater effort were involved in employment-related legal disputes.

**Conclusion:** This technique showed low morbidity and good functional results over the short term.

© 2016 Sociedade Brasileira de Ortopedia e Traumatologia. Published by Elsevier Editora Ltda. All rights reserved.

<sup>☆</sup> Work performed at the Universidade Federal do Triângulo Mineiro (UFTM), Uberaba, MG, Brazil.

\* Corresponding author.

E-mail: [mcorvino.ort@gmail.com](mailto:mcorvino.ort@gmail.com) (M.C. Nogueira).

<http://dx.doi.org/10.1016/j.rboe.2016.01.012>

2255-4971/© 2016 Sociedade Brasileira de Ortopedia e Traumatologia. Published by Elsevier Editora Ltda. All rights reserved.

## Reconstrução do ligamento patelofemoral medial com enxerto autólogo do tendão quadricipital no tratamento da luxação recidivante da patela

### R E S U M O

#### Palavras chave:

Ligamento patelofemoral  
Tendão quadricipital  
Luxação patelar

**Objetivo:** Avaliar a eficácia de técnica cirúrgica que usa o tendão do quadríceps como enxerto na reconstrução estática do LPFM.

**Métodos:** Estudo de série de casos, prospectivo, do qual participaram 22 pacientes com o diagnóstico de luxação recidivante da patela, que não apresentavam outras alterações anatômicas que necessitassem de tratamento cirúrgico. Os resultados funcionais da técnica foram avaliados por meio de dados clínicos e do questionário de Lysholm, com um ano de pós-operatório.

**Resultados:** Observou-se predomínio de pacientes do sexo feminino (86%) e menores de 21 anos (73%), a exemplo do observado na literatura. No primeiro retorno anual após a cirurgia, não houve dor significativa aos médios esforços, perda de amplitude de movimento e positividade dos testes de apreensão. Segundo o questionário empregado, os resultados foram graduados como bons. Aqueles que informaram dor intensa aos maiores esforços apresentavam pendências trabalhistas.

**Conclusão:** A técnica apresentada mostrou, em curto prazo, baixa morbidade e bons resultados funcionais.

© 2016 Sociedade Brasileira de Ortopedia e Traumatologia. Publicado por Elsevier Editora Ltda. Todos os direitos reservados.

## Introduction

Acute dislocation of the patella is a common event, especially among adolescents and young adults, with higher rates among females.<sup>1</sup> It can be triggered by traumatic or non-traumatic events. In the latter cases, it is associated with significant anatomical alterations of the knee extensor mechanism. There is no consensus regarding the ideal treatment after the first occurrence of dislocation, mainly because only 30% of the patients present a new episode.<sup>2</sup> However, in cases of recurrent dislocation (two or more episodes), the treatment is essentially surgical and has the aim of correcting the predisposing factors. Among these, reconstruction of the medial patellofemoral ligament (MPFL) is considered to be the most important procedure,<sup>3</sup> especially after knee injury.

The MPFL acts as the main ligament restricting lateral displacement of the patella at knee flexion of between 0° and 30°. Because of its biomechanical properties, it is essential for controlling the normal kinematics of the patellofemoral joint.<sup>5</sup> During the first episode of traumatic patellar dislocation, this anatomical structure becomes partially or totally torn. This injury is considered to be an essential factor enabling development of recurrent dislocation.<sup>6</sup>

The first reports of this reconstruction were made by Sugamuna et al.,<sup>7</sup> in 1990, who used tendon autografts, and by Ellera Gomes, who used synthetic grafts.<sup>8</sup> In the literature, different surgical techniques have been described, with options for static and dynamic reconstruction, but none of them is considered to be the gold standard.<sup>9</sup>

Surgical procedures using a portion of the extensor mechanism as a graft in static reconstruction of the MPFL, through tendon transfer, as described by Camanho et al.<sup>10</sup> for the patellar tendon, and by Steensen et al.<sup>11</sup> for the quadriceps tendon, are easily reproducible and have low morbidity.

The objective of this study was to evaluate the short-term results from MPFL reconstruction in patients with recurrent patellar dislocation, by means of a technique using a fragment from the quadriceps tendon as a graft.

## Materials and methods

This was a prospective case series. The participants were 22 patients of both sexes who had a diagnosis of recurrent patellar dislocation. They underwent surgical treatment for MPFL reconstruction at Hospital de Clínicas, Federal University of the Triângulo Mineiro (UFMG), in Uberaba, Minas Gerais, between January 2008 and September 2013. The participants signed a free and informed consent statement.

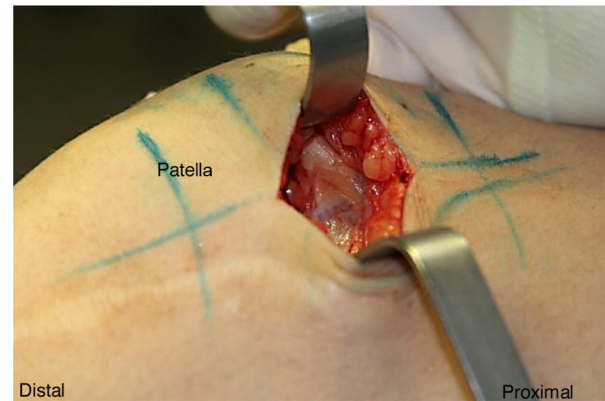
All the participants had presented a condition of first patellar dislocation consequent to an acute traumatic event and had undergone initial conservative treatment. However, they evolved with at least one recurrence and, because of this, surgical treatment was indicated. The same technique was used in all the operations. The patients were followed up after the operation by means of a clinical protocol consisting of outpatient return visits every 15 days over the first two months and monthly thereafter; and a preestablished physiotherapeutic protocol, as follows: first postoperative week: progressive partial weight-bearing with the aid of crutches, use of an immobilizer, isometric exercises for the quadriceps, analgesic measures and electrostimulation; third week: after removal of the immobilizer, progressive passive exercises to gain range of motion, initial proprioception exercises and closed kinetic chain exercises; sixth week: start of open kinetic chain exercises; tenth to twelfth week: patient was released to return to his/her previous activities. The minimum length of follow-up was 12 months.

**Table 1 – Lysholm questionnaire. Translation validated for the Portuguese language.**

<b>Claudication (5 points)</b>	<b>Pain (25 points)</b>
Never = 5	None = 25
Mild or periodic = 3	Mild or periodic during physical effort = 20
Severe and constant = 0	Greater pain during or after walking > 2 km = 10
	Grater pain during or after walking < 2 km = 5
	Constant = 0
<b>Weight-bearing (5 points)</b>	<b>Edema (10 points)</b>
None = 5	None = 10
With stick or crutch = 2	With heavy exercise = 6
Impossible = 0	With ordinary exercise = 3
	Constant = 0
<b>Locking (15 points)</b>	<b>Going up stairs (10 points)</b>
No locking or feeling of this = 15	No problem = 10
Feeling but without locking = 10	Slightly impaired = 6
Occasional = 6	One step at a time = 3
Frequent = 2	Impossible = 0
Joint locked during examination = 0	
<b>Instability (25 points)</b>	<b>Squatting (5 points)</b>
Never = 25	No problem = 5
Rarely during physical effort = 20	Slightly impaired = 4
Frequently during effort = 15	Not possible beyond 90 degrees = 2
Occasionally during daily activities = 10	Impossible = 0
Frequently during daily activities = 5	
At each step = 0	
<b>Total score:</b>	
Scoring: excellent: 95–100; good: 84–94; fair: 65–83; poor ≤64.	

The exclusion criteria for the study were defined after clinical evaluation, radiological evaluation (radiography, computed tomography and magnetic resonance imaging) and arthroscopic evaluation. The following patients were excluded: those with genu valgum, previous surgery in the same knee, abnormality of joint range of motion (ROM), Q angle greater than 20°, trochlear angle greater than 145°, TT-TG distance greater than 20 mm, high patella (greater than 1.2, as assessed using the Insall-Salvati index), patellar dysplasia of grade IV or V according to the Wiberg classification,<sup>12</sup> cartilaginous injury of grade III or IV according to the Outerbridge classification<sup>13</sup> and meniscal and/or ligament injuries with indications for repair or reconstruction.

One year after the operation, the patients were evaluated by means of clinical parameters (pain, ROM and patellar instability test) and through application of the Lysholm questionnaire, as validated for the Portuguese language<sup>14</sup> (Table 1). Their intensity of pain was investigated by means of a visual analog scale and was graded as mild (scores from 0 to 3), moderate (3 to 7) or severe (7 to 10).<sup>15</sup> ROM was investigated using a manual goniometer and instability, by means of the apprehension test. Assessments made by patients who were off work because of the surgical procedure were used as complementary data for this study.

**Fig. 1 – Surgical incision on the superomedial face of the patella, of approximately 50 mm.**

The data gathered were subsequently placed in an inventory in an electronic database, through validation by means of double data entry (typing). To analyze the results, descriptive statistical procedures were used.

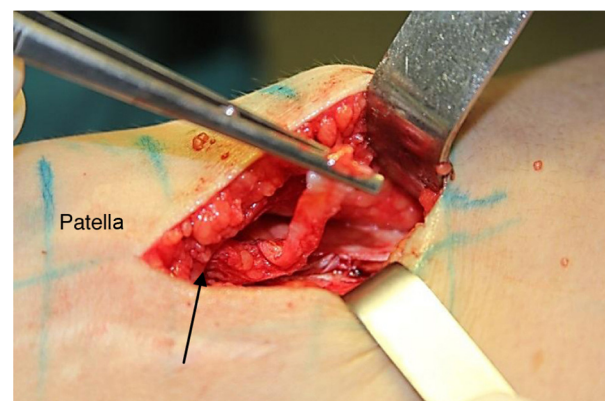
This study was approved by the Ethics Committee for Human Research of UFTM (protocol 2567/13).

### Surgical technique

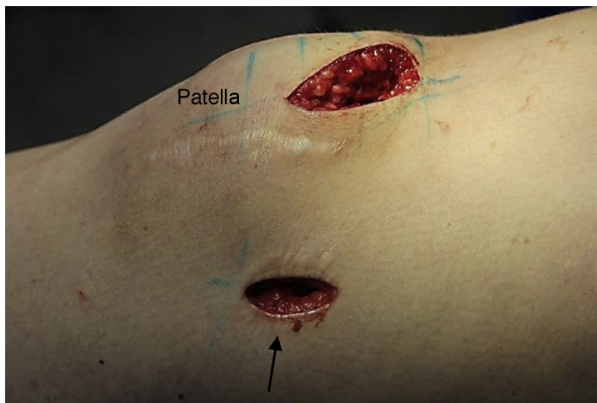The patients were positioned on a standard surgical table, in dorsal decubitus, and underwent spinal anesthesia. A pneumatic tourniquet was used routinely in this surgical procedure. Firstly, an inventory of the joint was performed by means of arthroscopy, in order to diagnose and treat any possible cartilage lesions.

A surgical incision was made at the level of the medial edge of the patella, 50 mm proximally to its upper edge, and this was continued distally until reaching the patellar level. Layer-by-layer dissection was performed down to the peritendon, which was incised vertically (Fig. 1).

The segment corresponding to the medial third of the quadriceps tendon, with a width of approximately 10 mm and length of 50 mm, was sectioned with preservation of the distal portion inserted in the patella (Fig. 2). The tendon segment

**Fig. 2 – The full thickness of the middle third of the tendon of the quadriceps (length of 10 mm) is sectioned while maintaining the distal insertion in the patella (arrow).**





**Fig. 3 – Incision on the medial face of the knee, of approximately 20 mm (arrow).**

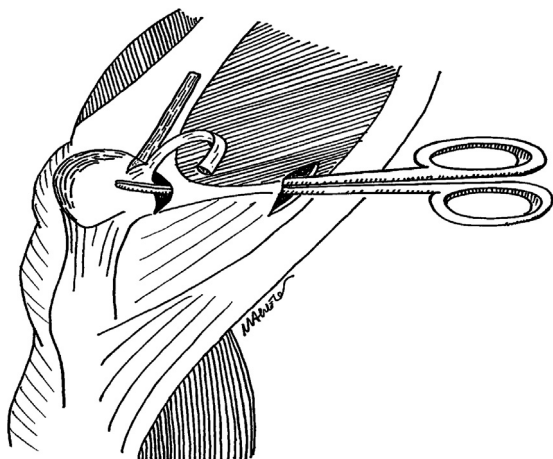
was prepared with suturing using absorbable thread (Vycril® 1.0mm) in anchored running stitches at its free end.

After graft preparation, the second stage of the procedure began. A vertical incision was made in the skin of the medial face of the knee, between the medial epicondyle and the tubercle of the adductor, of around 20mm in length (Fig. 3).

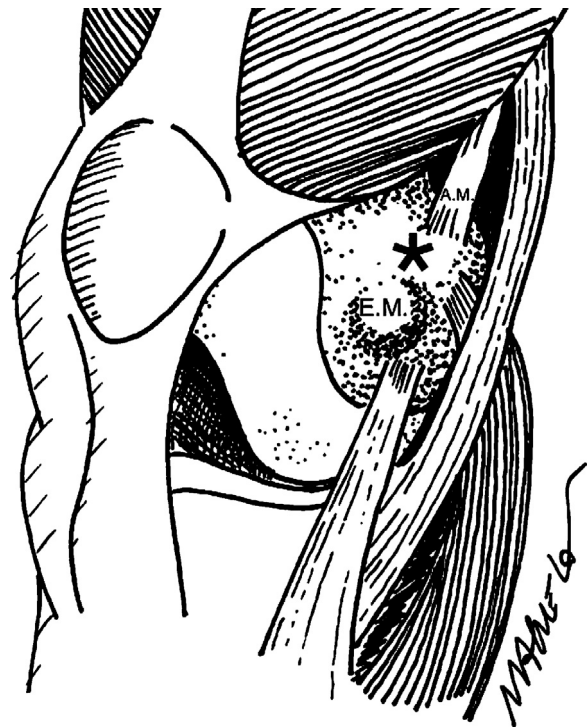
Since the intention was that the graft should pass along the normal anatomical path, from its origin to the point of fixation in the distal femur (Nomura's point),<sup>16</sup> through the second layer of Warren and Marshall,<sup>17</sup> an incision was made in the medial retinaculum and this layer was explored as far as the superomedial edge of the patella (Fig. 4).

The graft was passed into place medially and then needed to be fixed to the femur, at the point corresponding to its original insertion (Nomura's point). This was located with the aid of an image intensifying device (Fig. 5).

An anchor was inserted at this location (Fig. 6) and the graft was fixed while the knee was flexed at 30°, with the patella centered at the trochlea. After definitive fixation, the joint ROM and patellar stability over the knee flexion range of 0-30° were tested.



**Fig. 4 – Transfer of the graft to its fixation point on the distal femur, under the vastus medialis muscle.**

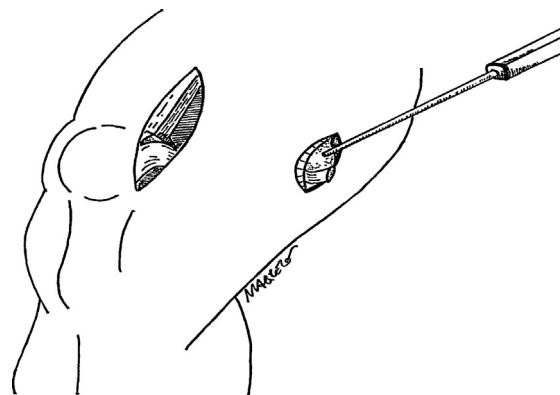


**Fig. 5 – \* Nomura's point: fixation of the medial patellofemoral ligament in the distal femur (ME = medial epicondyle, AM = insertion of the adductor magnus).**

**Results**

Twenty-two patients with a condition of current dislocation of the patella participated in this study. They were aged between 15 and 48 years and 73% were under the age of 21 years. Female patients predominated (86%) and the left leg was affected more frequently (59%). The worst scores from the Lysholm questionnaire were among the older participants (Table 2). The mean length of postoperative follow-up was 30 months, with a range from 12 to 52 months. There were no complications relating to the surgical wound.

Based on the questionnaire used, 59% of the patients presented good or excellent results, 27.2% fair results and 13.8%



**Fig. 6 – Fixation of the graft in the distal femur, with the aid of an anchor.**

**Table 2 – Characterization of the study sample, according to sex (M = male, F = female), age, side affected (R = right, L = left), employment-law issues (Y = yes, N = no) and scoring from the Lysholm questionnaire.**

Patient	Sex	Age	Side	Employment-law issues	Limping	Weight-bearing	Locking	Instability	Pain	Swelling	Going up stairs	Squatting	TOTAL SCORE
1	F	16	L	N	5	5	10	25	20	10	10	4	89
2	F	18	R	N	3	5	15	25	20	10	10	4	92
3	F	15	R	N	5	5	10	20	20	6	6	2	74
4	F	21	R	N	3	5	15	20	20	6	10	4	83
5	M	21	L	N	5	5	15	25	20	10	10	5	95
6	F	20	L	N	5	5	20	20	25	6	4	5	80
7	F	21	L	N	5	5	15	20	25	10	10	5	95
8	F	18	R	N	5	5	10	25	20	10	3	4	82
9	F	19	L	N	5	5	10	20	20	10	10	4	84
10	F	39	L	Y	5	5	10	15	10	3	6	2	56
11	F	19	R	N	5	5	15	25	25	10	10	4	99
12	F	40	L	Y	5	5	6	25	10	0	3	2	56
13	M	19	L	N	5	5	10	25	20	10	10	5	90
14	F	28	R	N	5	5	15	25	25	10	10	5	100
15	F	18	L	N	5	5	15	25	25	10	10	2	97
16	F	26	R	N	3	5	15	25	20	10	10	5	93
17	F	18	R	N	5	5	10	25	20	10	3	2	80
18	F	28	L	N	3	5	15	20	20	6	10	4	83
19	F	48	L	Y	5	5	10	15	10	3	6	4	58
20	F	20	R	N	5	5	15	25	25	10	10	2	97
21	M	19	L	N	5	5	15	20	20	10	10	4	89
22	F	17	L	N	5	5	10	25	20	10	10	5	90

**Table 3 – Results from patient's scores in the Lysholm questionnaire.**

Lysholm score	Number of patients	% of the patients
Excellent	06	27.2
Good	07	31.8
Regular	06	27.2
Poor	03	13.8

poor results (Table 3). All the participants who classified their results as poor reported that they experienced severe pain in the patellofemoral joint on making major effort. However, they had employment-law issues during the period evaluated. The final mean score for the questionnaire was 84.6, which was graded as a good result.

In the clinical evaluation one year after the operation, none of the patients said that they had any moderate or severe pain upon making medium effort involving the patellofemoral joint or the location of insertion of the anchor in the distal femur, as shown by the visual analog scale. There was no deficit of joint ROM and all the patients had negative results from the apprehension test. In 16 cases in which an evaluation at least 30 months after the operation was possible, the clinical results, the clinical results remained similar.

## Discussion

Independent of the etiology of recurrent dislocation of the patella, this is a pathological condition that mostly affects young adults and women,<sup>1</sup> as also observed in the present study. Both in post-traumatic and in non-traumatic cases in which conservative treatment is chosen, instability generally becomes recurrent and in most cases, anatomical alterations associated with tearing of the MPFL are seen. A previous randomized prospective study in which patients with traumatic dislocation of the patella were evaluated showed that the results were better after surgical treatment than after conservative treatment.<sup>18</sup>

The participants in the present study did not present any anatomical alterations with indications for complementary orthopedic procedures that have been developed for treating recurrent dislocation of the patella.<sup>19</sup> Most of these techniques have the aim of realigning the extensor mechanism and reducing the lateralization of the patella when the quadriceps is put into action. Distal realignment procedures (for cases with TT-TG distances greater than 20 mm or cases of high patella) consist of medialization and/or distalization of the anterior tibial tuberosity. Proximal realignment procedures depend on quadriceps contraction to keep the patella in the trochlear groove. Both of these have shown limited clinical results. However, intact passive stabilizers such as the MPFL have an important role independent of the misalignment, with results that are more effective than those from proximal or distal realignment procedures.<sup>20</sup>

The MPFL contributes approximately 50–70% of the restriction on lateral translation of the patella. Thus, it is the most important stabilizer of the patella and its reconstruction is the primary procedure in cases of recurrent luxation.<sup>20</sup> Several surgical techniques have been described, with different types

of grafts (artificial ligament, patellar tendon, quadriceps tendon or flexor tendons) and fixation methods (bone tunnel in the patella and screw in the femur; suturing in the patella and Endobutton in the femur; and anchor in the patella and screw in the femur, among others).<sup>21</sup> Recent systematic reviews have shown that reconstruction of the MPFL is an effective procedure with a low rate of recurrence of patellar instability and good functional and subjective results, independent of the surgical technique.<sup>22</sup>

The method using the quadriceps tendon as the graft is common among surgical procedures on the knee. It presents the advantages that the graft is easily obtained, no bone tunnels are needed and, because the patellar bone insertion is maintained, there is more economical use of surgical fixation materials. However, it also presents variations regarding the thickness of the graft (partial or total), the tendon segment used and the path followed between the superomedial surface of the patella and the medial femoral condyle (subcutaneous or below the vastus medialis muscle).<sup>11,23</sup>

The technique described here, in which a graft from the full thickness of the middle third of the quadriceps tendon was used, presented satisfactory efficacy, with a result that was classified as good according to the score from the Lysholm questionnaire. As described here, it enables the surgery to be less aggressive and, because of the anatomical path used and because only one extremity is kept free, adequate functionality for performing routine activities is ensured. This questionnaire was chosen because of its reliability for knee ligament injuries and because it contains the item "instability", which is important for evaluating the results from a surgical technique for ligament reconstruction.

In relation to the clinical results one year after the operation, no diminution of joint range of motion or positive apprehension tests was observed. None of the patients said that they had any moderate or severe pain in the region of the patellofemoral joint at rest or upon making medium effort. Among the patients who continued to be followed up, the good results were maintained. In 13.8% of the cases, the patients reported experiencing greater pain during more intensive effort (such as walking for more than 2 km). However, these participants, who were the oldest participants in the study, had employment-law issues and therefore probably wished to obtain some form of secondary advantage through the disease.

The homogenous population obtained for this study, without the presence of severe femoropatellar dysplasia or associated lesions, makes the results more reliable. There is a need for long follow-up of these patients, since some complications may only have emerged after the period studied. Pain consequent to joint degeneration can be highlighted among these, caused by increased medial retroapatellar force. Given the low morbidity and the results that were observed over the short term, this technique can be qualified as a good option for MPFL reconstruction surgery.

## Conclusion

Reconstruction of the medial patellofemoral ligament using an autologous graft from the quadriceps tendon is an easily

reproducible technique, with low morbidity, which presents good short-term results for treating recurrent dislocation of the patella.

### Conflicts of interest

The authors declare no conflicts of interest.

### REFERENCES

- Fithian DC, Paxton EW, Stone ML, Silva P, Davis DK, Elias DA, et al. Epidemiology and natural history of acute patellar dislocation. *Am J Sports Med.* 2004;32(5):1114-21.
- Stefancin JJ, Parker RD. First-time traumatic patellar dislocation: a systematic review. *Clin Orthop Relat Res.* 2007;455:93-101.
- Smith TO, Walker J, Russell N. Outcomes of medial patellofemoral ligament reconstruction for patellar instability: a systematic review. *Knee Surg Sports Traumatol Arthrosc.* 2007;15(11):1301-14.
- Zaffagnini S, Colle F, Lopomo N, Sharma B, Bignozzi S, Dejour D, et al. The influence of medial patellofemoral ligament on patellofemoral joint kinematics and patellar stability. *Knee Surg Sports Traumatol Arthrosc.* 2013;21(9):2164-71.
- Smirk C, Morris H. The anatomy and reconstruction of the medial patellofemoral ligament. *Knee.* 2003;10(3):221-7.
- Elias DA, White LM, Fithian DC. Acute lateral patellar dislocation at MR imaging: injury patterns of medial patellar soft-tissue restraints and osteochondral injuries of the inferomedial patella. *Radiology.* 2002;225(3):736-43.
- Sugamuna J, Mitani T, Suzuki N, Tezuka M, Iseki F, Fujikawa K, et al. Reconstruction of the medial patellofemoral ligament. *J Tokyo Knee Soc.* 1990;10:137-48.
- Ellera Gomes JL. Medial patellofemoral ligament reconstruction for recurrent dislocation of the patella: a preliminary report. *Arthroscopy.* 1992;8(3):335-40.
- Shah JN, Howard JS, Flanigan DC, Brophy RH, Carey JL, Lattermann C. A systematic review of complications and failures associated with medial patellofemoral ligament reconstruction for recurrent patellar dislocation. *Am J Sports Med.* 2012;40(8):1916-23.
- Camanho GL, Bitar AC, Hernandez AJ, Olivi R. Medial patellofemoral ligament reconstruction: a novel technique using the patellar ligament. *Arthroscopy.* 2007;23(1), 108.e1-4.
- Steensen RN, Dopirak RM, Maurus PB. A simple technique for reconstruction of the medial patellofemoral ligament using a quadriceps tendon graft. *Arthroscopy.* 2005;21(3): 365-70.
- Wiberg G. Roentgenographic and anatomic studies on the patellofemoral joint with special reference to chondromalacia patellar. *Acta Orthop Scand.* 1941;12:319-410.
- Outerbridge RE. The etiology of chondromalacia patellae. *J Bone Joint Surg Br.* 1961;43:752-7.
- Peccin MS, Ciconelli R, Cohen M. Questionário específico para sintomas do joelho Lysholm Knee Scoring Scale – tradução e validação para a língua portuguesa. *Acta Ortop Bras.* 2006;14(5):268-72.
- Anand KJ, Craig KD. New perspectives on the definition of pain. *Pain.* 1996;67(1):3-6.
- Nomura E, Inoue M, Osada N. Anatomical analysis of the medial patellofemoral ligament of the knee, especially the femoral attachment. *Knee Surg Sports Traumatol Arthrosc.* 2005;13(7):510-5.
- Warren LF, Marshall JL. The supporting structures and layers on the medial side of the knee: an anatomical analysis. *J Bone Joint Surg Am.* 1979;61(1):56-62.
- Bitar AC, D'Elia CO, Demange MK, Viegas AC, Camanho GL. Estudo prospectivo randomizado sobre a luxação traumática de patela: tratamento conservador versus reconstrução do ligamento femoropatelar medial com tendão patelar – mínimo de dois anos de seguimento. *Rev Bras Ortop.* 2011;46(6):675-83.
- Aglietti P, Buzzi R, De Biase P, Giron F. Surgical treatment of recurrent dislocation of the patella. *Clin Orthop Relat Res.* 1994;308:8-17.
- Schöttle PB, Fucentese SF, Romero J. Clinical and radiological outcome of medial patellofemoral ligament reconstruction with a semitendinosus autograft for patella instability. *Knee Surg Sports Traumatol Arthrosc.* 2005;13(7): 516-21.
- Gonçalves MJB, Carvalho Júnior LH, Soares LFM, Gonçalves TJ, Santos RL, Pereira ML. Reconstrução do ligamento patelofemoral medial para tratamento da luxação recidivante da patela. *Rev Bras Ortop.* 2011;46(2):160-4.
- Fisher B, Nyland J, Brand E, Curtin B. Medial patellofemoral ligament reconstruction for recurrent patellar dislocation: a systematic review including rehabilitation and return-to-sports efficacy. *Arthroscopy.* 2010;26(10): 1384-94.
- Noyes FR, Albright JC. Reconstruction of the medial patellofemoral ligament with autologous quadriceps tendon. *Arthroscopy.* 2006;22(8):904.e1-7.