

## Unusual vascular ring in infant with pulmonary atresia and ventricular septal defect

ROXANE MCKAY, JAROSLAV STARK, MARC DE LEVAL

*From the Thoracic Unit, The Hospital for Sick Children, Great Ormond Street, London*

**SUMMARY** A 3-day-old infant investigated for cyanotic heart disease was found to have partial DiGeorge syndrome and pulmonary atresia with ventricular septal defect. The only source of pulmonary blood flow was a right-sided persistent ductus arteriosus which originated from an aberrant right subclavian artery. Such a vascular ring has not been described previously. Surgical treatment included a left-sided prosthetic shunt in infancy followed by resection of the ligamentum arteriosum and right subclavian artery during the second year of life.

A left aortic arch with aberrant right subclavian artery and right ductus arteriosus is a rare form of complete vascular ring. Only cases in which there was also a retro-oesophageal and right descending thoracic aorta, with the ductus arising from the dorsal aortic root, have been recorded in the English publications.<sup>1,2</sup> The patient presented here is unique in that the descending aorta was on the left and the persistent ductus arteriosus originated from the aberrant subclavian artery itself. The association of this anomaly with pulmonary atresia, ventricular septal defect, and partial DiGeorge syndrome created special problems in surgical management.

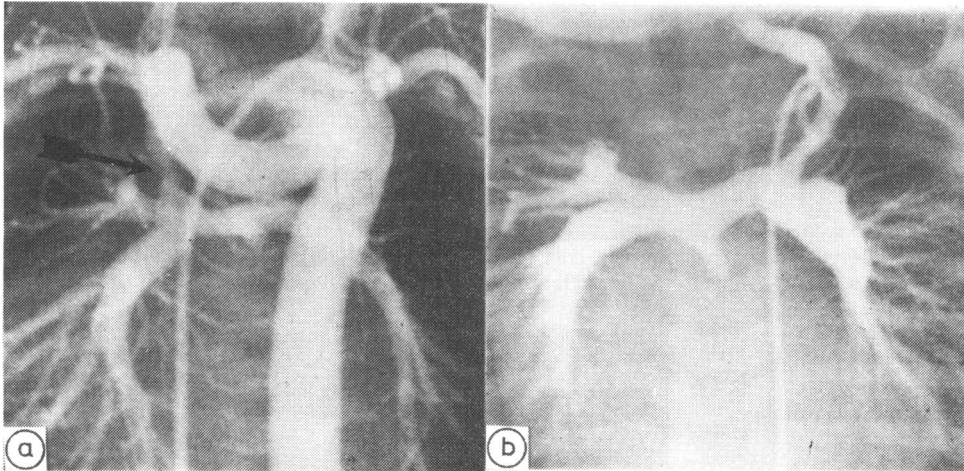
### Case report

A male infant, 3.2 kg, was transferred at 3 days of age for investigation of increasing cyanosis. Pregnancy and delivery had been uncomplicated, and he first became "dusky" with tachypnoea seven hours after birth. On physical examination, the baby had odd facies, with pointed ears, widely spaced eyes, and down-turned mouth. Moderate central cyanosis, a soft systolic murmur along the left sternal edge, and a single second heart sound were noted. No murmur was heard along the right sternal edge. Relevant laboratory investigations included an arterial PO<sub>2</sub> of 32 mmHg in room air, a serum calcium of 1.58 nmol/l, and the absence of thymic shadow on chest x-ray film.

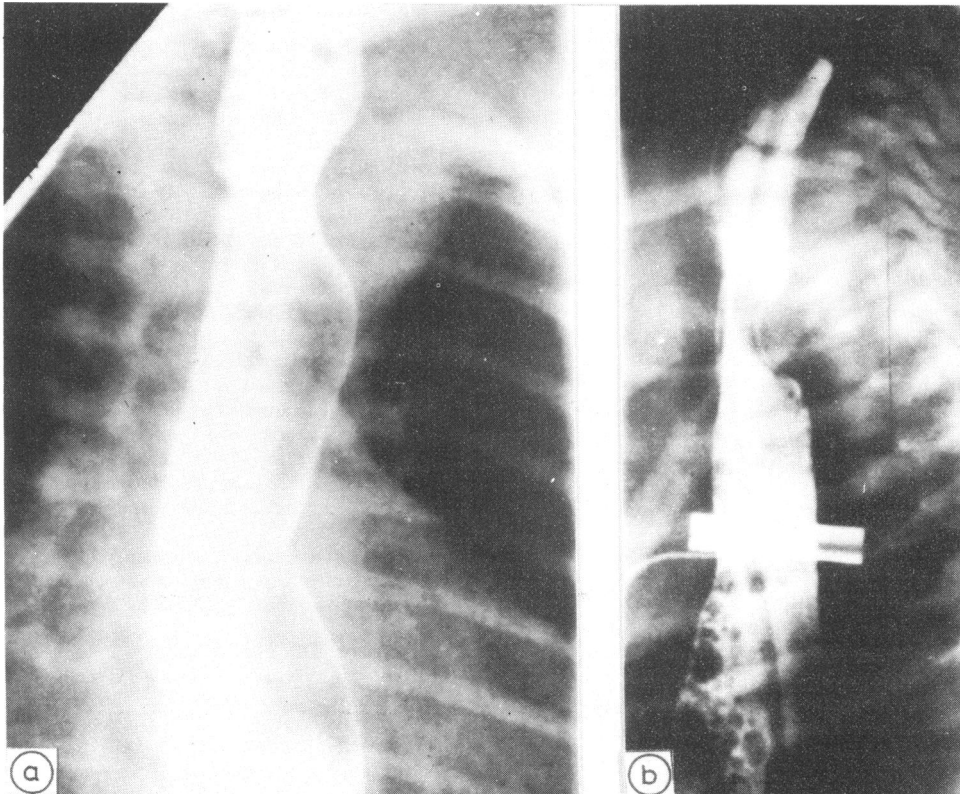
Cardiac catheterisation showed pulmonary atresia with a ventricular septal defect, left aortic arch, and an aberrant right subclavian artery. The sole blood supply to the lungs came from a right-sided persistent

ductus arteriosus arising from the aberrant subclavian artery (Fig. 1a). With patency of the ductus maintained by an infusion of prostaglandin E<sub>1</sub> at 0.1 µg/kg per min, a modified Blalock-Taussig shunt<sup>3</sup> was constructed the following day, using a 6 mm Gore-Tex conduit between the left subclavian and left pulmonary arteries. Postoperative recovery was haemodynamically satisfactory but complicated by multiple episodes of twitching, necrotising enterocolitis, and monilia infection. Investigation of the patient's hypocalcaemia subsequently disclosed low levels of parathormone on three occasions (70-140 ng/l; normal = 130-380 ng/l). Thymic dependent lymphocytes, however, were present and appeared to have normal function. A diagnosis of partial DiGeorge syndrome<sup>4</sup> was made, and the child was eventually dismissed from hospital at 3 months of age. Mild congestive heart failure was controlled by digoxin, and serum calcium levels maintained by dihydrotachysterol. The latter was discontinued after one year without recurrence of hypocalcaemia.

A poor feeder throughout infancy, the baby suffered progressive dysphagia and was unable to take solid food at 14 months of age. Reinvestigation of his cardiovascular status at that time showed that the ductus arteriosus had closed and the shunt was patent (Fig. 1b). Systemic arterial saturation was 74%. On barium swallow, the oesophagus was compressed laterally and posteriorly, consistent with a vascular ring formed by the left aortic arch, aberrant right subclavian artery, and the right ligamentum arteriosum (Fig. 2). The patient subsequently underwent division of the ligamentum arteriosum and aberrant right subclavian artery through a right thoracotomy with



**Fig. 1** Aortogram at 3 days of age (a) and selective injection into the origin of the left subclavian artery 14 months later (b). The catheter shows the position of the ascending aorta in the first investigation, with contrast opacifying the distal arch, the aberrant right subclavian artery, and the descending aorta. Confluent pulmonary arteries are supplied by a right-sided persistent ductus arteriosus which is stenosed at its mid-portion (arrow).



**Fig. 2.** Barium swallow in oblique (a) and lateral (b) projections showing compression of the oesophagus by the vascular ring.

complete relief of his feeding problems. At 3½ years of age, he now awaits correction of his pulmonary atresia and ventricular septal defect.

### Discussion

Anomalies of the aortic arch are encountered not infrequently in palliative surgery for cyanotic congenital heart disease. Among 841 patients explored with a view to systemic-pulmonary anastomosis, Bahnson and Blalock observed 40 vascular rings, including 36 instances of retro-oesophageal subclavian artery.<sup>5</sup> The aberrant subclavian artery on either side can be used to perform a satisfactory Blalock-Taussig anastomosis, and the resulting complete vascular ring has not caused symptoms of tracheal or oesophageal compression.<sup>6,7</sup> When the anomaly is a double aortic arch, using the smaller arch for the shunt achieves simultaneous palliation of cyanosis and division of the vascular ring.<sup>8,9</sup> In our patient, however, the pulmonary blood supply depended upon the integrity of the vascular ring, and the presence of a right-sided ductus precluded a Blalock-Taussig shunt on the side opposite to the aortic arch. With knowledge of the arch anatomy from preoperative angiography, it was possible to plan the initial prosthetic shunt on the side of the aortic arch, and this permitted subsequent interruption of the vascular ring when it became symptomatic.

Embryologically, this anomaly can be explained by persistence of the right sixth arch as the ductus arteriosus and the right eighth dorsal aortic root as the aberrant subclavian artery, with regression of the left sixth arch and the right fourth arch.<sup>10</sup> Factors that determine the side of the descending aorta are unknown but, it is of interest in this case, where the aorta remained on the left, that the retro-oesophageal portion of the subclavian artery was considerably larger than normal (Fig. 1a). Since the patient also had pulmonary atresia, it seems unlikely that the large segment resulted from preferential blood flow during development. Developmental anomalies of the third and fourth pharyngeal pouches are often associated with those of aortic arch derivatives, but this is thought to represent a response to a common teratogenic factor rather than a causal relation.<sup>11</sup>

The likelihood of compression symptoms occurring from this vascular anomaly is difficult to estimate. Among 14 patients reported with left aortic arch, right descending aorta, and right ligamentum arteriosum half suffered respiratory distress or feeding problems in infancy.<sup>12,13</sup> Associated cardiac anomalies were common, but none required palliative surgery, and the vascular ring was treated on its own merits.<sup>2,14</sup> In each case, the ligamentum or ductus arteriosus was divided through a right thoracotomy

rather than through the left-sided exposure used for most vascular rings.

Congenital heart disease as a presentation of the DiGeorge syndrome is well recognised and should be suspected in any infant with craniofacial stigmata and anomalies of the aortic arch.<sup>11,15</sup> The twitching episodes caused by hypocalcaemia in this patient were of little consequence; but sudden death during cardiac catheterisation or after correction of acidosis with alkali has been attributed to arrhythmias secondary to exacerbated hypocalcaemia.<sup>4</sup> In the partial DiGeorge syndrome, patients may have considerable cell-mediated immunity and, despite profound hypocalcaemia in infancy, achieve remission permanently during early childhood. Since survival of such patients has now been seen into the third decade,<sup>16</sup> aggressive treatment of the cardiovascular anomalies appears to be justified.

### References

- 1 Edwards JE. Retro-oesophageal segment of the left aortic arch, right ligamentum arteriosum and right descending aorta causing a congenital vascular ring about the trachea and esophagus. *Proceedings of the Staff Meetings of the Mayo Clinic* 1948; 23: 108-16.
- 2 Park SC, Siewers RD, Neches WH, Lenox CC, Zuberhuhler JR. Left aortic arch with right descending aorta and right ligamentum arteriosum. A rare form of vascular ring. *J Thorac Cardiovasc Surg* 1976; 71: 779-84.
- 3 deLeval MR, McKay R, Jones M, Stark J, Macartney FJ. Modified Blalock-Taussig shunt: use of the subclavian artery orifice as flow regulator in prosthetic systemic-pulmonary artery shunts. *J Thorac Cardiovasc Surg* 1981; 81: 112-9.
- 4 Conley ME, Beckwith JB, Mancor JFK, Tenckhoff L. The spectrum of DiGeorge syndrome. *J Pediatr* 1979; 94: 883-90.
- 5 Bahnson HT, Blalock A. Aortic vascular rings encountered in the surgical treatment of congenital pulmonic stenosis. *Ann Surg* 1950; 131: 356-62.
- 6 Blalock A. Surgical procedures employed and anatomical variations encountered in the treatment of congenital pulmonic stenosis. *Surg Gynecol Obstet* 1948; 87: 385-409.
- 7 Arciniegas E, Hakimi M, Hertzler JH, Farooki ZQ, Green EW. Surgical management of congenital vascular rings. *J Thorac Cardiovasc Surg* 1979; 77: 721-7.
- 8 Binet JP, Carpentier J, Pottemain M, Langlois J. Double aortic arch associated with tetralogy of Fallot in infants. Report of two cases. *J Thorac Cardiovasc Surg* 1966; 51: 116-8.
- 9 Waterston DJ, Pohl V, Kallfelz HC, Kreutzberg B. Shuntoperationen bei Fallotscher Tetralogie mit doppeltem Aortenbogen. *Dtsch Med Wochenschr* 1971; 96: 1191-5.
- 10 Stewart JR, Kincaid OW, Edwards JE. Left aortic arch: aberrant right subclavian artery and right ductus arteriosus (subgroup II B2). In: *An atlas of vascular rings and related malformations of the aortic arch system*. Springfield, Illinois: Charles C Thomas, 1964: 70.

- 11 Freedom RM, Rosen FS, Nadas AS. Congenital cardiovascular disease and anomalies of the third and fourth pharyngeal pouch. *Circulation* 1972; **46**: 165-72.
- 12 Ergin MA, Jayaram N, LaCorte M. Left aortic arch and right descending aorta: diagnostic and therapeutic implications of a rare type of vascular ring. *Ann Thorac Surg* 1981; **31**: 82-5.
- 13 Berman W Jr, Yabek SM, Dillon T, Neal JF, Aki B, Burstein J. Vascular ring due to left aortic arch and right descending aorta. *Circulation* 1981; **63**: 458-60.
- 14 Baumstark AE, Gordon DH, Haller JO, Martin EC. The left aortic arch and right descending aorta. *Br J Radiol* 1977; **50**: 788-92.
- 15 Moerman P, Goddeeris P, Lauwerijns J, Van Der Hauwaert LG. Cardiovascular malformations in DiGeorge syndrome (congenital absence or hypoplasia of the thymus). *Br Heart J* 1980; **44**: 452-9.
- 16 Miller MJ, Frame B. Partial DiGeorge syndrome or branchial dysembryogenesis? (letter). *Am J Dis Child* 1976; **130**: 1376-7.

Requests for reprints to Dr Roxane McKay, Milber Cottage, Manor Road, Seer Green, Beaconsfield, Buckinghamshire HP9 2QU.