

Atrioventricular discordance

Cross-sectional echocardiographic – morphological correlative study

GEORGE R SUTHERLAND,* JEFFREY F SMALLHORN,† ROBERT H ANDERSON,‡
MICHAEL L RIGBY, STEWART HUNTER

From the Regional Cardiothoracic Unit, Freeman Hospital, Newcastle upon Tyne; the Department of Paediatric Cardiology, The Hospital for Sick Children, Great Ormond Street, London; and the Cardiothoracic Institute, Brompton Hospital, London

SUMMARY Forty-nine patients with atrioventricular discordance were studied using cross-sectional echocardiography. The atrial arrangement was consistently predicted by echocardiographic analysis of either the patterns of pulmonary and systemic venous drainage or the arrangement of the great vessels within the upper abdomen. The ventricular arrangement was consistently predicted by direct identification of ventricular morphology. In hearts with two atrioventricular valves (47 patients) this was best derived by determining the pattern of implantation of the valve chordae to the ventricular myocardium. This proved to be more reliable in identifying ventricular morphology than either the analysis of trabecular patterns or the identification of valve leaflet morphology. In hearts with a common atrioventricular valve (two patients) ventricular arrangement had to be determined by identifying ventricular trabecular patterns.

Reversed implantation of the atrioventricular valve septal leaflets into the atrioventricular junction (previously reported as a constant feature of atrioventricular discordance) was present in only 12 patients, all of whom had an intact atrioventricular septum. In the remaining 37 patients a large perimembranous (subpulmonary) ventricular septal defect extended into the inlet part of the septum and produced a common level of insertion of the atrioventricular valve septal leaflets into the atrioventricular junction.

In terms of the ventriculoarterial connections, ventriculoarterial discordance was found in 36 patients, single outlet with pulmonary atresia in seven patients, and double outlet right ventricle in the remaining six. Abnormalities of the atrioventricular valves and the ventricular outflow tracts were also reliably identified. The echocardiographic findings were subsequently correlated with information derived from a study of similar necropsy material.

We conclude that, by using sequential segmental analysis, cross-sectional echocardiography will consistently identify atrioventricular discordance and its spectrum of associated lesions in even the most complex hearts.

Atrioventricular discordance is the specific atrioventricular connection in which each atrial chamber is connected to a morphologically inappropriate ventricle. This definition excludes hearts which may have

much in common with atrioventricular discordance, but in which the atrial chambers are isomeric ("situated ambiguously", "visceral heterotaxy", "splenic syndrome"). When the atrial chambers are isomeric then, irrespective of ventricular position and architecture, one ventricle must be connected to a morphologically appropriate atrium. In addition, excluded from this definition of atrioventricular discordance are hearts in which the atrial chambers connect to only one ventricle (double inlet ventricle or absent atrioventricular

*Present address: Southampton General Hospital, Southampton.

†Department of Paediatric Cardiology, Toronto Children's Hospital, Toronto, Canada.

‡R H Anderson is supported by the Joseph Levy Foundation together with the British Heart Foundation.

connection). Though often resembling atrioventricular discordance in terms of ventricular relations, the hearts with univentricular atrioventricular connection pose different problems to both the diagnostician and the surgeon.

In present day clinical practice it is essential to diagnose atrioventricular discordance and distinguish it from these other entities. Cross-sectional echocardiography is at its best in analysis of the atrioventricular junction and should provide the ideal tool in this respect. Recent investigations have shown its value in the non-invasive diagnosis of atrioventricular discordance.^{1,2} These studies, however, were restricted to patients having the combination of atrioventricular discordance with ventriculoarterial discordance—so-called congenitally corrected transposition. Though this is the commonest variant of atrioventricular discordance it is only part of the pathological spectrum encountered with this lesion. Indeed, the atrioventricular connection can exist with any ventriculoarterial connection. Here we review our experience in its diagnosis with several of the possible ventriculoarterial connections, and with both usually arranged (solitus) and mirror image (inversus) atrial chambers.

Patients and methods

Forty-nine patients with atrioventricular discordance were studied using cross-sectional echocardiography. The echocardiograms were recorded using either a Toshiba phased array sector scanner (2.4 MHz) or an Advanced Technology Laboratories mechanical sector scanner (3.0 or 5.0 MHz). The patients' ages ranged from 1 day to 19 years with the majority between the ages of 1 week and 10 years. All patients attended either the Regional Cardiothoracic Unit, Freeman Hospital, Newcastle; The Hospital for Sick Children, Great Ormond Street, London; or the Brompton Hospital, London. Comparative morphological studies were carried out by pathological sectioning of necropsied hearts with atrioventricular discordance drawn from the cardiopathological collections of the above three centres.

All 49 patients studied had correlative haemodynamic and angiocardigraphic information available from cardiac catheterisation. The wide spectrum of morphological abnormalities encountered in these 49 hearts is shown in Table 1. Forty-seven patients had usually arranged atrial chambers ("situs

Table 1 Atrioventricular discordance—a cross-sectional echocardiographic study

Abnormalities of atrial arrangement and cardiac position		No.
Atrial arrangement	Normal 47 pts	
Cardiac position	Inverted 2 pts	
	Normal 47 pts: Right chest 8 pts, Left chest 39 pts Inverted 2 pts: Right chest 2 pts, Left chest 0 pts	
Abnormalities of atrioventricular valves		No.
Common atrioventricular valve	"Classical" Ebstein's malformation	2
Morphological tricuspid valve	(TV with annular displacement into morphological RV)	3
	Dilated TV ring with large redundant TV leaflets (no annular displacement)	8
	Hypoplastic TV	2
	Minor chordal straddling	2
	No abnormality	
Morphological mitral valve		
Abnormalities of ventricular septum		Pts.
	Perimembranous ventricular septal defect (involving inlet, trabecular and outlet components of the muscular septum)	37
	Trabecular ventricular septal defect	2
	Intact interventricular septum	10
Abnormalities of ventricular arrangement		
	Side-by-side ventricles with vertical septal orientation	45
	Superior - inferior ventricular relation	3
	Criss-cross heart	1
Abnormalities of ventricular outflow tracts		
	Inadequate visualisation of left ventricular outflow tract	10
	Pulmonary atresia	10
	Subpulmonary obstruction ± valvar stenosis	23
	No subpulmonary obstruction	6
	Subaortic obstruction	0
Abnormalities of ventriculoarterial connections		
	Ventriculoarterial discordance	36
	Double outlet right ventricle (3 with imperforate pulmonary valve)	6
	Single outlet with pulmonary atresia	7

solitus"). Of these, 39 had left-sided and 8 had right-sided hearts. Two patients had mirror-image atrial chambers (situs inversus), both with the hearts in the right chest. Patients found to have isomeric atrial chambers were excluded, since atrioventricular discordance cannot by definition exist in this setting. In the 49 patients studied, the mode of atrioventricular communication was by two discrete atrioventricular valve orifices in 47 patients and via a common atrioventricular valve in the remaining two patients. The ventriculoarterial connections were discordant in 36 patients, double outlet right ventricle in six patients (three with imperforate pulmonary valves), and solitary aortic trunk with pulmonary atresia in seven patients.

Patients were studied either retrospectively or prospectively. Thirty-seven patients were known from previous angiocardiology to have atrioventricular discordance. These patients were recalled for echocardiography and the study was made without detailed knowledge of the associated morphological abnormalities. In the remaining 12 patients (all infants) the diagnosis of atrioventricular discordance was first made during the initial echocardiographic examination and was later confirmed at angiocardiology.

A standard echocardiographic procedure of examination was adhered to throughout the study. The transducer was first placed in the subcostal position and turned to cut the upper abdomen in a transverse section at approximately the level of the tenth thoracic vertebra. The precise relation of the inferior vena cava and descending aorta to each other and to the spinal body was noted.³ The transducer was then turned through 180° to produce a longitudinal section of these structures. A slight angulation of the transducer to the right in patients with usually positioned atrial chambers (solitus) will normally visualise the inferior vena cava in its long axis. This plane should be scanned to determine two important features: firstly, whether the suprarenal portion of the inferior vena cava continues to connect normally to the right atrium, and, secondly, whether the hepatic veins drain normally to the inferior vena cava. Having identified the morphology and spatial arrangement of the great vessels within the abdomen, the heart was then scanned from the subcostal, apical, and parasternal windows.⁴ From each transducer position long axis and short axis planes were scanned, the long axis planes being recorded both at right angles (four chamber) and parallel to the inlet part of the ventricular septum. The information derived from these planes using the scanning technique together with information from oblique planes was integrated to build up a comprehensive picture of the cardiac morphology. We found it important to take multiple

"step-wise" short axis sections throughout the heart beginning from the apex and ending at the great vessel roots to determine the ventriculoarterial connections and spatial relations. The echocardiographic examination was completed in all instances with a suprasternal scan. This approach was especially valuable in identifying the anatomy and spatial relations of the arch, ascending aorta, and pulmonary artery together with the ductus (if present). All patients subsequently had a high kilovoltage filtered beam radiograph to determine bronchial morphology and confirm the atrial arrangement.⁵

Results

(1) IDENTIFICATION OF ATRIAL ARRANGEMENT
Ideally, echocardiographic identification of the atrial arrangement (atrial situs) should be based on the visualisation of features intrinsic to the atria no matter how deformed they are—the so-called morphological method.^{6,7} For the atria this means identifying and distinguishing both the right and left atrial appendages and their junction with the smooth walled atrial components. Though this is morphologically feasible, in this study we were unable reliably to differentiate between right and left atria using cross-sectional echocardiography. In all cases studied, however, we were able to identify two discrete atrial chambers separated by an atrial septum. In every case pulmonary veins were visualised connecting to one of these atrial chambers (thus presumed to be the left atrium—Fig. 1a), with systemic veins connecting to the second atrium (thus presumed to be the right atrium—Fig. 1b). Atrial arrangement predicted by this indirect method (47 usual; two mirror-image) proved to be correct in every case when compared with the results of bronchial morphology derived from both filter film radiography⁵ and ultrasonography of the abdominal great vessels.³

(2) IDENTIFICATION OF VENTRICULAR CHAMBERS

The possible presence of a univentricular atrioventricular connection was first excluded by showing that each atrium was connected to a discrete ventricular chamber and that, when one of the atrioventricular valves was overriding, the degree of override was less than 50% (the 50% rule⁸). This information was derived by scanning the four chamber cuts from both the subcostal and precordial positions.

Several echocardiographic criteria for determining ventricular morphology were then examined so as to determine their accuracy in predicting morphology and hence the ventricular arrangement. They were, firstly, the level of attachment of the atrioventricular valve septal leaflets to the atrioventricular septum;

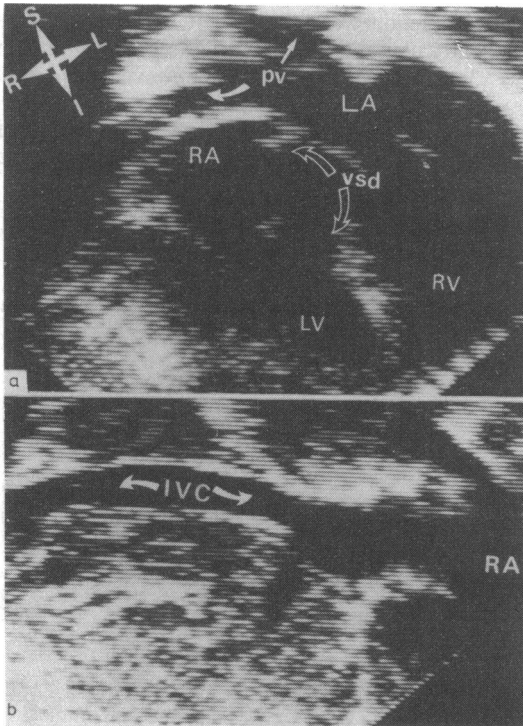


Fig. 1(a) A subcostal four chamber cut in a patient with atrioventricular discordance and a perimembranous inlet septal defect. Two discrete atrial chambers are visualised. Pulmonary veins are seen to drain to the left sided atrial chamber. (b) A subcostal long axis section of the upper abdomen in the same patient. A morphologically normal inferior vena cava is identified draining to the right sided chamber. The combined information derived from these two figures effectively identifies a normal (solitus) atrial arrangement. IVC, inferior vena cava; RA, right atrium; LA, left atrium; pv, pulmonary vein; RV, right ventricle; LV, left ventricle; vsd, ventricular septal defect. These abbreviations will be adhered to in subsequent figures. Where new abbreviations are used they will be explained under the appropriate figure legend.

secondly, the leaflet morphology of the inlet valve; thirdly, the morphology of the chordae and papillary muscles which form the subvalve tension apparatus; fourthly, the presence or absence of chordal attach-

ments to inlet septum or lateral ventricular free wall; fifthly, the trabecular pattern of the ventricular apical component (including the presence or absence of a moderator band); sixthly, the ventricular shape; and, finally, the presence or absence of fibrous continuity between the atrioventricular and arterial valve rings.

In the "typical" morphologically left ventricle the septal leaflet of the mitral valve is attached to the atrioventricular septum at a more basal position than the corresponding tricuspid septal leaflet; the mitral valve is a bileaflet structure which has a characteristic fishmouth appearance in short axis sectioning; the subvalvar apparatus consists of short chordae which are implanted into paired papillary muscles which in turn insert into the lateral portion of the ventricular free wall; the ventricle is ovoid in shape and has a fine apical trabecular architecture and in addition there is atrioventricular-arterial valve fibrous continuity.

The "typical" morphologically right ventricle has a more apical implantation of the tricuspid valve septal leaflet to the atrioventricular septum; a trileaflet opening pattern of the tricuspid valve when visualised in the subcostal short axis cut; a subvalve apparatus consisting of a prominent anterior apical papillary muscle and a small medial muscle with chordal attachments to the inlet septum and no chordal attachments to the lateral ventricular surface; a characteristically triangular shape with coarse apical trabecular architecture crossed by the moderator band and atrioventricular-arterial valve discontinuity.

Table 2 shows the reliability of cross-sectional echocardiography in identifying each of these features and thus distinguishing between the ventricles.

The most reliable predictor of ventricular morphology proved to be the manner in which the atrioventricular valve chordae implanted into the ventricular myocardium. In the 47 cases with two discrete atrioventricular valves the morphologically right ventricle had an inlet valve which had at least one chordal attachment to the inlet septum and the morphologically left ventricle had an inlet valve whose chordae implanted only onto the lateral ventricular wall (Fig. 2a). The morphologically mitral valve never showed chordal implantation onto the inlet septum. These

Table 2 Atrioventricular discordance—a cross-sectional echocardiographic study: reliability of individual echocardiographic features as predictors of ventricular morphology (47 pts with two atrioventricular valves)

Echocardiographic appearance	Morphological LV	vs	Morphological RV
Bileaflet inlet valve	47		18
Trileaflet inlet valve	0		29
Inlet valve chordae implanting into septum	0		47
Inlet valve paired chordae implanting into free wall	47		0
Moderator band	0		37
Coarse ventricular trabeculation	16		23
Smooth ventricular trabeculation	21		9

Note: Ventricular shape was not a reliable indicator of ventricular morphology.

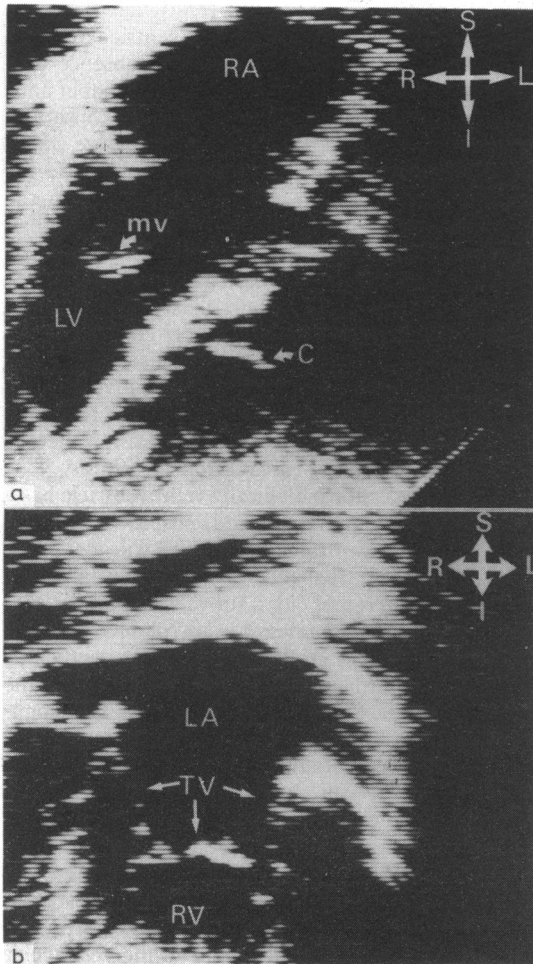


Fig. 2(a) A subcostal four chamber cut in atrioventricular discordance with intact ventricular septum. Note the inlet septal attachment of the chordae of the left sided atrioventricular valve. This identifies this valve as a tricuspid valve and the ventricle as a right ventricle. The chordae of the right sided valve insert onto the lateral ventricular wall identifying this as a mitral valve. mv, mitral valve; C, chordae (for remaining abbreviations see Fig. 1). (b) The subcostal short axis cut (in the same patient) showing the characteristic trileaflet opening pattern unique to the tricuspid valve and hence confirming the diagnosis of atrioventricular discordance. (This opening pattern is never visualised when studying the mitral valve.) TV, tricuspid valve. (For remaining abbreviations see Fig. 1.)

criteria could not be used in the two patients with a common atrioventricular valve as chordal implantation is so variable in this lesion. In these patients ventricular morphology has to be derived from identification of trabecular patterns.

Reversal of the normal pattern of insertion of the atrioventricular valve septal leaflets into the atrioven-

tricular junction was a consistent finding when the atrioventricular and inlet muscular septae were intact (Fig. 3a and b). In 37 patients, however, all with a large perimembranous inlet ventricular septal defect, the atrioventricular valve septal leaflets were attached to the central fibrous body at a common level with the

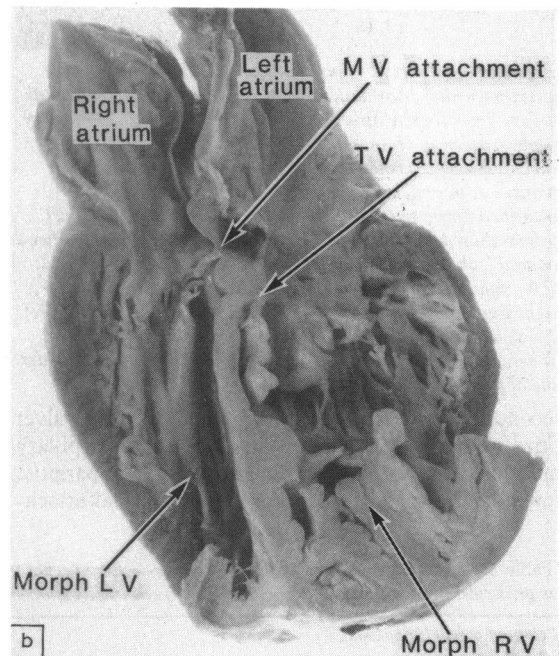
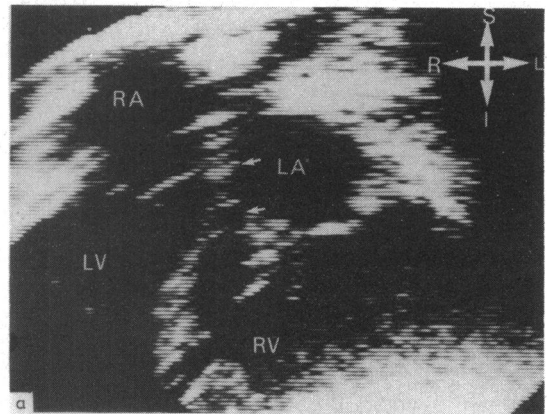


Fig. 3(a) Atrioventricular discordance with intact ventricular septum. The reversal of the normal pattern of implantation of atrioventricular valve septal leaflets (arrowed) into the atrioventricular junction is pathognomonic of this malformation. (b) The corresponding pathological specimen, sectioned in the same four chamber cut, accurately mirrors the above echocardiographic appearances. (For abbreviations see Fig. 1.)

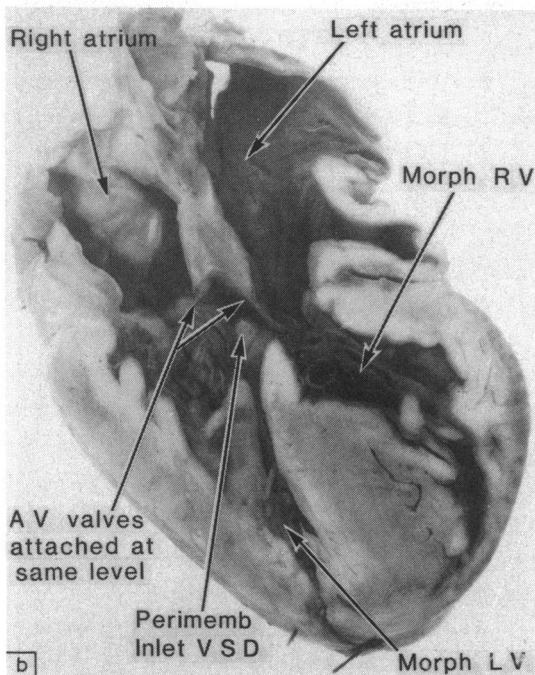
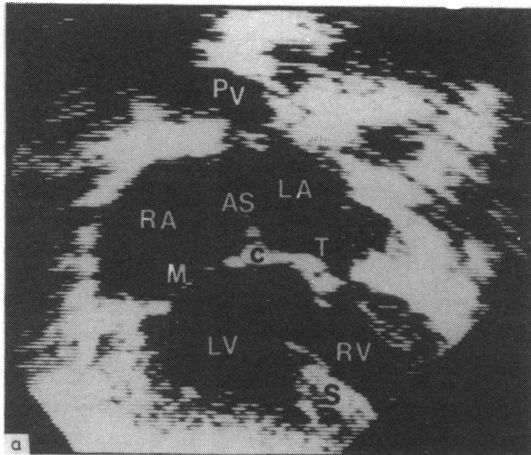


Fig. 4(a) Atrioventricular discordance with a large perimembranous inlet septal defect. A subcostal four chamber cut. Note the common level of attachment of the atrioventricular valve septal leaflets to the central fibrous body. This is a consistent finding where this combination of lesions is present. c, central fibrous body. (b) Atrioventricular discordance with a large perimembranous inlet septal defect (arrowed). A pathological specimen sectioned in a four chamber cut. Note the common level of implantation of the valve septal leaflets. (For abbreviations see Fig. 1.)

central fibrous body roofing the defect (Fig. 4a and b). This excavation of the atrioventricular septum by a perimembranous inlet defect has been previously

reported in hearts with atrioventricular concordance and is a pathognomonic feature of a perimembranous inlet defect.⁹

Other features were less reliable in identifying ventricular morphology. Direct identification of atrioventricular valve leaflet morphology was not a reliable method of determining the ventricular morphology. Using a series of precordial short axis cuts the morphological mitral valve was consistently visualised as a bileaflet structure in all 47 patients with two discrete atrioventricular valves. In 29 of these patients, using a subcostal short axis cut, the second atrioventricular valve was clearly visualised as having a trileaflet opening pattern (Fig. 2b) and hence was identified as a morphological tricuspid valve. In the remaining 18 patients the morphological tricuspid valve had a bileaflet opening pattern. Where observed, a moderator band immediately identified a ventricular chamber as being of morphologically right type.

The features described above were present irrespective of the ventricular relations or the ventriculoarterial connections.

The left-sided atrium was thus shown to connect to a morphologically right ventricle in all cases with usually arranged atrial chambers (atrial solitus) and to a morphologically left ventricle in the two cases with mirror-image atria (atrial inversus). The ventricular architecture was always as expected for the discordant connection, that is left hand pattern ("I" loop) with usually positioned atria and right hand pattern ("d" loop) with mirror-image atria.

The long axis cuts parallel to the inlet septum were particularly helpful in the cases with discordant ventriculoarterial connections but of less value in determining ventricular morphology with other arterial connections (see below).

(3) VENTRICULAR RELATIONS

In the majority of patients the relations were as anticipated for atrioventricular discordance, that is the morphologically right ventricle to the left with usually arranged atria (Fig. 5) and to the right with mirror-image atria. In four cases, however, the ventricular apical trabecular and outlet components either twisted around one another ("criss-cross" heart, one case) or else the septum was tilted to a horizontal position ("superoinferior" ventricles, three cases) (Fig. 6). Though they increased the complexity of the echocardiographic study these rotational abnormalities in no way prevented the diagnosis of the discordant atrioventricular connection.

(4) VENTRICULOARTERIAL CONNECTIONS

In all cases it was possible unequivocally to identify the ventriculoarterial connection present, as shown in Table 1. Combinations of all echocardiographic

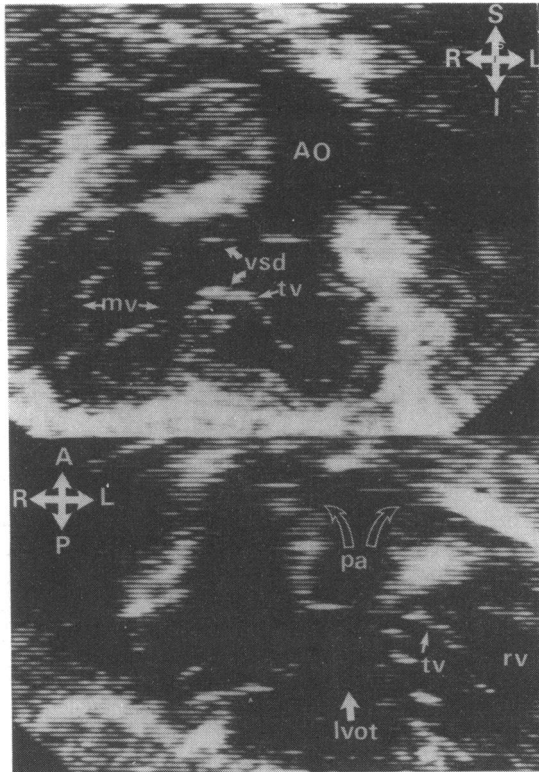


Fig. 5 Atrioventricular discordance with a large perimembranous inlet defect. The subcostal approach often provides the most information when assessing such hearts, as shown in these two Figures. Upper panel—subcostal four chamber cut. The ventricles are seen to be in a side by side relation with the septum lying in the characteristic anteroposterior plane. A large perimembranous defect is visualised. The chordae of the left sided atrioventricular valve (tricuspid) clearly implant into the crest of the trabecular septum which the right inlet valve chordae implant into the free wall of the right sided ventricle. The aorta is clearly visualised arising from the morphological right ventricle. Lower panel—angulation of the transducer to the patient's right using the same subcostal position clearly images the branching pulmonary artery arising from the right sided morphologically left ventricle. lvot, left ventricular outflow tract. (For remaining abbreviations see Fig. 1.)

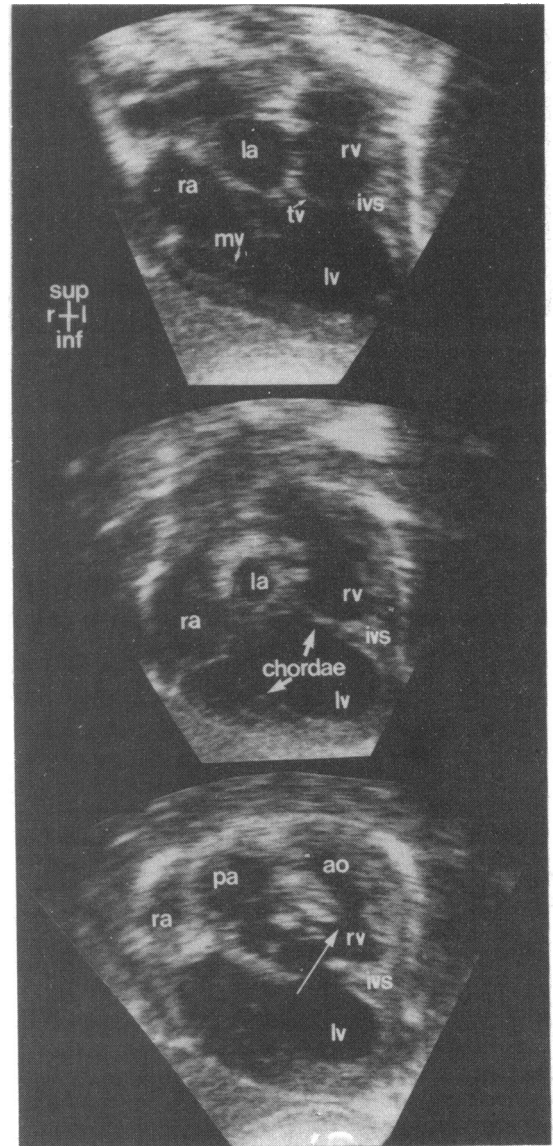


Fig. 6 Three frames from a subcostal scan through the heart of a patient in whom atrioventricular discordance was associated with superior-inferior ventricular relation and double outlet of the right (superior) ventricle. Upper panel—posterior four chamber cut. The initial appearances are suggestive of a double inlet atrioventricular connection. Scanning anteriorly (but still in the four chamber plane—middle panel) it is clear that the right atrioventricular valve chordae insert into a ventricular free wall

and that the left inlet valve chordae insert into the crest of the trabecular septum. Finally, in the lower panel, both ventricles are visualised with the morphological right ventricle lying in a superior position compared with the left ventricle. The left ventricle communicates with the right ventricle via a large perimembranous inlet defect. (The large arrow passes through the defect.) Both great vessels are clearly seen to arise from the superior right ventricle.

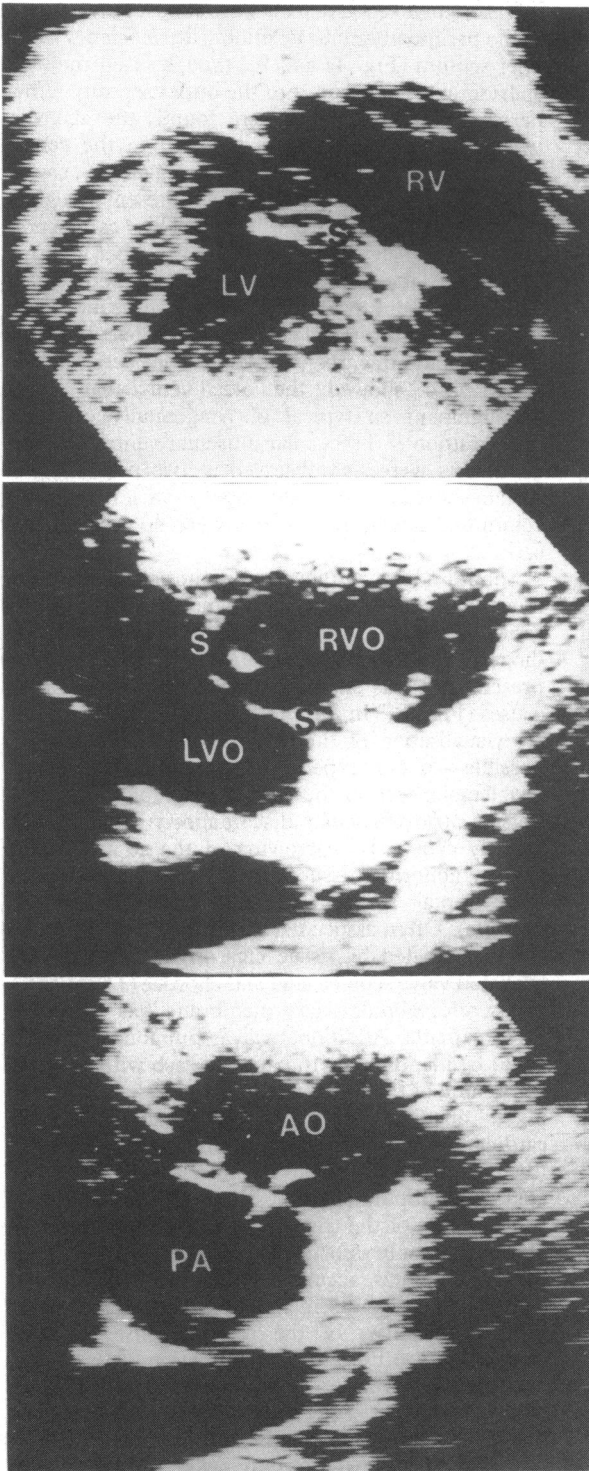


Fig. 7 *Ventriculoarterial discordance in atrioventricular discordance (congenitally corrected transposition). This montage demonstrates the principle of serial precordial short axis sectioning to determine precise ventriculoarterial connections and spatial relation. In the upper panel the ventricles are cut in a short axis cross-section. Moving the transducer to the next higher intercostal space cuts the ventricular outflow tracts in cross-sections. Moving the transducer one interspace higher the arterial valves are cut in cross-section, with the aortic valve lying anterior and to the right of the posterior pulmonary valve. This method of serial axis sectioning will reliably establish the precise ventriculoarterial connection and the relation of the great vessel roots to each other. RVO, right ventricular outflow; LVO, left ventricular outflow. (For remaining abbreviations see Fig. 1.)*

“cuts” which image the great vessels were needed to make this diagnosis. Tracing the ventricular outflow tracts through a series of precordial short axis sections was particularly helpful (Fig. 7). The long axis cut parallel to the inlet septum was of most value in diagnosing cases with single aortic trunk and pulmonary atresia (Fig. 8).

(5) ASSOCIATED MALFORMATIONS

These were reliably diagnosed in all cases studied. As anticipated, the classical triad^{10 11} of ventricular septal defect, pulmonary stenosis, and malformations of the left atrioventricular valve were most frequent.

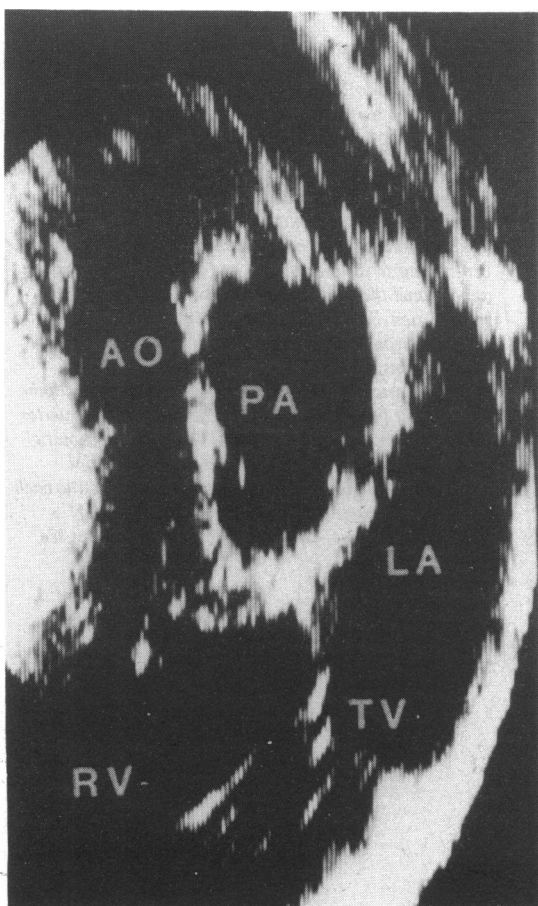


Fig. 8 Atrioventricular discordance with pulmonary atresia. A precordial long axis cut showing pulmonary atresia. There is a dense band of echoes clearly separating the morphological right ventricle from the main pulmonary artery. These echoes represent the atretic outflow tract. The aorta arises anteriorly from the morphological right ventricle.

Ventricular septal defects were almost always found in the perimembranous position with deficiency of the inlet septum (Fig. 4a and b), though often they had considerable extension into the outlet septum. When perimembranous defects were found, the atrioventricular valves were always attached to the central fibrous body at the same level (Fig. 4a and b), so that offsetting annular insertion was not present as a guide to atrioventricular discordance. This connection, however, was always identified by the other features, particularly the chordal attachments of the tricuspid valve to the septum and the presence of the moderator band in the morphologically right ventricle. The four chamber cuts in cases with ventriculoarterial discordance also showed the atrial-ventricular septal malalignment so typical of congenitally corrected transposition.¹² Trabecular muscular ventricular septal defects were also observed in two patients, well seen in short axis cuts at the appropriate level. Doubly committed subarterial defects were not seen in our series.

Subpulmonary outflow tract stenosis was one of the most common associated lesions encountered in this series. This was identified by cross-sectional echocardiography in 23 of the 33 patients in whom this was present and was shown to be the result of various causes (Fig. 9). (In the remaining 10 patients adequate visualisation of the subpulmonary area was not possible—in our experience this remains the most problematic area in the echocardiographic investigation of atrioventricular discordance.) This was frequently caused by narrowing of the subpulmonary area by abnormal tissue tags arising from the mitral valve septal leaflet and subvalve apparatus (17 patients). Often associated with this was further obstruction created by tissue tags originating from the tricuspid valve septal leaflet and chordae (11 patients). A discrete subpulmonary membrane was present in three patients. Additional valvar pulmonary stenosis could be identified in 16 patients, each with clear-cut thickening of the pulmonary valve cusps and a “doming” opening pattern. Cross-sectional echocardiography, however, was not of value in assessing the relative severity of the valvar stenosis when associated with subpulmonary obstruction.

Anomalies of the tricuspid valve were another one of the commonly associated abnormalities. They were consistently and accurately identified. Of the 47 patients with two discrete atrioventricular valves, 15 had abnormalities of the morphological tricuspid valve. Classical Ebstein’s malformation of the tricuspid valve was present in three cases (Fig. 10). The anterior downward displacement of the tricuspid valve ring into the morphological right ventricle associated with “plastering-down” of the septal tricuspid leaflet to the septal surface was easily

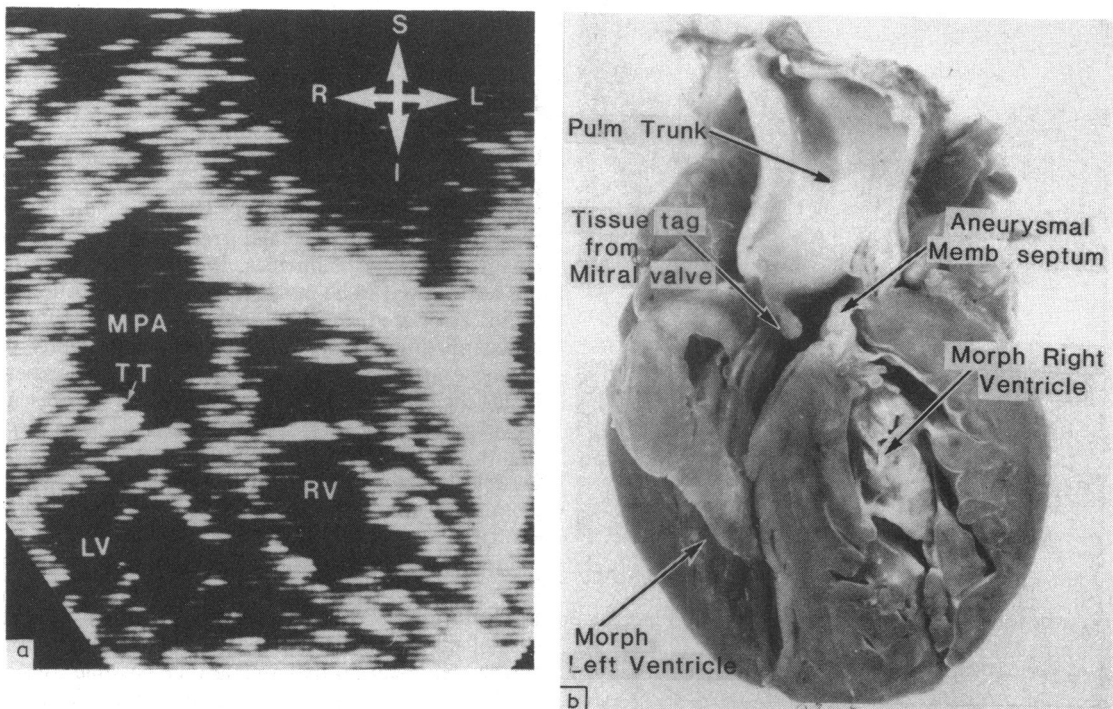


Fig. 9(a) A subcostal four chamber plus pulmonary root cut from a case of atrioventricular discordance with left ventricular outflow tract obstruction. The cross-sectional echocardiogram clearly showed the obstruction to be caused by tissue tags (TT) originating from both the mitral and tricuspid valves. (The proliferation of tricuspid tissue tags to form an aneurysm of the membranous septum is not well seen in this echocardiographic cut but was easily appreciated on other cuts.) (b) The pathological specimen (atrioventricular discordance with a perimembranous ventricular septal defect) from (a) sectioned in a subcostal four chamber plus pulmonary root cut. This specimen shows how involvement of mitral valve tissue tags and aneurysmal dilatation of the membranous septum can give rise to subpulmonary obstruction. These features were well visualised by cross-sectional echocardiography (see (a) above).

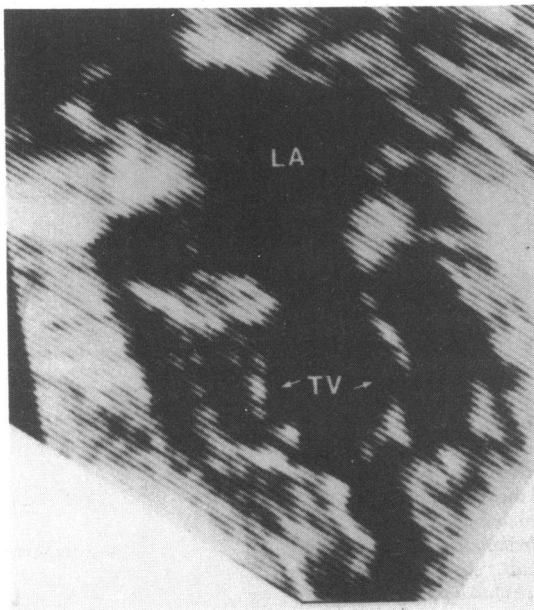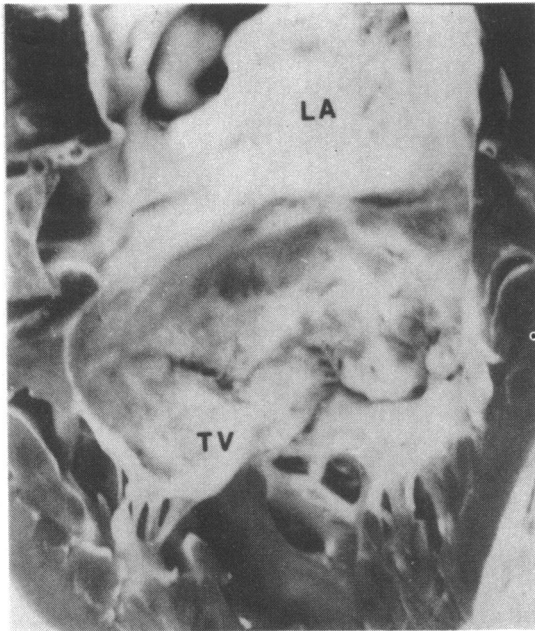


Fig. 10 The upper panel shows a pathological specimen sectioned in a four chamber plane of Ebstein's anomaly of the left sided atrioventricular valve in a case with atrioventricular discordance. The lower panel shows the corresponding echocardiographic features in the same patient. The large redundant tricuspid valve leaflets (small arrows) associated with the abnormal positioning of the tricuspid valve ring are clearly seen. (For abbreviations see Fig. 1.)

appreciated. In eight other cases an "Ebstein-like" malformation of the tricuspid valve was present. In these cases the tricuspid valve ring was normally positioned but was very large. The tricuspid valve leaflets were all large and redundant and were implanted into the septum and ventricular apex by short close packed chordae. There was no evidence of either anterior tricuspid valve ring displacement or "plastering-down" of the septal leaflet in these cases. Other abnormalities of the tricuspid valve were encountered; severe hypoplasia of the tricuspid valve (with tricuspid stenosis) was present in two patients; a minor degree of chordal straddling (precluding any attempt at closure of the perimembranous defect) was present in a further two patients.

Discussion

Cross-sectional echocardiography in our hands has proved to be consistently reliable in the diagnosis of atrioventricular discordance, whatever the ventriculoarterial connection and irrespective of the presence of associated anomalies. Indeed, the technique has also proved to be invaluable in the delineation of these associated lesions when present. M-mode echocardiography was very limited in its ability to diagnose atrioventricular discordance but in expert hands the diagnosis could be achieved.¹³ Our present experience, together with that of others^{1 2} has shown that the cross-sectional technique makes the diagnosis feasible for any who can distinguish a right atrium from a left atrium and a right ventricle from a left ventricle.

Ideally, these distinctions should be made by using cross-sectional echocardiography to identify directly the features particular to the given chambers. In the case of the ventricles this is certainly possible. With further experience it may well also be possible consistently to distinguish by echocardiography the morphologically right from the morphologically left atrium. Even without this facility, however, it is now possible to distinguish the atria by determining the morphology of their venous connections. If all the systemic veins connect to one atrium and all the pulmonary veins to the other, then for all practical purposes this means that the atria are lateralised and that the morphologically right atrium is the systemic one. The finding of anomalous venous connections, either systemic or pulmonary, should immediately alert the investigator to the possibility of atrial isomerism.¹⁴ Then filter film radiography⁵ or abdominal ultrasonography³ will reliably define visceral arrangement from which the atrial position can be inferred. Thus the experienced echocardiographer should always start his examination by studying the arrangement of the abdominal great vessels.¹ Using

this approach atrial position should be known with a high degree of confidence before the heart itself is scanned.

Knowing the atrial position, the diagnosis of atrioventricular discordance simply depends on the demonstration that each atrium is connected to a morphologically inappropriate ventricle. As Foale and his colleagues² have indicated, several features of ventricular morphology are of value in distinguishing by echocardiography the morphologically right from the morphologically left ventricle. In the final analysis all of these features are taken into consideration but, like Foale *et al.*,² we find the morphology of the tricuspid valve tension apparatus to be universally reliable. In all our cases we observed atrioventricular valve chordal attachments to the inlet septum only in the morphologically right ventricle. Unlike Foale *et al.*,² however, we did not find a reversal of the normal pattern of septal leaflet attachment of the atrioventricular valves to be uniformly present in hearts with atrioventricular discordance. When present it was always diagnostic, as also shown by Hagler and his colleagues.¹ It was not observed, however, in any case where there was an inlet component to a perimembranous ventricular septal defect, since in these hearts the associated deficiency of the inlet septum results in both atrioventricular valve septal leaflets being attached to the central fibrous body at the same level. But, in such cases though atrioventricular discordance could not be diagnosed from the septal leaflet attachments, attention to the other features of ventricular morphology, particularly the chordal attachments of the tricuspid valve, reliably distinguished morphologically right and left ventricles.

It was significant that by attention to atrioventricular connections and ventricular relations as separate features, no difficulty was encountered in diagnosing the presence of atrioventricular discordance in either "criss-cross" hearts or those with superior/inferior ventricles. Rare cases have now been described in which ventricular architecture was not as anticipated for the given connection. Thus, Weinberg *et al.*,¹⁵ have found hearts in which, despite the coexistence of usually arranged atria and atrioventricular discordance, the ventricular mass had a right hand pattern, that is a d-loop. Though we did not encounter such a heart in our series, by treating connections and relations as separate features we do not expect that these rare cases would give any difficulty in diagnosis.

Having established the criteria that allow us reliably to diagnose atrioventricular discordance our study also shows the need to discuss with care the precise ventriculoarterial connection. Though usually this connection is also discordant, it is not uniformly so. In one quarter of our series connections other than discordance were found. While concordant ven-

triculoarterial connection,¹⁶ double outlet left ventricle,¹⁷ and truncus¹⁸ were not seen in this experience, they must also be anticipated. When congenitally corrected transposition (double discordance) is found, then attention should immediately be turned to searching for the anticipated triad of associated lesions.¹⁰⁻¹¹ We had no difficulty in diagnosing and differentiating the different types of ventricular septal defect,¹¹ subpulmonary outflow tract obstruction,¹⁹ and tricuspid valve malformations encountered. It is of note, however, that we did not see any doubly committed subarterial ("supracristal") ventricular septal defects. These are much more frequent in Asian than in Caucasian populations.²⁰ If encountered, they would be distinguished by finding aortic-pulmonary valvar continuity in the roof of the defect.

In summary, by careful attention to diagnosis of atrial position and differentiation of ventricular morphology we here found cross-sectional echocardiography to be invaluable in the diagnosis of atrioventricular discordance. This has been the case whatever the cardiac position and ventricular relations and irrespective of the presence or absence of associated malformations. In our experience it provides the method of choice for analysis of the atrioventricular junction in this malformation though some additional information can be provided by judicious use of axial angiocardiology.²¹

References

- Hagler DJ, Tajik AJ, Seward JB, Edwards WD, Mair DD, Ritter DG. Atrioventricular and ventriculoarterial discordance (corrected transposition of the great arteries). Wide angle two-dimensional echocardiographic assessment of ventricular morphology. *Mayo Clin Proc* 1981; 56: 591-600.
- Foale R, Stefanini L, Rickards A, Somerville J. Left and right ventricular morphology in complex congenital heart disease defined by two dimensional echocardiography. *Am J Cardiol* 1982; 49: 93-9.
- Huhta JC, Smallhorn JF, Macartney FJ. Two dimensional echocardiographic diagnosis of situs. *Br Heart J* 1982; 48: 97-108.
- Hunter S, Sutherland G, Leech G, Kisslo J. *An introduction to echocardiography*. 2nd series. Unit 4: *Congenital heart disease*. London: Medi-Cine, 1982.
- Deanfield JE, Leanage R, Stroobant J, Chrispin AR, Taylor JFN, Macartney FJ. Use of high kilovoltage filtered beam radiographs for detection of bronchial situs in infants and young children. *Br Heart J* 1980; 44: 577-83.
- Lev M. Pathologic diagnosis of positional variations in cardiac chambers in congenital heart disease. *Lab Invest* 1954; 3: 71-82.
- Van Praagh R, David I, Van Praagh S. What is a ventricle? The single ventricle trap. *Pediatr Cardiol* 1982; 2: 79-84.
- Shinebourne EA, Tynan MJ, Anderson RH, Macartney

- FJ. Atrioventricular connexions. In: Anderson RH, Shinebourne EA, eds. *Paediatric cardiology 1977*. Edinburgh: Churchill Livingstone, 1978: 27-35.
- 9 Smallhorn JF, Sutherland GR, Anderson RH, Macartney FJ. Cross-sectional echocardiographic assessment of conditions with atrioventricular valve leaflets attached to the atrial septum at the same level. *Br Heart J* 1982; 48: 331-41.
 - 10 Van Praagh R. What is congenitally corrected transposition? *N Engl J Med* 1970; 282: 1097-8.
 - 11 Allwork SP, Bentall HH, Becker AE, et al. Congenitally corrected transposition of the great arteries: morphologic study of 32 cases. *Am J Cardiol* 1976; 38: 910-23.
 - 12 Becker AE, Anderson RH. Conditions with discordant atrioventricular connexions—anatomy and conducting tissues. In: Anderson RH, Shinebourne EA, eds. *Paediatric cardiology 1977*. Edinburgh: Churchill Livingstone, 1978: 184-97.
 - 13 Keutel J, Hagenmueller H. Echocardiography in diagnosis of corrected transposition. In: Anderson RH, Shinebourne EA, eds. *Paediatric cardiology 1977*. Edinburgh: Churchill Livingstone, 1978: 515-23.
 - 14 Macartney FJ, Zuberbuhler JR, Anderson RH. Morphological considerations pertaining to recognition of atrial isomerism. Consequences for sequential chamber localisation. *Br Heart J* 1980; 44: 657-67.
 - 15 Weinberg PM, Van Praagh R, Wagner HR, Cuaso CC. New form of criss-cross atrioventricular relation: an expanded view of the meaning of D and L-loops. Abstract Book of World Congress of Paediatric Cardiology. Edinburgh: Churchill Livingstone 1980: 319.
 - 16 Quero-Jiménez M, Raposo-Sonnenfeld I. Isolated ventricular inversion with situs solitus. *Br Heart J* 1975; 37: 293-304.
 - 17 Brandt PWT, Calder AL, Barratt-Boyes BG, Neutze JM. Double outlet left ventricle. Morphology, cineangiographic diagnosis and surgical treatment. *Am J Cardiol* 1976; 38: 897-909.
 - 18 Espino-Vela J, de la Cruz MV, Muñoz-Castellanos L, Plaza L, Attie F. Ventricular inversion without transposition of the great vessels in situs inversus. *Br Heart J* 1970; 32: 292-303.
 - 19 Anderson RH, Becker AE, Gerlis LM. The pulmonary outflow tract in classically corrected transposition. *J Thorac Cardiovasc Surg* 1975; 69: 747-57.
 - 20 Okamura K, Konno S. Two types of ventricular septal defect in corrected transposition of the great arteries: reference to surgical approaches. *Am Heart J* 1973; 85: 483-90.
 - 21 Attie F, Soni J, Ovseyevitz J, Muñoz-Castellanos L, Testelli MR, Buendia A. Angiographic studies of atrioventricular discordance. *Circulation* 1980; 62: 407-15.
- Requests for reprints to Dr G R Sutherland, Southampton General Hospital, Tremona Road, Shirley, Southampton SO9 4XY.