

Chordal rupture

I: Aetiology and natural history

D B G OLIVEIRA, K D DAWKINS, P H KAY, M PANETH

From the Brompton Hospital, London

SUMMARY Between 1970 and 1981, 12% of patients undergoing mitral valve surgery were found to have chordal rupture. Spontaneous or primary rupture accounted for 74.6% of patients (primary group); in the remainder (secondary group) chordal rupture complicated chronic rheumatic valvular disease (8.9%), bacterial endocarditis on both normal (8.5%) and rheumatic valves (4.7%), ischaemic heart disease (2.3%), acute rheumatic fever (0.5%), and osteogenesis imperfecta (0.5%). Isolated posterior rupture was seen most frequently (54%), with anterior rupture in 36% and rupture of both mitral cusps in 10% of patients. A short symptomatic history of acute mitral regurgitation was rare, occurring in only 4% of patients in either the primary or secondary groups, suggesting that mitral regurgitation due to ruptured chordae is a progressive disease. In contrast to previous reports the clinical presentation did not help to differentiate the aetiology of the chordal rupture.

Rupture of the chordae tendineae of the mitral valve was first described by Corvisart in 1806.¹ Pure mitral regurgitation itself was initially regarded as an uncommon disease² and ruptured chordae tendineae a rarity as a cause, with only occasional case histories and reports of small series being published initially.³⁻¹² In the past 20 years the condition has been increasingly recognised and larger series have been reported.¹³⁻²² Later reports have found ruptured chordae to be the second commonest,²³ or leading,²⁴ cause of pure mitral regurgitation.

As the importance of ruptured chordae has become increasingly recognised so have ideas about the aetiology evolved. Initially, it was thought that bacterial endocarditis was the major cause,^{13 17} often on the basis of rheumatic heart disease (the first case described by Corvisart was probably due to endocarditis). Sanders *et al.*²² also reported a case following non-bacterial endocarditis. The importance of rheumatic heart disease alone as a cause was also soon established.⁸ Much less often ruptured chordae have been reported in acute rheumatic fever,²⁵ after blunt trauma^{9 26} or surgery,^{16 27} in Marfan's²⁸ and the Ehlers-Danlos²² syndromes, osteogenesis imperfecta,²⁹ systemic lupus erythematosus,³⁰ congenital heart disease,²³ hypertrophic obstructive cardiomyopathy,³¹ systolic click-late systolic murmur (mitral valve prolapse) syndrome,³² and in association with pregnancy.³³ Acute myocardial infarction, although usually causing mitral regurgitation by

papillary muscle dysfunction or rupture,^{34 35} may also present with ruptured chordae.^{22 23 36} In addition, coronary artery disease without infarction has been reported in association with chordal rupture.³⁷ Aortic regurgitation,^{22 38} pre-existing unrelated mitral regurgitation,¹⁶ or any cause of left ventricular volume overload are thought in some cases to lead to chordal rupture by increased strain and stretching of previously normal chordae. Chordal rupture may also be seen in association with left atrial myxoma as a result of the "wrecking ball" action of the tumour.³⁹

Spontaneous chordal rupture was first described in 1934⁷ and has assumed increasing importance since then. The concept of primary spontaneous chordal rupture as distinct from ruptured chordae secondary to the causes given above was developed in 1967 by Selzer *et al.*²⁰ and Auger and Wigle.⁴⁰ In recent series spontaneous chordal rupture has been found to be the commonest type.^{24 41}

In this paper we have reviewed the recent surgical experience of ruptured chordae at this hospital in order to illustrate the present natural history of the condition in the light of the above concepts.

Patients and methods

The case records of all patients found to have ruptured chordae at open heart surgery for mitral regurgitation in the years 1970-81 inclusive were reviewed. Only cases documented at operation were included, as mitral regurgitation due to prolapsing mitral leaflets may be indistinguishable—both from the history and

Table Aetiology, clinical details, and surgical findings in 213 patients with chordal rupture

Aetiology	No (%) of patients	Age (mean \pm SD, years)	Sex		With atrial fibrillation		Cusps affected					
			M	F	No	%	Anterior		Posterior		Both	
							No	%	No	%	No	%
Spontaneous rupture	159 (74.6)	59 \pm 11	91	68	58	36	50	31	98	62	11	7
Chronic rheumatic disease*	19 (8.9)	51 \pm 15	3	16	14	74	8	42	8	42	2	11
Subacute bacterial endocarditis												
Normal valve*	18 (8.5)	48 \pm 19	6	12	3	17	9	50	3	17	5	28
Rheumatic valve	10 (4.7)	41 \pm 12	2	8	6	60	8	80	1	10	1	10
Ischaemic heart disease	5 (2.3)	67 \pm 5	4	1	3	60	0	0	4	80	1	20
Acute rheumatic fever	1 (0.47)	4	0	1	0	0	1	0	0	0	0	0
Osteogenesis imperfecta	1 (0.47)	63	1	0	0	0	0	0	0	0	1	1

* In one (5%) patient the cusp affected was not stated.

the clinical examination—from regurgitation due to ruptured chordae.⁴¹

In view of the difficulties of obtaining adequate data in a retrospective survey certain aspects were not analysed but reviews of the physical signs,⁴² radiological appearances,^{43,44} and haemodynamic variables appear elsewhere.^{40,45}

Results

During the period 1970–81, 213 patients (106 women and 107 men) came to surgery with ruptured chordae tendineae. Mean age at the time of presentation was 56 (range 4–78) years. In the same period a total of 1833 patients underwent surgery for all forms of mitral valve disease; thus chordal rupture accounted for 12% of patients undergoing mitral valve surgery.

AETIOLOGY

The Table shows the causes of the chordal rupture. Spontaneous or primary rupture accounted for 74.6% of patients (primary group), secondary rupture occurring in the remaining 54 patients (secondary group). Nineteen patients with chronic rheumatic mitral valve disease were found to have chordal rupture at the time of surgery. Of this subgroup, 15 (80%) had previously undergone closed mitral valvotomy. In 18 patients (8.5% of the total) documented bacterial endocarditis resulted in chordal rupture on a previously normal valve. In 10 patients bacterial endocarditis affected a rheumatic valve causing predominant mitral regurgitation. Endocarditis was caused by several organisms including *Streptococcus viridans*, *Streptococcus faecalis*, *Staphylococcus aureus*, and Q fever. The remaining causes of chordal rupture were related to ischaemic heart disease (5), acute rheumatic carditis (1), and osteogenesis imperfecta (1).

AGE AND SEX

Patients with spontaneous rupture were predominantly men (ratio 1.3:1), with a mean (\pm SD) age of 59 \pm 11 years (Table). In the groups with chronic

rheumatic disease, bacterial endocarditis (normal valve), and bacterial endocarditis (rheumatic valve) the age ranges (mean \pm SD) were not statistically different (51 \pm 15, 48 \pm 19, and 41 \pm 12 years respectively). Women were affected more commonly than men in all these groups. Patients who had had an acute myocardial infarction with subsequent chordal rupture were significantly older than all other patients (mean \pm SD, 67 \pm 5 years, $p < 0.01$), with a predominance of men (Table).

RHYTHM

The Table also shows the incidence of atrial fibrillation. This ranged from 17%–74% in the different groups, being most frequent in the patients with chronic rheumatic mitral valve disease. Overall, of 213 patients, 84 (39%) were in atrial fibrillation, 128 (60%) were in sinus rhythm, and one was in complete atrioventricular block.

SYMPTOMS

All patients presented with dyspnoea on effort, often with associated palpitations. At surgery 56% of patients were in New York Heart Association functional classes III and IV. Subjective exercise assessment was identical for the primary and secondary groups (56% of patients in classes III and IV). The duration of symptoms was wide, ranging from a few days in one patient to more than 10 years in another who had had progressive dyspnoea on effort for 30 years (Figure). Most patients had symptoms for between one month and one year before presentation; again the data for the primary and secondary groups were similar.

CUSPS AFFECTED

In the whole series of patients isolated posterior chordal rupture was seen most often (54%), with anterior rupture present in 36%, and rupture of the chordae to both cusps least often (10%). In the primary group posterior rupture was seen in 62% of patients whereas in the secondary group it accounted for only 30% of

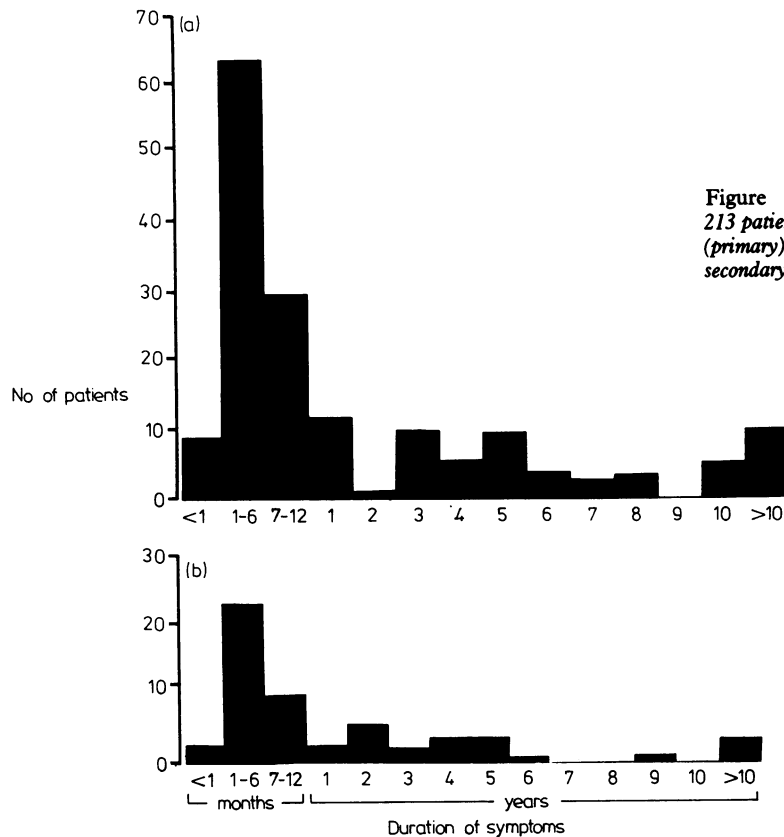


Figure Duration of symptoms in 213 patients with (a) spontaneous (primary) chordal rupture and (b) secondary chordal rupture.

patients. In two (0.9%) patients the cusp affected was not stated by the surgeon (Table).

Discussion

Mitral regurgitation caused by ruptured chordae tendineae forms a small proportion of surgically treated mitral valve disease. The present series is not a complete record of all cases of chordal rupture seen in the period stated in at least two ways. Firstly, any cases of incidental chordal rupture found at operation for lesions other than mitral regurgitation have not been included. Secondly, there were several patients investigated during this period who were thought to have chordal rupture but whose symptoms were not severe enough to warrant surgery. This state of "compensated" chordal rupture has been recognised for some time,²⁰ but in view of the difficulties in making the diagnosis with certainty without direct inspection of the valve these cases have also been excluded. The remaining 213 cases seen over 11 years are, however, representative of a recent population presenting for

surgery with haemodynamically significant chordal rupture.

The present series confirms the increasing importance of spontaneous (or primary) chordal rupture. In an early report,¹³ only 20% of patients had spontaneous rupture. Nevertheless, spontaneous rupture accounted for 68% of cases in more recent series²³ and was present in 75% of our patients. It seems unlikely that the decreasing incidence of rheumatic fever is the full explanation for this apparent change in aetiology. Furthermore, there has been no appreciable improvement in the morbidity and mortality associated with bacterial endocarditis during this period.

The aetiological basis of spontaneous chordal rupture is still unclear, but it probably results from abnormalities of collagen synthesis and degradation. Caulfield *et al.*⁴⁶ found focal dissolution of elastin and collagen in both ruptured and non-ruptured chordae, valve tissue, and regions of chordae remote from the site of rupture. Kastor *et al.*⁴⁷ noted a particularly high incidence of paravalvular leaks after mitral valve replacement for ruptured chordae and speculated that

this might be due to a generalised weakness of the tissues. It has also been suggested that myxomatous transformation leading to floppy valves with or without chordal rupture may represent a forme fruste of the Marfan syndrome,⁴⁸ and the connection between the myxomatous floppy mitral valve and chordal rupture is well established.⁴⁹ Another histological study,⁵⁰ however, found that changes of oedema and necrosis of collagen with endothelial loss were confined (with one exception) to the region of rupture, and these authors suggest that this relative normality of remaining tissue provides some theoretical justification for mitral valve repair as opposed to replacement.

As reported previously by most,^{20 23 42} but not all,²¹ workers there was a higher incidence of ruptured chordae to the posterior leaflet in the spontaneous group. Although the detailed arrangement of the chordae is very variable, there is some anatomical basis for the predominance of posterior chordal rupture. Despite the larger area of the anterior mitral leaflet, it is tangential to systolic flow and hence liable to less stress than the posterior leaflet which is perpendicular to flow during systole. The anterior leaflet is also attached to the central fibrous body which is a semirigid structure and forms part of the axial skeleton of the heart. Furthermore, the anterior mitral leaflet often has two large thick "strut" chordae⁵¹ whereas those to the posterior leaflet are short and thin.

The incidence of chordal rupture in patients with chronic rheumatic mitral valve disease is higher than reported previously; in part, this may reflect the changing pattern of cardiac surgery in that 80% of these patients had undergone previous closed mitral valvotomy, which may occasionally result in chordal rupture. In patients with a floppy mitral valve bacterial endocarditis tends to result in chordal rupture of the posterior cusp whereas in bacterial endocarditis on normal or rheumatic valves the anterior cusp is most commonly affected, with chordal rupture often occurring in association with cusp perforation.

Rarely, ischaemic heart disease is associated with chordal rupture. The papillary muscles are supplied by end arteries,⁵² and acute myocardial infarction results in papillary muscle dysfunction or, less frequently, papillary muscle rupture. By contrast the chordae tendineae are avascular structures, although in the normal mitral valve a small proportion of chordae show a muscle core throughout their length, particularly to the anterior cusp.⁵³ In most instances ischaemic chordal rupture is a misnomer since the site of the dehiscence is through the fibrous tip of the papillary muscle at the point of chordal insertion, and at surgery (or necropsy) this may be morphologically and histologically indistinguishable from true chordal

rupture. Ischaemic rupture of the body of a chorda remote from a papillary muscle is very rare, but it has been reported in a "muscularised" chorda.⁵⁴ In most cases of chordal rupture the aetiology can be determined by direct inspection of the valve by an experienced surgeon or pathologist. In a few patients the aetiology is unclear from the naked eye appearance of the valve, and in these cases histology and electron microscopy are often non-contributory.

Data from this study lend support to the concept of a distinct group with spontaneous chordal rupture (Table). In the spontaneous group men predominated (57%), although this was not as pronounced as in the study of Selzer *et al.*²⁰ The prevalence of spontaneous chordal rupture in men suggests that the aetiology may be different from mitral valve prolapse, which is seen more often in women, and may be associated with chordal rupture. As expected, rheumatic groups (with and without bacterial endocarditis) showed a predominance of women whereas in the ischaemic group men were more commonly affected. The incidence of atrial fibrillation is in accord with previous experience, being generally lower in the primary group. Although the ischaemic group was older than the others, there was no significant age difference between the remainder of the secondary groups. Other workers have found that patients in the spontaneous rupture group have a narrower age range and are generally older than those in the secondary groups.^{20 23}

The acute presentation of patients with chordal rupture on a previously normal valve has been emphasised in published reports.^{17 19 40} In the present series the duration of symptoms was similar in the primary and secondary groups (Figure), and a short symptomatic history of less than one month was rare in both groups, accounting for only 4% of all patients. This suggests that the initial event is rupture of a few chordae only, which is well tolerated. In time further chordae rupture as a result of increased stress placed on the remaining chordae and the associated prolapse of a segment of the affected cusp. Thus mitral regurgitation becomes more severe to the extent that the patient becomes symptomatic.

Further aspects of the surgical treatment of chordal rupture are reviewed in part II of this paper.

We thank Professor M J Davies for helpful advice during the preparation of this paper.

References

- 1 Corvisart JN. *Essai sur les maladies et les lésions organiques du coeur et des gros vaisseaux*. Paris: Migneret, 1806.
- 2 Brigden W, Leatham A. Mitral incompetence. *Br Heart J* 1953; 15: 55-73.
- 3 Flint A. *A practical treatise on the diagnosis, pathology and*

- treatment of disease of the heart. Philadelphia: Blanchard and Lea, 1859.
- 4 Peacock TB. On some of the causes and effects of valvular disease of the heart: being the Croonian lectures of the Royal College of Physicians. London: J Churchill, 1865.
 - 5 Bristowe JS. Rupture of chordae tendineae; consequent symptoms of heart disease. *Transactions of the Pathological Society (London)* 1873; 24: 72-5.
 - 6 Frew HWD. Rupture of the chordae tendineae following scarlet fever. *Glasgow Medical Journal* 1931; 115: 195-7.
 - 7 Frothingham C, Hass GM. Rupture of normal chordae tendineae of the mitral valve. *Am Heart J* 1934; 9: 492-9.
 - 8 Bailey OT, Hickman JA. Rupture of mitral chordae tendineae: clinical and pathological observations on seven cases in which there was no bacterial endocarditis. *Am Heart J* 1944; 28: 578-600.
 - 9 Barber H. The effects of trauma, direct and indirect, on the heart. *Q J Med* 1944; 13: 137-67.
 - 10 Osmundson PJ, Callahan JA, Edwards JE. Mitral insufficiency from ruptured chordae tendineae simulating aortic stenosis. *Proceedings of the Staff Meetings of the Mayo Clinic* 1958; 33: 235-44.
 - 11 Miller R, Pearson RJ. Mitral insufficiency simulating aortic stenosis. *N Engl J Med* 1959; 260: 1210-3.
 - 12 Shapiro HA, Weiss DR. Mitral insufficiency due to ruptured chordae tendineae simulating aortic stenosis. *N Engl J Med* 1959; 261: 272-6.
 - 13 Osmundson PJ, Callahan JA, Edwards JE. Ruptured mitral chordae tendineae. *Circulation* 1961; 23: 42-54.
 - 14 Menges H Jr, Ankeney JL, Hellerstein HK. The clinical diagnosis and surgical management of ruptured mitral chordae tendineae. *Circulation* 1964; 30: 8-16.
 - 15 Sanders CA, Scannell JG, Harthorne JW, Austen WG. Severe mitral regurgitation secondary to ruptured chordae tendineae. *Circulation* 1965; 31: 506-16.
 - 16 Marchand P, Barlow JB, Du Plessis LA, Webster I. Mitral regurgitation with rupture of normal chordae tendineae. *Br Heart J* 1966; 28: 746-58.
 - 17 Roberts WC, Braunwald E, Morrow AG. Acute severe mitral regurgitation secondary to ruptured chordae tendineae. *Circulation* 1966; 33: 58-70.
 - 18 Raftery EB, Oakley CM, Goodwin JF. Acute subvalvular mitral incompetence. *Lancet* 1966; ii: 360-5.
 - 19 Childress RH, Maroon JC, Genovese PD. Mitral insufficiency secondary to ruptured chordae tendineae. *Ann Intern Med* 1966; 65: 232-244.
 - 20 Selzer A, Kelly JJ Jr, Vannitamby M, Walker P, Gerbode F, Kerth WJ. The syndrome of mitral insufficiency due to isolated rupture of the chordae tendineae. *Am J Med* 1967; 43: 822-36.
 - 21 Klughaupt M, Flamm MD, Hancock EW, Harrison DC. Nonrheumatic mitral insufficiency; determination of operability and prognosis. *Circulation* 1969; 39: 307-16.
 - 22 Sanders CA, Austen WG, Harthorne JW, Dinsmore RE, Scannell JG. Diagnosis and surgical treatment of mitral regurgitation secondary to ruptured chordae tendineae. *N Engl J Med* 1967; 276: 943-9.
 - 23 Selzer A, Katayama F. Mitral regurgitation: clinical patterns, pathophysiology and natural history. *Medicine (Baltimore)* 1972; 51: 337-66.
 - 24 Jais JM, Cadilhac M, Luxereau P, et al. Les insuffisances mitrales par rupture et elongation de cordages. *Arch Mal Coeur* 1981; 74: 129-38.
 - 25 Hwang WS, Lam KL. Rupture of chordae tendineae during acute rheumatic carditis. *Br Heart J* 1968; 30: 429-31.
 - 26 McLaughlin JS, Cowley RA, Smith G, Matheson NA. Mitral valve disease from blunt trauma. *J Thorac Cardiovasc Surg* 1964; 48: 261-71.
 - 27 Brock RC. The arterial route to the aorta and pulmonary valves. The mitral route to the aortic valve. *Guys Hospital Reports* 1950; 99: 236-46.
 - 28 Simpson JW, Nora JJ, McNamara DG. Marfan's syndrome and mitral valve disease: acute surgical emergencies. *Am Heart J* 1969; 77: 96-9.
 - 29 Wood SJ, Thomas J, Braimbridge MV. Mitral valve disease and open heart surgery in osteogenesis imperfecta tarda. *Br Heart J* 1973; 35: 103-6.
 - 30 Murray FT, Fuleihan DS, Cornwall CS, Pinals RS. Acute mitral regurgitation from ruptured chordae tendineae in systemic lupus erythematosus. *J Rheumatol* 1975; 2: 454-9.
 - 31 Wolstenholme GEW, O'Connor M, eds. *Ciba Foundation symposia: cardiomyopathies*. London: J & A Churchill, 1964: 295.
 - 32 Goodman D, Kimbiris D, Linhart JW. Chordae tendineae rupture complicating the systolic click-late systolic murmur syndrome. *Am J Cardiol* 1974; 33: 681-4.
 - 33 Caves PK, Paneth M. Acute mitral regurgitation in pregnancy due to ruptured chordae tendineae. *Br Heart J* 1972; 34: 541-4.
 - 34 Burch GE, De Pasquale NP, Phillips JH. The syndrome of papillary muscle dysfunction. *Am Heart J* 1968; 75: 399-415.
 - 35 Austen WG, Sokol DM, DeSanctis RW, Sanders CA. Surgical treatment of papillary-muscle rupture complicating myocardial infarction. *N Engl J Med* 1968; 278: 1137-41.
 - 36 Hudson REB. *Cardiovascular pathology*. vol. 1. London: Arnold, 1965: 716.
 - 37 Cuasay RS, Morse DP, Spagna P, Fernandez J, Lemole GM. Massive mitral regurgitation from chordal rupture and coronary artery disease. *Ann Thorac Surg* 1978; 25: 438-43.
 - 38 Manhas DR, Hessel EA, Winterscheid LC, Dillard DH, Merendino KA. Repair of mitral incompetence secondary to ruptured chordae tendineae. *Circulation* 1971; 43: 688-97.
 - 39 Wise JR Jr. Mitral regurgitation due to rupture of chordae tendineae by calcified atrial myxoma. *Br Med J* 1974; ii: 95-6.
 - 40 Auger P, Wigle ED. Sudden, severe mitral insufficiency. *Can Med Assoc J* 1967; 96: 1493-503.
 - 41 Shore DF, Wong P, Paneth M. Results of mitral valvuloplasty with a suture plication technique. *J Thorac Cardiovasc Surg* 1980; 79: 349-57.
 - 42 Littler WA, Epstein EJ, Coulshed N. Acute mitral regurgitation resulting from ruptured or elongated chordae tendineae. *Q J Med* 1973; 42: 87-110.
 - 43 Raphael MJ, Steiner RE, Raftery EB. Acute mitral incompetence. *Clin Radiol* 1967; 18: 126-36.
 - 44 Wexler L, Silverman JF, DeBusk RF, Harrison DC. Angiographic features of rheumatic and nonrheumatic mitral regurgitation. *Circulation* 1971; 44: 1080-6.

- 45 Baxley WA, Kennedy JW, Feild B, Dodge HT. Hemodynamics in ruptured chordae tendineae and chronic rheumatic mitral regurgitation. *Circulation* 1973; 48: 1288-94.
- 46 Caulfield JB, Page DL, Kastor JA, Sanders CA. Connective tissue abnormalities in spontaneous rupture of chordae tendineae. *Arch Pathol* 1971; 91: 537-41.
- 47 Kastor JA, Akbarian M, Buckley MJ, *et al.* Paravalvular leaks and hemolytic anemia following insertion of Starr-Edwards aortic and mitral valves. *J Thorac Cardiovasc Surg* 1968; 56: 279-88.
- 48 Read RC, Thal AP, Wendt VE. Symptomatic valvular myxomatous transformation (the floppy valve syndrome). A possible forme fruste of the Marfan syndrome. *Circulation* 1965; 32: 897-910.
- 49 Stinson EB, Griep RB, Oyer PE, Shumway NE. Long-term experience with porcine aortic valve xenografts. *J Thorac Cardiovasc Surg* 1977; 73: 54-63.
- 50 Scott-Jupp W, Barnett NL, Gallagher PJ, Monro JL, Ross JK. Ultrastructural changes in spontaneous rupture of mitral chordae tendineae. *J Pathol* 1981; 133: 185-201.
- 51 Lam JHC, Ranganathan N, Wigle ED, Silver MD. Morphology of the human mitral valve. I. Chordae tendineae: a new classification. *Circulation* 1970; 41: 449-58.
- 52 Ranganathan N, Burch GE. Gross morphology and arterial supply of the papillary muscles of the left ventricle of man. *Am Heart J* 1969; 77: 506-16.
- 53 Davies MJ. *Pathology of cardiac valves*. (Postgraduate pathology series.) London: Butterworths, 1980.
- 54 Fenoglio J Jr, Tuan-duc-Pham. Ruptured chordae tendineae. An electron microscope study. *Hum Pathol* 1972; 3: 415-20.

Requests for reprints to Dr K D Dawkins, Brompton Hospital, Fulham Road, London SW3 6HP.