

Cor triatriatum sinistrum

Diagnostic features on cross sectional echocardiography

I ÖSTMAN-SMITH,* N H SILVERMAN,† P OLDERSHAW, C LINCOLN,
E A SHINEBOURNE

From the Departments of Paediatric Cardiology, Cardiology, and Cardiothoracic Surgery, Brompton Hospital, London

SUMMARY M mode and cross sectional echocardiography was carried out in three cases of cor triatriatum sinistrum (two infants and one adult). In two cases a peculiar double arch appearance, not previously reported, was found. All three cases were referred for surgery without cardiac catheterisation, and the diagnosis proved to be correct. The characteristic echocardiographic feature of cor triatriatum is an intra-atrial membrane detected in multiple planes of examination, curving anteroinferiorly and inserting some distance away from the mitral valve ring, proximal to the left atrial appendage. Superiorly the membrane runs parallel to, and a short distance behind, the aortic root creating a superior recess of the distal left atrial chamber. These features differentiate cor triatriatum from a supravalar mitral ring. During diastole the membrane moves forward towards the mitral valve funnel. This, together with the arching appearance of the membrane on four chamber views and the more superior position of the membrane, makes it possible to distinguish cor triatriatum from total anomalous pulmonary venous drainage to the coronary sinus.

From a review of past experience at the Brompton Hospital of the diagnostic accuracy of cardiac catheterisation in this condition, it is concluded that cross sectional echocardiography is superior to angiography as a technique for diagnosing cor triatriatum.

Cor triatriatum is a rare cardiac malformation comprising about 0.1% of congenital heart disease.¹ Experience at the Brompton Hospital from 1970 to 1982 shows that of 3733 cardiac catheterisations at which congenital heart disease was diagnosed, there were only four cases of true cor triatriatum, confirming a prevalence of 0.1%. Three of these cases had isolated cor triatriatum sinistrum, while the fourth had in addition total anomalous pulmonary venous drainage to the superior vena cava, mitral atresia, aortic stenosis, and atrial and ventricular septal defects; in this case the cor triatriatum was not diagnosed at catheterisation but was found at post-

mortem examination. In a further four cases the catheter/angiographic diagnosis was cor triatriatum, but at operation a supravalar mitral ring (two cases) or total anomalous pulmonary venous drainage was found. Thus in these eight patients with left ventricular inflow obstruction but a normal mitral valve the catheter diagnosis was correct in three, with four false positive and one false negative result.

Thus in our experience cardiac catheterisation and angiography are not a reliable means of differentiating cor triatriatum from other causes of left ventricular inflow obstruction. As angiography may worsen the condition of an ill infant it would clearly be of value if the diagnosis of cor triatriatum could be made by non-invasive methods. Cross sectional echocardiography has been shown to be valuable in analysing the cause of a left ventricular inflow obstruction.²

We report three cases of cor triatriatum sinistrum in which the diagnosis was suspected clinically and confirmed by cross sectional echocardiography and which were referred for surgery without cardiac catheterisation. The echocardiographic features that

*Present address: Department of Paediatrics, John Radcliffe Hospital, Headington, Oxford.

†Visiting professor of paediatrics; permanent address: Department of Pediatrics C340, University of California San Francisco, San Francisco, California 94143, USA.

Requests for reprints to Dr I Östman-Smith, Department of Paediatrics, John Radcliffe Hospital, Headington, Oxford OX3 9DU.

Accepted for publication 4 October 1983

distinguish cor triatriatum from other forms of left ventricular inflow obstruction are reviewed.

Patients and methods

Cross sectional echocardiography was performed with a 90° angle ATL sector scanner using a 5 MHz (for the infants) or 3 MHz (for the adult) transducer, with the echocardiographic examination carried out from the standard parasternal, apical, subcostal, and suprasternal notch transducer locations.^{3 4}

CASE REPORTS

Case 1

A 16 month old boy with failure to thrive and frequent chest infections was admitted in congestive heart failure. On examination he was wasted and ill looking, tachypnoeic, and breathing with recession, with fine basal crepitations over both lungs. There was a precordial bulge with an increased left parasternal cardiac impulse, a normal first heart sound, a narrowly split second heart sound with accentuated pulmonary component, and a high pitched variable pansystolic murmur at the lower right and left sternal edges; the liver was palpable 4 cm below the costal margin. Electrocardiograms showed sinus rhythm, right atrial hypertrophy, a mean frontal QRS axis +120°, partial right bundle branch block with right ventricular hypertrophy, and flat T waves in leads V4R and V1. Chest x ray films showed situs solitus, a left aortic arch, and a normal sized heart but severe pulmonary venous congestion. Cross sectional echocardiography showed the left atrium to be divided by a membrane inserting well away from the mitral valve (see below for details), and cor triatriatum was diagnosed. Despite intensive treatment for heart failure his condition remained poor, and because cardiac catheterisation seemed unlikely to add any further information he was referred for surgery without catheterisation.

At operation a thick membrane, attached superiorly far away from the mitral valve ring with a 3 mm opening, was found and resected. The postoperative course was uneventful, and the child is now asymptomatic and has started to thrive.

Case 2

A 4 month old girl had been tachypnoeic with frequent chest infections from 2 months of age and at 3 months was failing to thrive, dyspnoeic, and sweating. A murmur was noted, and treatment with digoxin and frusemide started with no improvement. On admission she was ill, mottled, tachypnoeic, grunting, and breathing with pronounced recession. There was a prominent central precordial bulge with

an increased left parasternal impulse. The first heart sound was normal and the second narrowly split with some accentuation of the pulmonary component. There was an ejection systolic murmur at the third left intercostal space and a diastolic murmur at the lower left sternal edge and apex. Her liver was palpable at 3 cm below the costal margin. An hyperoxic test was normal. Electrocardiograms showed sinus rhythm, right atrial hypertrophy, a mean frontal QRS axis of +120°, severe right ventricular hypertrophy with flat T waves in V1, and reduced left ventricular forces. The chest x ray films showed situs solitus, a left aortic arch, moderate cardiomegaly, pulmonary plethora, and pulmonary venous congestion. Cross sectional echocardiography showed a membrane within the left atrium, inserting well away from the mitral valve ring, while contrast echocardiography showed a slight right to left shunt from the right atrium to the left atrium distal to the membrane. In view of her poor condition and because we considered that cardiac catheterisation would not add any essential information, she underwent immediate surgery.

At operation a large atrial septal defect connecting the right atrium and the proximal left atrial chamber was found, and a membrane between the proximal and distal left atrium was resected. No defect was seen in the resected portion of the membrane or localised by probe. She made a satisfactory postoperative recovery and is now asymptomatic and thriving.

Case 3

A 31 year old woman had had recurrent chest infections in childhood. A murmur had been noted at 4 years old. Physical findings suggested an atrial septal defect with fixed splitting of the second heart sound, and cardiac catheterisation at the age of 5 had shown a pulmonary artery pressure of 21/13 mm Hg and an increase in oxygen saturation at the ventricular level. At 8 years of age she was referred for surgery. At operation all pulmonary veins were seen to drain into the left atrium, and a 2 cm circular atrial septal defect was detected low in the atrial septum, unusually close to the tricuspid and mitral valves. There was a very prominent eustachian valve which made it difficult to suture the atrial septal defect without redirecting the blood flow from the inferior vena cava into the left atrium. Postoperatively she developed transient atrioventricular block but otherwise progressed well. She was able to participate in games but was never able to run for more than 200 m because of breathlessness. From the age of 30 years she had noted increasing breathlessness and fatigue on exertion.

On examination there was a prominent left parasternal and apical impulse, a loud and split first heart sound, fixed splitting of the second heart sound with a normal intensity pulmonary component becoming

louder on exercise, a short presystolic diastolic murmur, and a soft pansystolic murmur at the apex. Electrocardiograms showed sinus rhythm, a PR interval of 0.18 s, a mean frontal QRS axis of $+120^\circ$, partial right bundle branch block, and no definite right ventricular hypertrophy. Chest x ray films showed a left aortic arch with a small aortic knuckle, a normal sized heart, and increased pulmonary vascular markings, probably both arterial and venous, but no septal lines. Cross sectional echocardiography showed a membrane within the left atrium and a possible small defect in the atrial septum distal to the dividing atrial membrane (see below). Cor triatriatum was diagnosed and she was referred for surgery. At operation a thick membrane inserted above the fossa ovalis was found and resected. The membrane contained an opening measuring 4 mm \times 8 mm, situated inferiorly and to the right. In addition a small atrial septal defect in the lower part of the atrial septum was found. A very prominent eustachian valve was again noted.

Results

M MODE ECHOCARDIOGRAPHY

On M mode echocardiography a linear echo arising behind the aortic root within the left atrium could be seen (Fig. 1). This was fairly anterior, and in all three cases was positioned in the anterior half or even anterior third of the atrium. In case 3 the membrane showed some movement during the cardiac cycle— anterior during the first half of systole, posterior dur-

ing the second half, and then a sharp anterior movement with the onset of diastole; during diastole the pattern was reminiscent of that of a stenotic mitral valve (Fig. 1). A separate normal mitral valve echo was also seen.

CROSS SECTIONAL ECHOCARDIOGRAPHY

Parasternal long axis view—In all three cases a membranous structure within the left atrium could be seen. Superiorly this membrane ran parallel to, and a short distance behind, the aortic root and then curved anteroinferiorly to insert some distance away from the mitral valve ring (Fig. 2). Particularly in case 1 the membrane moved forward in diastole. The space between the aortic root and the membrane was variable, being smallest in case 1—constituting about 20% of the left atrial diameter—and largest in case 3, in which it varied between 30% and 40% of the left atrial diameter during the cardiac cycle. The thickness of the membrane echo also varied, being rather thin in case 1 and thicker in cases 2 and 3. In cases 1 and 2 the interventricular septum was bulging into the left ventricle, which was unusually small. The mitral valve leaflets showed normal movement in all three cases.

Parasternal short-axis view—The pulmonary artery was notably enlarged, and the aortic root was small in both cases 1 and 2, whereas there was no obvious pulmonary artery enlargement in case 3. Again, in all three cases a membrane could be seen within the left atrium running transversely behind the aortic root (Fig. 3). Although it was difficult to image the whole

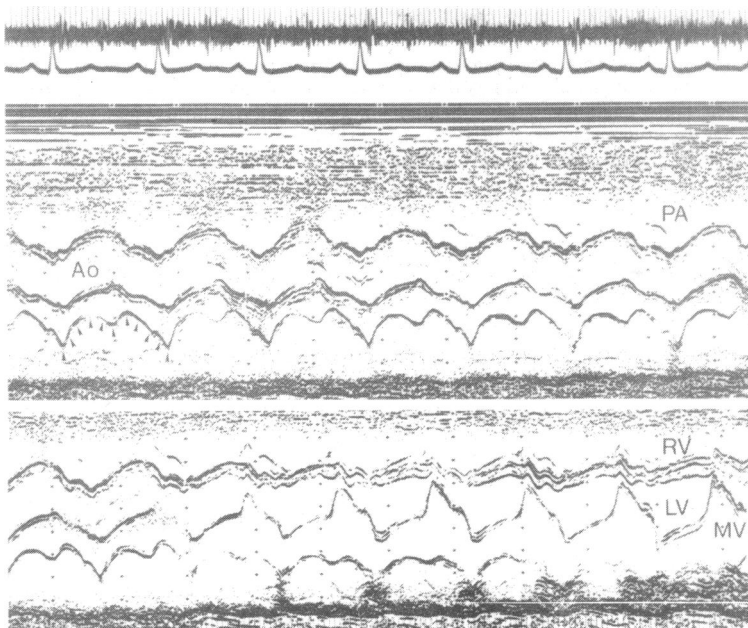


Fig. 1 M mode echocardiogram showing a sweep from the aortic root into the left ventricle with a distinct abnormal linear echo within the anterior part of the left atrium (marked with arrowheads) becoming more posterior as the anterior mitral valve leaflet comes into view. The electrocardiogram relates to the upper panel only. Ao, aorta; PA, pulmonary artery; RV, right ventricle; LV, left ventricle; MV, mitral valve.

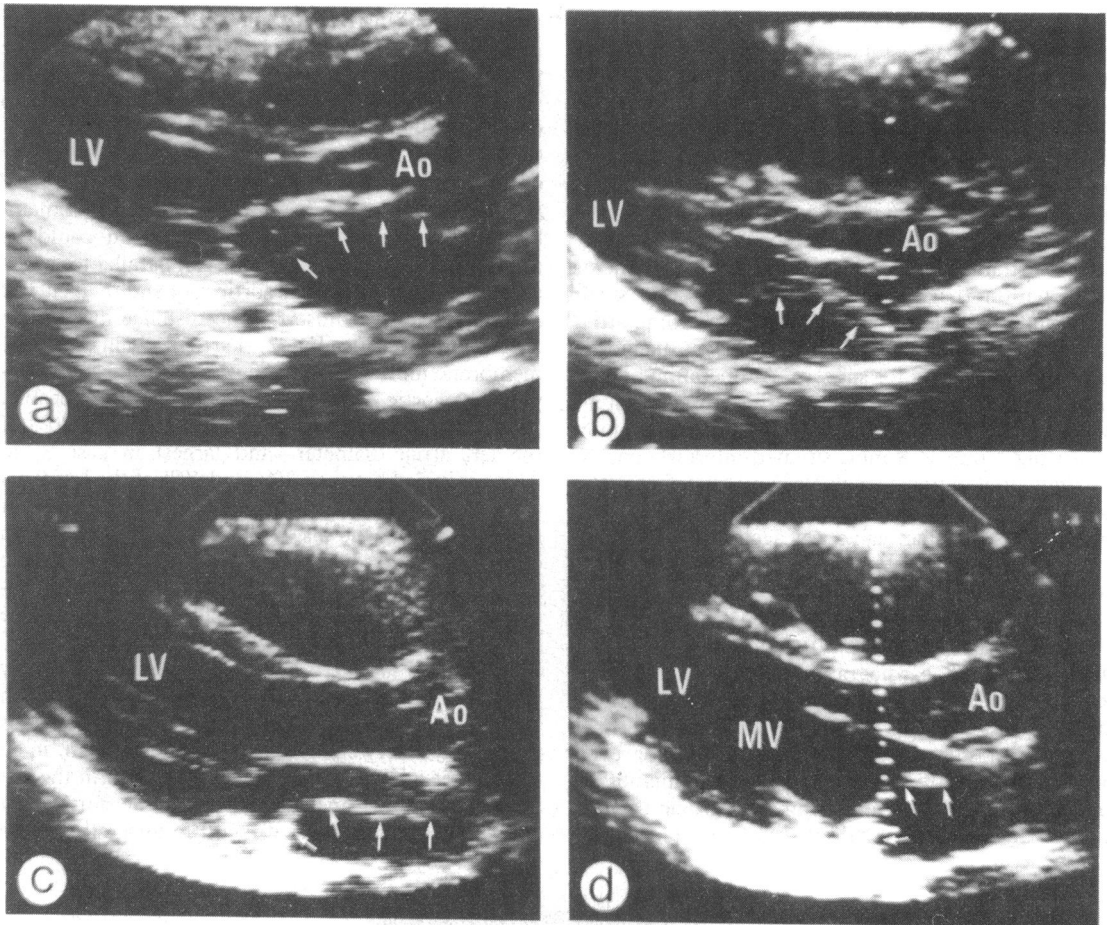


Fig. 2 Cross sectional echocardiographic appearances in the parasternal long axis view. (a) Case 1: the abnormal membrane within the left atrium is marked by small arrows; in this case the membrane was very thin. Although it is difficult to demonstrate on a freeze frame the movement towards the mitral valve funnel in diastole made it easier to identify the membrane as a definite intra-atrial structure when viewed in real time. (b) Case 2: the massively enlarged right ventricle distorts the appearances in this view causing the interventricular septum to bulge into the left ventricular outflow tract virtually touching the anterior leaflet of the mitral valve. The abnormal membrane (small arrows) is thicker and easily seen. (c) and (d) show the appearances in case 3 in end systole and diastole respectively. The abnormal membrane (small arrows), which again is fairly thick, moves anteriorly, closer to the aortic root during diastole. In all three cases the proximal left atrium—that is, the part of the left atrium receiving the pulmonary veins—is posterior and inferior to the distal left atrium, with the latter creating a recess behind the aortic root. Ao, aorta; MV, mitral valve; LV, left ventricle.

of the membrane on a freeze frame, in real time it was clear that the membrane was continuous and that at the aortic level medially it arched posteriorly to join the atrial septum. At the aortic cusp level the distance between the membrane and the aortic root again ranged from 20% to 40% of the left atrial diameter, but on scanning towards the left ventricle the membrane gradually became more posterior; in case 3 the proximal left atrial chamber also became more medial with an increasingly oblique membrane the more anterior the echocardiographic plane.

Parasternal and apical four chamber views—In both cases 1 and 2 the right ventricle was considerably enlarged and formed the apex, whereas the left ventricle was very small; and in both cases the membrane was better imaged in a parasternal rather than an apical four chamber view. In case 3, on the other hand, the membrane and its relation with the mitral valve and the left atrial appendage was well seen in the apical four chamber view (Fig. 4). In all three cases the left atrial appendage was distal to the membrane, and the pulmonary veins joined a common pulmonary

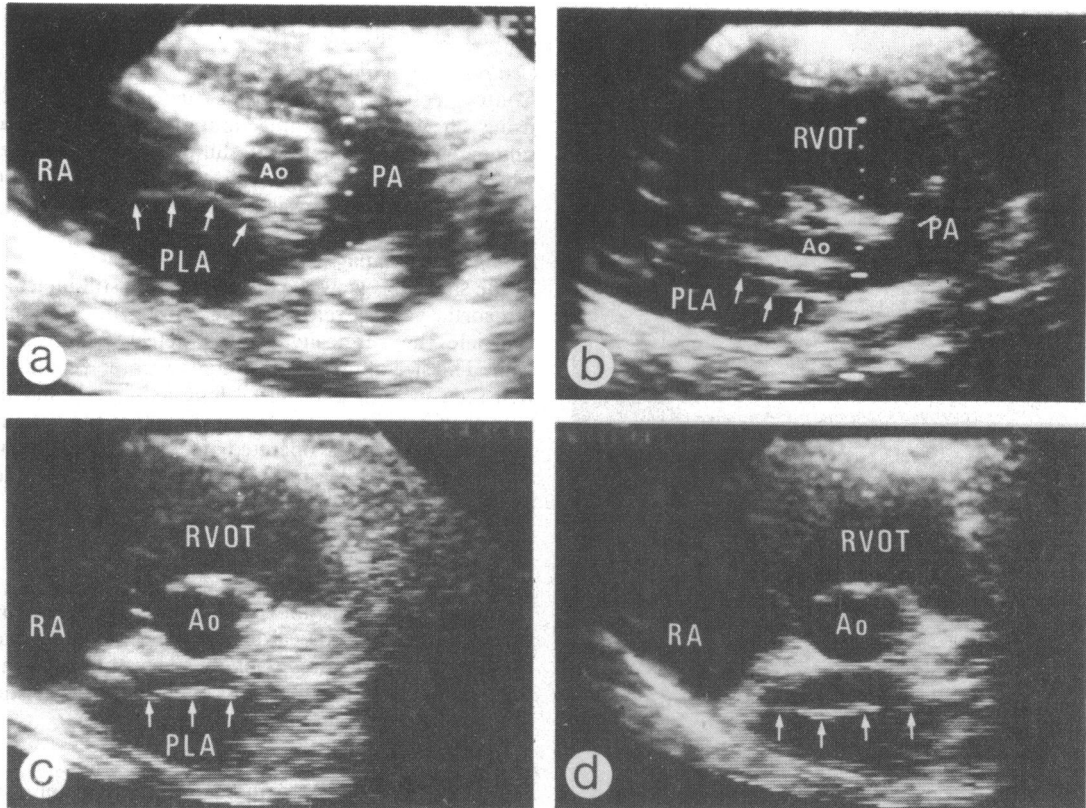


Fig. 3 Cross sectional echocardiographic appearances in the parasternal short axis view. (a) Case 1: the abnormal membrane (small arrows) within the left atrium is quite close to the aortic root with the enlarged proximal left atrium posterior to it, but the small recess of the distal left atrium behind the aorta can still be seen at the aortic valve level. The aorta is small and the pulmonary artery enlarged. (b) Case 2: again the abnormal membrane (small arrows) anterior to the proximal left atrium is well seen at the aortic valve level. The aorta is small and the right ventricular outflow tract and the pulmonary artery notably enlarged. (c) and (d) (case 3) show the variation in the position of the abnormal membrane (small arrows) during the cardiac cycle. The aorta is of normal size. Ao, aorta; PA, pulmonary artery; RA, right atrium; PLA, proximal left atrium; RVOT, right ventricular outflow tract.

venous chamber proximal to the membrane. The orifice in the membrane was difficult to image; in case 1 no consistent defect was seen in the membrane, but in cases 2 and 3 suggestive defects were seen (Fig. 5) and in both instances these defects were in a fairly inferior and medial—that is, right sided—location. In case 3 the membrane had the shape of a single arch, whereas in both cases 1 and 2 the membrane had a peculiar double arch appearance. In case 3 the more inferior the echocardiographic cut the more medial the pulmonary venous chamber became, and eventually it projected slightly to the right of the plane of the interventricular septum (Fig. 5b). In case 3 a membrane like structure was seen also in the right atrium, which in inferior echocardiographic cuts was attached to the atrial septum and crossed the right atrium transversely; however, in more anterior cuts this

structure was no longer visible and was thought to represent a prominent eustachian valve (Fig. 4c).

Subcostal views—Sagittal and transverse views were used to determine the situs, which in all three cases was solitus.⁵ In case 2 a very prominent eustachian valve was noted. The subcostal short axis views did not show the membrane well, but in cases 1 and 2 they confirmed the gross enlargement of the right ventricle and the comparatively small left ventricle. The subcostal four chamber view showed the membrane with its peculiar double arch configuration well in both cases 1 and 2 (Fig. 5c and d), and was the optimal view for looking at the atrial septum.

Suprasternal notch views—In all three cases a normal innominate vein and right superior vena cava was found, and in cases 1 and 2 enlargement of the main and right pulmonary artery was confirmed, and a

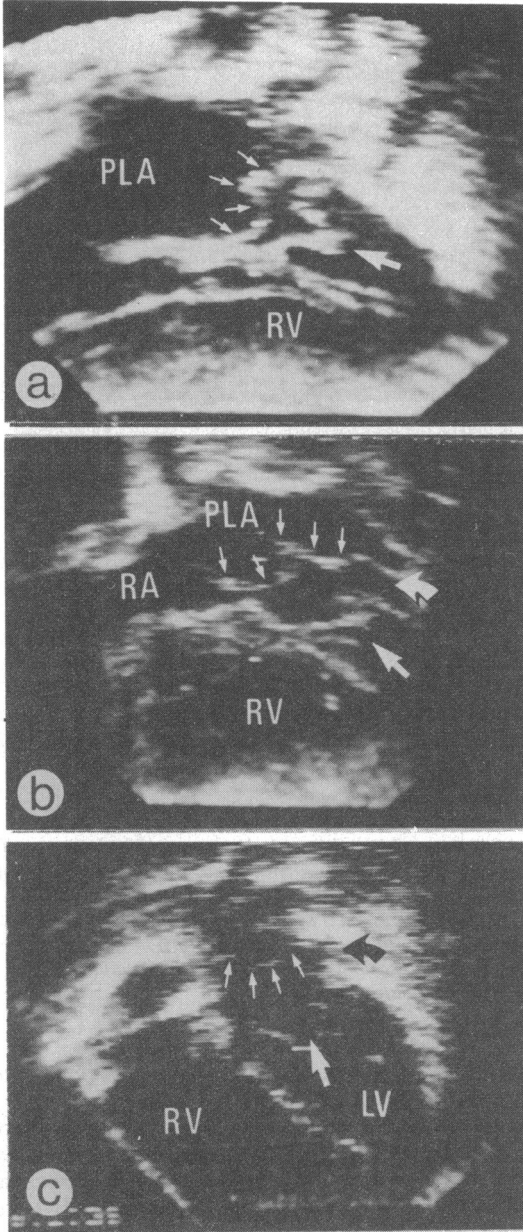


Fig. 4 Cross sectional echocardiographic appearances in four chamber views. (a) Case 1: in a parasternal four chamber view the abnormal membrane (small arrows) within the left atrium is seen to have a double arch appearance. (b) Case 2: a parasternal four chamber view again shows a double arch appearance of the membrane (small arrows), and the left atrial appendage (curved arrow) is seen to be distal to the membrane. (c) Case 3: in the apical four chamber view the pulmonary veins can be seen entering the proximal left atrium at the top of the picture; the membrane (small arrows) has a single arch appearance, and again the left atrial appendage (dark curved arrow) is seen to be distal to the membrane. In all parts of the figure thick straight arrows point to the mitral valve. PLA, proximal left atrium; RA, right atrium; RV, right ventricle; LV, left ventricle.

normal aortic arch evident.

Contrast echocardiography

Contrast echocardiography was carried out in case 2, using an intravenous injection of 2 ml of normal saline. A small right to left shunt at the atrial level which appeared to occur distal to the membrane within the left atrium was evident.

Postoperative findings

In the short axis view the membrane was still intact at the aortic valve level, but on scanning into the left ventricle the surgically created defect was readily seen. The size of the defect in the membrane could be well seen in both parasternal long axis views and in four chamber views, and it was clear that the patient in case 1, who was operated on using a left atrial approach, had had a more extensive removal of the membrane.

Discussion

In these three cases the patients were referred for surgery without prior cardiac catheterisation on the basis of clinical features strongly suggesting left ventricular inflow obstruction and of their characteristic echocardiographic findings.

ANATOMY

In their review of the pathological anatomy of cor triatriatum van Praagh and Corsini pointed out that the chamber into which the pulmonary veins drain—that is, the proximal left atrium—is dorsal and obliquely inferior to the ventral left atrial chamber—that is, the distal left atrium—with the subdividing membrane bulging upward and anteriorly⁶; all these features were well shown with cross sectional echocardiography in our cases. This fact is not universally appreciated, as even some textbooks claim that the proximal left atrial chamber is posterior and superior.¹ Van Praagh and Corsini also found that the most common site for a single defect in the membrane was inferior and medial occurring a short distance behind the posteromedial commissure of the mitral valve,⁶ which corresponds well to the apparent defects seen in the membrane in cases 2 and 3. Another point of interest in their study was that embryologically the common pulmonary vein arises as a mid-line outgrowth from the primitive atrium and that when enlarging it grows out from the most rightward, inferior, and posterior corner of the left atrium; this may explain why the common pulmonary venous chamber may be as notably right sided as seen in case 3. In terms of classification, all our cases fitted into the subgroup termed type A by Thilenius *et al.* in their expanded classification⁷—that is, a classical cor triatriatum with a funnel shaped posteroinferior proximal

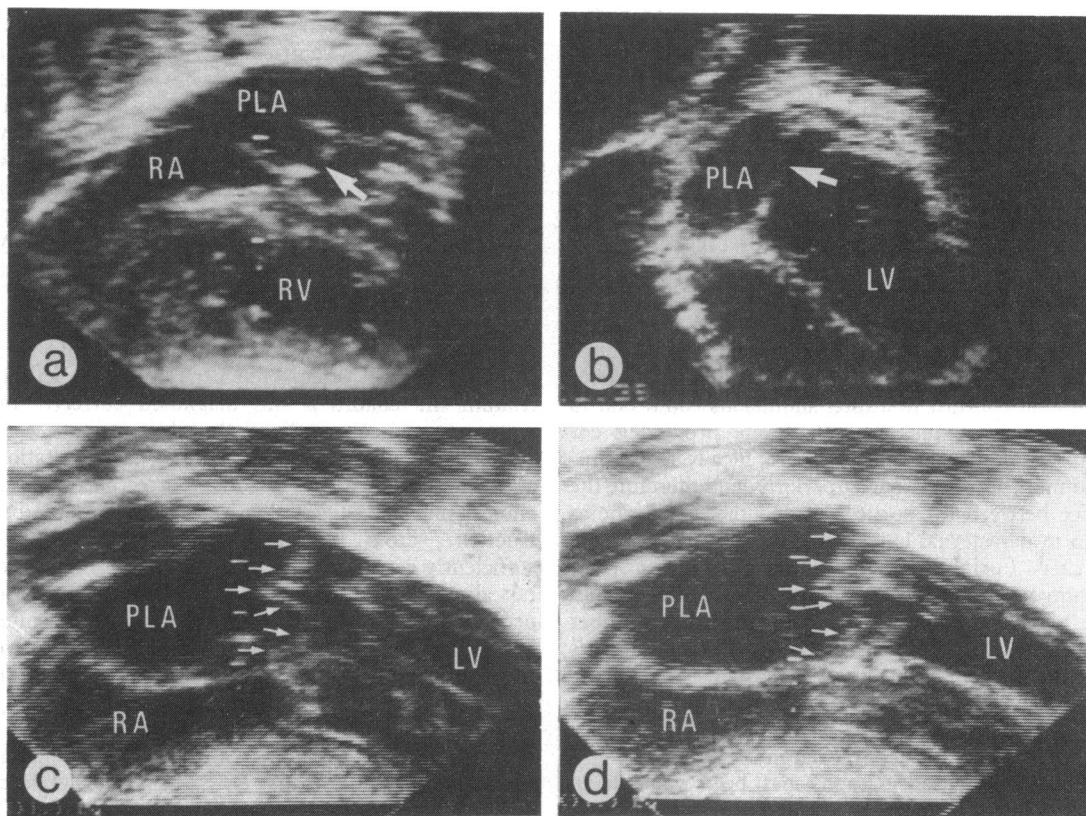


Fig. 5 Cross sectional echocardiographic appearances in four chamber view. (a) Case 2: inferior echocardiographic plane in parasternal four chamber view shows (arrow) an apparent defect in the membrane. (b) Case 3: inferior plane of an apical four chamber view, shows (arrow) an apparent defect in the membrane. It is noteworthy that the proximal left atrium extends so far medially that it is to the right of the interventricular septum. (c) and (d) case 1 in the subcostal four chamber view show the membrane (small arrows) moving into the mitral valve funnel in diastole and again a distinct double arch appearance. The medial arch of the membrane shows two minor areas of dropout in the same position as the defect seen in case 2. PLA, proximal left atrium; RA, right atrium; RV, right ventricle; LV, left ventricle.

chamber. In type B there is an inferior, wedge shaped mid-line chamber receiving the pulmonary veins, in association with a rudimentary coronary sinus, and in type C there is a superior mid-line chamber, not receiving any pulmonary veins and separate from a normal coronary sinus; the latter two types are exceedingly rare.⁷

FEATURES ON M MODE ECHOCARDIOGRAPHY

There are several previous publications reporting the M mode echocardiographic appearances of cor triatriatum, and they all find a linear echo within the left atrium behind the aortic root,⁸⁻¹⁰ and in some cases this echo shows a movement resembling a stenotic mitral valve as in our case 3.¹⁰ It is noteworthy that in all the published pictures the abnormal echo lies anteriorly within the left atrium, as in our cases. This

is helpful in the differential diagnosis as both the linear echo sometimes seen "within" the left atrium in total anomalous pulmonary venous drainage and the artefactual echoes sometimes seen in the left atrium tend to be more posterior.

FEATURES ON CROSS SECTIONAL ECHOCARDIOGRAPHY

The cross sectional echocardiographic findings in cor triatriatum are quite characteristic. When detected in multiple planes of examination the membrane can easily be distinguished from artefacts. Its position within the left atrium is typical and may be differentiated from that of a supralvalvar mitral ring, which occurs exclusively within the mitral valve funnel with the membrane distal to the left atrial appendage in contradistinction to cor triatriatum. Furthermore, a sup-

ravalvar ring lacks a superior recess behind the aortic root. It is also possible that cor triatriatum may be confused with total anomalous pulmonary venous connexion to the coronary sinus. Although both conditions show an apparent "membrane" in the left atrium, the position and the course of the membrane are different. In total anomalous pulmonary venous connexion the echo from the enlarged coronary sinus/pulmonary venous confluence can be seen in several planes.¹¹ The apparent "membrane" arises in the atrioventricular groove immediately posteriorly and superiorly to the posterior mitral valve leaflet, and the course can be defined by a combination of parasternal long axis and posterior apical four chamber views. In contrast to a total anomalous connexion to the coronary sinus, the membrane producing cor triatriatum appears echocardiographically to be situated more anteriorly and superiorly, and therefore the space between the aortic root and the membrane as seen in parasternal long axis and short axis planes is smaller. Furthermore, the membrane of cor triatriatum arches towards the mitral valve funnel both in the parasternal long axis and in the four chamber views, and the convexity of the membrane becomes especially prominent when seen in diastole in real time recordings. When a double arch appearance of the membrane is present this would appear to be pathognomonic for cor triatriatum.

Contrast echocardiography has been valuable in certain circumstances to exclude the presence of total anomalous venous connexion by failing to demonstrate an obligatory right to left shunt at the atrial level,¹¹ as would a normal hyperoxic test.¹² In the presence of an atrial septal defect or patent foramen ovale distal to the membrane, however, these techniques may fail to differentiate between cor triatriatum and total anomalous pulmonary venous drainage.

In the only other accounts to our knowledge of cross sectional echocardiographic appearances of cor triatriatum two cases with a single arch similar to our case 3 were reported.^{13 14} Nevertheless, neither the membrane behind the aortic root nor a double arch appearance of the membrane in four chamber views has previously been described.

CLINICAL PRESENTATION

The clinical presentation of our cases deserves comment. None had the "classical" murmurless heart, either because of a coexisting atrial septal defect or because of tricuspid regurgitation. All had signs of pulmonary hypertension with pulmonary venous congestion on the plain chest x ray film and minimal, if any, cardiomegaly, which suggests either a left ventricular inflow obstruction or an obstructed normal or anomalous pulmonary venous drainage. An elec-

trocardiographic finding of note was that in addition to evidence of right ventricular hypertrophy both our infants had electrocardiographic evidence of right atrial but not of left atrial hypertrophy. Right atrial hypertrophy was present in all hearts examined by van Praagh and Corsini,⁶ as was enlargement of the proximal left atrial chamber; however, of the walls of this chamber only the oblique anterosuperior membrane contains cardiac muscle,⁶ which presumably explains the absence of electrocardiographic features of left atrial hypertrophy.

CONCLUSIONS

In conclusion, in three consecutive cases of cor triatriatum the condition was diagnosed correctly by cross sectional echocardiography. The patients were referred for surgery without cardiac catheterisation and the diagnosis proved to be correct. When the clinical findings suggest left ventricular inflow obstruction, cross sectional echocardiography is sufficiently accurate that cardiac catheterisation need not always be performed. Cor triatriatum may also occur as a silent association with complex congenital heart disease,^{14 15} and in such instances preoperative recognition of the cor triatriatum may influence the surgical approach.

We are very grateful to Dr D G Gibson for making his equipment available to us. IÖ-S thanks the Oxford Regional Health Authority for support during an off-service year. We thank Dr G Sutton for permission to present his case (No 3) in this paper.

References

- 1 Keith JD, Rowe RD, Vlad P. *Heart disease in infancy and childhood*. 3rd ed. New York: Macmillan, 1978.
- 2 Snider AR, Rogé CLL, Schiller NB, Silverman NH. Congenital left ventricular inflow obstruction evaluated by two-dimensional echocardiography. *Circulation* 1980; **61**: 848-55.
- 3 Tajik AJ, Seward JB, Hagler DJ, Mair DD, Lie JT. Two-dimensional real-time ultrasonic imaging of the heart and great vessels: technique, image orientation, structure identification and validation. *Mayo Clin Proc* 1978; **53**: 271-303.
- 4 Silverman NH, Snider AR. *Two-dimensional echocardiography in congenital heart disease*. Englewood Cliffs, NJ: Appleton Century Crofts, 1982.
- 5 Huhta JC, Smallhorn JF, Macartney, FJ. Cross-sectional echocardiographic diagnosis of situs. *Br Heart J* 1982; **48**: 97-108.
- 6 Van Praagh R, Corsini I. Cor triatriatum: pathologic anatomy and a consideration of morphogenesis based on 13 postmortem cases and a study of normal development of the pulmonary vein and atrial septum in 83 human embryos. *Am Heart J* 1969; **78**: 379-405.
- 7 Thilenius OG, Bharati S, Lev M. Subdivided left atrium:

- an expanded concept of cor triatriatum sinistrum. *Am J Cardiol* 1976; **37**: 743–52.
- 8 Lundström N-R. Ultrasoundcardiographic studies of the mitral valve region in young infants with mitral atresia, mitral stenosis, hypoplasia of the left ventricle, and cor triatriatum. *Circulation* 1972; **45**: 324–34.
 - 9 Gibson DG, Honey M, Lennox SC. Cor triatriatum: diagnosis by echocardiography. *Br Heart J* 1974; **36**: 835–8.
 - 10 Bett JH, Graff RF, Stafford EG, Dryburgh L. Echocardiographic diagnosis of cor triatriatum. *Aust NZ J Med* 1978; **8**: 428–30.
 - 11 Snider AR, Ports TA, Silverman NH. Venous anomalies of the coronary sinus detection by M-mode, two-dimensional and contrast echocardiography. *Circulation* 1979; **60**: 721–7.
 - 12 Jones WA, Baumer JH, Joseph MC, Shinebourne EA. Arterial oxygen tension and the response to oxygen breathing in differential diagnosis of congenital heart disease in infancy. *Arch Dis Child* 1976; **51**: 667–73.
 - 13 Silverman NH, Schiller NB. Apex echocardiography. A two-dimensional technique for evaluating congenital heart disease. *Circulation* 1978; **57**: 503–11.
 - 14 Jacobstein MD, Hirschfeld SS. Concealed left atrial membrane: pitfalls in the diagnosis of cor triatriatum and supra valve mitral ring. *Am J Cardiol* 1982; **49**: 780–6.
 - 15 Thilenius OG, Vitullo D, Bharati S, *et al.* Endocardial cushion defect associated with cor triatriatum sinistrum or supra valve mitral ring. *Am J Cardiol* 1979; **44**: 1339–43.