

Ankylosing spondylitis and an aortic arch syndrome

R G HULL, * R A ASHERSON, † J A N RENNIE*

From the *Department of Rheumatology, City Hospital, Aberdeen; and the †Rheumatology Unit, Royal Postgraduate Medical School, Hammersmith Hospital, London

SUMMARY A 63 year old woman with a 16 year history of ankylosing spondylitis and peripheral joint involvement later presented with a large vessel arteritis affecting the branches of the arch of the aorta.

Cardiovascular complications of ankylosing spondylitis are well recognised. Most often they appear clinically as aortic incompetence and more rarely as cardiac conduction defects.^{1,2} Arteritis of large vessels such as the branches of the arch of the aorta is rare. We report the case of a patient with ankylosing spondylitis with peripheral joint involvement in whom an arteritis later developed affecting the subclavian and vertebral arteries. Although the aortic wall appeared slightly thickened on an echocardiogram, the aortic valve was normal.

Case report

A 63 year old woman first presented in October 1967 at the age of 47 years with left sacroiliac pain and local tenderness. Pelvic x ray findings and an erythrocyte sedimentation rate were normal. In December 1975 she developed low backache radiating to the buttocks. The erythrocyte sedimentation rate was 120 mm/first hour with a normal blood count. The Rose-Waaler and rheumatoid arthritis latex test results were negative, and x ray films of the spine and pelvis showed no abnormality.

In February 1976 she developed a generalised illness with myalgia, malaise, stiffness of her shoulders and hips, and back pain radiating to the thighs. She had a systolic murmur over the aortic area radiating to the neck. Apart from a proximal weakness there were no other neurological signs. Her haemoglobin concentration was 10.6 g/dl; white blood cell count was $13.9 \times 10^9/l$ and the film showed rouleaux with a normochromic normocytic anaemia. The erythrocyte sedimentation rate was 108 mm/first hour. Serum pro-

tein concentrations and protein electrophoresis were normal. She remained seronegative; Paul Bunnell, brucella, and viral studies were negative. Antinuclear antibodies were absent. X ray films of the pelvis showed calcification at the insertion of the hip adductors.

Treatment with prednisolone was started, but two years later she developed pain, stiffness, and swelling of the finger joints of both hands, and effusions of both knees, suggesting that the episode of 1976 was a myalgic onset of a seronegative arthritis. In October 1978 she was admitted because of pain in her left hip, knees, and hands. There was reduced internal rotation of both hips and swelling of the proximal interphalangeal joints of her hands. The blood pressure in the right arm was 120/80 mm Hg. Her erythrocyte sedimentation rate remained raised, and her serological tests remained negative. X ray films showed joint space narrowing in the metacarpophalangeal joints and erosions of both ulnar styloids. There was also joint space narrowing in the left hip and sclerosis of the sacroiliac joints with possible erosions. There was osteophytic lipping between the third and fourth lumbar vertebrae. She was treated with indomethacin.

In 1979 she had an episode of vaginal bleeding and was subsequently found to have an adenocarcinoma of the uterus. This was treated by hysterectomy and postoperative radiotherapy. There has been no clinical evidence of recurrence. Over the next two years she had an episode of tenosynovitis of the flexor tendons of the right hand and also pain in her left subtalar joint. Her left hip continued to be painful and further x ray films showed sclerosis and joint space narrowing with lesser changes on the right. The sacroiliac joints showed periarticular sclerosis with erosive changes, and her lumbar spine showed syndesmophytes consistent with the diagnosis of ankylosing spondylitis (Fig. 1).

Requests for reprints to Dr R G Hull, Rheumatology Unit, Royal Postgraduate Medical School, Hammersmith Hospital, Du Cane Road, London W12 0HS.

In October 1981 at the age of 61 years she developed pain in her arms while wringing out some washing. The pain in her right arm continued, and

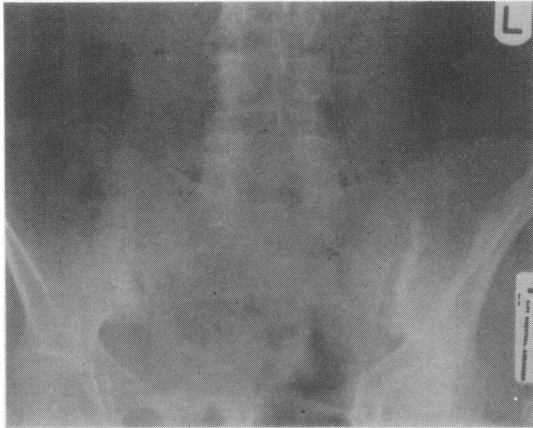


Fig. 1 Radiograph of pelvis showing sacroiliitis and lumbar syndesmophytes.

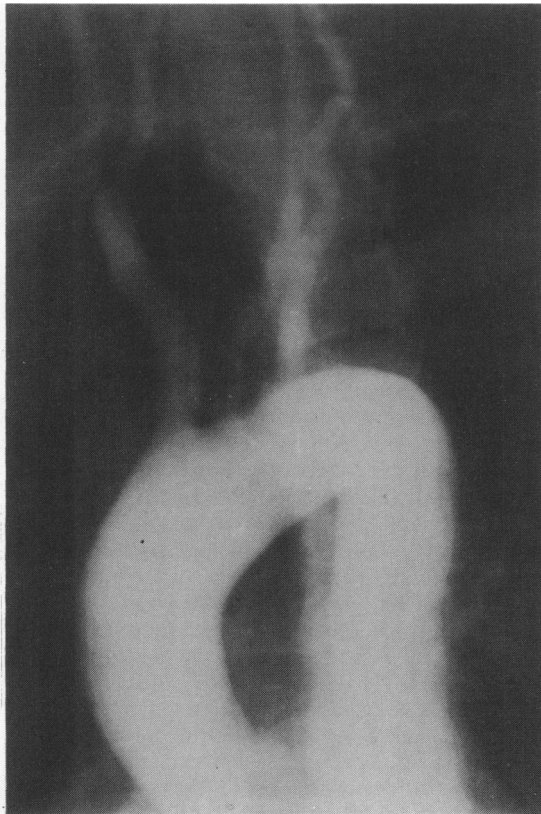


Fig. 2 Arch aortogram showing absence of filling of the subclavian arteries and narrowing of the origins of the vertebral arteries.

her hands felt cold. No subclavian, brachial, or wrist pulses could be felt. All other pulses were present. Her arms were warm and appeared adequately perfused. By January 1982 she had developed bilateral claudication of the forearms with delayed capillary filling. The erythrocyte sedimentation rate was 150 mm/first hour. An arch aortogram showed occlusion of both subclavian arteries beyond the origin of the vertebral arteries. The vertebral arteries themselves showed considerable narrowing at their origins (Fig. 2). The carotid arteries were normal. There were poor collateral channels with no evidence of vessel filling distal to the block. These changes were consistent with an aortic arch syndrome. She was treated medically with aspirin.

She was again admitted in September 1982 with increasing pain in her left hip. The aortic murmur was unchanged but she had developed bruits in both carotid arteries. An echocardiogram showed some thickening of the aortic wall, but the aortic valve was normal and there was no evidence of stenosis. There was reduced movement of the distal and proximal interphalangeal joints. Hip movements were reduced. The haemoglobin concentration was 10.6 g/dl; white blood cell count $10.5 \times 10^9/l$ and platelet count $851 \times 10^9/l$. The erythrocyte sedimentation rate was 115 mm/first hour, and she remained seronegative. In November 1982 she had a left total hip replacement. Blood pressure during the operation was monitored with a thigh cuff and a Doppler method. Histology of the joint capsule showed extensive synovial damage with a fibrinous inflammatory exudate overlying granulation tissue. She was typed for the HLA antigens and showed A28, Aw19, B5, and B40.

Discussion

Cardiac manifestations of ankylosing spondylitis in the form of aortic and mitral valvular disease and heart block have been well documented.^{1,2} Involvement distal to the aortic root has, however, been reported only rarely.³⁻⁶ Ankylosing spondylitis in association with an aortic arch syndrome has been reported by Paloheimo *et al*⁷ in four patients and Ghozlan *et al*⁸ in one (Table).

Although these patients were described as having Takayasu's arteritis, a disease generally of young women,⁹ they include a man of 46 years. Our patient was 61 years old at onset, whereas the other women were aged less than 25 years. The older age of our patient and the history of a myalgic episode at the onset of her arthritis raises the possibility of a giant cell arteritis. The two diseases may be difficult to differentiate histologically,¹⁰ but the subsequent joint involvement does not favour giant cell arteritis. The delay between the onset of the arteritis and the

Table Reported cases of ankylosing spondylitis and an aortic arch syndrome

Author (Case No)	Sex	Age (yr)	Arterial stenosis and murmurs	Changes on radiology	ESR (mm/h)	Delay in arteritis after arthritis (yr)
Paloheimo <i>et al</i>						
1	M	46	Both subclavian, left carotid, both vertebral, both renal	Sacroiliitis, syndesmophytes, lumbar spine, peripheral joints	67	4
2	F	24	Right subclavian, systolic murmur	Sacroiliitis	112	3
3	F	25	Both subclavian, both carotid, systolic murmur	Sacroiliitis, lumbar spine	20-120	4
4	F	24	Both subclavian, left vertebral, both carotid	Sacroiliitis, lumbar spine	74	No arthritis
Ghozlan <i>et al</i>						
5	F	22	Left subclavian, left vertebral, left carotid, left renal	Sacroiliitis, knees	30	3
Present case						
6	F	61	Both subclavian, both vertebral, systolic murmur	Sacroiliitis, lumbar spine, peripheral joints	115	3

development of joint symptoms was 3-4 years in all but one case. All cases except one had a raised erythrocyte sedimentation rate during the acute phase of the arteritis. Most had characteristic systemic symptoms. Three patients developed sacroiliitis concurrently with the arteritis and, in two, these features were asymptomatic. It is apparent that some patients develop sacroiliitis concurrently with the systemic phase of the arteritis, whereas others may manifest an arteritis several years after the onset of their ankylosing spondylitis. Our patient was negative for the HLA B27 antigen, and it is of interest that the only other case tissue typed was also negative for this antigen.⁸

A patient has recently been reported with a seronegative spondyloarthropathy presenting with Reiter's syndrome and sacroiliitis, who subsequently developed a histologically confirmed aortitis proximal to the aortic bifurcation.¹¹ Eighteen months later after surgical excision and grafting the patient developed a large joint arthritis and sacroiliitis. Aortic arch syndromes have also been associated with rheumatoid arthritis in the past.¹²⁻¹³ Our patient showed evidence of an arteritis of the major arch vessels, lumbar syndesmophytes, and sacroiliitis. She also had a symmetrical peripheral arthritis with erosion of the ulnar styloid. Although this would suggest rheumatoid arthritis, erosions have been reported in seronegative spondyloarthropathies including ankylosing spondylitis¹⁴ and do not preclude the diagnosis.

Joint pains and synovitis may occur with the onset of the acute phase of the arteritic disease and is estimated by Serre *et al* to occur in 25% of cases.¹⁵ This present case represents the sixth case of ankylosing spondylitis in association with an aortic arch syndrome presumed to be inflammatory in origin.

References

- 1 Clark WS, Kulka JP, Bauer W. Rheumatoid aortitis with aortic regurgitation. An unusual manifestation of rheumatoid arthritis (including spondylitis). *Am J Med* 1957; 22: 580-92.
- 2 Ansell BM, Bywaters EGL, Doniach I. The aortic lesion of ankylosing spondylitis. *Br Heart J* 1958; 20: 507-15.
- 3 Toone EC Jr, Pierce EL, Hennigar GR. Aortitis and aortic regurgitation associated with rheumatoid spondylitis. *Am J Med* 1959; 26: 255-63.
- 4 Duvernoy WFC, Schatz J. Rheumatoid spondylitis associated with aneurysmal dilatation of the entire thoracic aorta. *Henry Ford Hospital Medical Bulletin* 1966; 14: 309-12.
- 5 Ball GV, Hathaway B. Ankylosing spondylitis with widespread arteritis. *Arthritis Rheum* 1966; 9: 737-45.
- 6 Somer T, Siltanen P. Aneurysm of the descending thoracic aorta, amyloidosis and renal carcinoma in a patient with ankylosing spondylitis. *Am J Med* 1970; 49: 408-15.
- 7 Paloheimo JA, Julkunen H, Siltanen P, Kajander A. Takayasu's arteritis and ankylosing spondylitis: report of four cases. *Acta Med Scand* 1966; 179: 77-85.
- 8 Ghozlan R, Amor B, Debarre F. Association d'une maladie de Takayasu et d'une spondylarthrite ankylosante, un nouveau cas. *Ann Med Interne (Paris)* 1977; 128: 959-63.
- 9 Ross RS, McKusick VA. Aortic arch syndromes. *Arch Intern Med* 1953; 92: 701-40.
- 10 Lande A, Berkmen YM. Aortitis: pathologic, clinical and arteriographic review. *Radiol Clin North Am* 1976; 14: 219-40.
- 11 Morgan SH, Asherson RA, Hughes GRV. Distal aortitis complicating Reiter's syndrome. *Br Heart J* 1984 (in press).
- 12 Sandring H, Welin G. Aortic arch syndrome with special reference to rheumatoid arteritis. *Acta Med Scand* 1961; 170: 1-19.
- 13 Falivoc RE, Cooney DF. Takayasu's arteritis and rheumatoid arthritis. *Arch Intern Med* 1964; 114: 594-600.
- 14 Bluestone R. Seronegative polyarthritis. In: Cohen AS, ed. *Rheumatology and immunology*. New York: Grune and Stratton, 1979: 210-5.
- 15 Serre H, Simon L, Lamboley C. Les manifestations articulaires de la maladie de Takayasu. *Sem Hop Paris* 1970; 46: 1587-602.