

## Case reports

# Distal aortitis complicating Reiter's syndrome

S H MORGAN, R A ASHERSON, G R V HUGHES

*From the Department of Rheumatology, Royal Postgraduate Medical School, Hammersmith Hospital, London*

**SUMMARY** Distal aortitis was diagnosed in a 44 year old man who had previously shown clinical features of Reiter's syndrome. This appears to be the first reported case of distal aortitis associated with Reiter's syndrome.

Aortitis complicating seronegative spondyloarthritis, particularly Reiter's syndrome, is well recognised. The sites usually involved are the aortic ring and ascending aorta. We report a case of distal aortitis and Reiter's syndrome—a combination not previously documented.

### Case report

A 44 year old white man was admitted in 1980 for vascular surgery with an 18 month history of bilateral calf claudication, which restricted mobility to 200 yards. Examination showed weak femoral pulses but no palpable pulses below this. Other peripheral pulses were all intact. He was a non-smoker, and all tests to exclude conditions such as hypercholesterolaemia and diabetes mellitus had normal results, as did clotting tests and an electrocardiogram.

Translumbar aortography (Figure a) showed pronounced stenosis of the distal 3 cm of the aorta, and he underwent aortoiliac bypass grafting. At operation there was considerable periaortitis, and subsequent histology (Figure b) confirmed an underlying aortitis. Serological test results for syphilis were all negative.

His postoperative course was uncomplicated, but he was referred for rheumatological advice in 1982 having developed increasingly severe joint pains, which had first started in 1978 when he developed metatarsalgia. Painful swelling of his knees and ankles occurred intermittently together with low back pain, circinate balanitis, and aphthous ulceration. There had been some grittiness of his eyes and a rash on the soles of his feet, which were typical of keratoderma blenorrhagica.

There were no bowel symptoms, no history of psoriasis, and no previous episodes of urethritis.

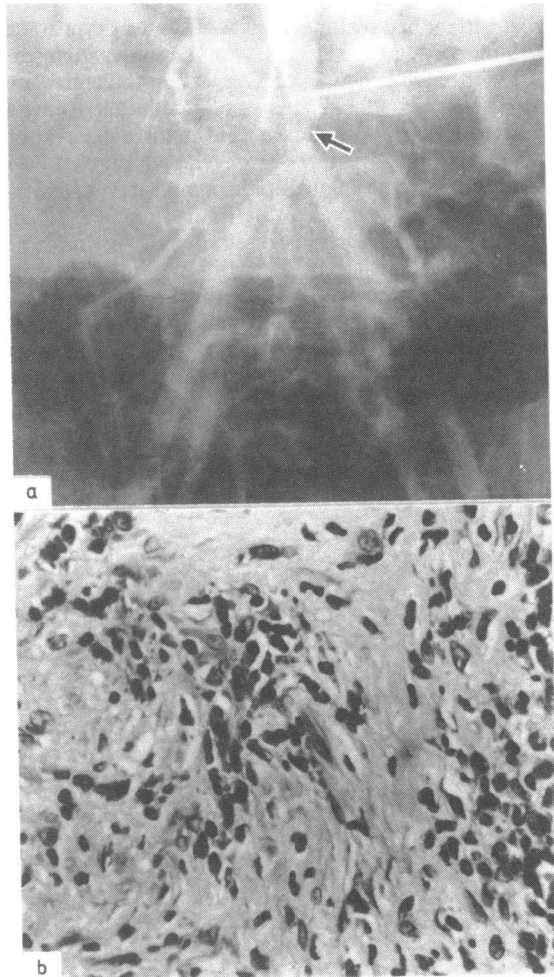


Figure (a) Translumbar aortogram showing distal aortic narrowing (arrow) proximal to bifurcation and (b) histological section of aorta showing aortitis. Haematoxylin and eosin  $\times 400$  original magnification.

Requests for reprints to Dr S H Morgan, Department of Rheumatology, Royal Postgraduate Medical School, Hammersmith Hospital, Du Cane Road, London W12 0HS.

An isotopic bone scan (technetium-99m) confirmed active synovitis, although joint radiology did not show any destructive changes. Radiographs of the sacroiliac joints showed some sclerosis and loss of joint space, but all other investigations were normal except for a rapid erythrocyte sedimentation rate (65 mm/first hour). Tissue typing was A<sub>1</sub>, A<sub>26</sub>, BW<sub>42</sub>, CW<sub>3</sub>, DR<sub>4</sub>.

To date there has been no clinical recurrence of the aortitis, but as his arthritis had not responded to conventional treatment with non-steroidal anti-inflammatory drugs more aggressive treatment with methotrexate was given resulting in remission symptoms.

### Discussion

This patient had features typical of Reiter's syndrome with mucocutaneous lesions, conjunctivitis, and arthritis with sacroiliac disease. These clinical features are consistent with the diagnosis of "definite" Reiter's syndrome as proposed in a recent report.<sup>1</sup> Soon after the onset of these features he developed calf claudication leading to the angiographic demonstration of aortic narrowing proximal to the bifurcation. Histologically this was a clearly localised area of aortitis. The association of distal aortitis with Reiter's syndrome has not to our knowledge been previously reported, although aortic regurgitation and ascending aortitis have been documented, occurring with a frequency of 2.5%.<sup>2</sup>

The inter-relation of Reiter's syndrome to ankylosing spondylitis and psoriatic arthropathy have been reviewed recently,<sup>3</sup> and distal aortic involvement similar to that in our patient occurred in one patient with ankylosing spondylitis emphasising the close "overlap" between the seronegative spondyloarthropathies.<sup>4</sup> The aortitis occurring in these seronegative diseases is histologically non-specific unlike that in rheumatoid disease. This bears a resemblance to Takayasu's aortitis, and indeed a Takayasu syndrome has been described in patients with rheumatoid arthritis although infrequently.<sup>5</sup>

### References

- 1 Wilkens RF, Arnett FC, Bitter T, *et al.* Reiter's syndrome—evaluation of preliminary criteria for definite disease. *Bull Rheum Dis* 1983; 32: 31–4.
- 2 Csonka GW, Litchfield JW, Oates JK, Willcox RR. Cardiac lesions in Reiter's disease. *Br Med J* 1961; i: 243–7.
- 3 Good AE. Reiter's disease. A review with special attention to cardiovascular and neurologic sequelae. *Semin Arthritis Rheum* 1974; 3: 253–86.
- 4 Moll JMH. Seronegative arthropathies. *J R Soc Med* 1983; 76: 445–8.
- 5 Sandring H, Welin G. Aortic arch syndrome with special reference to rheumatoid arteritis. *Acta Med Scand* 1961; 170: 1–19.