

## Absent or occult pulmonary artery

PATRIZIA PRESBITERO,\* CATHERINE BULL,† SHEILA G HAWORTH,  
MARC R DE LEVAL

*From the Thoracic Unit, The Hospital for Sick Children, and the Department of Paediatric Cardiology, Institute of Child Health, London*

**SUMMARY** Of 12 patients with angiographically absent pulmonary artery, 11 were investigated surgically. The previously occult pulmonary artery was found in 10 patients, in five of whom a vestige of an intrapericardial artery was present and in five the artery was patent only at the hilus, a gap existing between the main pulmonary artery and the hilar vessel, and no artery was found in one. All patients with an intrapericardial artery had right ventricular outflow tract obstruction and a ductus descending vertically from underneath the aortic arch. In those without an intrapericardial vessel the occult artery was on the side opposite the aortic arch, and there was evidence of a ductus coming from the innominate artery on the side of the interruption. The occult pulmonary artery, where identified at operation, was usually joined initially to the systemic circulation. Ultimately, continuity between the hilar and main pulmonary artery may be established surgically. Where no intrapericardial vessel exists, however, a conduit may be required to bridge the gap.

It seems advisable to search for the occult artery as early in life as is feasible in the hope that providing a blood supply will ensure development of the vessel and normal lung growth.

The absence of a main branch of the pulmonary artery was first described by Frantzel in 1868.<sup>1</sup> Since then several cases of patients with and without intracardiac anomalies have been reported. In 1954 McKim and Wiglesworth<sup>2</sup> and later Sotomora and Edwards<sup>3</sup> pointed out that the distal portion and intrapulmonary vessels of the so called "absent pulmonary artery" are in fact usually present. McKim and Wiglesworth<sup>2</sup> also underlined an occasional relation between the absence of a pulmonary artery and the persistence of a ductus arteriosus on the same side as the interruption. Perfusion of the hilar pulmonary artery by a ductus, arising either from the aorta directly or from an innominate artery, was described as the distal ductal origin of the pulmonary artery by Sotomora and Edwards.<sup>3</sup>

We reviewed 12 patients with angiographic absence of a main branch of the pulmonary artery, all but one of whom were investigated surgically. We established

which part of the artery was absent, specifically whether it was the intrapericardial or the more distal part of the vessel near the hilus. The relation between the absent pulmonary artery and the ductus arteriosus was also considered as well as the embryological mechanism of this anomaly.

### Patients and methods

From 1973 to 1982, 12 patients with apparent absence of one pulmonary artery were seen at this hospital. We excluded from the study patients with an absent pulmonary artery who had pulmonary atresia and major aortopulmonary collateral arteries feeding the hilar and intrapulmonary arteries and those who had an aortic origin of one pulmonary artery (hemitruncus arteriosus). Also excluded were patients with agenesis of one lung. The age at which patients first came to our notice ranged from 5 days to 12 years.

All the patients underwent at least one angiographic examination, most having serial studies. In the search for the absent artery contrast medium was injected into both the right ventricle and the systemic circulation in all patients. In three patients, studied more recently, pulmonary venous wedge injections were also performed. All the angiograms were reviewed to

Requests for reprints to Dr M de Leval, Thoracic Unit, Hospital for Sick Children, Great Ormond Street, London WC1N 3JH.

\*Present address: Ospedale Molinette, Torino, Italy.

†Present address: The Brompton Hospital, Fulham Road, London SW3 6HP.

Accepted for publication 6 March 1984

Table *Angiographic data of 12 patients with absent pulmonary artery*

Case No	Intracardiac anatomy	Age at operation on absent artery	Affected pulmonary artery	Side of aortic arch	Intrapleural PA	Origin of ductus or dimple
1	Normal	—	L	R	?	Aorta
2	Normal	9 yr	R	L	—	R innom
3	LPV obstruction	1 yr	R	L	—	R innom
4	VSD	12 yr	L	R	—	L innom
5	VSD	3 yr	L	R	—	L innom
6	Fallot	1 yr	L	R	—	L innom
7	Fallot	6 mth	L	R	—	L innom
8	Fallot	9 yr	L	L	+	Aorta
9	Fallot	1 yr	L	L	+	Aorta
10	Fallot	5 d	L	L	+	Aorta
11	PA and IVS	3 yr	L	L	+	Aorta
12	UVH and PA	10 yr	L	L	+	Aorta

R, right; L, left; LPV, left pulmonary vein obstruction; PA, pulmonary atresia; IVS, intact ventricular septum; UVH, univentricular heart; innom, innominate artery; VSD, ventricular septal defect; —, absent; +, present.

determine the side of the aortic arch and the presence and origin of a ductus arteriosus or ductus dimple. Natural and surgically created alternative sources of blood supply to the affected lung were also documented. Eleven patients underwent at least one surgical procedure. The aim was to look for the absent pulmonary artery and, when found, to connect it to the main pulmonary artery or to the systemic circulation.

## Results

### RADIOLOGICAL FINDINGS

In patients with a normal intracardiac anatomy or a left to right intracardiac shunt, the chest x ray film showed that the lung on the affected side was smaller and had diminished pulmonary vascular markings compared with the contralateral lung (Fig. 1).

The affected pulmonary artery was on the opposite side of the aortic arch in seven patients (cases 1–7), and this was the right side in two patients (cases 2 and

3). These seven patients had a variable intracardiac anatomy, some having a normal heart, some a left to right shunt, and others a low pulmonary blood flow (Table). In one of them (Fig. 2) a persistent ductus arteriosus had been shown on the left side at the first angiographic study (Fig. 2a); it had closed by the time of the operation on that pulmonary artery (modified Blalock-Taussig shunt), as seen on the postoperative angiogram showing a ductus dimple and a patent shunt (Fig. 2b). In another patient (Fig. 3) there was an absent right pulmonary artery (Fig. 3a) and on that side a ductus dimple (Fig. 3b). At operation a pulmonary artery only at the hilus was found on the right side and was connected to the main pulmonary artery with a vascular prosthesis (Fig. 3c).

The absent pulmonary artery was on the side of the aortic arch in five patients (cases 8–12). They all had severe right ventricular outflow tract obstruction. In one of them the ductus was patent at the time of the initial angiogram and fed confluent pulmonary

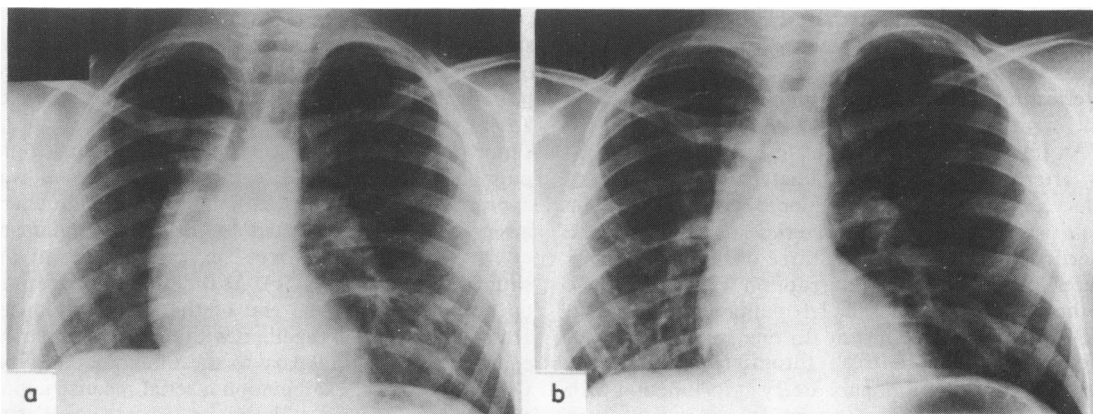


Fig. 1 Chest x ray film showing a small and hypoperfused right lung in comparison with the left (a). Two years later, after a right Blalock-Taussig shunt, the size of the right lung had increased (b).

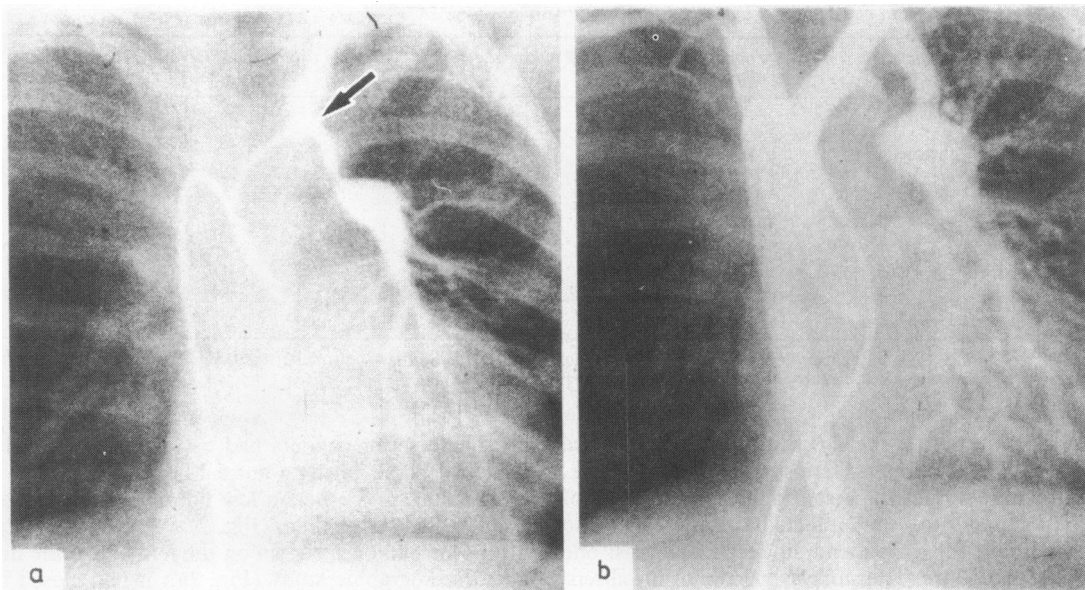


Fig. 2 Selective injection into a severely narrowed persistent ductus arteriosus arising from a left innominate artery (right aortic arch) (a). The ductus was closed at the time of the operation and this is shown on the aortogram performed one year after a modified Blalock-Taussig shunt (b).

arteries. Five years later angiocardiology failed to show either the ductus or the left pulmonary artery (Fig. 4a, b).

#### SURGICAL FINDINGS

Of all the 11 patients explored on the side of the absent artery, the pulmonary artery was identified near or at the hilus in all but one, the exception being the oldest child aged 12 years (case 4). These 10 patients included five in whom no intrapericardial vessel was found at operation (Table). In all of these five patients the hilar vessel was found to be in continuity with a fibrous thread, the ligamentum arteriosum, arising from the innominate artery on the side opposite the aortic arch (Figs. 2 and 3).

An intrapericardial element of the absent pulmonary artery, continuous with a patent hilar pulmonary artery, was found in five patients (cases 8–12). The main and left pulmonary arteries were joined by a short occluded segment. In three of the five patients (cases 8, 9, and 12) the interruption was a membrane at the junction between the left pulmonary artery and the ligamentum arteriosum. In one patient (case 10) aged only 5 days a fresh thrombus occluded the lumen of the left pulmonary artery at its junction with a closed main pulmonary artery. In one patient (case 11) a short atretic segment of intrapericardial artery was identified, continuous with the hilar artery. In all

five patients a ligamentum arteriosum arising from beneath the aorta on the side of the aortic arch was found at operation or necropsy.

In 10 patients in whom a pulmonary artery was found surgical procedures aiming to increase pulmonary blood flow included a systemic to pulmonary artery shunt on that side in seven cases (Fig. 4c) and a conduit connexion between the main pulmonary artery and the interrupted pulmonary artery in one (Fig. 3c). Furthermore, two patients without an intrapericardial pulmonary artery, who had had a shunt inserted, subsequently underwent connection of the main pulmonary artery and the interrupted pulmonary artery. Fig. 5 shows one of these cases of absent right pulmonary artery with left aortic arch. A shunt procedure was first performed on a small right pulmonary artery. One year later that vessel was appreciably larger (Fig. 5b). The right pulmonary artery was then connected to the main pulmonary artery with an 8 mm Gore-Tex prosthesis, and the shunt was closed (Fig. 5c). At the time of the second operation the proximal end of the right pulmonary artery was excised together with the fibrous string connecting the pulmonary to the innominate artery. On microscopical examination a serial reconstruction of the tissue showed a closed ductus arteriosus with ductal tissue extending into and occluding the right pulmonary artery (Fig. 6).

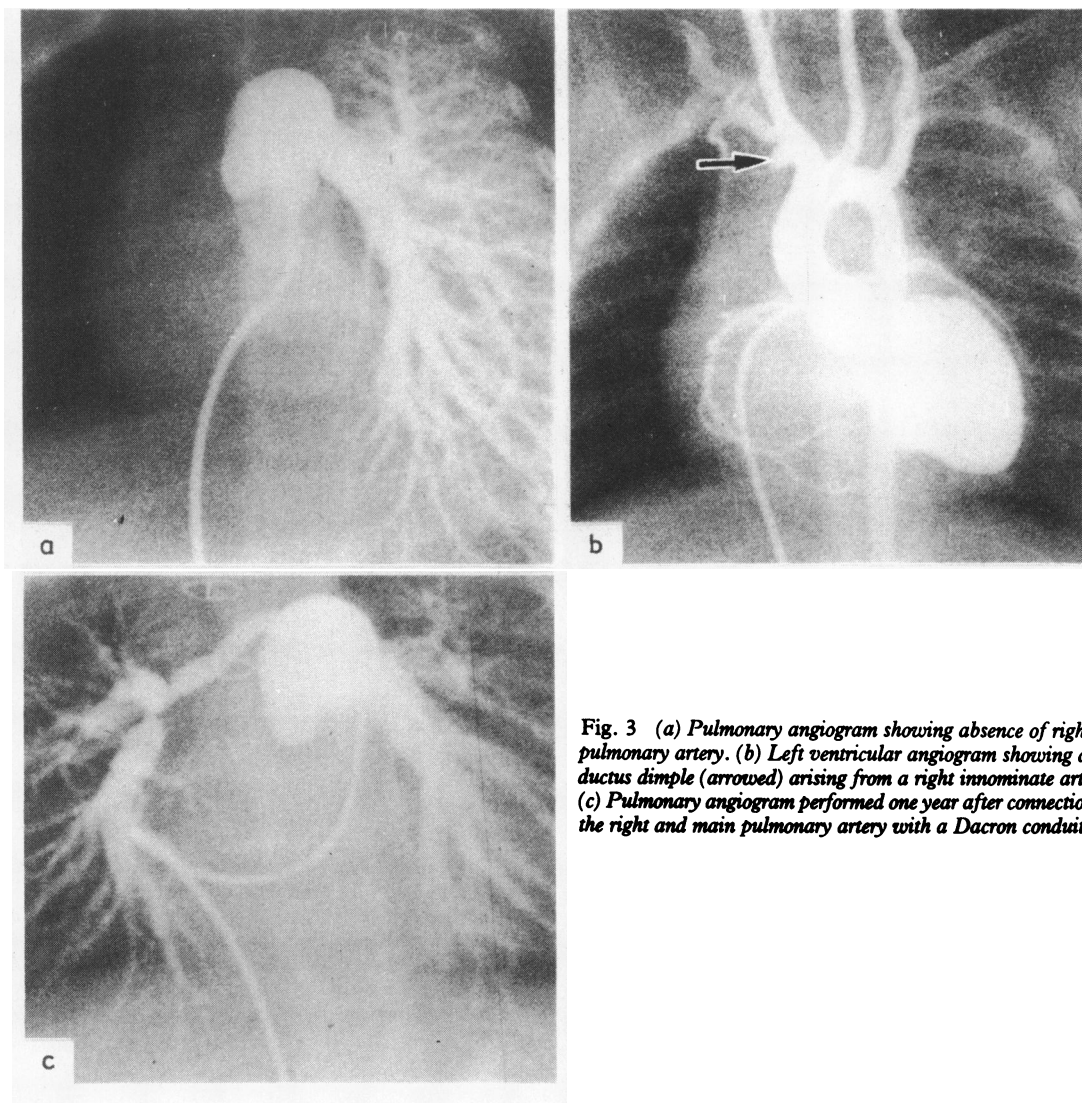
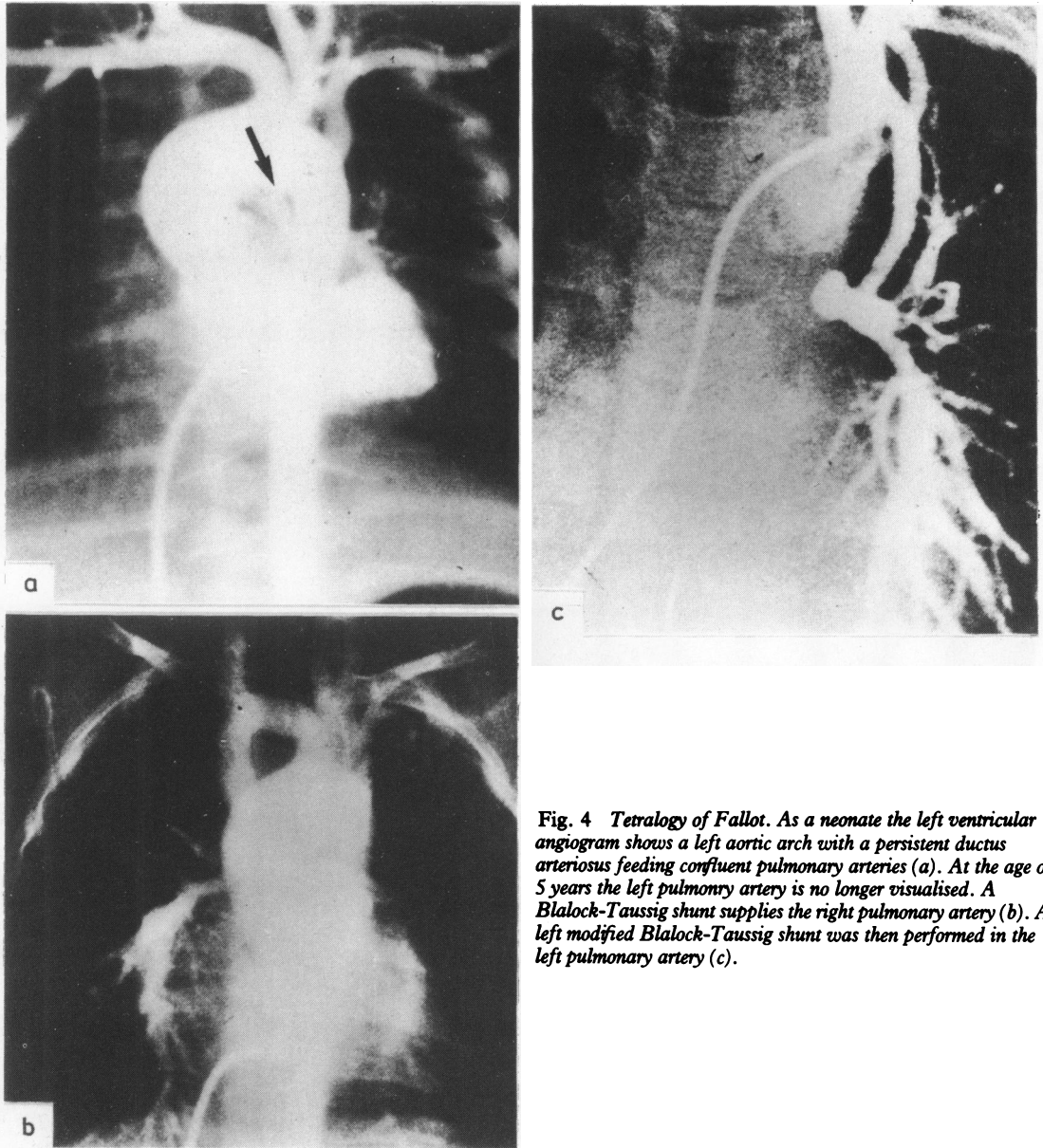


Fig. 3 (a) Pulmonary angiogram showing absence of right pulmonary artery. (b) Left ventricular angiogram showing a ductus dimple (arrowed) arising from a right innominate artery. (c) Pulmonary angiogram performed one year after connection of the right and main pulmonary artery with a Dacron conduit.

## Discussion

The present study confirms the pathological conclusions of McKim and Wiglesworth<sup>2</sup> and Sotomora and Edwards<sup>3</sup> who pointed out, as previously mentioned, that the distal portion and intrapulmonary vessels of the so called absent pulmonary arteries are in fact usually present. Thus the artery is usually occult rather than absent.

Although it is easy to understand why no intrapulmonary vessel opacifies from the systemic or pulmonary arterial circulation one would expect to be able to inject these occult arteries retrogradely by pulmonary venous wedge injection.<sup>4</sup> Our three attempts at venous wedge injection in this series were unhelpful. It is not our practice to use general anaesthesia for cardiac catheterisation. Injection into the pulmonary veins is a potent stimulus to coughing in the conscious

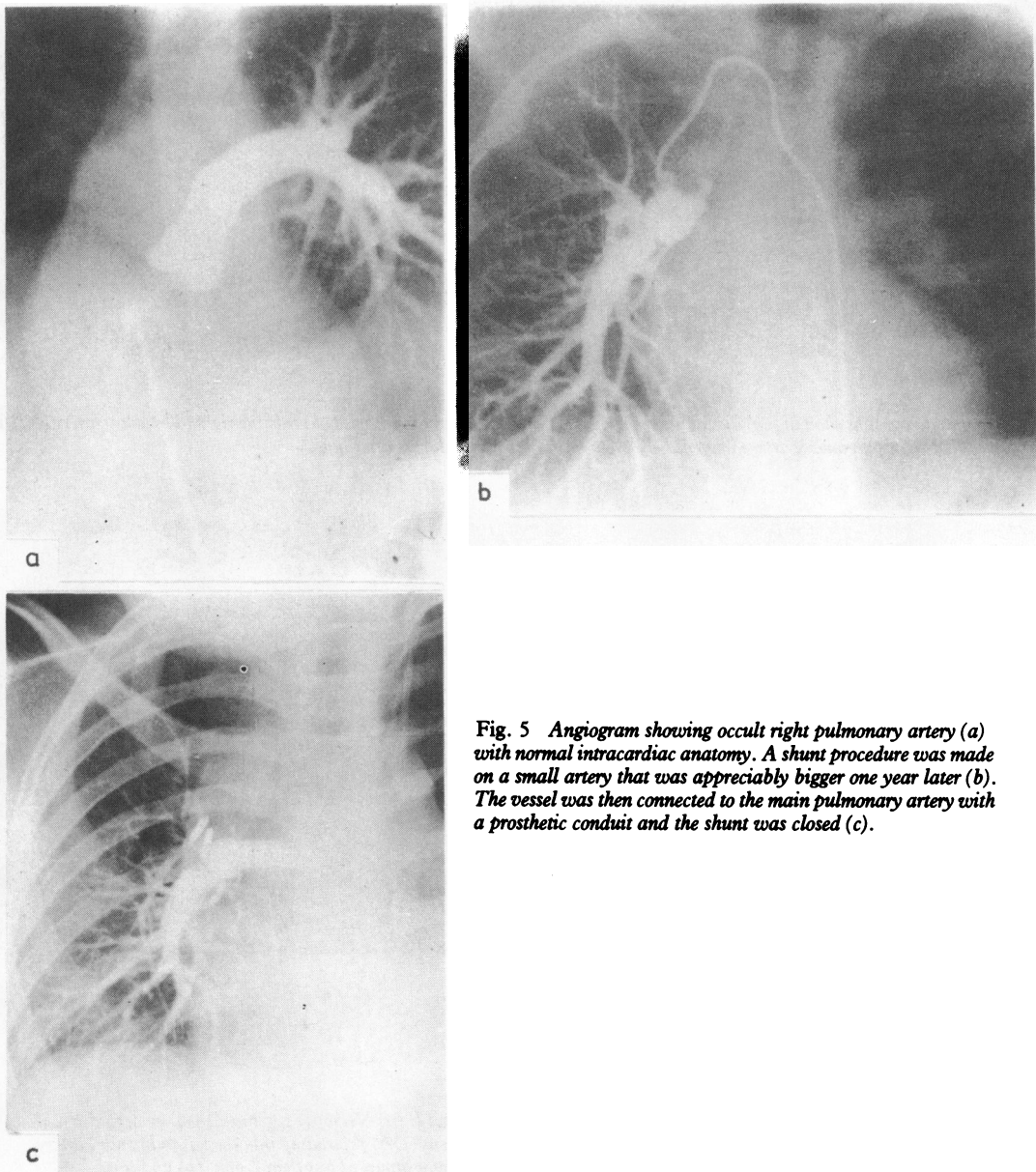


**Fig. 4** *Tetralogy of Fallot. As a neonate the left ventricular angiogram shows a left aortic arch with a persistent ductus arteriosus feeding confluent pulmonary arteries (a). At the age of 5 years the left pulmonary artery is no longer visualised. A Blalock-Taussig shunt supplies the right pulmonary artery (b). A left modified Blalock-Taussig shunt was then performed in the left pulmonary artery (c).*

patient, and this may have impeded retrograde filling of the pulmonary arteries in our patients.

We have delineated two patterns of occult pulmonary artery: patients with and without intrapericardial arteries. Typically, those without an intrapericardial pulmonary artery showed the anomaly on the side opposite the aortic arch and had evidence of a ductus coming from the innominate artery on the same side.

Perhaps embryological atresia or early involution of the structure destined to become the intrapericardial artery on that side (the proximal part of the sixth aortic arch) is the primary defect in these cases. This could occur if the heart is otherwise normal or when any cardiac anomaly is present. If the sixth arch on the side opposite the aortic arch does not persist the more primitive connexion with the intrapulmonary



*Fig. 5 Angiogram showing occult right pulmonary artery (a) with normal intracardiac anatomy. A shunt procedure was made on a small artery that was appreciably bigger one year later (b). The vessel was then connected to the main pulmonary artery with a prosthetic conduit and the shunt was closed (c).*

vessels may remain to feed the ipsilateral pulmonary artery. This structure appears after birth to originate from the innominate artery and contains ductal tissue. If such an innominate ductus closes after birth the intrapulmonary artery on that side will lose its main source of blood supply and not be demonstrable by contrast injections into the pulmonary or systemic circulations. We have recorded this sequence of events

in one of our patients (Fig. 2).

The second group of patients had a small occluded intrapericardial pulmonary artery in continuity with the hilar vessels on the left side, best described as an interrupted pulmonary artery. All had severe or complete right ventricular outflow tract obstruction and all were associated with a left ductus, which descended vertically from under the aortic arch.



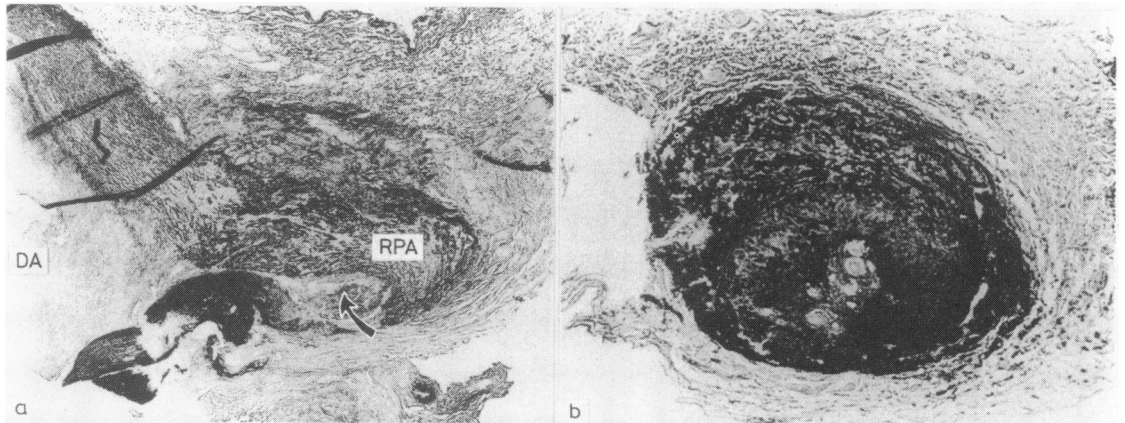


Fig. 6 Photomicrographs showing (a) ductal tissue extending from the ductus arteriosus (DA) into the right pulmonary artery (RPA) and (b) occluded right pulmonary artery immediately proximal to the closed ductus arteriosus.

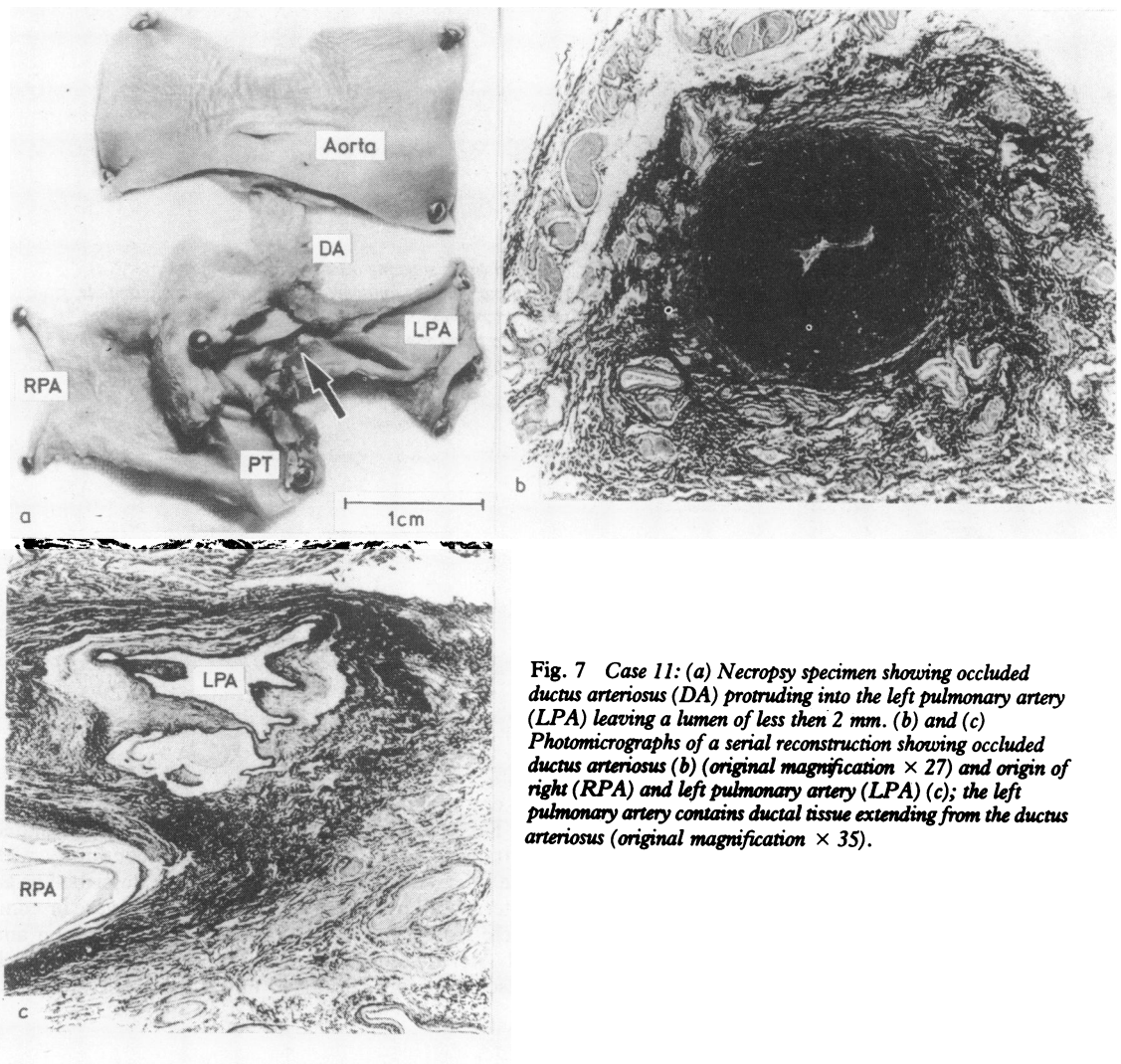


Fig. 7 Case 11: (a) Necropsy specimen showing occluded ductus arteriosus (DA) protruding into the left pulmonary artery (LPA) leaving a lumen of less than 2 mm. (b) and (c) Photomicrographs of a serial reconstruction showing occluded ductus arteriosus (b) (original magnification  $\times 27$ ) and origin of right (RPA) and left pulmonary artery (LPA) (c); the left pulmonary artery contains ductal tissue extending from the ductus arteriosus (original magnification  $\times 35$ ).

We postulate that patients in whom some intrapericardial artery is found at operation or necropsy probably had confluent pulmonary arteries at some stage. In one of our patients we have indeed evidence with serial angiograms that the anomaly was acquired after birth and associated with the closure of the ductus (Fig. 4). A sling of ductus tissue can surround the aorta, opposite the insertion of a normal "horizontal" duct (which carries blood from the main pulmonary artery to the descending aorta in fetal life); it has been postulated that constriction of such a ductus may lead to coarctation of the aorta.<sup>5</sup> Patients with an interrupted pulmonary artery may represent the opposite lesion—"coarctation" of the pulmonary artery at the site of insertion of a "vertical" ductus (which carries blood from the aorta to the pulmonary artery in ductus dependent lesions).<sup>6</sup> It is worth noting that stenosis at the origin of the left pulmonary artery is a well described complication of tetralogy of Fallot and may well represent a lesion related to the occlusions we have described. In four such cases seen in recent years in our unit sequential angiography showed that stenosis occurred after birth and was related to the closure of the ductus arteriosus. This was confirmed by histological demonstration of ductal tissue, extending and protruding into the lumen of the left pulmonary artery in one patient (Fig. 7).

Having established that it is worth exploring the patient for the occult artery, we have delineated two patterns of the anomaly which may prove helpful in the surgical management. In patients in whom the pulmonary artery on the side opposite the aortic arch is absent there is unlikely to be an intrapericardial pulmonary artery, and a useful intrapulmonary vessel may well be missed if only the pericardium is explored—for example, through a sternotomy incision. Moreover, these are the patients likely to require a conduit to bridge the gap between the hilar and main pulmonary artery when they come for complete repair. Conversely, in patients with interruption on the side of the aortic arch the intrapericardial pulmonary artery is likely to be present and the gap shorter so that continuity is more readily established—for example, with a patch.

In either group it seems advisable to search for the missing artery as early as possible as the vessel is unlikely to grow after the closure of the ductus

arteriosus; it may even be completely obliterated as seen in the 5 day old child (case 10), in whom a fresh thrombus was found at operation. In experimental animals in which the left pulmonary artery was ligated at birth the hilar and axial pulmonary arteries became smaller and were often obliterated by 4 to 6 months of age in rapidly growing pigs, despite a satisfactory bronchial arterial supply to the intra-acinar pulmonary arteries.<sup>7</sup> Such animals have a small lung with small alveoli. In the present study, the only patient without an identifiable hilar pulmonary artery was aged 12, the oldest patient in the series.

Thus all children with an interrupted pulmonary artery should be assumed to have a pulmonary artery, if only at the hilus, into which it would be possible to insert a prosthesis and so connect it to a systemic artery and ultimately to the pulmonary trunk. In the presence of an intracardiac anomaly, blood flow should be restored through the interrupted pulmonary artery as a first procedure. The intracardiac repair can then be carried out later when the vasculature of both lungs has had time to benefit from the more even distribution of flow. The risk of intracardiac repair may then be decreased.

#### References

- 1 Frantzel O. Angeborener Defekt der rechten Lungenarterie. *Virchows Arch [Pathol Anat]* 1868; 43: 420.
- 2 McKim JS, Wiglesworth FW. Absence of the left pulmonary artery: a report of six cases with autopsy findings in three. *Am Heart J* 1954; 47: 845-59.
- 3 Sotomora RF, Edwards JE. Anatomic identification of so-called absent pulmonary artery. *Circulation* 1978; 57: 624-33.
- 4 Singh SP, Rigby ML, Astley R. Demonstration of pulmonary arteries by contrast injection into pulmonary vein. *Br Heart J* 1978; 40: 55-7.
- 5 Becker A, Anderson RH. Malformation of the aortic arch. In: Crawford T, ed. *Pathology of congenital heart disease*. London: Butterworth, 1981: 321-38.
- 6 Santos MA, Moll JN, Drummond C, Araujo WB, Romao N, Reis NB. Development of the ductus arteriosus in right ventricular outflow tract obstruction. *Circulation* 1980; 62: 818-22.
- 7 Haworth SG, McKenzie SA, Fitzpatrick ML. Alveolar development after ligation of left pulmonary artery in newborn pig: clinical relevance to unilateral pulmonary artery. *Thorax* 1981; 36: 938-43.