

The heart and tuberous sclerosis

An echocardiographic and electrocardiographic study

JOHN L GIBBS

From the Non Invasive Heart Unit, Killingbeck Hospital, Leeds

SUMMARY Cross sectional echocardiography, 12 lead electrocardiography, and 24 hour ambulatory electrocardiography were performed in eleven patients with tuberous sclerosis. Echocardiography showed single or multiple intramyocardial masses, most commonly in the ventricular septum, suggestive of rhabdomyomata in seven of the eleven cases. One patient with a normal echocardiogram showed ventricular pre-excitation on electrocardiography, with tachycardias of 180 beats per minute on ambulatory monitoring. Sinus bradycardia, sinus tachycardia, and supraventricular tachycardia were also seen, but their importance is uncertain.

Echocardiography and electrocardiography should be routinely performed in the assessment of patients with tuberous sclerosis and ambulatory electrocardiography should be considered in those with seizures that respond poorly to anticonvulsants.

Since the first reported case of cardiac rhabdomyoma in 1862¹ the association of this tumour with tuberous sclerosis has become well recognised. Most information on these tumours has of necessity been related to morbid anatomy and there is little information on the frequency of cardiac involvement in such patients during life. With the advent of echocardiography, non-invasive antemortem diagnosis of intracardiac masses has become possible,² and ventricular rhabdomyomata have been detected with both M mode³ and cross sectional^{4,5} echocardiography.

Syncope, seizures, and "funny turns" occurring in patients with tuberous sclerosis are likely to be attributed to cerebral causes. These patients, however, may have abnormal hearts and such symptoms may be of cardiac origin. I have assessed the frequency of echocardiographic abnormalities in patients with tuberous sclerosis and have investigated whether the presence of cardiac tumours in these patients was related to detectable disturbances in cardiac rhythm.

Patients and methods

A standard letter was circulated to neurologists and paediatricians within the paediatric cardiology catchment area of this hospital (population approximately five million), asking for permission to write to any patients with tuberous sclerosis under their care. Letters were also sent to patients registered with the Tuberous Sclerosis Association and living within the same catchment area inviting them to join the study. Twenty three patients with tuberous sclerosis were identified; 11 of them agree to participate in the study. One case had already been investigated at this hospital because of palpitation.

The patients were aged from 4 to 54 years (mean (SD) 20(13)). Nine patients had mental retardation ranging from mild educational subnormality to severe retardation with pronounced hyperactivity. The two mentally normal adult patients had adenoma sebaceum and subungual fibromata as the only clinical manifestations of tuberous sclerosis. Eight of the eleven patients had some form of epilepsy and were taking diazepam, clonazepam, phenytoin, sodium valproate, carbamazepine, or a combination of these anticonvulsants. All subjects were examined by cross sectional echocardiography, 12 lead electrocardiography, and 24 hour ambulatory electrocardiography. With the exception of the one case already under the care of this hospital none of the

Requests for reprints to Dr J.L. Gibbs, Non Invasive Heart Unit, Killingbeck Hospital, York Road, West Yorkshire LS14 6UQ.

Accepted for publication 2 September 1985

patients had previously undergone cardiac investigation.

Results

ECHOCARDIOGRAPHY

Seven of the eleven patients had abnormal echocardiograms (Figure). Single or multiple echodense masses were detected in the ventricular septum alone in four cases, in the septum and posterior left ventricular wall in one, and in the posterior left ventricular wall alone in two. The masses ranged in diameter from 0.3 cm to 1.2 cm. All seven patients with abnormalities on the echocardiogram were epileptic and all were at least slightly mentally retarded. No masses affecting the atria were detected, and apart from the intramyocardial masses the cardiac anatomy appeared normal.

ELECTROCARDIOGRAPHY

Four patients had unremarkable ambulatory electrocardiographic recordings. In the seven remaining

cases sinus tachycardias at rates of approximately 150 beats per minute, unrelated to seizures, occurred in two patients aged 21 and 23 years, both of whom were severely mentally retarded and bed-ridden. These patients also showed abrupt slowing of sinus rhythm from 70 to 47 and from 100 to 60 beats per minute respectively while awake but at rest. Both had involuntary movements and frequent episodes of hyperactivity, were taking anti-convulsants, and had abnormal echocardiograms. Sinus tachycardias of 150 beats per minute occurred in two other patients during seizures. Abrupt sinus slowing was seen in one further subject, a 35 year old woman whose heart rate abruptly fell from 70 beats per minute to 45 beats per minute while she was awake but at rest; a pronounced sinus arrhythmia was seen on the 12 lead electrocardiogram. She was taking no medication and had a normal echocardiogram. Two patients, one aged 14 who had an abnormal echocardiogram and one aged 4 years who had a normal echocardiogram, had supraventricular tachycardias at rates of 140 and 180 beats per minute

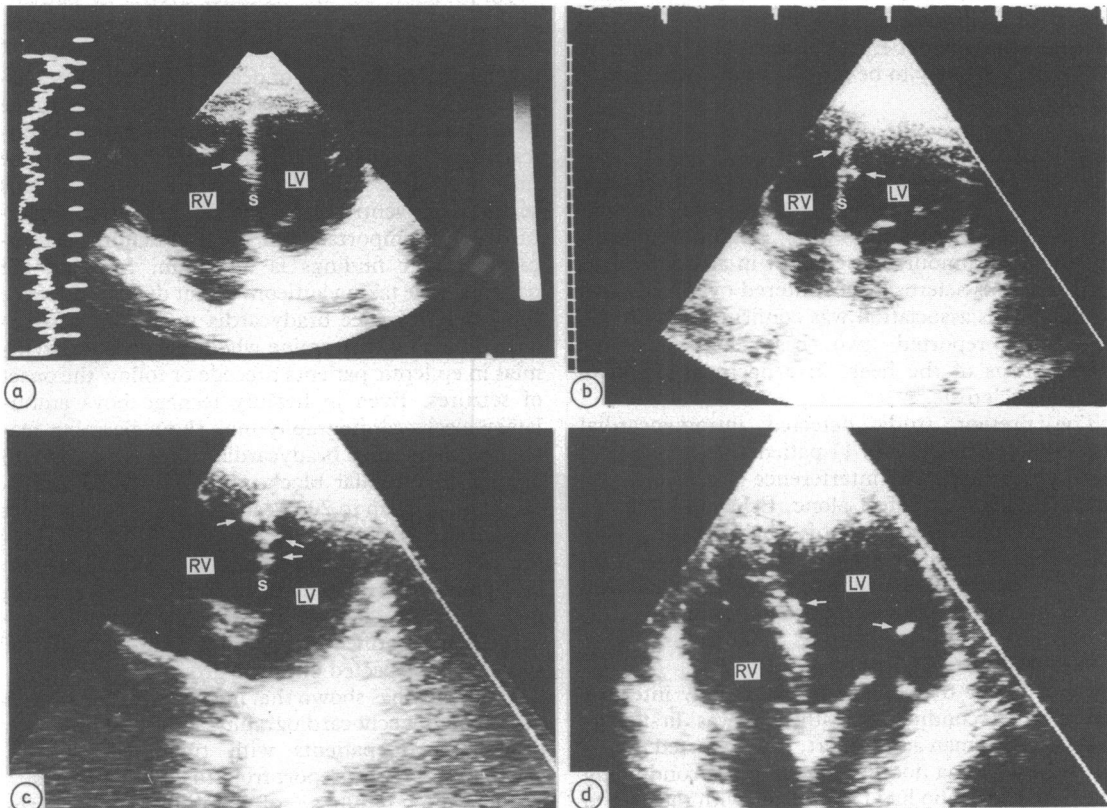


Figure Examples of echocardiographic abnormalities in patients with tuberous sclerosis. Intramyocardial masses (arrowed) were detected as single (a) or multiple (b, c) lesions in the ventricular septum and were also seen in the posterior left ventricular wall (d). RV, right ventricle; LV, left ventricle; S, ventricular septum.

respectively that occurred during seizures and rapidly reverted to sinus rhythm after the seizures. In the latter case, ventricular pre-excitation (with a PR interval of 50 ms and without a delta wave) was present throughout the 24 hour recording period and 12 lead electrocardiogram. Both patients were regularly taking anticonvulsants. Sinus bradycardia at rates of between 60 and 45 beats per minute was present throughout the ambulatory recording of one 14 year old boy with an abnormal echocardiogram whose seizures were treated with diazepam alone.

Discussion

STUDY POPULATION

The prevalence of tuberous sclerosis in Oxford has been estimated at between 1:15 000 and 1:30 000.⁶ In my study 23 cases were detected in a population of approximately five million (approximately 1:217 000). The method of identifying those with tuberous sclerosis was relatively crude and there can be little doubt that a considerable number of cases were not identified. Patients with mild manifestations of disease are less likely to seek medical attention, and the patients with tuberous sclerosis in this paper are likely to be those who are more severely affected.

ECHOCARDIOGRAPHY

The high frequency of rhabdomyoma of the heart in patients dying of tuberous sclerosis was first suggested by Steinbiss, who found clinically unsuspected tumours at necropsy in all six patients with tuberous sclerosis encountered over a ten year period.⁷ This association was confirmed by Crome, who also reported two cases of congenital fibroelastosis of the heart in a necropsy study of tuberous sclerosis.⁸

The present study detected intramyocardial masses in seven (64%) of 11 patients. In no case did there appear to be any interference of cardiac function due to a mass effect alone. Echocardiographic abnormalities suggestive of rhabdomyoma are detectable in a large proportion of patients with tuberous sclerosis, particularly when the clinical manifestations of the disease are pronounced.

ELECTROCARDIOGRAPHY

The possibility that cardiac tumours may interfere with normal conduction pathways was first suggested by Wegman and Egbert, who reported multiple rhabdomyoma nodules invading the conducting system in a girl who had tachycardia with rates up to 200 beat per minute.⁹ Duras reported a further case in which frequent extrasystoles were noted in a patient with severe mental retardation and adenoma

sebaceum.¹⁰ A case presenting with palpitation has been described,¹¹ in which the patient had classic stigmata of tuberous sclerosis. Electrocardiography showed the symptoms to be due to multifocal ventricular extrasystoles; an intraventricular conduction defect was also noted. Ventricular septal rhabdomyoma may also be associated with neonatal complete heart block.^{12 13} Rhabdomyomatosis may be the underlying cause of ventricular pre-excitation, with rhabdomyomatous fibres forming an accessory atrioventricular pathway and leading to symptomatic tachycardias.¹⁴ The only patient in the present series who showed ventricular pre-excitation had an apparently normal echocardiogram, but the resolution of ultrasonic imaging may be incapable of detecting masses that are much smaller than 3 mm in diameter. Indeed, in the case report referred to above,¹⁴ the rhabdomyomatous changes were extensive microscopically but only appeared macroscopically as a localised thickening of the mitral valve and may well have been missed by echocardiography.

Information on the terminal events in patients with tuberous sclerosis suggests that status epilepticus, renal failure,¹⁵ and intercurrent infection¹⁶ are the principal causes of death. Multiple large cardiac tumours may cause heart failure and death due to a mass effect alone,¹⁷ but the frequency and clinical importance of cardiac arrhythmias have yet to be fully evaluated. Apart from the one patient in this series with ventricular pre-excitation and tachycardias, the importance of the ambulatory electrocardiographic findings is uncertain. Most of the patients were taking anticonvulsant drugs, and since these may produce bradycardia it may be particularly difficult to determine whether cardiac arrhythmias in epileptic patients precede or follow the onset of seizures. Even in healthy teenage boys ambulatory electrocardiography may show alarming features such as sinus bradycardia, sinus arrest, five to one atrioventricular block, supraventricular tachycardia at rates up to 200 beats per minute, and short episodes of ventricular tachycardia.¹⁸ For this reason, 24 hour electrocardiographic recordings are best reserved for the cases of tuberous sclerosis in which seizure control deteriorates despite anticonvulsant treatment or in which a cardiac cause of syncope is suspected on other grounds.

This study has shown that intramyocardial masses detectable by echocardiography are found in a high proportion of patients with tuberous sclerosis, confirming a recent report from the United States.¹⁹ While the findings of ambulatory electrocardiography in epileptic patients are difficult to interpret, it is clear that potentially serious arrhythmias may occur. Echocardiography and 12 lead elec-

trocadiography should be routinely performed in patients with tuberous sclerosis, and in cases in which seizures are difficult to control the possibility of a cardiac rather than a cerebral aetiology should be borne in mind.

I thank Mrs Ann Hunt of the Tuberous Sclerosis Association for her administrative help; Dr Leon Gerlis and Dr Gordon Williams for their advice and encouragement; Mrs Gill Wharton for her technical assistance; and Dr D F Dickinson, Killingbeck Hospital, Leeds; Dr R N Hakin, St Luke's Hospital, Bradford; Dr D W Sumner, St James Hospital, Leeds; Dr G M Wilson, Staincliffe General Hospital, Dewsbury; and Dr E G S Spokes, Bootham Park Hospital, York, for their cooperation.

JLG is supported by the National Heart Research Fund.

References

- 1 Von Recklinghausen FD. Verhandlungen der gesellschaft für geburtshilfe. Ein Herz von einem neugeboren. *Monatschrift für geburtskunde und frauenkrankheiten* 1862; 20: 1-3.
- 2 Ports TA, Cogan J, Schiller NB, Rapaport E. Echocardiography of left ventricular masses. *Circulation* 1978; 58: 528-36.
- 3 Farooki ZQ, Henry JG, Arciniegas E, Green EW. Ultrasonic pattern of ventricular rhabdomyoma in two infants. *Am J Cardiol* 1974; 34: 842-4.
- 4 Lababidi Z, Wu JR, Walls J, Curtis J. Neonatal cyanosis caused by cardiac rhabdomyomas. *Am Heart J* 1984; 108: 624-7.
- 5 Horgan JH, O'M Shiel F, Goodman AC. Tumor invasion of the interventricular septum detected by conventional echocardiography. *JCU* 1976; 4: 133-4.
- 6 Hunt A, Lindenbaum RH. Tuberous sclerosis: a new estimate of prevalence within the Oxford region. *J Med Genet* 1984; 21: 272-7.
- 7 Steinbiss W. Zur kenntnis der Rhabdomyome des Herzens und ihrer Beziehungen zur tuberösen Gehirnsklerose. *Virchows Archiv für Pathologische, Anatomie und Physiologie und für Klinische Medizin* 1923; 243: 22-38.
- 8 Crome L. The structural features of epiloia, with special reference to endocardial fibroelastosis. *J Clin Pathol* 1954; 7: 137-40.
- 9 Wegman ME, Egbert DS. Congenital rhabdomyoma of the heart associated with arrhythmia. *J Paediatr* 1935; 6: 818-24.
- 10 Duras FP. Cardiac manifestations in a case of tuberous sclerosis. *Br Heart J* 1945; 7: 37-40.
- 11 Taylor TR. Tuberous sclerosis presenting as cardiac arrhythmia. *Br Heart J* 1968; 30: 132-4.
- 12 Nadas AS, Ellison RC. Cardiac tumors in infancy. *Am J Cardiol* 1968; 21: 363-6.
- 13 Gasul BM, Arcilla RA, Lev M. *Heart disease in children*. Philadelphia: JB Lippincott, 1966: 1086.
- 14 Gotlieb AI, Chan M, Palmer WH, Huang S. Ventricular pre-excitation syndrome. Accessory left atrioventricular connection and rhabdomyomatous myocardial fibers. *Arch Pathol Lab Med* 1977; 101: 486-9.
- 15 Ross AT, Dickerson WW. Tuberous sclerosis. *Archives of Neurology and Psychiatry* 1943; 50: 233-57.
- 16 Scheig RL, Bornstein P. Tuberous sclerosis in the adult. *Arch Intern Med* 1961; 108: 789-95.
- 17 Batchelor TM, Maun ME. Congenital glycogenic tumors of the heart. *Archives of Pathology* 1945; 39: 67-73.
- 18 Dickinson DF, Scott O. Ambulatory electrocardiographic monitoring in 100 healthy teenage boys. *Br Heart J* 1984; 51: 179-83.
- 19 Bass JL, Brenningstall GN, Swaiman KF. Echocardiographic incidence of cardiac rhabdomyoma in tuberous sclerosis. *Am J Cardiol* 1985; 55: 1379-82.