

Postpartum coronary artery dissection¹

PHILIP J. SHAVER, THOMAS F. CARRIG, AND WILLIAM P. BAKER

From the Division of Cardiology, Department of Medicine, National Naval Medical Center, Bethesda, Maryland, U.S.A.

A 27-year-old woman experienced anterior myocardial infarction three weeks after the delivery of her second child. Coronary arteriography subsequently showed primary dissection of the left coronary artery. This patient is believed to be the second reported survivor of angiographically proven peripartal left coronary artery dissection and the only such patient to achieve and maintain asymptomatic status for a prolonged period without operative intervention.

Primary coronary artery dissection was first described by Pretty in 1931. Forty-four additional cases have since been reported. Twelve of these patients were in the peripartal period (Wells, 1960; Burton and Zawadzki, 1962; Brody *et al.*, 1965; Palomino, 1969; Di Maio and Di Maio, 1971; Asuncion and Hyun, 1972; Claudon *et al.*, 1972; Razavi, 1975).

Primary dissection of a coronary artery during pregnancy or the puerperium had been thought by some authors to be invariably fatal (Bulkley and Roberts, 1973). We were able to find only one reported patient in whom the diagnosis had been angiographically confirmed during life (Razavi, 1975). Sudden death or a catastrophic ischaemic event is the usual presentation. This paper reports a case of primary coronary artery dissection occurring three weeks postpartum with prolonged survival.

Case report

A 28-year-old woman, gravida 2, para 2, was recently examined at the United States National Naval Medical Center 4 months after acute myocardial infarction. Five months before, her second full-term uncomplicated pregnancy was terminated by a caesarean section without maternal or fetal difficulty. Mild hypertension one week postpartum was controlled with a brief course of mild sedation. Three weeks postpartum the patient experienced the sudden onset of severe substernal pressure which radiated to both upper extremities and both sides of the jaw and persisted for several hours. She

was admitted to a coronary care unit where serial electrocardiograms and serum enzyme levels confirmed acute anterior myocardial infarction. Her course in the hospital was uncomplicated. After convalescence she returned to normal activity and has been asymptomatic since.

There was no history of previous cardiovascular disease. Her blood pressure had been normal before the myocardial infarction and is at present normal without drugs. She had smoked 40 cigarettes daily for 10 years. Both maternal grandparents had myocardial infarction in their seventh decade but there was no other family history of coronary heart disease.

Physical examination revealed an apparently healthy woman who was 178 cm tall and weighed 76 kg. Her pulses were normal and the blood pressure was 104/68 mmHg. There were a grade 2/6 short midsystolic murmur and a fourth heart sound at the apex. The remainder of the examination was normal except for an abdominal surgical scar.

The serum cholesterol and triglyceride levels were 220 and 115 mg/100 ml (5.7 mmol/l and 1.3 mmol/l), respectively. A glucose tolerance test was normal. The electrocardiogram (Fig. 1) showed anterior and lateral myocardial infarction. The chest x-ray examination was normal.

Cardiac catheterisation four months after myocardial infarction showed a normal cardiac index of 3.4 l/min per m² and normal pressures within the right atrium (2 mmHg), right ventricle (18/2 mmHg), pulmonary artery (17/8 mmHg), left ventricle (120/8 mmHg), and aorta (110/68 mmHg). There was a large area of akinesis of the anterior wall of the left ventricle. The right coronary arteriogram (Fig. 2a) was normal. The left coronary

¹The opinions and assertions expressed are the private ones of the authors and are not to be construed as official or reflecting the views of the Navy Department.

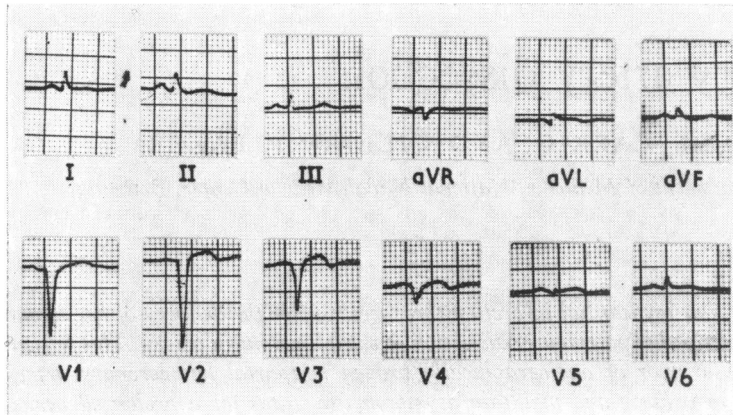


Fig. 1 *Electrocardiogram showing anterior and lateral myocardial infarction.*

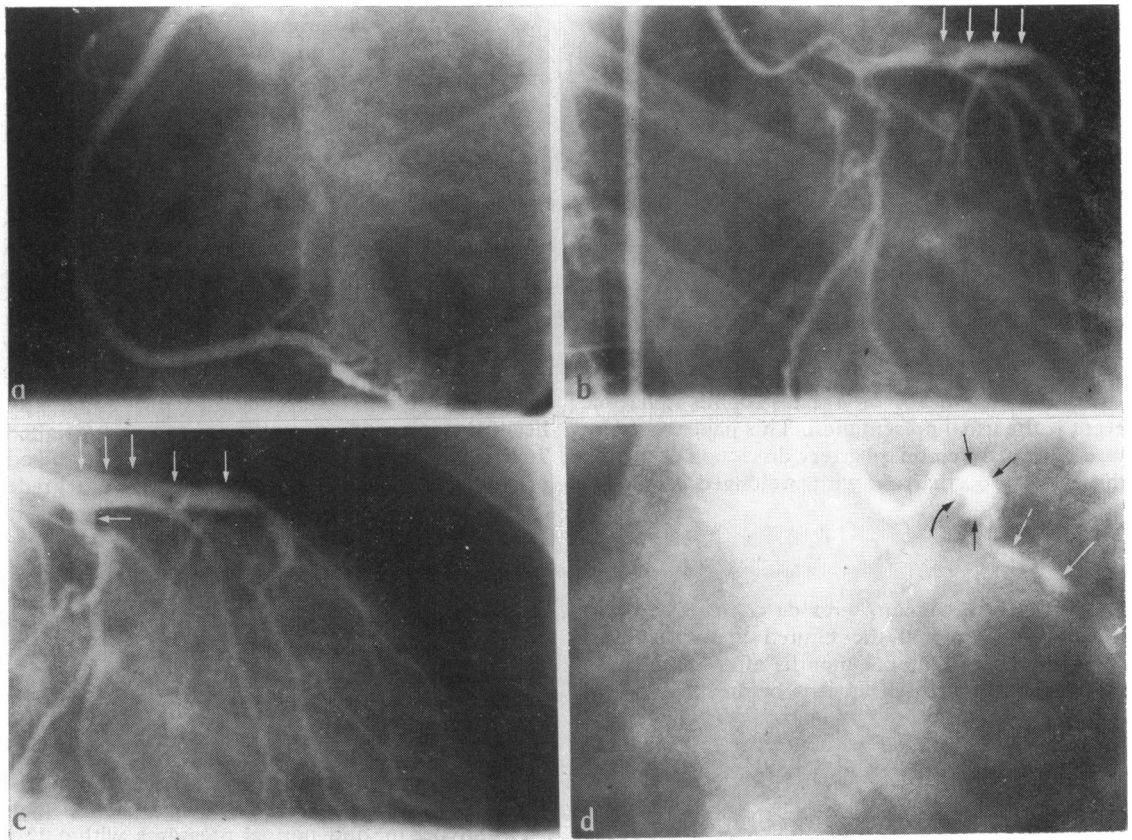


Fig. 2 (a) *Normal right coronary arteriogram in left anterior oblique projection.* (b and c) *Early and late frames of left coronary arteriogram in right anterior oblique projection showing retrograde opacification of false lumen of the left anterior descending and proximal circumflex coronary arteries (white arrows).* (d) *Late frame of left coronary arteriogram in left anterior oblique projection showing retained contrast medium in the false lumen of the left anterior descending (black arrows) and circumflex coronary arteries (white arrows). The left anterior descending coronary artery is seen indenting the false aneurysm in its wall (curved arrow).*

arteriogram showed a small lumen within the main left coronary artery from which the circumflex and marginal circumflex branches filled directly (Fig. 2b). After opacification of the left circumflex and marginal circumflex coronary arteries there was progressive retrograde opacification along the course of the left anterior descending coronary artery (Fig. 2b and c) followed by anterograde opacification in a course parallel to the proximal left circumflex coronary artery (Fig. 2c). This was interpreted as a false lumen within the media of these two arteries. After washout of the contrast media from the true lumen of the circumflex system, the false lumina of the proximal left anterior descending and left circumflex coronary arteries remained opacified (Fig. 2d). The left anterior descending coronary artery is seen as an unopacified region in the margin of the false aneurysm.

Discussion

Including our patient, there are, to our knowledge, 46 reported cases of spontaneous primary coronary artery dissection (Forker *et al.*, 1973; Razavi, 1975; Westbrook, 1975). With only 3 exceptions, one in the peripartal period, in each of the previously reported cases the diagnosis was established at necropsy. Approximately 75 per cent of these patients were women.

Eleven peripartal patients with primary dissection of a coronary artery have been documented by necropsy and one by coronary arteriography. Two of the patients were in the ninth month of gestation and 10 were between 14 and 80 days postpartum. In age, the patients ranged from 26 to 42 years and most were multiparous. Among those who died after arrival at a hospital, the longest survival was 10 hours. Seven patients were dead on arrival. The single previously reported survivor (Razavi, 1975) had an anterolateral myocardial infarct 6 days postpartum. Six months later she had a recurrence of substernal chest pain. Coronary arteriography revealed a dissection of the left anterior descending, main left, and left circumflex coronary arteries. She subsequently underwent left ventricular aneurysmectomy and saphenous vein graft from the aorta to the posterolateral branch of the left circumflex coronary artery. The patient did well and was alive 4 years after operation.

In the case described here dissection involved the left circumflex as well as the left anterior descending and perhaps the main left coronary arteries. This has been previously reported in 3 peripartal patients (Asuncion and Hyun, 1972; Claudon *et al.*, 1972; Razavi, 1975). The left anterior descending coronary artery has been involved in all 13 cases.

With rare exception, the patients have been normotensive and have had uncomplicated pregnancies and parturition. The effect of straining during labour and delivery may initiate intimal rupture with subsequent haemorrhage into the media days to weeks later. Three patients had findings consistent with such a two-stage process (Wells, 1960; Brody *et al.*, 1965; Palomino, 1969).

As a rule, however, an intimal tear has not been identified and it has been suggested that rupture of the vasa vasorum into the media is the usual initial event.

The association of aortic dissection with pregnancy has been well documented (Schnitker and Bayer, 1944; Mandel *et al.*, 1954; Grech, 1961; Cavanzo and Taylor, 1969). A hormonal basis for this association has been suggested by several studies (Perl and Catchpole, 1950; Pedowitz and Perell, 1957; Asboe-Hansen, 1958; Manalo-Estrella and Barker, 1967). The current belief is that degeneration of the ground substance causes a weakening of the tunica media of the vessels during pregnancy and that this is instrumental in dissection (Manalo-Estrella and Barker, 1967). This same mechanism may be operative in peripartal coronary artery dissection.

This report documents the clinical course and angiographic findings in a survivor of postpartum primary coronary artery dissection. The patient is asymptomatic and operative intervention has not been recommended. Thus, dissection of a coronary artery is not always fatal. This entity should be considered in the differential diagnosis of acute myocardial infarction in the peripartal period.

We would like to thank Dr. David Redwood, Chief of Cardiology, Cedars of Lebanon Health Care Center, Miami, Florida, and Dr. Park W. Willis III, Professor of Medicine, Director of Division of Cardiology, University of Michigan School of Medicine, for their assistance in evaluating the coronary arteriograms and preparing this manuscript.

References

- Asboe-Hansen, G. (1958). Hormonal effects on connective tissue. *Physiological Reviews*, **38**, 446-462.
- Asuncion, C. M., and Hyun, J. (1972). Dissecting intramural hematoma of the coronary artery in pregnancy and the puerperium. *Obstetrics and Gynecology*, **40**, 202-210.
- Brody, G. L., Burton, J. F., Zawadzki, E. S., and French, A. J. (1965). Dissecting aneurysms of the coronary artery. *New England Journal of Medicine*, **273**, 1-6.
- Bulkley, B. H., and Roberts, W. C. (1973). Dissecting aneurysm (hematoma) limited to coronary artery. *American Journal of Medicine*, **55**, 747-756.
- Burton, J. F., and Zawadzki, E. S. (1962). The coronary aneurysm. *Journal of Forensic Sciences*, **7**, 486-492.

- Cavanzo, F. J., and Taylor, H. B. (1969). Effect of pregnancy on the human aorta and its relationship to dissecting aneurysms. *American Journal of Obstetrics and Gynecology*, **105**, 567-568.
- Claudon, D. G., Claudon, D. B., and Edwards, J. E. (1972). Primary dissecting aneurysm of coronary artery. *Circulation*, **45**, 259-266.
- Di Maio, V. J. M., and Di Maio, D. J. (1971). Postpartum dissecting coronary aneurysm. *New York State Journal of Medicine*, **71**, 767-769.
- Forker, A. D., Rosenlof, R. C., Weaver, W. F., Carveth, S. W., and Reese, H. E. (1973). Primary dissecting aneurysm of the right coronary artery with survival. *Chest*, **64**, 656-648.
- Grech, E. S. (1961). Dissecting aneurysm associated with pregnancy. *Journal of Obstetrics and Gynaecology of the British Commonwealth*, **68**, 682-684.
- Manalo-Estrella, P., and Barker, A. E. (1967). Histopathologic findings in human aortic media associated with pregnancy. *Archives of Pathology*, **83**, 336-341.
- Mandel, W., Evans, E. W., and Walford, R. L. (1954). Dissecting aortic aneurysm during pregnancy. *New England Journal of Medicine*, **251**, 1059-1061.
- Palomino, S. J. (1969). Dissecting intramural hematoma of left coronary artery in the puerperium. *American Journal of Clinical Pathology*, **51**, 119-125.
- Pedowitz, P., and Perell, A. (1957). Aneurysms complicated by pregnancy. I. Aneurysms of the aorta and its major branches. *American Journal of Obstetrics and Gynecology*, **73**, 720-735.
- Perl, E., and Catchpole, H. R. (1950). Changes induced in the connective tissue of the pubic symphysis of the guinea pig with estrogen and relaxin. *Archives of Pathology*, **50**, 233-239.
- Pretty, H. C. (1931). Dissecting aneurysm of coronary artery in a woman aged 42: rupture. *British Medical Journal*, **1**, 667.
- Razavi, M. (1975). Unusual forms of coronary artery disease. In *Cleveland Clinic Cardiovascular Consultations. Cardiovascular Clinics*, **7** (1), p. 25. Ed. by A. H. Brest. F. A. Davis, Philadelphia.
- Schnitker, M. A., and Bayer, C. A. (1944). Dissecting aneurysm of the aorta in young individuals, particularly in association with pregnancy, with report of a case. *Annals of Internal Medicine*, **20**, 486-511.
- Wells, A. L. (1960). Dissecting aneurysm of coronary artery in the puerperium. *Journal of Pathology and Bacteriology*, **79**, 404-405.
- Westbrook, R. I. (1975). Primary dissecting aneurysm of the coronary artery. *Nebraska State Medical Journal*, **60**, 8-10

Requests for reprints to Cdr. Philip J. Shaver, Cardiology Division, Naval Regional Medical Center, Portsmouth, Virginia 23708, U.S.A.