

Anatomy of left ventricular outflow tract¹

ROBERT WALMSLEY

From the Department of Anatomy and Experimental Pathology, The University, St Andrews, Scotland

SUMMARY The left ventricular outflow tract is here considered to be that region of the left ventricle that lies between the anterior cusp of the mitral valve and the ventricular septum. The ventricular septum lies at an angle of 45 degrees to the median plane. The 'anterior' wall of the outflow tract is therefore antero-medial and the 'posterior' wall is posterolateral.

In the anterior wall are both the muscular and membranous parts of the ventricular septum. The outflow septal myocardium is smooth-walled. At the junction of the muscular and membranous parts of the septum lies the atrioventricular bundle. The right face of the membranous septum gives attachment to the medial wall of the right atrium and also to a small part of the septal cusp of the tricuspid valve. The membranous septum is therefore partly atrioventricular. At its upper end the membranous septum is continuous with the right lateral wall of the root of the aorta. The root of the aorta passes to the right and upwards and the membranous septum separates the aorta from the right ventricle.

The posterior wall of the outflow tract is formed not only by the anterior mitral cusp but also by the 'intervalvar septum' and, in its upper part, by a curtain formed by the fusion of the anterior and posterior mitral cusps.

The ventricular septum, like the atrial septum, lies at an angle of about 45 degrees to the median plane. The septa are so orientated that the right heart lies as much in front of the left heart as to its right side. The entire length of the inflow tract of the left ventricle may be seen in sections of the entire thorax that pass parallel to the ventricular septum. To prepare sections to show the length of the left ventricular outflow tract the heart must, however, be cut vertically at right angles to the ventricular septum (Fig. 1). In such sections the ventricular septum is seen to form the anteromedial wall of the outflow tract: for simplicity in nomenclature this will be called its 'anterior' wall. The greater part of the posterolateral wall of the tract is formed by the anterior (aortic) cusp of the mitral valve: again, for the sake of simplicity, this will be called the 'posterior' wall. This outflow tract region of the left ventricle has been called the aortic vestibule, and the subaortic, subvalvar, or subvalvular region by different workers. Though the outflow tract of the left ventricle might justifiably be regarded as

extending from the left ventricular apex to the aortic valve I shall here consider the left ventricular outflow tract to be that part of the left ventricular chamber that lies in front of the anterior cusp of the mitral valve.

According to such a definition of the left ventricular outflow tract it must be emphasised that there is no line of demarcation on its anterior (septal) wall to indicate the lower border of the tract. This is indicated on its posterior wall by the free lower border of the anterior cusp of the mitral valve, a uniquely important structure in cardiac anatomy. The anterior mitral cusp is interposed between the inflow and outflow tracts of the left ventricle: the inflow tract lies below and behind the cusp and the outflow tract is in front of it. The left ventricular outflow tract is a complex musculomembranous channel or tunnel which has a length of about 25 mm in the adult heart: its length does, however, show considerable variation in different hearts.

Anterior wall of left ventricular outflow tract

The anterior wall of the outflow tract is formed by the obliquely orientated ventricular septum. Though the greater part of this wall is formed by the muscular part of the septum, its upper medial

¹Lecture delivered on 6 April 1978 at the Ninth Annual Cardiac Surgical Course organised by the British Post-graduate Medical Federation.

Received for publication 5 June 1978

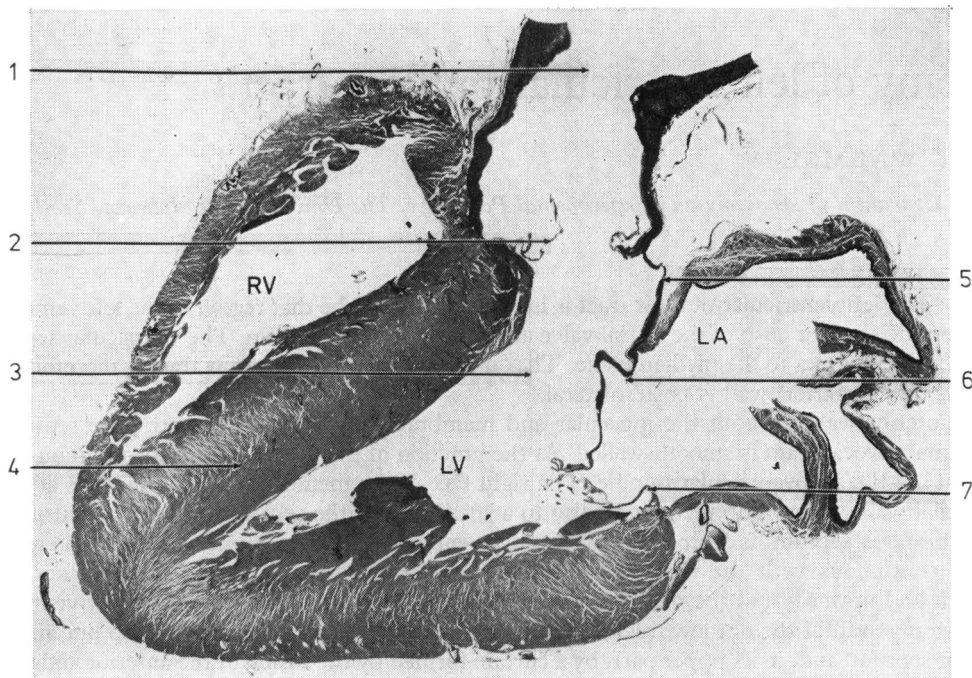


Fig. 1 Section through the heart of a 50-year-old man, to show both the inflow and outflow tracts of left ventricle. The outflow tract of the left ventricle lies in front of the anterior cusp of the mitral valve. The intervalvar septum is unusually long in this heart. The left atrium (LA) is seen to lie behind the left ventricle (LV) and the right ventricle (RV) lies above and in front of the ventricular septum in this oblique section.

(1) ascending aorta; (2) right coronary cusp of aortic valve; (3) left ventricular outflow tract; (4) ventricular septum; (5) intervalvar septum; (6) anterior cusp of mitral valve; (7) posterior cusp of mitral valve.

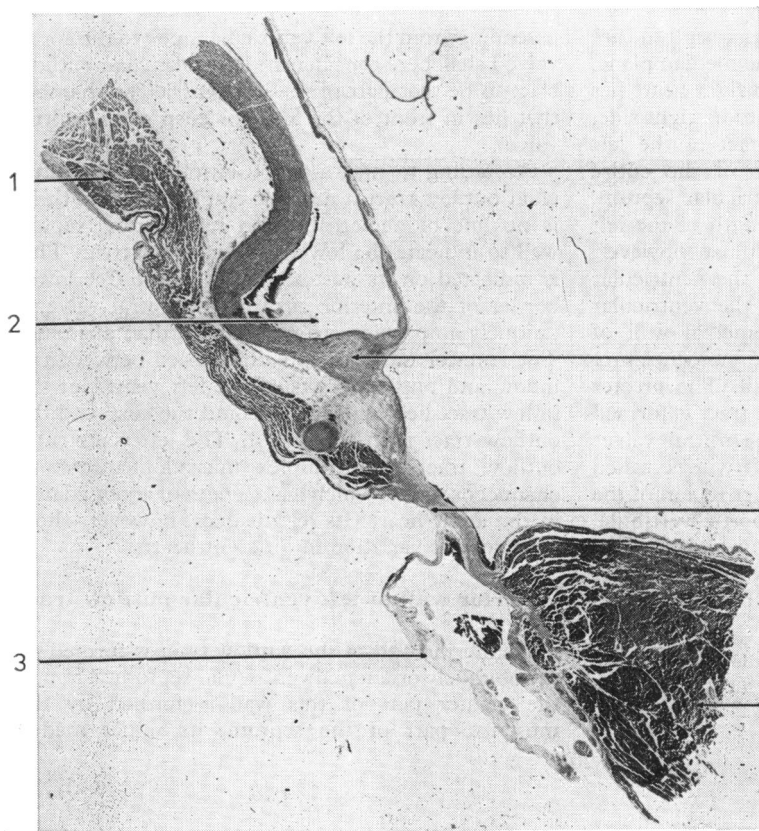


Fig. 2 Section through the right lateral wall of the root of the aorta and membranous and muscular parts of ventricular septum. The septal cusp of the tricuspid valve and the medial wall of the right atrium are attached to the right face of the membranous septum which is orientated obliquely at an angle of about 45 degrees to median plane. (1) Medial wall of right atrium; (2) right coronary aortic sinus; (3) septal cusp of tricuspid valve; (4) right coronary cusp of aortic valve; (5) aortic annulus; (6) membranous septum; (7) muscular ventricular septum.

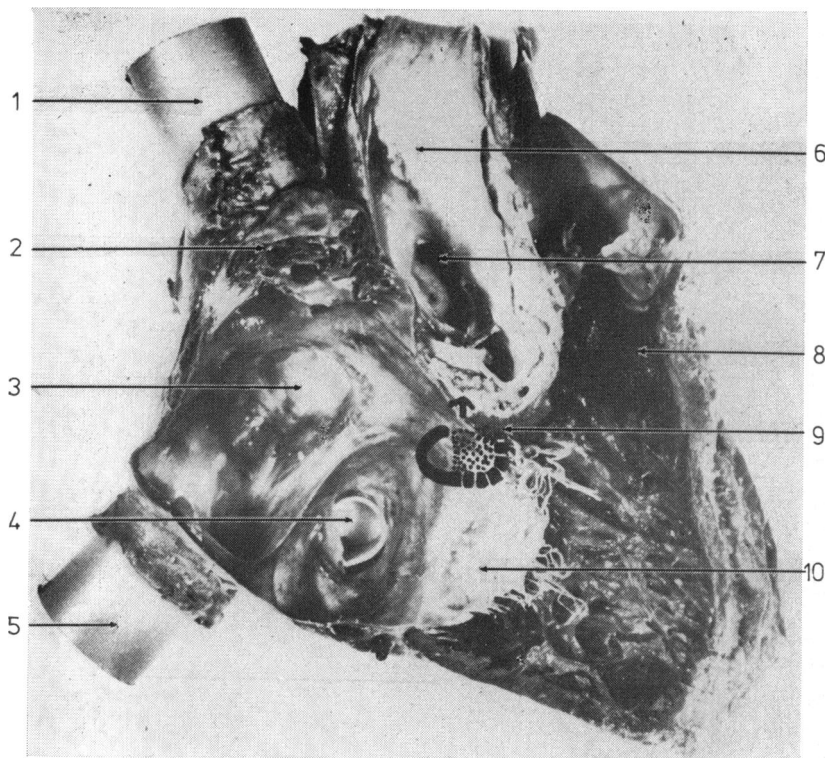


Fig. 3 Section of right heart to show the medial septal wall of the right atrium and the right ventricle. Plastic tubes were inserted into the superior and inferior venae cavae. The septal cusp of the tricuspid valve is seen in its entirety. The region of the membranous septum is indicated by continuous and interrupted lines. The interrupted line and stippled area show the part of the membranous septum that is under cover of the tricuspid valve cusp. The arrow indicates the junction of the right coronary and non-coronary cusps of the aortic valve. (1) Superior vena cava; (2) right atrial appendage; (3) fossa ovalis, right atrium; (4) coronary sinus ostium; (5) inferior vena cava; (6) aorta; (7) left coronary artery ostium; (8) infundibulum, right ventricle; (9) supra-ventricular crest; (10) septal cusp of tricuspid valve.

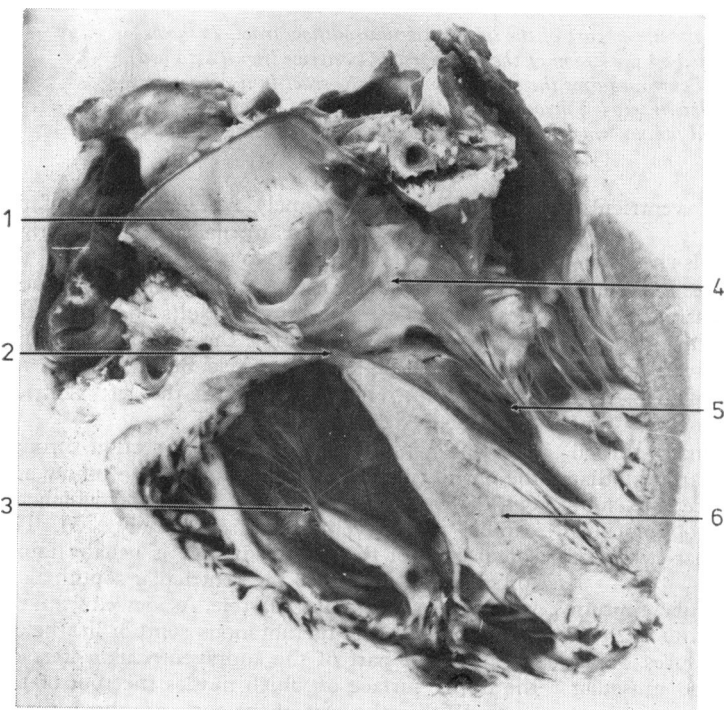


Fig. 4 Oblique section of the heart to show both right and left ventricles and lower part of the ascending aorta. The right lateral wall of the aorta passes downwards and to the left to become continuous with the membranous part of the ventricular septum which overlies the right ventricle. (1) Ascending aorta; (2) membranous part of ventricular septum; (3) right ventricle; (4) anterior cusp of mitral valve; (5) left ventricle; (6) muscular ventricular septum.

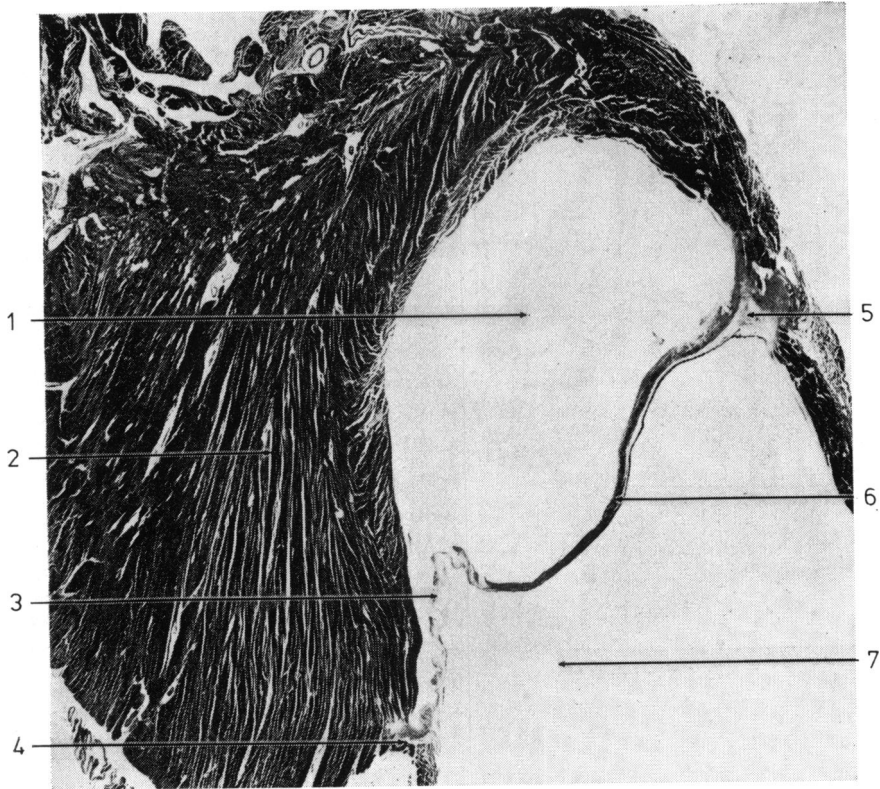


Fig. 5 *Transverse section of the upper part of the left ventricular outflow tract. It shows the curtain or veil that is formed by the fusion of the anterior and posterior (lightly stained) mitral valve cusps. This cuspal curtain forms the posterior wall of the tract in its uppermost part. (1) Left ventricular outflow tract; (2) myocardium of left ventricle; (3) posterior cusp of mitral valve; (4) mitral fibrous 'ring'; (5) central fibrous body; (6) anterior cusp of mitral valve; (7) left atrium.*

part is formed by the membranous ventricular septum.

The myocardium of the anterior wall is characterised by the smoothness of its free surface: in none of many normal human hearts examined has there been any evidence of the trabeculae carneae that are such a prominent feature of the inflow tract of the ventricle. It is to the uppermost part of this septal myocardium that part of the right coronary cusp of the aortic valve is attached (Fig. 1). In many normal hearts examined it is the same myocardium that protrudes so obviously into the immediate sub-aortic part of the outflow tract. Hypertrophy of this myocardium would certainly cause a narrowing of the outflow tract.

The membranous part of the ventricular septum has a maximum breadth of 15 mm in the hearts I have examined histologically and measures about 10 mm from the aortic annulus to the muscular septum (Fig. 2): it is about 1 mm thick.

Two structures, namely the septal cusp of the tricuspid valve and the medial wall of the right atrium, gain attachment to the right face of the membranous septum (Fig. 2). The manner of attachment of these 2 structures results in the membranous septum separating the left ventricle not only from the right ventricle but also from the right atrium. (It also separates the left ventricle from the pericardial cavity.)

It is a simple matter to make a section through the entire right heart to show both the inflow and outflow tracts of the right ventricle which lie parallel to the ventricular septum (Fig. 3). The septal cusp of the tricuspid valve is usually found to be closely applied to the ventricular septum as it would be in ventricular diastole. As viewed from the right ventricle the membranous septum lies below the posterior part of the supraventricular crest on the upper surface of which nestles the root of the aorta. Within the root of the aorta are the 3 dilata-

tions of the aortic sinuses of Valsalva. The junctional zone between the right coronary and noncoronary cusps of the aortic valve lies above the membranous septum.

It is an anatomical fact that the ostium of the left coronary artery, when it is 'on centre' at the middle of the left coronary sinus, lies diametrically opposite the junction of the right coronary and noncoronary cusps: it is, however, at least 25 mm above the cuspal junction. Thus, the upper surface of the closed aortic valve is directed not only upwards but also to the right (Fig. 4).

At the lower part of the junction of the membranous and muscular parts of the ventricular septum lies the atrioventricular bundle of His. Developmentally and anatomically the main His bundle is primarily associated with the myocardium of the septum and through its right and left bundle-branches it supplies the entire musculature of the ventricles. The membranous septum is complex in its development and it is not surprising that a failure in its formation is so frequently a feature of many malformed hearts. In this connection it is important to note that, in the normal heart, the membranous ventricular septum is continuous, through the aortic annulus, with the right lateral or inferior wall of the root of the ascending aorta (Fig. 2).

The obliquity of the root of the aorta is a fact of major anatomical importance. It passes upwards and to the right at an angle of at least 45 degrees to the median plane. The right aortic wall, in the region of the noncoronary sinus, impinges on the anterior part of the medial wall of the right atrium to form the interatrial eminence called the torus aorticus. The membranous septum has, *in situ*, an orientation that is even more nearly horizontal than the right wall of the aortic root (Fig. 4). As the aorta overlies the right ventricle it would not require any dextro-position of its root for it to communicate with the right ventricle if there were a failure in development of the membranous septum.

In an enlarged heart with mitral stenosis and calcification of the 'appositional zones' (Walmsley, 1978) of both mitral cusps the membranous septum was found to be paper-thin.

Posterior wall of left ventricular outflow tract

The greater part of the posterior wall of the outflow

tract is formed by the anterior cusp of the mitral valve.

In the human heart the line of attachment of the anterior wall of the left atrium is below the attachment of the left coronary cusp of the aortic valve (Fig. 1). The intervening space is bridged by a fibrous lamina which has been called the 'intervalvar septum' (Walmsley and Watson, 1978). This septum, which varies between 2 and 10 mm in length in the adult human heart, also participates in the formation of the posterior wall of the outflow tract.

A second additional structure in the posterior wall of the outflow tract is the posterior (mural) mitral cusp. It is well recognised that the cusps of both atrioventricular valves fuse with one another in their basal parts for most of 1 cm. The uppermost part of the posterior wall of the outflow tract is formed, therefore, by a curtain or veil of the fused mitral cusps (Fig. 5). The posterior mitral cusp component of this curtain is easily identified by the notched appearance of its ventricular surface, resulting from the attachments of chordae tendineae of the third order: in microscopical sections it stains lightly. At its lateral or basal side this posterior cusp is attached to the relatively narrow atrioventricular fibrous 'ring' which lies in the depth of the atrioventricular sulcus. On the medial or right side the anterior mitral cusp is attached to the central fibrous body, as it is always seen to be in transverse sections of the heart at this level. It is in sections such as this that the left ventricular outflow tract truly has the appearance of a musculomembranous tunnel.

References

- Walmsley, R. (1978). Anatomy of human mitral valve in adult cadaver and comparative anatomy of the valve. *British Heart Journal*, **40**, 351-366.
- Walmsley, R., and Watson, H. (1978). *Clinical Anatomy of the Heart*. Churchill Livingstone, Edinburgh.

Requests for reprints to Professor Robert Walmsley, Department of Anatomy and Experimental Pathology, University of St Andrews, Bute Medical Buildings, St Andrews KY16 9TS, Scotland.