

M-mode and cross-sectional echocardiographic study of the left ventricular wall motions in complete left bundle-branch block

JUNICHI FUJII, HIROSHI WATANABE, TAN WATANABE, NOBUMITSU TAKAHASHI, AKIO OHTA, AND KAZUZO KATO

From the Cardiovascular Institute, 7-3-10 Roppongi, Minato-ku, Tokyo 106, Japan

SUMMARY M-mode and cross-sectional echocardiograms of 37 patients with complete left bundle-branch block were compared with those of 5 patients with complete atrioventricular block during right ventricular pacing, 20 patients with anteroseptal infarction, and 20 normal subjects.

Of 37 patients with complete left bundle-branch block, 35 showed 3 types (A, B, and C) of abnormal septal motion and 2 patients showed normal septal motion. In type A and B, early and abrupt posteriorly-directed motion of the septum occurred during the pre-ejection period. After this early abnormal motion, the septum moved anteriorly in type A and posteriorly in type B. Type C exhibited akinetic or dyskinetic septal motion throughout systole. The onset of posterior wall contraction was delayed in all patients with complete left bundle-branch block.

These patterns of abnormal septal motion were observed in almost all portions of upper- to mid-septum that could be recorded by cross-sectional echocardiography.

Abnormal septal motion of types A and B was also observed during right ventricular pacing. It is suggested that abnormal septal motion of types A and B could be explained by asynchronous contraction of the left ventricle, with delayed activation of the left side of the septum and of the left ventricular free wall.

The septal motion of type C is almost the same as that seen in patients with extensive septal infarction. Most of the patients having abnormal septal motion of type C had electrocardiographic and vectorcardiographic findings which were compatible with extensive septal infarction. Thus patients with complete left bundle-branch block and type C motion may have sufficient septal damage to prevent the early posterior motion seen in type A and B patients. Different sequence of ventricular activation will be responsible for the difference between type A and B. It is also possible that some patients with type A septal motion may have septal damage to some degree, in contrast to type B.

Normal septal motion recorded in 2 patients with complete left bundle-branch block might be the result of a peripheral block of the left bundle-branch.

M-mode and cross-sectional echocardiography have proved to be valuable in the study of left ventricular wall motion and the assessment of left ventricular function (Diamond *et al.*, 1971; Jacobs *et al.*, 1973; Fujii *et al.*, 1976).

Recently, echocardiography has disclosed a characteristic ventricular septal motion in patients with left bundle-branch block (McDonald, 1973; Dillon *et al.*, 1974). It has been suggested that abnormal septal motion is related to an altered

sequence of activation and contraction. However, no studies have been performed to analyse the left ventricular wall motion in left bundle-branch block by cross-sectional echocardiography.

The purpose of this study was (1) to analyse the motion of the interventricular septum and the left ventricular posterior wall in patients with complete left bundle-branch block by M-mode and cross-sectional echocardiography; (2) to relate septal motion during right ventricular endocardial pacing to that in complete left bundle-branch block; and (3) to compare septal motion in complete left bundle-branch block with that in septal infarction.

Materials and methods

M-mode and cross-sectional echocardiograms of 37 patients with complete left bundle-branch block were compared with those of 5 patients with complete atrioventricular block during right ventricular endocardial pacing, and 20 patients with anteroseptal infarction without complete left bundle-branch block. All 62 patients had normal sinus rhythm. There were 41 men and 21 women. The mean age was 63 years (range 40 to 76). Complete left bundle-branch block was defined according to Massie and Walsh (1960). All 37 patients with complete left bundle-branch block had a QRS duration of 0.12 second or wider (mean 0.135 second). Basic disorders of patients with complete left bundle-branch block are old myocardial infarction (11 patients), angina pectoris (4 patients), congestive cardiomyopathy (6 patients), aortic valve disease (3 patients), hypertrophic cardiomyopathy (2 patients), hypertension (2 patients), and unknown (9 patients). The diagnosis of myocardial infarction was made on the basis of clinical history, increased serum enzyme activity, and electrocardiographic findings. All 5 patients with complete atrioventricular block of unknown aetiology showed normal septal motion before pacing. One of them had left ventricular anterior wall pacing after right ventricular endocardial pacing because of pacing failure. Twenty normal subjects were used as controls.

M-mode and cross-sectional echocardiograms were recorded simultaneously with the electrocardiogram and phonocardiogram, using ALOKA SSD-33 and SSD-110 instruments with a 2.25 MHz unfocused transducer of 10 mm diameter at a repetition rate of 1000 impulses per second (Fujii *et al.*, 1976). Ultrasonic cross-section B-scans were made along the long axis of the left ventricle, with the transducer tilting in sector arc from the base of the heart to the apex, at end-diastole (the onset of R wave in the electrocardiogram), early systole (D point, shown in Fig. 2), and end-systole (aortic component of the second heart sound in phonocardiogram), respectively (Fujii *et al.*, 1976).

Results

The interventricular septum moves slightly in an anterior direction during isovolumetric contraction and shows major posterior motion during subsequent ventricular ejection. In early diastole, it moves anteriorly and returns gradually to a more anterior position during diastasis. Septal motion is of smaller amplitude than posterior wall motion and moves in the opposite direction to posterior wall motion throughout almost the entire cardiac cycle except end-systole. Synergic motion is also shown in the whole extent of the left ventricular wall by cross-sectional echocardiography (Fig. 1).

Of 37 patients with complete left bundle-branch

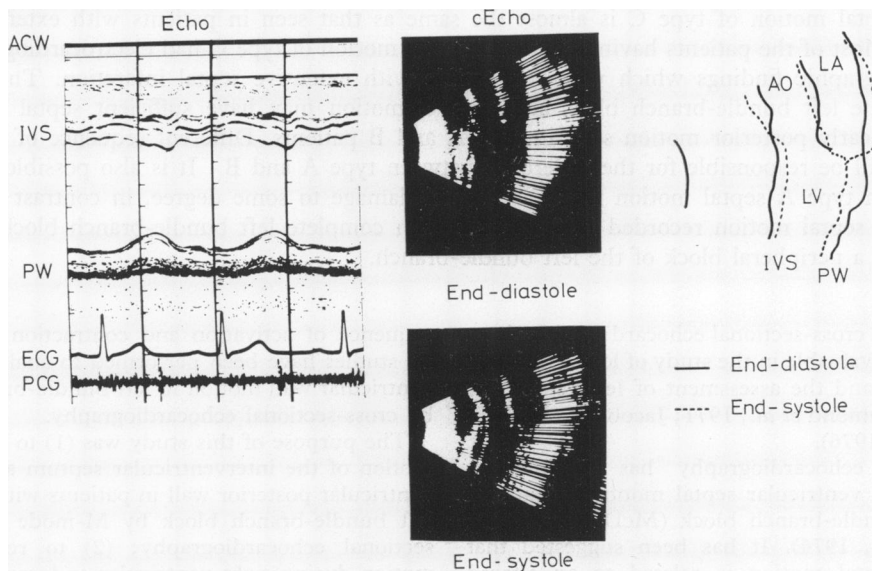


Fig. 1 Echocardiogram (Echo) and cross-sectional echocardiogram (cEcho) through the long axis of the left ventricle at end-diastole and end-systole in a normal subject. ACW, anterior chest wall; IVS, interventricular septum; PW, posterior wall; LA, left atrium; LV, left ventricle; AO, aorta.

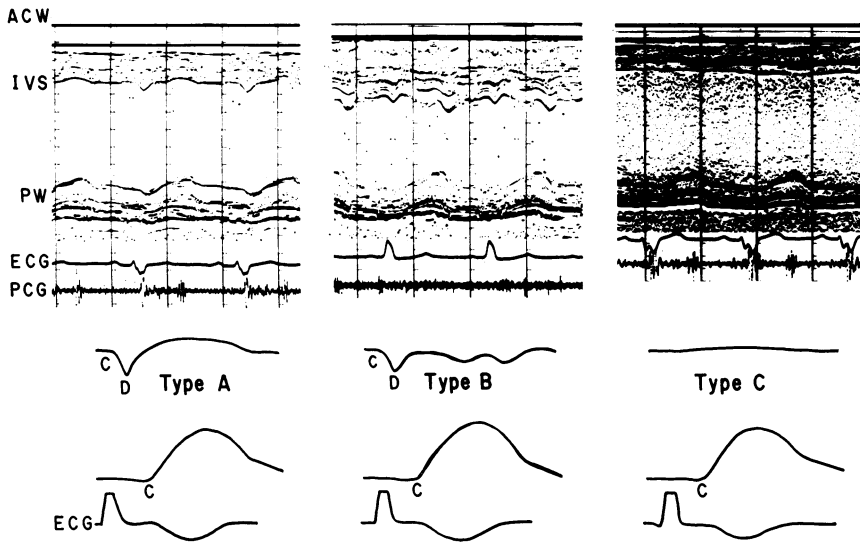


Fig. 2 Echocardiograms showing 3 types (A, B, C) of abnormal septal motions in patients with complete left bundle-branch block.

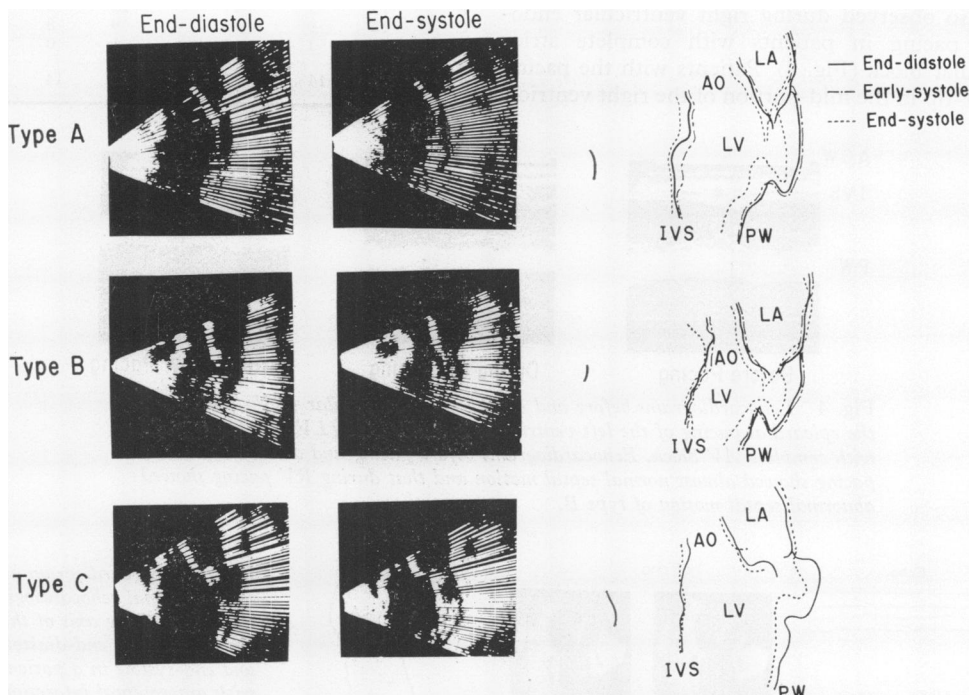


Fig. 3 Cross-sectional echocardiograms through the long axis of the left ventricle at end-diastole, early systole, and end-systole in patients with complete left bundle-branch block, who showed abnormal septal motions of types A, B, C.

block, 35 were found to have 3 types (A, B, C) of abnormal septal motion while the other 2 patients had normal septal motion (Fig. 2).

Among the 35 patients with abnormal septal motion, 23 showed early and abrupt posterior-directed motion of the septum occurring within 51 ± 23 ms (mean ± 1 SD) of the onset of the QRS. The amplitude of this motion was 4 ± 1 mm. After this early abnormal motion, the septum moved anteriorly in 10 patients (type A) and posteriorly in 13 patients (type B); 12 patients exhibited akinetic or dyskinetic septal motion throughout systole without early systolic abnormal motion (type C). Akinetic or dyskinetic septal motion with early systolic posterior motion of small amplitude (less than 2 mm) was included in type C.

The onset of posterior wall contraction occurred within 152 ± 30 ms after the onset of the QRS in all patients with complete left bundle-branch block. This is significantly delayed ($P < 0.01$) since the mean value for normal subjects is 93 ± 14 ms. Cross-sectional echocardiography revealed that the abnormal septal motion occurred in upper- to mid-portions of the septum which could be recorded (Fig. 3).

The abnormal septal motion of types A and B were also observed during right ventricular endocardial pacing in patients with complete atrioventricular block (Fig. 4). Patients with the pacing catheter-tip in the mid-portion of the right ventricle

showed abnormal septal motion of type A. With right ventricular apical pacing, abnormal septal motion of either type A or type B occurred. One patient with abnormal septal motion of type B during right ventricular endocardial pacing showed almost normal septal motion during epicardial pacing of the left ventricular anterior wall (Fig. 4).

Septal motion of type C detected by M-mode and cross-sectional echocardiography was similar to that seen in patients with anteroseptal infarction (Fig. 5). All the 12 patients with type C septal motion had documented cardiac diseases which consisted of either myocardial infarction or congestive cardiomyopathy.

Electrocardiographic and vectorcardiographic ab-

Table Relation between types of abnormal septal motion and abnormal electrocardiographic and vectorcardiographic findings

Type of septal motion	No. of patients	Electrocardiogram		Vectorcardiogram		
		Abnormal Q in I, aVL, V5, 6, or V1-3		No. of patients	Initial vector directed right-anteriorly or left-posteriorly	
		(+)	(-)		(+)	(-)
A	10	2	8	9	3	6
B	13	2	11	13	3	10
C	12	9	3	9	8	1
Normal	2	1	1	1	0	1
n	37	14	23	32	14	18

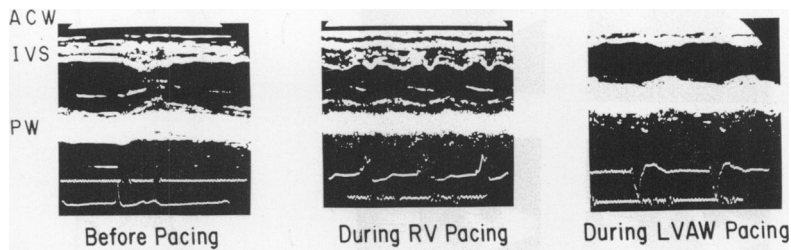


Fig. 4 Echocardiograms before and during right ventricular (RV) pacing and the epicardial pacing of the left ventricular anterior wall (LVAW) in a patient with complete AV block. Echocardiograms before pacing and during LVAW pacing showed almost normal septal motion and that during RV pacing showed abnormal septal motion of type B.

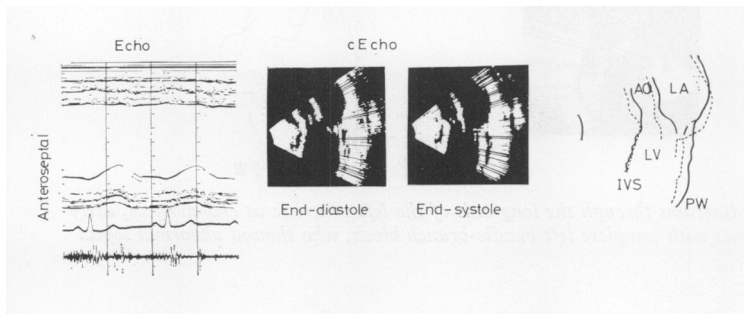


Fig. 5 Echocardiogram and cross-sectional echocardiograms through the long axis of the left ventricle at end-diastole and end-systole in a patient with anteroseptal infarction. Septal motion is dyskinetic, similar to abnormal septal motion in type C.

normalities, which were consistent with extensive septal infarction with complete left bundle-branch block (Chapman and Pearce, 1957; Scott, 1962; Doucet *et al.*, 1966), were observed in 75 per cent and 89 per cent of patients with abnormal septal motion of type C, respectively, contrasting with type A (20%, 33%), and type B (15%, 23%) (Table). These abnormal findings consisted of abnormal Q waves in leads I, aVL, or anterior chest leads, with complete left bundle-branch block. Vectorcardiographic abnormalities consisted of an initial vector directed rightward and anteriorly or leftward and posteriorly.

Discussion

Systolic contraction of the normal human left ventricle is a symmetrical and orderly process which depends on the normal rapid spread of myocardial activation (Amer *et al.*, 1960; Durrer *et al.*, 1970; McDonald *et al.*, 1972). The present study showed that patients with complete left bundle-branch block have 3 types of abnormal septal motion, in contrast to normal subjects. These abnormal septal movements were observed in almost all portions of upper- to mid-septum which could be recorded by cross-sectional echocardiography. The mechanism of the abnormal septal motion in complete left bundle-branch block could be examined by comparing the sequence of activation and contraction of the left ventricle in complete left bundle-branch block with that of normal subjects and that during pacing of the right ventricle. Abnormal septal motion of type A and B was similar to that of complete atrioventricular block during right ventricular pacing. Moreover, experimental study disclosed that ventricular activation begins on the right side of the septum and invades this structure from right to left before activating the free wall of the left ventricle in complete left bundle-branch block (Becker *et al.*, 1958; Sodi-Pallares, 1963; Scott, 1965). It is, therefore, suggested that the abnormal septal motion of types A and B is caused by asynchronous contraction of the left ventricle, with delayed activation of the left side of the septum and of the left ventricular free wall. Patients with the pacing catheter tip in the mid-portion of the right ventricle showed abnormal septal motion of type A, while some patients with right ventricular apical pacing showed abnormal septal motion of type B. These data suggest that a different sequence of ventricular activation and contraction is responsible for the difference between type A and B motion (Gomes *et al.*, 1977; Zoneraich *et al.*, 1977).

However, it is also possible that the septal myocardium is damaged to some degree (though not so

extensively as in type C) in type A, in contrast to type B. The fact that about 20 per cent and 33 per cent of patients with type A septal motion had abnormal electrocardiographic and vectorcardiographic findings which were compatible with septal infarction supports this possibility (Table). Further study is needed to solve this problem. Abnormal septal motion of type C is almost the same as that seen in extensive septal infarction. The underlying cardiac abnormalities of patients with type C septal motion were largely myocardial infarction or congestive cardiomyopathy. A high proportion of patients with abnormal septal motion of type C also had abnormal electrocardiographic and vectorcardiographic findings which were compatible with extensive septal infarction with complete left bundle-branch block (Chapman and Pearce, 1957; Scott, 1962; Doucet *et al.*, 1966). Thus patients with complete left bundle-branch block and type C motion may have sufficient septal damage to prevent the early posterior motion seen in type A and B patients. It is possible that some patients with type A septal motion may have septal damage to some degree, as mentioned above. The normal septal motion recorded in 2 patients with complete left bundle-branch block could be the result of a peripheral, rather than a proximal, block of the left bundle-branch.

References

- Amer, N. S., Stucker, J. H., Hoffman, B. F., Cappelletti, R. R., and Domingo, R. T. (1960). Activation of the interventricular septum studied during cardiopulmonary bypass. *American Heart Journal*, **59**, 224-237.
- Becker, R. A., Scher, A. M., and Erickson, R. V. (1958). Ventricular excitation in experimental left bundle branch block. *American Heart Journal*, **55**, 547-556.
- Chapman, M. G., and Pearce, M. L. (1957). Electrocardiographic diagnosis of myocardial infarction in the presence of left bundle branch block. *Circulation*, **16**, 558-571.
- Diamond, M. A., Dillon, J. C., Haine, C. L., Chang, S., and Feigenbaum, H. (1971). Echocardiographic features of atrial septal defect. *Circulation*, **43**, 129-136.
- Dillon, J. C., Chang, S., and Feigenbaum, H. (1974). Echocardiographic manifestations of left bundle branch block. *Circulation*, **49**, 876-880.
- Doucet, P., Walsh, T. J., and Massie, E. (1966). A vectorcardiographic and electrocardiographic study of left bundle branch block with myocardial infarction. *American Journal of Cardiology*, **17**, 171-179.
- Durrer, D., Van Dam, R. Th., Freud, G. E., Janse, M. J., Meijler, F. L., and Arzbaecher, R. C. (1970). Total excitation of the isolated human heart. *Circulation*, **41**, 899-912.
- Fujii, J., Watanabe, H., and Kato, K. (1976). Detection of the site and extent of the left ventricular asynergy in myocardial infarction by echocardiography and B-scan imaging. *Japanese Heart Journal*, **17**, 630-648.
- Gomes, J. A. C., Damato, A. N., Akhtar, M., Dhath, M. S., Calon, A. H., Reddy, C. P., and Moran, H. E. (1977). *American Journal of Cardiology*, **39**, 641-650.
- Jacobs, J. J., Feigenbaum, H., Corya, B. C., and Philips, J. F. (1973). Detection of left ventricular asynergy by echo-

- cardiography. *Circulation*, **48**, 263-271.
- McDonald, I. G. (1973). Echocardiographic demonstration of abnormal septal motion of interventricular septum in left bundle branch block. *Circulation*, **48**, 272-280.
- McDonald, I. G., Feigenbaum, H., and Chang, S. (1972). Analysis of left ventricular wall motion by reflected ultrasound. *Circulation*, **46**, 14-25.
- Massie, E., and Walsh, T. J. (1960). *Clinical Vectorcardiography and Electrocardiography*. Year Book Medical Publishers, Chicago.
- Scott, R. C. (1962). Current concepts of ventricular activation in the normal heart, in left bundle branch block and in left bundle branch block with myocardial infarction. *American Heart Journal*, **64**, 696-705.
- Scott, R. C. (1965). Left bundle branch block. A clinical assessment. Part I. *American Heart Journal*, **70**, 535-566.
- Sodi-Pallares, D. (1963). Electrocardiographic diagnosis of myocardial infarction in the presence of bundle branch block, ventricular premature beats and Wolff-Parkinson-White syndrome. *Progress in Cardiovascular Diseases*, **6**, 107-136.
- Zoneraich, S., Zoneraich, O., and Rhee, J. J. (1977). Echocardiographic evaluation of septal motion in patients with artificial pacemakers: vectorcardiographic correlation. *American Heart Journal*, **93**, 596-602.

Requests for reprints to Dr Junichi Fujii, The Cardiovascular Institute, 7-3-10 Roppongi, Minato-ku, Tokyo 106, Japan.