

# Thallium-201 myocardial imaging in evaluation of asymptomatic individuals with ischaemic ST segment depression on exercise electrocardiogram<sup>1</sup>

DENNIS G. CARALIS, IAN BAILEY, HAROLD L. KENNEDY, AND BERTRAM PITT

*From the Department of Clinical Investigations, Baltimore US Public Health Service Hospital, and the Johns Hopkins Hospital Department of Medicine (Division of Cardiology), Baltimore, Maryland, USA*

**SUMMARY** Asymptomatic adults with normal physical examination, normal resting electrocardiogram, and normal routine laboratory evaluation who have a positive exercise electrocardiogram and abnormal exercise thallium-201 myocardial image have a very high probability of angiographically significant coronary artery disease. If, on the other hand, the exercise electrocardiogram is positive for 'ischaemic' ST segment changes, but the exercise thallium image is normal, the probability for coronary disease is low. The exercise electrocardiogram combined with thallium-201 myocardial image are safe non-invasive methods which can be performed on an out-patient basis.

The ST segment response on the exercise electrocardiogram has been increasingly used as a method to detect individuals with ischaemic heart disease. Its popularity is based on epidemiological studies (Bruce and McDonough, 1969; Doyle and Kinch, 1970; Froelicher *et al.*, 1974; Aronow and Cassidy, 1975) of asymptomatic subjects with positive ST segment response to exercise, predicting a higher risk of developing myocardial ischaemic events over the next several years. However, the predictive accuracy of a positive exercise electrocardiogram in asymptomatic individuals who agreed to have coronary arteriographic studies performed is less than 53 per cent (Froelicher *et al.*, 1973; Borer *et al.*, 1975).

Thallium-201 myocardial imaging has recently been shown to be a sensitive method to detect transient myocardial ischaemia (Bailey *et al.*, 1977). Thallium-201 has biological properties similar to potassium-43 (Zaret *et al.*, 1973) and is taken up by viable myocardial cells with an intact sodium-potassium ATPase system in proportion to myocardial blood flow in accordance with the Sapirstein principle (Sapirstein, 1956). Areas of myocardial ischaemia can be detected by a relative decrease in regional tracer uptake (Strauss *et al.*, 1973). The present study was undertaken in an effort to determine whether thallium-201 (<sup>201</sup>Tl) myocardial imaging at rest and during maximal exercise is

<sup>1</sup>Presented in part during the 26th Annual Scientific Meeting of the American College of Cardiology.

Received for publication 8 May 1979

useful in the evaluation of asymptomatic patients with a positive exercise electrocardiogram.

## Patients and methods

Out of 3496 consecutive treadmill exercise tests performed primarily on asymptomatic patients, 22 asymptomatic individuals with normal physical examination developed 2 mm or more horizontal ST segment depression on the electrocardiogram during maximal exercise. These individuals had routine laboratory studies, chest x-ray films, resting electrocardiogram both in the supine and standing position and after hyperventilation all of which were normal. The ST depression during exercise testing was not associated with chest pain or any other angina-like symptoms. Fifteen of these 22 patients agreed to be evaluated further. There were 14 men and one woman with a mean age of 53 years (range 27 to 62 years). The female patient had a history of episodic ventricular tachycardia.

## MYOCARDIAL IMAGING

Thallium-201<sup>2</sup> was administered intravenously in a dose of 1.5-2 mCi for both the rest and exercise myocardial studies with the patient fasting and upright to minimise hepatic and gastric concentration.

<sup>2</sup>Thallium-201 (thallous chloride) was supplied as a sterile pyrogen-free radiopharmaceutical in 0.9 per cent saline at pH 5-6 in a specific activity of 1 mCi/ml (Philips-Duphar or New England Nuclear). The half life of the isotope is 72 hours. The radiation burdens are: 0.7 rads/mCi whole body, and to the target organs, kidney, and gonads 0.5 rads/mCi (Cook *et al.*, 1976).

Myocardial imaging began 10 minutes after the tracer administration. Images were recorded with the patient supine in the anterior view, 40 and 60 degree left anterior oblique views (obtained by rotating the detector). This procedure (Bailey *et al.*, 1977) facilitated comparison of each rest view with each view obtained after exercise. A 37 photomultiplier tube Anger type scintillation camera (Ohio Nuclear Series 100) equipped with high resolution parallel hole collimator was used. Images were recorded with a 20 per cent window centred on the mercury *x*-ray peaks (69–80 keV). A total of 50 000 counts was recorded in the region of the myocardium (approximately 200–300 000 counts/image) to minimise the statistical fluctuations in the thallium image. This resulted in a count density of at least 1000 counts/cm<sup>2</sup> over the region of the left ventricular myocardium. Images were recorded into an Ohio Nuclear Series 150 data system after uniform field correction and stored on magnetic tape. Imaging in each of the views required 8 to 12 minutes. The rest and exercise studies were performed one week apart. The patients were familiarised with the exercise procedure during a previous visit. An indwelling Teflon cannula was inserted percutaneously into a forearm vein and kept patent with a slow infusion of saline to facilitate injection of tracer during exercise. Exercise was carried out in the imaging laboratory using an electrically braked Godart bicycle ergometer according to the following procedure. After an initial warm-up period of cycling without workload, the load was set at 50 watts and then increased by 25 watt increments every three minutes until further exercise was limited by breathlessness, fatigue, or the occurrence of an arrhythmia. <sup>201</sup>Tl was injected at peak exercise and patients were encouraged to maintain a constant level of exercise for an additional one minute. Continuing exercise after tracer injection was important in order to achieve the state during which the majority of the tracer is cleared from the blood. The electrocardiogram and systemic pressure were monitored throughout the exercise and the recovery periods. The subjects remained seated on the bicycle while the post-exercise electrocardiograms were recorded. When electrocardiograms were completed, the patient was placed supine beneath the scintillation camera and imaging was started. The time interval between thallium-201 myocardial imaging and coronary arteriography was less than six weeks in all patients. No clinical coronary event occurred between any of the studies. The electrocardiogram was recorded in the same fashion as described earlier.

The myocardial images were interpreted by two observers before coronary arteriography was carried

out. Images from the study patients and known normal subjects were randomly mixed. All the resting images were normal, showing a homogeneous tracer distribution in the region of the left ventricular myocardium. A normal variant pattern includes somewhat decreased uptake of radionuclide in the apical region, probably resulting from the geometry of the left ventricle. This variant pattern has been seen in about 20 per cent of normal individuals (Zaret, 1977). To determine the percentage of the left ventricle that was involved by a tracer defect, the outline of the left ventricle in each projection was traced. The area of decreased tracer uptake was then superimposed on the left ventricular outline and expressed as a percentage of the left ventricular circumference, excluding the region of the aortic valve plane in the anterior projection, and the aortic and mitral valve planes in the left anterior oblique projection. A previous investigation (Cook *et al.*, 1976) has disclosed that normal individuals may have small regions of decreased tracer concentration at the apex, as mentioned above, or at the region of insertion of the mitral valve on the high posterolateral wall of the left ventricle. The exercise myocardial <sup>201</sup>Tl image was evaluated in a similar fashion. The pair of rest and exercise studies was examined together and considered positive for ischaemia only if a new perfusion defect involving more than 15 per cent of left ventricular circumference appeared during exercise and had not been present at rest.

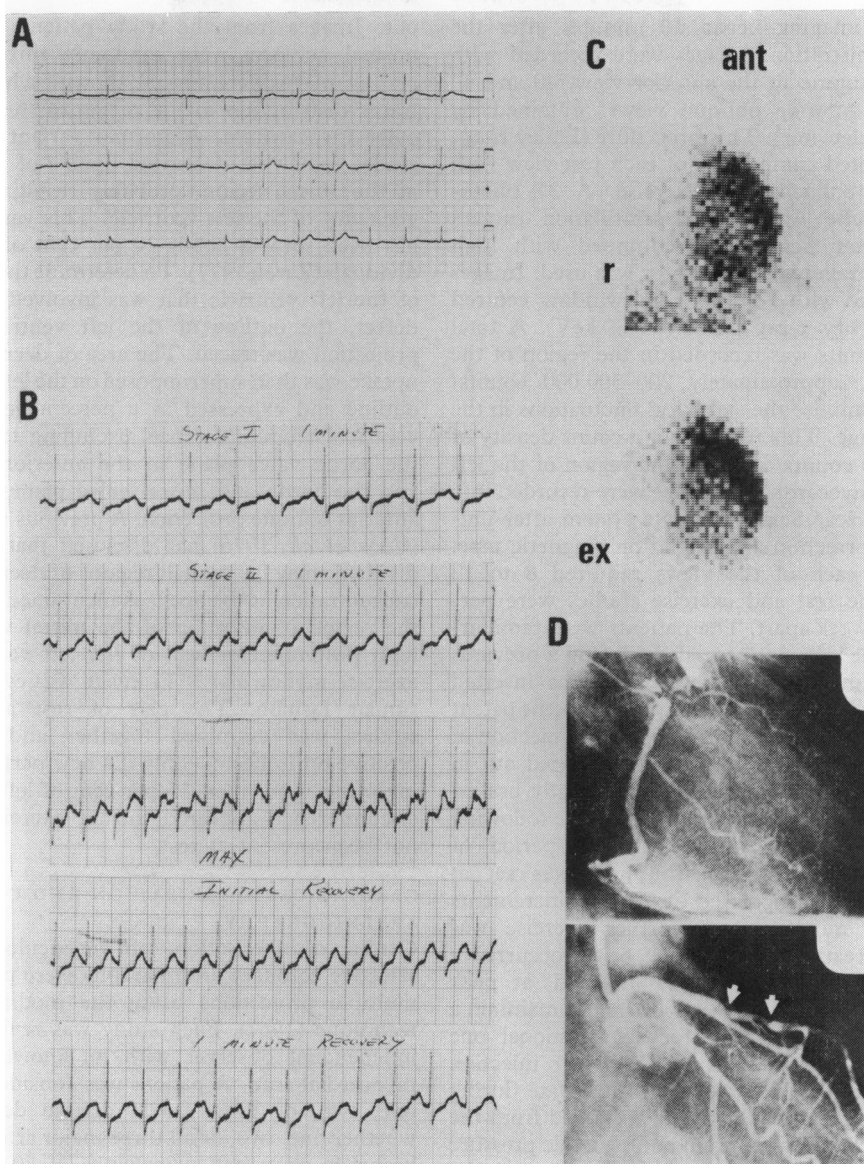
#### CARDIAC CATHETERISATION AND CORONARY ARTERIOGRAPHY

Cardiac catheterisation, left ventriculography, and selective coronary arteriography were performed in multiple projections using the modified Judkins technique (1967). Each study was reviewed by an independent observer with no knowledge of the myocardial scan. A patient was considered to have one, two, or three vessel disease depending on whether one, two, or all three major arteries of their branches contained narrowings of 70 per cent or more of the respective luminal area. A narrowing of greater than 70 per cent in the main left coronary artery was considered as a significant narrowing of both the anterior descending and circumflex coronary arteries.

All electrocardiograms, and <sup>201</sup>Tl myocardial images and angiograms were technically adequate for evaluation. Informed consent was obtained from all volunteers and there were no complications resulting from any of these procedures.

#### Results

All exercise electrocardiograms both during tread-

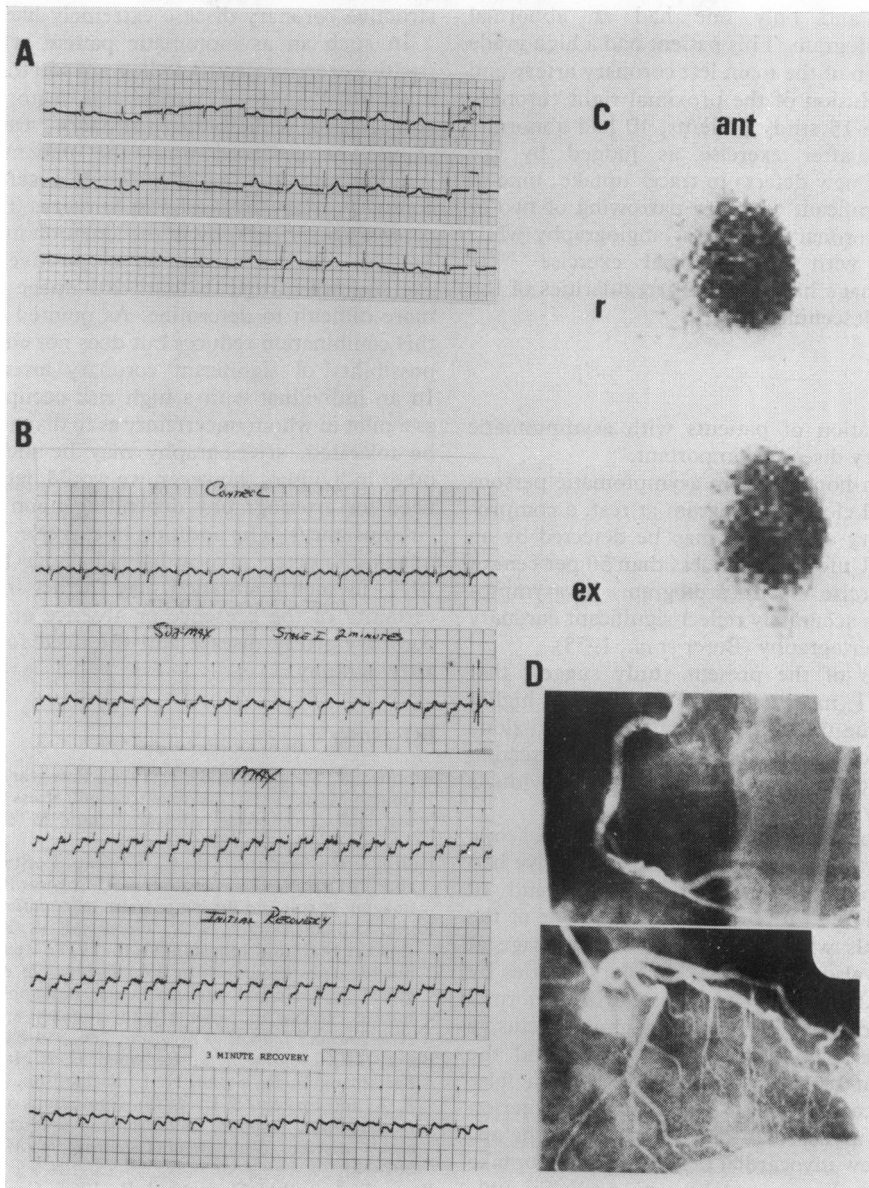


**Fig. 1** Findings in a 61-year-old asymptomatic man. (A) Normal electrocardiogram at rest. (B) Abnormal exercise electrocardiogram showing 3 mm horizontal ST depression, rate 165/min, lead V5. (C) Thallium-201 myocardial scan at rest (r) and exercise (ex) in the anterior (ant) and 60° left anterior oblique projections. The rest study shows a relatively uniform pattern of tracer uptake in the left ventricular myocardium. The exercise study shows a perfusion defect involving the inferior wall. (D) Selective coronary arteriography from the same patient. The right coronary artery (top) is totally occluded, proximally, and the left anterior descending artery has high grade occlusive lesions proximally (arrows) in this asymptomatic man with a 'dominant right coronary circulation'.

mill testing and on the bicycle ergometer, done at different times, exhibited 2 mm or more horizontal ST depression in lead V5. All patients had a normal

homogeneous pattern of  $^{201}\text{Tl}$  uptake at rest.

Of the 15 asymptomatic individuals with horizontal ST depression on exercise testing, five had



**Fig. 2** Findings in a 65-year-old asymptomatic man. (A) Normal electrocardiogram at rest. (B) Abnormal exercise electrocardiogram showing 3-5 mm horizontal ST depression, rate 152/min, lead V5. (C) Thallium-201 myocardial scan at rest (r) and exercise (ex) in the anterior (ant) and 60° left anterior oblique projections. The rest study shows a relatively uniform pattern of tracer uptake in the left ventricular myocardium. The exercise study showed no radiopenic areas in any projection. (D) Selective coronary arteriography from the same patient. The right coronary artery (top) is normal. The left coronary arterial system (bottom) is free of any occlusive lesions.

normal  $^{201}\text{Tl}$  myocardial image after exercise while 10 individuals developed new defects in tracer

uptake. Four of the five individuals with a normal exercise thallium-201 image had normal coronary

arteriograms and only one had an abnormal coronary arteriogram. This patient had a high grade occlusive lesion of the main left coronary artery and near total occlusion of the proximal right coronary artery. Of the 15 study patients, 10 had abnormal  $^{201}\text{Tl}$  images after exercise as judged by the appearance of new defects in tracer uptake; nine of these had significant coronary narrowing of two or more major coronary vessels at angiography while one patient with an abnormal exercise  $^{201}\text{Tl}$  myocardial image had minimal irregularities of the left anterior descending artery.

## Discussion

The identification of patients with asymptomatic coronary artery disease is important.

It had been hoped that in asymptomatic persons with a normal electrocardiogram at rest, a compromised coronary circulation may be detected by an exercise test. Unfortunately, less than 50 per cent of 'positive' exercise electrocardiograms in asymptomatic subjects accurately reflect significant coronary disease by arteriography (Borer *et al.*, 1975).

The results of the present study suggest that exercise  $^{201}\text{Tl}$  myocardial image has a higher predictive value than ST segment depression alone on the exercise electrocardiogram in detecting myocardial ischaemia in asymptomatic individuals with coronary artery disease.

Of the 15 patients who were positive for ischaemic ST changes on exercise electrocardiogram, five had normal exercise  $^{201}\text{Tl}$  myocardial image and 10 had abnormal  $^{201}\text{Tl}$  myocardial image. Four of the five individuals with normal myocardial image at peak exercise also had normal coronary arteries by angiography. However, one patient with a normal  $^{201}\text{Tl}$  myocardial image had high grade occlusive lesions of the main left coronary artery and the proximal right coronary artery. This was a false negative myocardial image. The diagnostic criterion for a positive myocardial image is based on the appearance of new myocardial defects in tracer uptake after exercise. Tracer uptake was probably uniformly reduced in this patient. This homogeneity of myocardial perfusion in some patients with triple vessel coronary disease has been noted before for both  $^{201}\text{Tl}$  (Bailey *et al.*, 1977) and other cationic tracers (Hall *et al.*, 1975). Ten patients had an abnormal exercise  $^{201}\text{Tl}$  myocardial image. Nine out of 10 had significant coronary disease by angiography and one had minimal and insignificant lesions in the anterior descending system. The finding of a positive exercise myocardial image in an asymptomatic patient with a positive exercise electrocardiogram makes the probability of ob-

structive coronary disease extremely likely.

In such an asymptomatic patient with both a positive exercise electrocardiogram and thallium-201 myocardial image we advise risk factor reduction and further follow-up. Coronary arteriography should be reserved until the patient becomes symptomatic and is considered a candidate for coronary artery bypass graft surgery. The role of coronary arteriography in the situation in which the exercise electrocardiogram is positive and the exercise myocardial thallium-201 image negative is more difficult to determine. As pointed out above, this combination reduces but does not eliminate the possibility of significant coronary artery disease. In an individual with a high risk occupation such as a pilot in whom uncertainty as to diagnosis cannot be tolerated, arteriography may be indicated. In other individuals, however, we would determine the need for arteriography depending upon individual circumstances. The addition of exercise, blood pool imaging to detect myocardial ischaemia (Borer *et al.*, 1977) in such a situation may further increase the certainty of the presence or absence of significant coronary artery disease and the need for coronary arteriography.

## References

- Aronow, W. S., and Cassidy, J. (1975). Five year follow-up on double Master's test, maximal treadmill stress test and resting and postexercise apexcardiogram in asymptomatic persons. *Circulation*, **52**, 616-618.
- Bailey, I. K., Griffiths, L. S. C., Rouleau, J., Strauss, H. W., and Pitt, B. (1977). Thallium-201 myocardial perfusion imaging at rest and during exercise. *Circulation*, **55**, 79-87.
- Borer, J. S., Bacharach, S. L., Green, M. V., Kent, K. M., Epstein, S. E., and Johnston, G. S. (1977). Real-time radionuclide cineangiography in the non-invasive evaluation of global and regional left ventricular function at rest and during exercise in patients with coronary artery disease. *New England Journal of Medicine*, **296**, 839-844.
- Borer, J. S., Brensike, J. F., Redwood, D. R., Itscoitz, S. B., Passamani, E. R., Stone, N. J., Richardson, J. M., Levy, R. I., and Epstein, S. E. (1975). Limitations of the electrocardiographic response to exercise in predicting coronary artery disease. *New England Journal of Medicine*, **293**, 367-371.
- Bruce, R. A., and McDonough, J. R. (1969). Coronary disease and exercise. *Texas Medicine*, **65**, 73-77.
- Cook, D. J., Bailey, I., Strauss, H. W., Rouleau, J., Wagner, H. J., jun, and Pitt, B. (1976). Thallium-201 for myocardial imaging: appearance of the normal heart. *Journal of Nuclear Medicine*, **17**, 583-589.
- Doyle, J. T., and Kinch, S. H. (1970). The prognosis of an abnormal electrocardiographic stress test. *Circulation*, **41**, 545-553.
- Froelicher, V. F., jun, Thomas, M. M., Pillow, C., and Lancaster, M. D. (1974). Epidemiologic study of asymptomatic men screened by maximal treadmill testing for latent coronary artery disease. *American Journal of Cardiology*, **34**, 770-776.
- Froelicher, V. F., Yanowitz, F. G., Thompson, A. J., and Lancaster, M. (1973). The correlation of coronary angio-

- graphy and the electrocardiographic response to maximal treadmill testing in 76 asymptomatic men. *Circulation*, **48**, 597-604.
- Hall, R. R., McGowan, R. L., Bryson, A. L., Flam, M. D., Martin, N. D., and Grant, D. (1975). Correlation of non-invasive myocardial imaging studies with coronary angiography in the evaluation of patients for obstructive coronary artery disease. *Circulation*, **51** and **52**, Suppl. II, 110.
- Judkins, M. P. (1967). Selective coronary arteriography. I. A percutaneous transfemoral technic. *Radiology*, **89**, 815-824.
- Sapirstein, L. A. (1956). Fractionation of the cardiac output of rats with isotopic potassium. *Circulation Research*, **4**, 689-692.
- Strauss, H. W., Zaret, B. L., Martin, N. D., Wells, H. P., jun, and Flam, M. D., jun (1973). Non-invasive evaluation of regional myocardial perfusion with potassium 43. *Radiology*, **108**, 85-90.
- Zaret, B. L. (1977). Myocardial imaging with radioactive potassium and its analogs. *Progress in Cardiovascular Diseases*, **20**, 81-94.
- Zaret, B. L., Strauss, H. W., Martin, N. D., Wells, H. P., jun, and Flamm, M. D., jun (1973). Non-invasive regional myocardial perfusion with radioactive potassium. *New England Journal of Medicine*, **288**, 809-812.

Requests for reprints to Dr D. G. Caralis, The Johns Hopkins Hospital, Baltimore, Maryland 21205, USA.