

# Lightning and the heart

S H D JACKSON,\* D J PARRY

*From the Department of Medicine, Good Hope General Hospital, Sutton Coldfield, West Midlands*

**SUMMARY** Two patients sustained lightning-induced myocardial necrosis and had clinical evidence of myocardial injury. In the first case, clinically more severely affected, the electrocardiographic changes simulated acute inferior myocardial infarction while in the second case only mild non-specific ST and T wave changes were seen. The presence of cardiac muscle creatine kinase isoenzyme confirmed that these non-specific changes also reflected myocardial necrosis. Resting thallium-201 myocardial imaging in the first case showed normal perfusion. In both cases there was complete clinical and electrocardiographic recovery.

Lightning injuries may involve almost any organ. Myocardial necrosis after lightning injury has been demonstrated at necropsy.<sup>1-3</sup> During life, however, this has only been inferred from electrocardiography and vonventional serum cardiac enzyme studies. The extent to which the raised serum enzymes reflect myocardial damage, so far as we know, has not previously been reported. We describe two patients in whom lightning injury involved the heart and in whom cardiac creatine kinase (CK) isoenzyme was assayed. In the first, electrocardiographic abnormalities of acute inferior myocardial necrosis were present but serum cardiac CK was absent and thallium-201 myocardial imaging showed normal perfusion of the inferior surface of the heart. In the second case despite only transient electrocardiographic changes the cardiac muscle CK isoenzyme was raised.

## Case histories

On 4 June 1978 lightning struck a group of three doctors with their families enjoying a Saturday afternoon at a leisure park. They had been caught in a thunderstorm and were sheltering under a tree. Of the five adults and three children in the group only three adults were injured.

The two most seriously affected arrived in the casualty department within 30 minutes.

### CASE 1

A 41-year-old man had been holding an umbrella in his right hand and a baby in his left arm. The

baby was unhurt. His first memory after the event was of complete paralysis of both legs and right arm followed by gasping for breath. During the following 30 minutes he regained the power in his limbs but developed a severe burning pain in his right arm and shoulder. He had no history of heart disease nor had he ever had an electrocardiogram recorded. There were extensive first degree burns of his right arm and shoulder together with singed hairs on the left leg and right chest. The remains of the corresponding part of his shirt are shown in Fig. 1. There was an exit burn on the lateral aspect of the right foot approximately 1 mm in diameter. A corresponding hole had been burnt in the right shoe (Fig. 2). The blood pressure was 110/70 mmHg and there were no signs of cardiac failure. Tone, power, and reflexes were reduced in both legs; plantar responses were flexor. There was complete destruction of the tympanic membrane on the right side with corresponding loss of air conduction. Over the six hours after admission his systolic blood pressure fell progressively to 80 mmHg, but this returned to normal after four hours.

Serial hydroxybutyrate dehydrogenase (SHBD), total CK, alanine transaminase (ALT) levels (Table), and electrocardiograms (Fig. 3) were performed. Thallium-201 resting myocardial imaging at 19 days showed normal perfusion of the inferior surface of the heart, despite the electrocardiographic abnormalities. He made a good recovery, his burns healing without scarring. At three months only the Q waves persisted on the electrocardiogram and these were less than 2 mm in amplitude and less than 0.04 seconds in duration. Myringoplasty will be performed in due course.

\*Present address: Vancouver General Hospital, 855 West 12th Avenue, Vancouver, BC, Canada V5Z 1M9.

Received for publication 3 August 1979

### CASE 2

A 43-year-old man had severe, tight, central chest pain together with shortness of breath. His first memory on 'waking up' was that he was totally paralysed. As the paralysis disappeared he developed paraesthesiae initially in the right arm and then in both legs. The chest pain developed some minutes later. Again, there was no relevant past history. There were singed hairs over the right arm and leg and an exit burn on the lateral aspect of the right foot, approximately 1 mm in diameter. The blood pressure was 90/60 mmHg rising to 110/70 mmHg after 15 minutes. There was no neurological deficit. The electrocardiogram at one hour showed non-specific ST-T wave changes in the anterolateral leads (Fig. 3). These changes had resolved after 24 hours. Serial enzyme studies are shown in the Table. He made a rapid recovery and was discharged after

five days complaining only of mild aches and pains. A week later he still had some weakness of grip and dorsiflexion of the foot on the left, with an extensor plantar response on the left.

### Discussion

The atmospheric conditions that give rise to lightning are now well known.<sup>3-5</sup> Lightning may cause current to flow by direct strike, side flash, or step voltage, depending on local circumstances. Side flash occurs when a direct strike hits a conductor of high resistance and represents a pathway of lower resistance. The step voltage effect is caused by a potential difference being set up between the feet.<sup>4</sup> The mechanisms by which injuries are produced include (a) electrical burns; (b) interference with the electrical status of neuro-

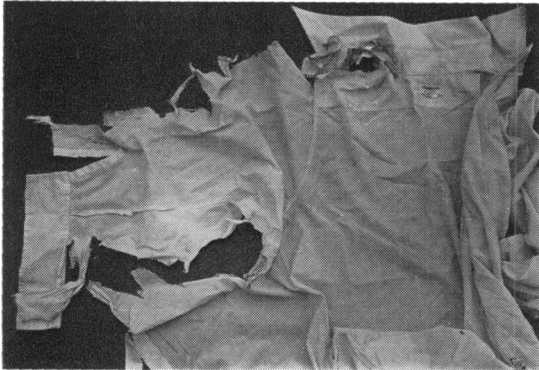

Fig. 1 Shirt from case 1.

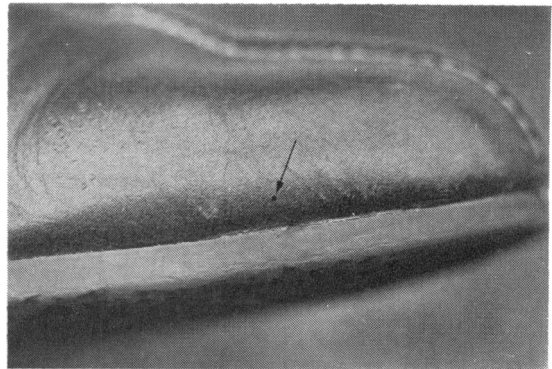


Fig. 2. Right shoe from case 1 showing exit burn hole.

Table Serial serum enzyme studies

Investigations	Approximate time after injury					
	1 h	24 h	48 h	72 h	4 d	9 d
Case 1						
SHBD (IU/l)	577	268	214			133
Total CK (IU/l)	248	701	533			400
CK isoenzymes:						
Skeletal muscle	+ve		+ve	+ve		
Cardiac muscle	-ve		-ve	-ve		
Brain	-ve		-ve	-ve		
ALT (IU/l)		673		314		89
Case 2						
SHBD (IU/l)		166	207		204	
Total CK (IU/l)		1752	832		431	
CK isoenzymes:						
Skeletal muscle		+ve			+ve	
Cardiac muscle		+ve			-ve	
Brain		-ve			-ve	
ALT (IU/l)		58			54	

Reference values: Hydroxybutyrate dehydrogenase (SHBD) = < 230 IU/l.  
 Total creatine kinase (CK) = 20 to 170 IU/l.  
 Alanine transaminase (ALT) = < 30 IU/l.

muscular cells (including the effects of muscular spasm and cardiac arrhythmias); and (c) blast injuries.

In both our patients the findings were compatible with a combination of step voltage and side flash injuries. The step voltage effect characteristically caused paralysis and weakness of the legs. The more serious injuries in our first patient were probably

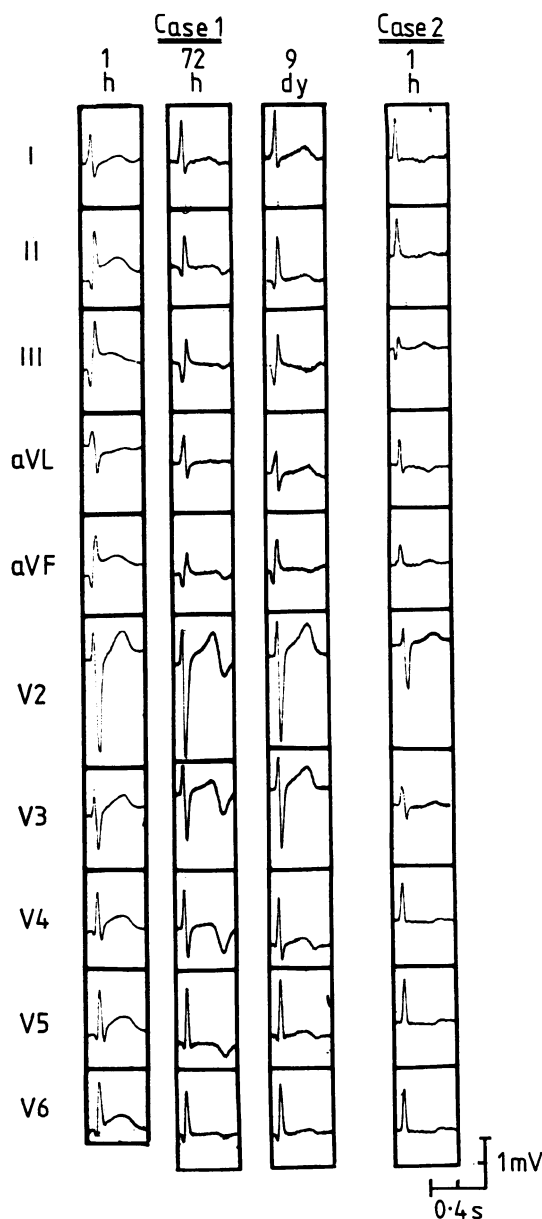


Fig. 3 Serial electrocardiograms from case 1 and initial electrocardiogram from case 2.

the result of a side flash rather than a direct strike.<sup>6</sup> The group was sheltering under a large tree and was within 15 feet of a railway line. A furrow had been produced in the ground by the lightning, linking the group with the railway line. The likely sequence of events was that the lightning hit the nearby tree and took the path of least resistance by side flashing to the umbrella, thence through the patient, and finally across the ground to the railway line.

The burns and singed hairs suggest that the major pathway taken by the lightning was superficial in both patients, perhaps partly because of wet clothes. The appearances in the tympanic membrane were those of an electric burn, which is not in keeping with the usual finding of blast injury.<sup>6</sup> The late neurological sequelae in case 2 suggest pyramidal tract damage but the significance of this is not clear, though delayed neurological effects have recently been attributed to oedema of the spinal cord.<sup>7</sup>

In the first patient the clinical course and serial changes in the inferior electrocardiographic leads suggest that transmural myocardial necrosis occurred. In addition, the ST-T wave changes in the anterolateral leads suggest that diffuse myocardial injury may also have occurred. The absence of cardiac CK isoenzyme in the presence of myocardial necrosis could be explained by the more rapid clearance of the cardiac relative to the skeletal muscle isoenzyme,<sup>8</sup> the assay not being performed at 24 hours on this patient. The normal thallium imaging suggests that the necrosis was not the result of infarction. However, myocardial imaging is a qualitative study dependent on the demonstration of relative differences of radionuclide uptake. Hence, particularly in situations where there are diffuse changes on the electrocardiogram, false negative studies can occur.<sup>9</sup>

In the second patient the early clinical course and ST-T wave changes, though non-specific in themselves, are confirmatory evidence that the cardiac CK isoenzyme represents myocardial necrosis.

It is clear from our cases that while myocardial necrosis resulting from lightning injury may produce electrocardiographic abnormalities simulating acute myocardial infarction, it may also produce short-lived non-specific ST-T wave changes. Further, we suggest that in this context where skeletal muscle damage almost invariably occurs, total CK levels may be misleading.

#### References

- <sup>1</sup>Hanson GL, McIlwraith GR. Lightning injury: two case histories and a review of management. *Br Med J* 1973; 4: 271-4.

- <sup>2</sup>Myers GJ, Colgan MT, VanDyke DH. Lightning-strike disaster among children. *JAMA* 1977; **238**: 1045-6.
- <sup>3</sup>Kravitz H, Wasserman MJ, Valaitis J, Anzinger RE, Naidu SH. Lightning injury. *Am J Dis Child* 1977; **131**: 413-5.
- <sup>4</sup>*Lancet*. Death by lightning. 1977; **1**: 230.
- <sup>5</sup>Dawson G, Fuguay DM, Kasemir HW. Lightning modification. In: Hess WN, ed. *Weather and climate modification*. New York: Wiley, 1974: 596-629.
- <sup>6</sup>Wright JW, Silk KL. Acoustic and vestibular defects in lightning survivors. *Laryngoscope* 1974; **84**: 1378-86.

- <sup>7</sup>Sharma M, Smith A. Paraplegia as a result of lightning injury. *Br Med J* 1978; **2**: 1464-5.
- <sup>8</sup>Yasmineh WG, Pyle RB, Cohn JN, Nicoloff DM, Hanson NQ, Steele BW. Serial serum creatine phosphokinase MB isoenzyme activity after myocardial infarction. *Circulation* 1977; **55**: 733-8.
- <sup>9</sup>Zaret B. Myocardial imaging with radioactive potassium and its analogs. *Prog Cardiovasc Dis* 1977; **20**: 81-94.

Requests for reprints to Dr S H D Jackson, Vancouver General Hospital, 855 West 12th Avenue, Vancouver, BC, Canada V5Z 1M9.