

# Cardiovascular complications of homozygous familial hypercholesterolaemia

J M ALLEN, G R THOMPSON, N B MYANT, R STEINER, C M OAKLEY

*From the Departments of Clinical Cardiology and Diagnostic Radiology, Royal Postgraduate Medical School, and MRC Lipid Metabolism Unit, Hammersmith Hospital, London*

**SUMMARY** Seven patients with homozygous familial hypercholesterolaemia, two female and five male, aged 12 to 25 years, underwent clinical and angiographic assessment to define the associated cardiovascular abnormalities. Four patients had angina, two of whom also had syncope on exertion. All had an ejection systolic murmur but no ejection click and a loud aortic second sound. All but one had a systolic gradient between the left ventricle and aorta, ranging from 20 to 80 mmHg at the time of presentation. Angiography showed a characteristic narrowing of the aortic root in all and five of the seven patients had coronary ostial stenosis. One patient died after an aortocoronary bypass and aortic valvotomy and two others underwent aortocoronary bypass and aortic valve replacement, one of whom also died after operation. The survivor and three other patients are now undergoing regular plasma exchange and remain well. The seventh patient died suddenly before the latter form of treatment could be started. These findings confirm that premature, severe atheroma of the aortic valve and root is a characteristic feature of homozygous familial hypercholesterolaemia and carries a high mortality.

Early death from the cardiac consequences of premature atheroma is the usual outcome of homozygous familial hypercholesterolaemia.<sup>1,2</sup> Inherited as an autosomal dominant, this rare disease is characterised by very high plasma levels of cholesterol<sup>3</sup> and the development of cutaneous and tendon xanthomata in childhood.<sup>4</sup> We have studied seven patients with this disorder, in whom we have been able to document both clinically and angiographically a characteristic distribution of atheroma in the aortic root and coronary arteries. The severity of symptoms in two patients warranted aortocoronary bypass and aortic valve replacement and a third underwent aortocoronary bypass with aortic valvotomy.

## Case reports

### CASE 1

P A-S (born 17 July 1953) was a 23-year-old Greek Cypriot student whose early history has been described previously.<sup>5</sup> Her parents were first cousins. Skin xanthomata had been noted at the age of 6 months but treatment for her hypercholesterolaemia was not started until the age of 9 years. She first attended this hospital at the age of

12 in 1966. At that time her serum cholesterol was above 26.0 mmol/l (1000 mg/dl) with a serum triglyceride of 0.50 mmol/l (45 mg/dl). She had bilateral corneal arcus and multiple xanthomata over elbows, knees, and ankles. Her arterial pulses were regular, but slow rising. Blood pressure 130/70 mmHg. She had a loud ejection systolic murmur in the aortic area.

In 1969, she developed typical angina. The electrocardiogram at this time showed sinus rhythm with left ventricular hypertrophy and widespread ST depression at rest. An exercise electrocardiogram was positive.

From 1969 to 1973, she received a variety of drugs (nicotinic acid, cholestyramine, Secholex, neomycin, clofibrate) which only partially controlled her hypercholesterolaemia. From 1974 she was treated by monthly plasma exchange.<sup>5</sup> At this time it was noted that she had a pronounced left ventricular heave and the aortic component of the second heart sound became palpable. She had a grade 3/4 ejection systolic murmur in the aortic area with a thrill but no ejection click.

In 1976 she underwent cardiac catheterisation and a pressure gradient of 75 mmHg was recorded across the aortic valve. Angiography showed a normally contracting left ventricle, but the aortic

root showed gross irregularity with ostial narrowing of the left coronary artery (see Fig. 1).

By February 1977 her angina had become more severe, with episodes of chest pain at rest, and she was admitted for cardiac surgery. At operation the aortic root was seen to be small with extensive mural atheroma. The aortic valve had soft mobile cusps which were somewhat thickened and were fused at one commissure. When this was divided the aortic valve orifice seemed adequate. Both coronary ostia were very stenosed. Three grafts were inserted between the aorta and the anterior descending and circumflex branches of the left coronary artery, and the right coronary artery. She came off bypass easily but died on the second postoperative day from intraperitoneal haemorrhage.

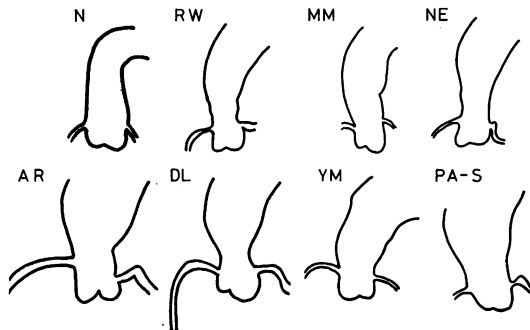


Fig. 1 Line drawings of aortograms of all patients are shown in comparison with the normal (N). The aorta normally expands in diameter as it reaches the aortic valve. In all seven homozygotes, aortography showed a characteristic irregular narrowing of the proximal aorta. This funnelling appears to be a distinctive feature of this disease.

#### CASE 2

Y M was a 23-year-old Zambian Asian (born 18 July 1952) whose parents were also first cousins and whose family tree is shown below (Fig. 2). The symbol □ represents normal subjects; ◻, and ◐ heterozygotes; and ◼, and ◑ homozygotes: values of serum cholesterol concentration are also shown.

Achilles tendon xanthomata were first noted at the age of 5 in 1957 and he subsequently developed xanthomata over the elbows. In 1969 he was started on cholestyramine and clofibrate in an attempt to lower his serum cholesterol but with little obvious benefit. At the age of 20 in 1972, he developed angina on exertion.

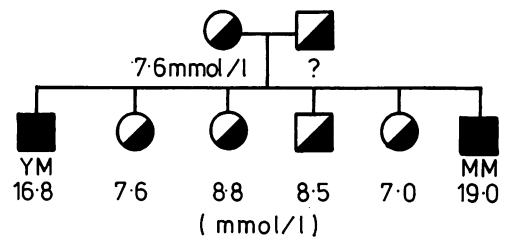


Fig. 2 Family tree of YM (case 2) and of MM (case 3).

On examination he had bilateral corneal arcus and multiple large cutaneous and tendinous xanthomata. His pulse was 72 and regular. He had a wide pulse pressure, blood pressure 180/100 mmHg. There was an obvious ejection systolic murmur and early diastolic murmur in the aortic area. Chest x-ray was normal. Electrocardiography showed sinus rhythm and pronounced left ventricular hypertrophy. The serum cholesterol was 16.8 mmol/l (689 mg/dl).

In July 1974, cardiac catheterisation (at The London Hospital) demonstrated a gradient across the valve of 30 mmHg. Aortography showed irregular funnelling of the aorta down to the valve (Fig. 1) with some aortic regurgitation. Coronary angiography showed diffuse disease of the left anterior descending and circumflex arteries, together with severe narrowing at the origin and in the first centimetre of the right coronary artery.

In December 1975, the patient was referred by Professor R Cohen for consideration for plasma exchange but died suddenly, aged 23, before this could be instituted.

#### CASE 3

MM is the 15-year-old youngest brother of case 2 (Y M) (see family tree, Fig. 2); at the age of 5 years he had skin lesions similar to those of his brother. In 1976, when he was 12, he first attended this hospital. Examination disclosed early corneal arcus and widespread cutaneous planar and tendinous xanthomata. His pulse was regular and normal in character, blood pressure 110/70 mmHg, but he had bilateral carotid and femoral bruits. The aortic component of the second sound was loud and he had a grade 3/4 ejection systolic murmur in the aortic area. Chest x-ray was normal, electrocardiography did not show any abnormalities, but echocardiography did disclose a thickened and narrowed aortic root. His serum cholesterol was 19.0 mmol/l (735 mg/dl), triglyceride 0.9 mmol/l (80 mg/dl).

In January 1978, angiography confirmed that the aortic root was narrowed and irregular (Fig. 1) though cardiac catheterisation disclosed no gradient across the valve or supra-avalvular area. Coronary angiography showed a stricture in the proximal third of the left anterior descending artery (Fig. 3) but there were no ostial stenoses.

He is now undergoing regular plasma exchange. He has remained well and has not developed any cardiovascular symptoms.

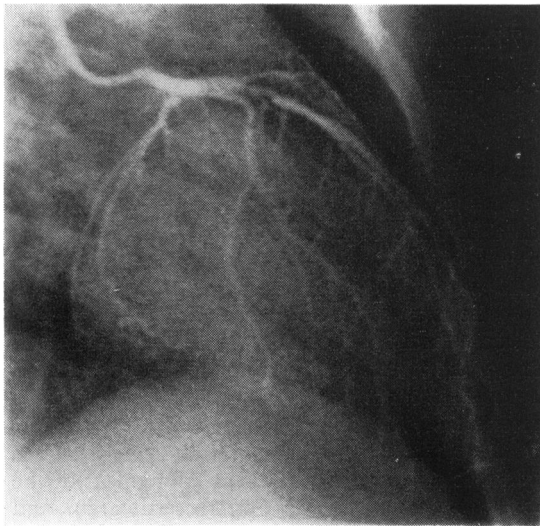


Fig. 3 Left coronary angiogram of MM (case 3) showing a long stricture at the origin of the left anterior descending artery. The distal vessels are unaffected.

#### CASE 4

A R was born on 17 November 1950 of an English father and Greek mother. Tendon xanthomata were first noticed at the age of 12 years. In 1970 at the age of 19 her serum cholesterol was 15.6 mmol/l (600 mg/dl), triglyceride 2.2 mmol/l (194 mg/dl). Examination showed no corneal arcus but she had multiple tendon xanthomata. Her pulse rate was 80 per minute and of normal character, blood pressure 115/75 mmHg. She had bruits over the carotid arteries and in the aortic area, and a grade 2/4 ejection systolic murmur. Chest x-ray and electrocardiogram were normal.

She received various cholesterol-lowering drugs over the next five years but without much success. She then underwent a trial of plasma exchange<sup>5</sup> but this was abandoned after a year because of difficulty of venous access.

In 1975, she developed angina on exertion. Examination of the cardiovascular system disclosed no new signs. Resting and exercise electrocardiograms were normal. Cardiac catheterisation showed a gradient across the aortic valve of 34 mmHg. Angiography showed narrowing and irregularity of the aortic root. The left coronary ostium also was narrowed.

In 1976, a portacaval shunt was carried out, as previously described,<sup>6</sup> but unfortunately this procedure resulted in only a temporary fall in serum cholesterol (see Fig. 4). In December 1978, she developed severe central chest pain and syncopal attacks on exertion. Examination showed a change in the character of her pulse, which was now very slow in rising. Blood pressure was 110/70 mmHg. There was an obvious left ventricular heave, a grade 3/4 aortic systolic murmur, and the aortic component of the second sound was loud. Electrocardiogram showed obvious left ventricular hypertrophy and an exercise electrocardiogram was strongly positive. Repeat catheterisation now showed a pressure gradient across the valve of 130 mmHg and on angiography the left ventricle was very hypertrophied.

She underwent cardiopulmonary bypass in February 1979. At operation patchy atheroma was seen in the ascending aorta but the sinuses of Valsalva had been virtually obliterated by large atheromatous cushions. The aortic valve was excised and the aortic root reconstructed with a Dacron graft to allow placement of a 23 mm Björk-Shiley valve. Three aortocoronary bypass grafts were inserted to the left anterior descending, circumflex, and right coronary arteries.

After successful treatment of postoperative bacterial endocarditis the patient is now remarkably well and is undergoing regular plasma exchange via an arteriovenous fistula in the arm.

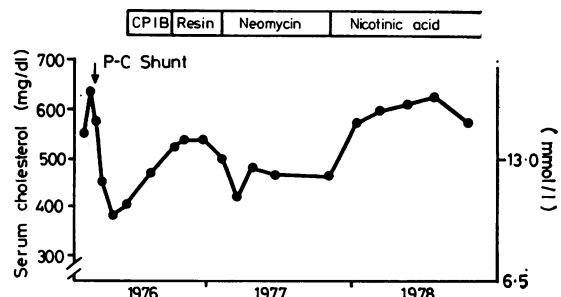


Fig. 4 Serial cholesterol levels in the patient A R (case 4) after a portacaval shunt (PC shunt).

## CASE 5

R W, a 23-year-old Englishman (born 21 March 1953), was first noticed to have xanthomata at the age of 5 years. His family tree is shown in Fig. 5. He was initially treated with conventional cholesterol-lowering drugs (nicotinic acid, clofibrate, and cholestyramine) by Dr E Jepson who subsequently referred him for plasma exchange in October 1975.

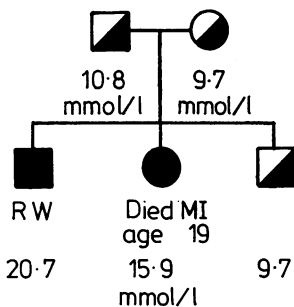


Fig. 5 Family tree of RW (case 5).

Examination showed bilateral corneal arcus and multiple cutaneous and tendon xanthomata. He had bruits over the carotid and femoral arteries; blood pressure 125/70 mmHg. There was a grade 3/4 ejection systolic murmur and the aortic component of the second sound was loud. Serum cholesterol was 20.7 mmol/l (795 mg/dl) and triglyceride 0.9 mmol/l (78 mg/dl). Chest x-ray was normal and electrocardiogram showed sinus rhythm and evidence of a previous anteroseptal infarct, with Q waves from V1 to V4. An exercise electrocardiogram was negative.

Cardiac catheterisation showed a gradient across the aortic valve of 40 mmHg. Angiography showed some apical dyskinesia and the aortic root was narrowed and deformed with gross irregularity (Fig. 1). Coronary angiography demonstrated two small strictures in the left main stem and one in the right coronary ostium.

The patient was started on plasma exchange in 1977 and he has remained well.<sup>7</sup>

## CASE 6

D L is a 16-year-old English boy who presented with xanthomata around the elbows and heels at the age of 9 years. His family history is shown below (Fig. 6). He was treated for four years by conventional cholesterol-lowering agents and during

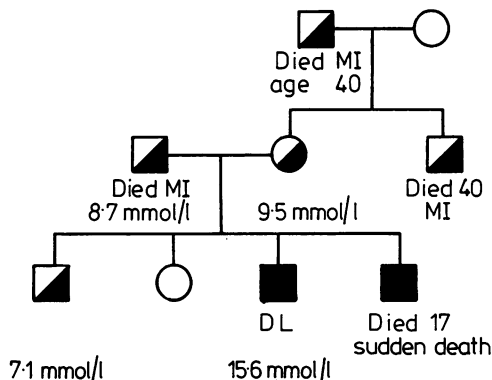


Fig. 6 Family tree of DL (case 6).

this time his serum cholesterol fluctuated around 15.6 mmol/l (600 mg/dl).

He was referred to this hospital by Dr J Hall when he was 12 years old for consideration for plasma exchange. Examination disclosed bilateral corneal arcus and multiple cutaneous and tendon xanthomata. Pulse was of normal character, blood pressure 130/70 mmHg. He had no carotid bruits, but there was a loud ejection systolic murmur in the aortic area and a loud aortic component of the second sound. Chest x-ray, electrocardiogram, and exercise electrocardiogram were all normal, but echocardiography showed a thickened and narrowed aortic root (Fig. 7). His serum cholesterol was 20.6 mmol/l (780 mg/dl) and triglyceride 1.1 mmol/l (97 mg/dl).

Cardiac catheterisation showed a pressure gradient across the aortic valve of 20 mmHg. Angiography demonstrated funnelling and narrowing of the aortic root (Fig. 1). Both coronary ostia were narrowed.

Regular plasma exchange was started in 1976 and two cardiac catheterisations at annual intervals have shown the pressure gradient across the valve to be unchanged, as described elsewhere.<sup>7</sup>

## CASE 7

N E was a 19-year-old English student. Xanthomata were noted at the age of 18 months and by 7½ years (1968) he had extensive xanthomata and had developed angina. He was treated with clofibrate and cholestyramine but his serum cholesterol levels remained persistently raised between 17.6 mmol/l (675 mg/dl) and 25.2 mmol/l (975 mg/dl). In 1976 he developed syncopal attacks and a 24 hour electrocardiographic tape recording showed periods

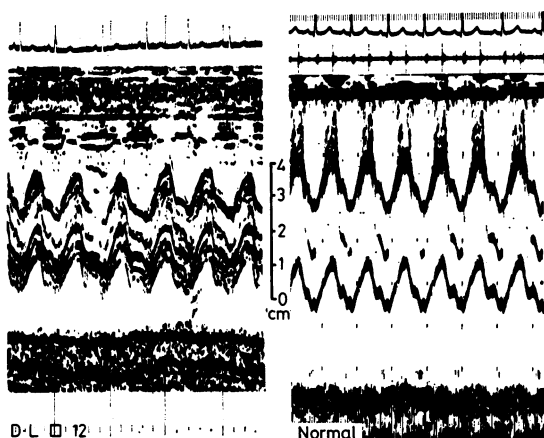


Fig. 7 Echocardiography of patient D L (case 6) in comparison with a normal child of the same age shows narrowing and apparent thickening of the aortic root and valve cusps. In addition there are many abnormal echoes within the aortic root suggesting distorted movement of the cusps.

of sinus arrest, atrioventricular dissociation, and ischaemic ST changes. A pacemaker was implanted at St Mary's Hospital, London.

In April 1979, he was referred by Professor V Wynn for consideration for plasma exchange. He complained of increasing angina on exertion, and had continued to suffer syncopal attacks. Examination disclosed bilateral arcus, xanthelasma, and some xanthomata. His pulse was 72 and slow rising, blood pressure 100/60 mmHg. He had bilateral carotid thrills and bruits. The apex beat showed a distinct left ventricular heave. There was a systolic thrill over the praecordium and a grade 3/4 ejection systolic murmur. The aortic component of the second sound was very loud. Electrocardiogram showed demand pacing but the unpaced beats showed distinct left ventricular hypertrophy.

Cardiac catheterisation showed a gradient across the aortic valve of 80 mmHg. Angiography indicated hypertrophy of the left ventricle. The aortic root showed widespread atheromatous deposits causing considerable narrowing and funnelling (Fig. 1 and 8). Coronary angiography showed strictures of the left anterior descending artery and proximal third of the right coronary artery. In June 1979, a Konno operation<sup>8</sup> was carried out to widen the aortic root, and a 25 mm Björk-Shiley valve and three aortocoronary bypass grafts were inserted. Post-operative progress was complicated by bacterial endocarditis, and development of an aorto-right ventricular fistula. He subsequently underwent a

further operation to close the fistula; he died during the operation.

## Discussion

Homozygous familial hypercholesterolaemia is a rare disorder,<sup>9</sup> the estimated incidence in Western countries being less than 1:1 000 000. There have been a number of case series previously published<sup>10 11</sup> but in none of these have the characteristic cardiovascular complications of the disease been fully documented. Though aortic stenosis has been recognised clinically and at necropsy,<sup>12-14</sup> it is only in recent years that angiographic study of patients has been performed and described, and then only in isolated instances. The abnormalities which have been reported in individual cases include strictures of the coronary arteries,<sup>1</sup> aortic stenosis, and narrowing of the aortic root.<sup>15-17</sup>

We have been able to study seven patients with homozygous familial hypercholesterolaemia. All were submitted at least once to cardiac catheterisation and angiography in order to define precisely the cardiac abnormalities.

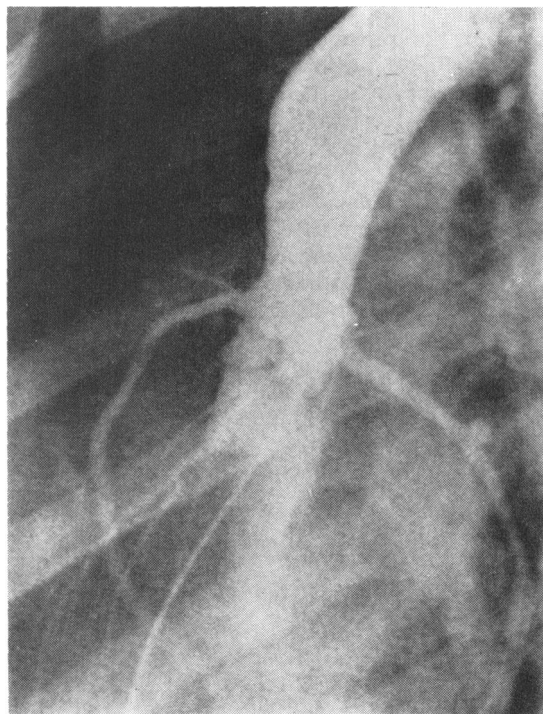


Fig. 8 Aortography of patient N E (case 7) shows the characteristic funnelling and irregularity of the proximal aortic root.

Three of the seven patients had no symptoms of cardiovascular involvement. The remaining four all suffered from typical angina. Two of them also had syncopal attacks on exertion.

All the patients had a loud ejection systolic murmur in the aortic area, a well recognised clinical finding.<sup>12-16</sup> In addition, each had a characteristic loud closure sound of the aortic valve. None had an ejection click.

Electrocardiography showed an old anterior infarct in one patient (R W, case 5); a further four patients had or developed evidence of left ventricular hypertrophy. Three patients (M M, case 3; D L, case 6, and N E, case 7) were examined by echocardiography. In each of the three, the aortic root was shown to be narrowed and apparently thickened and the aortic valve movement was distorted.

Aortography provides the best means of recognising the typical cardiovascular features of this disease. In all patients the proximal aortic root was narrowed and its outline was irregular and funnelled towards the aortic valve (Fig. 1 and 8). This represents the accumulation of atheroma which is most noticeable in the sinuses of Valsalva and extends proximally to involve the coronary ostia and aortic valve cusps. Strictures were commonly seen in the proximal portions of the coronary arteries (Fig. 3) but the distal vessels were remarkably free of disease. Catheterisation across the aortic valve recorded systolic pressure gradients ranging from nil in M M (case 3) to 130 mmHg in A R (case 4).

Pressure gradients between the left ventricle and aorta have been described in previous case reports,<sup>13-16</sup> but Wennevold and Jacobsen<sup>16</sup> considered that the gradient in their patient was the result of the supra-ventricular narrowing. In all our patients the gradient was at valve level and no gradient could be shown above that site. The appearance of the supra-ventricular part of the aorta in our patients was similar to that described by

Wennevold and Jacobsen<sup>16</sup> and it seems unlikely that such a long but relatively slight degree of narrowing could be responsible for gradients of 95 mm which they observed. The aortic valve presumably cannot open fully because of atheromatous masses occupying the sinuses of Valsalva and it may be these rather than atheromatous deposits on the cusps themselves which determine the obstruction.

The three patients without angina were found at cardiac catheterisation to have the lowest gradients across the aortic valve (Table), whereas the two patients with both angina and syncope had the highest gradients. It is noteworthy that case 4 was studied twice during the period 1975 to 1978 during which her serum cholesterol was poorly controlled (Fig. 4). Over these three years, the gradient across the aortic valve increased from 34 mmHg to 130 mmHg, her angina became more severe, and she developed the ominous symptom of syncope.

The loud closure sound of the aortic valve in homozygous familial hypercholesterolaemia presumably results from atheromatous involvement of the aortic cusps. The ejection systolic murmur probably represents turbulent flow through the narrowed aortic valve orifice as well as across the irregular and narrowed aortic root (Fig. 1 and 8). An ejection click is not heard but the loud aortic closure sound is characteristic. It is important to recognise aortic stenosis but its severity is difficult to assess clinically. The character of the carotid pulses may be altered as a result of atheromatous deposits within them and the form of the peripheral pulses may be modified by inelasticity of the large conducting arteries for the same reason. The aortic murmur may be lengthened by turbulence within the aortic root and murmurs over the carotids may arise locally so that the murmur may be no guide to the severity of obstruction to left ventricular outflow. Left ventricular hypertrophy may be recognised by palpation and electrocardiography but

Table Summary of initial cardiovascular findings in homozygotes

Case no.	Patient	Sex	Age when studied (y)	Angina	Syncope	Systolic murmur (grade)	Loud A <sub>2</sub>	ECG	LV aortic systolic pressure gradient (mmHg)
1	P A-S	F	23	+	-	3/4	+	LVH	75
2	Y M	M	22	+	-	2/4	+	LVH	30
3	M M	M	14	-	-	3/4	+	Normal	0
4	A R	F	25	+	-	2/4	+	Normal	34
5	R W	M	22	-	-	3/4	+	Q waves, V1-V4	40
6	D L	M	12	-	-	2/4	+	Normal	20
7	N E	M	19	+	+	3/4	+	LVH	80

an atrial beat and ST-T wave changes may equally result from associated coronary ostial involvement. Narrowing of the aortic root and apparent thickening can be shown by echocardiography, but multiple echoes from within the aortic box make assessment of the size of the aortic valve orifice difficult. Measurement of the left ventricular-aortic gradient remains essential and the rapid increase in severity as in case 4 underlines the need for serial measurements in these patients.<sup>7</sup> The progression of aortic stenosis was heralded by worsening angina and the onset of syncope attacks in our patients. These may lead to sudden death unless surgical relief is obtained; the surgery is complex and the operative risks are high. There is, however, now some evidence which suggests that effective control of the serum cholesterol by plasma exchange may prevent or delay the development of these complications.<sup>7</sup>

Maximal deposition of atheroma in the proximal part of the aorta is the reverse of the usual situation<sup>14</sup> and is a unique feature of homozygous familial hypercholesterolaemia. Experimentally, lesions very similar to those found in homozygotes have been induced in rats made hypercholesterolaemic by diet.<sup>18</sup> Studies in pigs and dogs<sup>19</sup> suggest that transendothelial flux of lipoproteins would be greatest in areas of greatest shear stress, these being the sinuses of Valsalva, coronary ostia, and ascending aorta. Under normal circumstances, however, these regions are relatively free from atheroma possibly because efflux as well as influx of lipoproteins is thought to be promoted by high shear stresses occurring at the arterial wall.<sup>20</sup> Superimposition of extreme hypercholesterolaemia upon a normal haemodynamic background might be expected to enhance influx of lipoprotein cholesterol without necessarily promoting efflux. If so this could explain the premature onset and unusual anatomical localisation of atheroma in homozygous familial hypercholesterolaemia.

We are grateful to Dr E Jepson and Professor V Wynn for allowing us to include the patients R W and N E, respectively. These patients were studied at this hospital but remained primarily under their care.

### References

- Bialostozky D, Luengo M, Magos C, Zorrilla E. Coronary insufficiency in children. *Am J Cardiol* 1975; **36**: 509-14.
- Rigdon RH, Willeford G. Sudden death during childhood with xanthoma tuberosum: review of literature and report of a case. *JAMA* 1950; **142**: 1262-71.
- Fredrickson DS, Levy RI. Familial hyperlipoproteinemia. In: Stanbury JB, Wyngaarden JB, Fredrickson DS, eds. *The metabolic basis of inherited disease*. New York: McGraw Hill, 1972: 545-614.
- Khachadurian AK. The inheritance of essential familial hypercholesterolemia. *Am J Med* 1964; **37**: 402-7.
- Thompson GR, Lowenthal R, Myant NB. Plasma exchange in the management of homozygous familial hypercholesterolaemia. *Lancet* 1975; **i**: 1208-11.
- Soutar AK, Myant NB, Thompson GR. Simultaneous measurement of apolipoprotein B turnover in very low and low density lipoproteins in familial hypercholesterolaemia. *Atherosclerosis* 1977; **28**: 247-56.
- Thompson GR, Myant NB, Kilpatrick D, Oakley CM, Raphael MJ, Steiner RE. Assessment of long-term plasma exchange for familial hypercholesterolaemia. *Br Heart J* 1980; **43**: 680-8.
- Konno S, Imai Y, Iida Y, Nakajima M, Tatsuno K. A new method for prosthetic valve replacement in congenital aortic stenosis associated with hypoplasia of the aortic valve ring. *J Thorac Cardiovasc Surg* 1975; **70**: 909-17.
- Thompson GR. Familial hypercholesterolaemia. In: Peeters H, ed. *Lipoprotein molecule*. Nato Advanced Study Institute Series. Series A: Life sciences, Vol. 15, Plenum Press, New York 1978; 215-26.
- Brown MS, Goldstein ML. Familial hypercholesterolemia: genetic, biochemical and pathophysiological considerations. *Adv Intern Med* 1975; **20**: 273-96.
- Mabuchi H, Tatami R, Haba T, et al. Homozygous familial hypercholesterolemia in Japan. *Am J Med* 1978; **65**: 290-7.
- Cook CD, Smith HL, Giesen CW, Berdez GL. Xanthoma tuberosum, aortic stenosis, coronary sclerosis and angina pectoris. Report of a case in a boy 13 years of age. *Am J Dis Child* 1947; **73**: 326-33.
- Barr DP, Rothbard S, Eder HA. Atherosclerosis and aortic stenosis in hypercholesteremic xanthomatosis. *JAMA* 1954; **156**: 943-7.
- Roberts WC, Ferrans VS, Levy RI, Fredrickson DS. Cardiovascular pathology in hyperlipoproteinemia. *Am J Cardiol* 1973; **31**: 557-70.
- Stanley P, Chartrand C, Davignon A. Acquired aortic stenosis in a 12 year old girl with xanthomatosis. *N Engl J Med* 1965; **273**: 1378-80.
- Wennevold A, Jacobsen JG. Acquired supravalvular aortic stenosis in familial hypercholesterolemia. *Am J Med* 1971; **50**: 823-7.
- Berger GMB, Miller JL, Bonnici F, Joffe HS, Dubovsky DW. Continuous flow plasma exchange in the treatment of homozygous familial hypercholesterolemia. *Am J Med* 1978; **65**: 243-51.
- Záhör Z, Czabonová V. Experimental atherosclerosis of the heart valves in rats following a long-term atherogenic regimen. *Atherosclerosis* 1977; **27**: 49-57.
- Fry DL. Responses of the arterial wall to certain physical factors. In: Ciba Foundation Symposium 12 (New Series). *Atherogenesis: initiating factors*. Amsterdam: Associated Scientific Publishers, 1973; 93-125.

- 20 Caro G, Fitzgerald JM, Schroter RC. Atheroma and arterial wall shear. Observation, correlation and proposal of a shear-dependent mass transfer mechanism for atherogenesis. *Proc R Soc Lond [Biol]* 1971; **177**: 109-59.

Requests for reprints to Dr C M Oakley, Department of Clinical Cardiology, Hammersmith Hospital, Du Cane Road, London W12 0HS.