

# Rastelli procedure for transposition of the great arteries, ventricular septal defect, and left ventricular outflow tract obstruction\*

## *Early and late results in 41 patients (1971 to 1978)*

A L MOULTON,† M R DE LEVAL, F J MACARTNEY, J F N TAYLOR, J STARK

*From the Thoracic Unit, The Hospital for Sick Children, Great Ormond Street, London*

**SUMMARY** Forty-one children with transposition of the great arteries, ventricular septal defect, and left ventricular outflow tract obstruction underwent a Rastelli operation between 1971 and 1978. A homograft valve preserved in an antibiotic solution and extended with a Dacron tube was the conduit of choice. Alternatively, conduits with porcine heterografts or valves constructed from calf pericardium were used. They were positioned to the left of the aorta whenever possible. The intraventricular tunnel from the left ventricle to the aorta was constructed from Dacron velour. There were four early and seven late deaths. The last 13 consecutive patients have survived. Early deaths were related to unfavourable anatomy, conduit compression, and sepsis. Residual ventricular septal defects and postoperative infection were the main factors contributing to the late deaths.

The combination of transposition of the great arteries, ventricular septal defect, and left ventricular outflow tract obstruction is uncommon. It occurred in 97 (0.67%) of the 15 044 patients with congenital heart disease reviewed by Keith and colleagues<sup>1</sup>; but significant left ventricular outflow tract obstruction occurred in 28 to 31 per cent of patients with transposition of the great arteries plus ventricular septal defect.<sup>2-3</sup> Early attempts to resect the left ventricular outflow tract obstruction in combination with a Mustard procedure and closure of the ventricular septal defect usually failed to relieve obstruction completely.<sup>4-6</sup>

After the first clinical use of an unvalved pericardial tube as an extracardiac conduit,<sup>7</sup> the experimental work of Arai and colleagues,<sup>8</sup> and the first clinical application of an aortic homograft as a conduit,<sup>9</sup> Rastelli<sup>10</sup> introduced a new procedure for the treatment of patients with the combination of transposition of the great arteries, ventricular septal defect, and left ventricular outflow tract

obstruction. He suggested diverting left ventricular output to the aorta by occluding the proximal pulmonary artery and creating a conduit within the right ventricle which would carry blood ejected through the ventricular septal defect into the aorta. Right ventricular flow would be carried to the distal pulmonary trunk by means of an external aortic homograft conduit. This achieved complete bypass of left ventricular outflow tract obstruction and an anatomical as well as physiological correction (Fig. 1a-c).

The purpose of this paper is to review the complete series of patients who have undergone this type of operation for these three anomalies at The Hospital for Sick Children, Great Ormond Street, London.

### Subjects

Between 1971 and 1978, 41 children underwent Rastelli's operation for transposition of the great arteries, ventricular septal defect, and left ventricular outflow tract obstruction (some of these children were subjects of previous reports<sup>11 12</sup>). There were 30 male and 11 female subjects in the group, ranging in age from 2 years 3 months to 14 years 10 months

\* This work was supported in part by a British Heart Foundation grant.

† Present address: Division of Thoracic and Cardiovascular Surgery, University of Maryland Hospital, 22 S. Greene Street, Baltimore, Maryland 21201, USA.

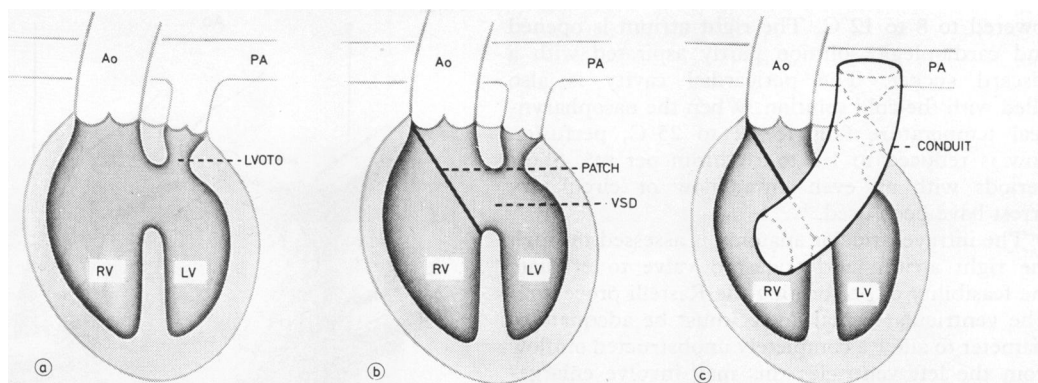


Fig. 1a, b, c Principle of Rastelli's operation for transposition of the great arteries, associated with ventricular septal defect and left ventricular outflow tract obstruction. Ao, aorta; PA, pulmonary artery; RV, right ventricle; LV, left ventricle; VSD, ventricular septal defect; LVOTO, left ventricular outflow tract obstruction.

(median 7 years 9 months). At the time of operation the children weighed from 12.5 kg to 50 kg (median 20.3 kg). All patients were cyanotic at the time of operation. Aortic oxygen saturations were 55 to 88 per cent (median 78%) and haemoglobin levels 11.4 to 24.8 g/100 ml (median 19.69 g/100 ml).

Thirty-three patients had undergone previous palliative procedures (Table 1). Some patients had one or more operations. One 2½-year-old child underwent a Mustard operation with closure of ventricular septal defect and attempted relief of left ventricular outflow tract obstruction. Because of severe postoperative heart failure he required reoperation and a Rastelli procedure was successfully performed.

#### OPERATIVE TECHNIQUE

The principle of the technique described in Rastelli's original paper has been followed. After a median sternotomy, any functioning shunts, the ductus arteriosus (if patent), and proximal pulmonary arteries are dissected. The conduit is prepared before establishing cardiopulmonary bypass and a Dacron portion preclotted. At present, we prefer a fresh aortic homograft preserved in an antibiotic solution. The homograft is obtained as soon as possible after death. It is placed in a valve-

preserving nutrient antibiotic solution, containing: medium 199 with no sodium bicarbonate (10 ml), preheated "Cals" serum No. 1 (8 ml), 4.4 per cent sodium bicarbonate (5 ml), sterile distilled water (77 ml), nystatin (250 000 units in 10 ml), methicillin (1000 mg 1.5 ml), erythromycin 600 mg in 12 ml, gentamicin 400 mg in 10 ml, and streptomycin 20 000 units.

The coronary ostia of the homograft are oversewn, the mitral valve and adjacent ventricular muscle trimmed, and a Dacron tube of matching diameter is then anastomosed to the "ventricular" end of the homograft. If a suitable homograft is not available, we use the Hancock conduit (Dacron tube with a gluteraldehyde-preserved porcine valve). Other alternatives are pericardial or dura-mater valves inserted into the Dacron tube.

The aorta is cannulated close to the origin of the innominate artery with a right-angled metal cannula. Right angled Rygg cannulae are introduced through the right atrial appendage and the right atrium just above the inferior vena cava. Pre-existing shunts are occluded. A Waterston shunt is either compressed or the pulmonary artery is snared on either side of the shunt; a Potts anastomosis is occluded by digital pressure through the left pulmonary artery; Blalock-Taussig shunts or persistent ductus arteriosus are ligated before cardiopulmonary bypass is established. Cardiopulmonary bypass with a flow of 2.4 l/min per m<sup>2</sup> is used and the perfusate cooled to 20 to 25°C. The left ventricle is vented through the left atrium or through the left ventricular apex. The aorta is cross-clamped and cold (4°C) cardioplegic solution containing St. Thomas's solution<sup>13</sup> is infused into the aortic root until the myocardial temperature is

Table 1 Previous operations

None	8
Pulmonary artery banding	2
Balloon atrial septostomy	13
Blalock-Hanlon septectomy	10
Blalock-Taussig shunt	24
Other aortopulmonary shunts	5

lowered to 8 to 12°C. The right atrium is opened and cardioplegic solution partly aspirated with a discard sucker. The pericardial cavity is also filled with the cold solution. When the nasopharyngeal temperature falls to 22 to 25°C, perfusion flow is reduced to 1.8 to 1.2 l/min per m<sup>2</sup>. Short periods with an even lower flow or circulatory arrest have been used.

The intraventricular anatomy is assessed through the right atrium and tricuspid valve to evaluate the feasibility of performing the Rastelli procedure. The ventricular septal defect must be adequate in diameter to allow a completely unobstructed outflow from the left ventricle; this may involve enlargement. The position of the aorta and the tricuspid valve with its subvalvar apparatus must permit placement of the patch to redirect the left ventricular outflow into the aortic root.

Visualisation of the papillary muscles and chordae of the tricuspid valve helps to select the optimal ventriculotomy site. The ventriculotomy is an oblique or vertical incision directed towards the main pulmonary artery. Care must be taken to avoid damage to major branches of the coronary arteries. In the first patients in this series, Rastelli's

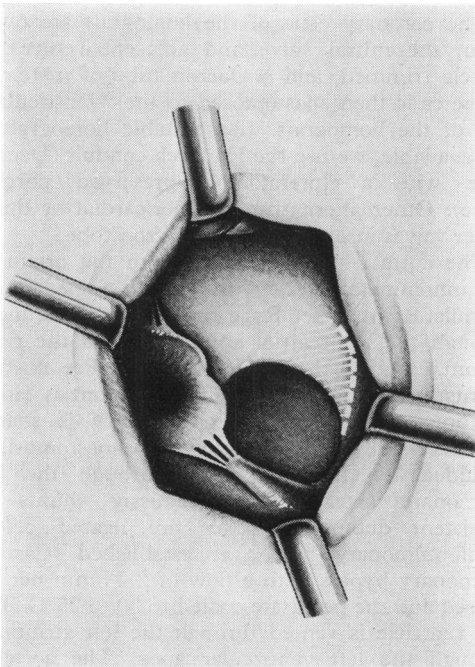


Fig. 2 The ventricular septal defect viewed through the right ventriculotomy; the area available for ventricular septal defect enlargement is cross-hatched.

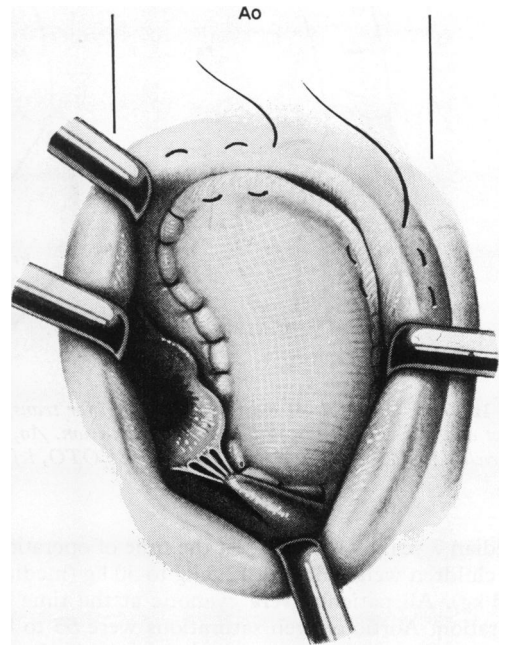


Fig. 3 Left ventricular flow is diverted to the aorta through the ventricular septal defect using a large patch. Ao, aorta.

original description was followed, that is with a conduit lying to the right of the aorta. Since 1973 we have directed the ventriculotomy incision and the conduit to the left of the aorta whenever the main pulmonary artery is to the left of or behind the aorta. In this position, the conduit does not cross the midline, and compression by the sternum is avoided. We do not resect a button of myocardium, though very hypertrophied right ventricular musculature at the edge of the ventriculotomy is often resected.

The ventricular septal defect is again inspected via the ventriculotomy. If its diameter is smaller than the aortic valve annulus, it is enlarged by incision or resection of the septum towards the lateral-superior aspect of the defect (Fig. 2). If accessible, the leaflets of the pulmonary valve are oversewn through the ventricular septal defect, though this may also be done later via the pulmonary artery. A generous patch of Dacron velour is then fashioned to direct blood from the left ventricle through the ventricular septal defect into the aorta (Fig. 3). Interrupted mattress sutures with Teflon pledgets are usually used. If running Prolene is used, it is reinforced with several pledgeted mattress sutures. The suture line starts at the lower

corner of the ventricular septal defect, near the tricuspid valve and runs along the border of the ventricular septal defect (with the usual care to avoid the conduction system) to the anterior right ventricular wall, to provide an adequate left ventricular outflow channel. In five patients, the tricuspid chordae and papillary muscle apparatus crossed the ventricular septal defect and precluded normal placement of the ventricular septal defect patch. In one patient the tricuspid valve was replaced; in three others a papillary muscle was detached and reattached. In one patient, a 26 mm Dacron tube was successfully inserted as an intraventricular conduit between the ventricular septal defect and aorta, coursing among the tricuspid chordae.

The proximal pulmonary artery is now ligated. We prefer this to transection because bleeding from the relatively inaccessible ventricular end of the pulmonary artery has been bothersome. The

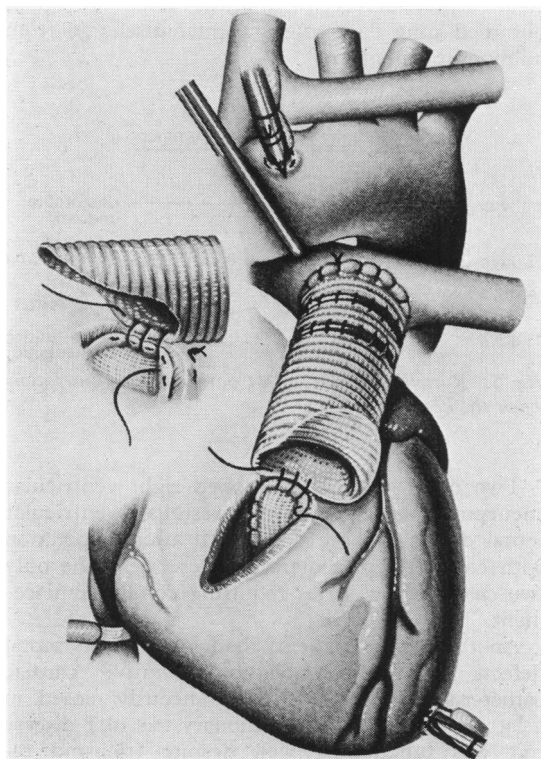


Fig. 4 The conduit is attached distally to the pulmonary artery. The proximal anastomosis to the right ventricle is started. The initial stitches are anchored to the upper border of the ventricular septal defect patch. Insert shows oblique trim to the proximal end of the conduit.

Table 2 Operative technique in 41 patients

<b>Conduit</b>	
Composite homograft	19
Porcine heterograft	22
<b>VSD enlarged</b>	
Resuspension tricuspid papillary	3
Replacement tricuspid valve	1
Intraventricular Dacron tube	1
<b>Pulmonary artery</b>	
Divided and oversewn	14
Ligated only	16
Ligated and pulmonary valve oversewn	9
Pulmonary valve oversewn only	2
<b>Relation conduit to aorta</b>	
Left	23
Right (1-TGA in six patients)	18

VSD, ventricular septal defect; TGA, transposition of the great arteries.

pulmonary trunk distal to the ligature is opened widely, usually from the left to the right pulmonary artery. The conduit is trimmed so that the valve is as close to the pulmonary artery as possible. The valve is thus protected by the large aorta, which in our view diminishes the possibility of valve compression or distortion. The conduit is stitched to the pulmonary artery with a running suture of Prolene. When the distal anastomosis is completed, the cross-clamp is released and the air carefully evacuated from the aortic root and left ventricular vent. The conduit is fashioned and sutured to the margins of the ventriculotomy, incorporating the upper edge of the ventricular septal defect patch (Fig. 4). The proximal anastomosis is performed on a beating heart while the patient is being rewarmed, with a second sump placed in the right ventricle via the tricuspid valve. A patent foramen ovale or atrial septal defect is closed. The right atriotomy is then sutured and cardiopulmonary bypass terminated in the usual manner when the body temperature has returned to normal. In none of the patients in this series did we have to delay sternal closure, or excise any of the sternum to accommodate the conduit. Details of the operative technique used are summarised in Table 2.

### Early results

The postoperative course is summarised in Table 3. Inotropic agents were liberally administered, usually before a low cardiac output syndrome had developed. One of the two patients in whom an intra-aortic balloon was inserted survived, though he needed embolectomy and has a residual peroneal palsy with foot drop. Ventilatory support for several

Table 3 Postoperative course in 37 early survivors

Inotropic support	19
Intra-aortic balloon pump	1
Renal failure, dialysis	3
Tracheostomy	2
Early reoperations	9
Mediastinal debridement	2
Laparotomy (bleeding caused by dialysis catheter)	1

days postoperatively was common, two patients required tracheostomy for prolonged mechanical ventilation. All patients were noted to be in sinus rhythm with right bundle-branch block at the time of discharge. Only one patient (a long-term survivor) had associated left anterior hemiblock.

Four of the 41 patients undergoing the Rastelli procedure (9.9%) died in the hospital (Fig. 5) but there have been no deaths in the 13 patients operated on since January 1977. One patient died on the table. Because of the long distance between the aorta and the ventricular septal defect (which was crossed by an anomalous muscle band), there was a 40 mmHg gradient between the left ventricle and aorta at completion of the repair. After revision of the ventricular septal defect patch, the patient still could not be weaned from bypass.

Three patients died in the immediate post-operative period with a low cardiac output. One had required tricuspid valve replacement as part of the repair and died two days later despite treatment with the balloon pump. One patient died four days postoperatively and was suspected of having conduit compression as the conduit had been placed across the midline to the right of the aorta. The third patient died 15 days after operation with continued low cardiac output, peritoneal dialysis for renal failure, and proven sepsis.

### Late results

Table 4 lists the causes of the late deaths from the 37 early survivors. Two patients died suddenly three months and three years postoperatively. One of these patients had an abnormal tricuspid papillary muscle detached and resuspended on the ventricular septal defect patch during the Rastelli procedure.

Table 4 Late deaths in 37 early survivors

Sudden	3 mth, 3 y	2
Aortic rupture at reoperation	10 wk	1
Haemoptysis	5 mth	1
Sepsis	15 mth	1
Damage to the coronary artery at reoperation	9 mth	1
Pulmonary embolus	14 mth	1

After early reoperation for mediastinal infection, he developed a residual ventricular septal defect and tricuspid regurgitation and died with aortic dissection at attempted reoperation 10 weeks later. Necropsy showed that the ventricular septal defect patch had torn away, creating holes in the septal leaflet of the tricuspid valve though the reattached papillary muscle was intact. The other patient, who had undergone early reoperation for mediastinal infection, died suddenly five months after operation with massive haemoptysis. Necropsy was not performed. The fifth child had an early postoperative fever and leukocytosis but positive blood cultures were not obtained until 15 months later, just before his death. The sixth late death resulted from damage to the left coronary artery, which originated high on the right side of the aorta. This origin was obscured by adhesions and the damage was caused during reoperation for residual ventricular septal defect nine months after the original Rastelli procedure. The seventh child underwent uneventful repair of a residual ventricular septal defect 14 months after operation, but died nine days after hospital discharge from pulmonary embolism.

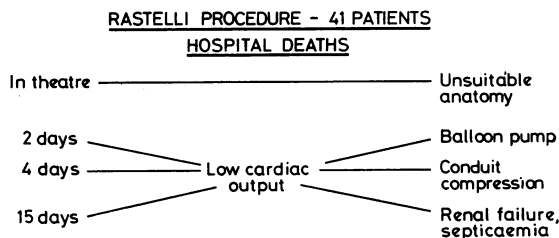


Fig. 5 Rastelli procedure in 41 patients. The illustration shows the hospital deaths.

Two other patients developed right ventricular aneurysms associated with residual ventricular septal defect and are doing well after reoperation with conduit replacement.<sup>14</sup> These were the only two cases in our series requiring conduit replacement.

Another three patients had ventricular septal defects documented on postoperative cardiac catheterisation; one had spontaneously closed in a later study, one had pulmonary vascular disease but was functioning well despite tricuspid regurgitation and moderate right ventricular failure, while the third is doing well on no medications. Five patients have clinically suspected ventricular septal defects but are asymptomatic on maintenance digoxin. The actuarial survival curve for the

present group of patients is given in Fig. 6. Comparative results of other series of Rastelli's procedure for transposition of great arteries plus ventricular septal defect plus left ventricular outflow tract obstruction are listed in Table 5.<sup>15 16</sup>

**Discussion**

The combination of these three anomalies is uncommon and the causes of the left ventricular outflow tract obstruction are multiple. Isolated valvular stenosis is rare, though it may occur in association with other lesions.<sup>17</sup> Subvalvular stenosis may be caused by a fibrous shelf, a fibromuscular tunnel, herniation of accessory tricuspid tissue through the ventricular septal defect, abnormal attachment of the mitral valve, aneurysm of the membranous ventricular septum, or septal hypertrophy.<sup>18-21</sup>

Direct attempts to resect this stenotic area in combination with a Mustard operation and ventricular septal defect closure may not alleviate the gradient—because of the arrangement of the mitral valve, ventricular septum, and coronary arteries.<sup>22</sup> More recently, good results with the relief of left ventricular outflow tract obstruction combined with the Mustard operation have been achieved.<sup>23 24</sup> However, the Rastelli procedure offers several advantages in this group of patients by providing adequate relief of the left ventricular outflow tract obstruction while transferring the left ventricle and mitral valve to the systemic arterial circulation. It should, therefore, avoid any concern about late right ventricular function and the tricuspid regurgitation sometimes seen after the

Table 5 Results of Rastelli operation

Institution	Period	No. of patients	Early and late deaths	Mortality (%)
Mayo Clinic*	1968-75	59	16	27
Great Ormond St.	1971-78	41	11	27
Boston Children's†	1972-76	7	1	14

\*Marcelletti *et al.*<sup>15</sup>

†Norwood *et al.*<sup>16</sup>

Mustard procedure.<sup>25 26</sup> Obstructions to pulmonary and systemic venous return and post-Mustard arrhythmias will be avoided.

The long-term success of the Rastelli procedure will also depend upon continuing satisfactory function of the conduit as well as on myocardial performance. Early repairs used aortic homografts to restore continuity between the right ventricle and the pulmonary artery. Reports of calcification, the development of high gradients, and valvular regurgitation in the aortic homograft,<sup>27-29</sup> as well as limited availability, have led to the introduction of a commercially available glutaraldehyde-preserved porcine heterograft valve in a Dacron tube.<sup>30</sup>

Our experience and that of others<sup>31-33</sup> has shown that relatively fresh antibiotic sterilised homografts will function well over more than 10 years. They are easier to handle and better haemostasis is achieved. We, therefore, prefer to use a fresh aortic homograft preserved in an antibiotic solution, when available.

Some of the gradients between the right ventricle and pulmonary artery are related to technical

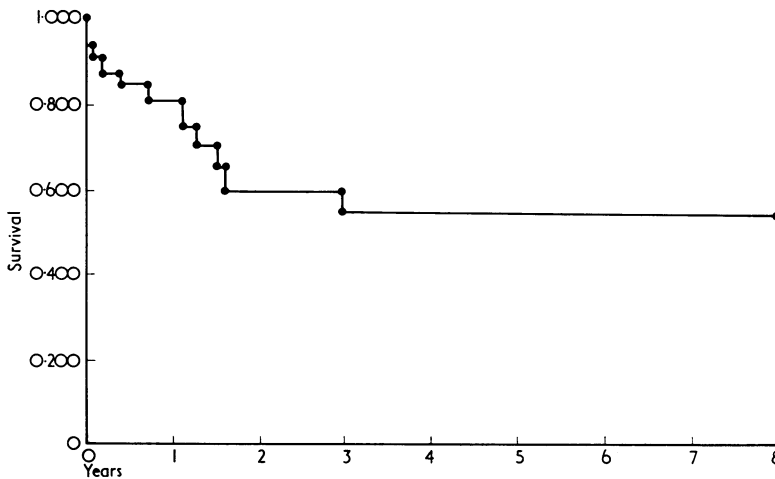


Fig. 6 Actuarial survival curve for patients undergoing Rastelli procedure for transposition of great arteries, ventricular septal defect, and left ventricular outflow tract obstruction.

factors rather than the type of conduit used.<sup>34 35</sup> Completely asymptomatic patients may have significant gradients and some urge routine cardiac catheterisation after the Rastelli procedure.<sup>36</sup> Reoperation for conduit stenosis was necessary in two patients out of 37 early survivors (5%) in this series, in contrast to eight patients (17%) of early survivors in the Mayo Clinic series.<sup>15</sup> If the ventricular septal defect is restrictive, it must be enlarged in the first instance. In the Mayo Clinic series<sup>15</sup> the ventricular septal defect was enlarged in 35 per cent of those patients undergoing the Rastelli procedure; early mortality in this group was only 10 per cent, as opposed to a mortality of 24 per cent in those patients whose ventricular septal defects were judged "adequate" without enlargement. The ventricular septal defect was enlarged in 80 per cent of our patients. The enlargement did not affect early or late mortality.

Residual ventricular septal defects are seen more frequently after the Rastelli procedure than after other operations for ventricular septal defect.<sup>35</sup> This could be related to the large patch necessary to provide unobstructed outflow into the aorta. Anomalies of ventricular musculature and tricuspid chordae obscuring the margins of the ventricular septal defect also increase the risk of a residual defect. Five (14%) of the 37 early survivors in our series required reoperation for ventricular septal defect (two with associated right ventricular aneurysm, one with concurrent tricuspid regurgitation) compared with five of 48 (11%) in Marcelletti's series.<sup>15</sup> Three of our five patients died at or after reoperation; therefore a residual ventricular septal defect appeared to have an adverse effect on long-term survival, though this impression could not be confirmed statistically.

Postoperative infectious complications have been a major problem in the series since they were associated with one early and three late deaths. We were unable to relate these infections to the type of extracardiac conduit used, or to a particular antibiotic regimen. They were most probably a consequence of the complexity of the surgical procedures involved, and the insertion of a large amount of prosthetic material.

All patients in our series were discharged in normal sinus rhythm; only one patient—a long-term survivor—had associated left anterior hemiblock. Three patients had transient postoperative arrhythmias. Two late deaths were sudden and unexplained and could have been related to undiagnosed arrhythmias.

The success of the Rastelli procedure depends upon careful selection of patients as well as on meticulous surgical techniques. The combination

of improved techniques of angiocardiology and sector echocardiography should enable accurate preoperative diagnosis of most of the lesions associated with transposition, ventricular septal defect, and left ventricular outflow tract obstruction which are likely to cause problems during operation. Tilted oblique projections of left ventricular angiocardiology<sup>37 38</sup> allow easy recognition of the small infundibular defect immediately under both semilunar valves which may not be possible to enlarge without resecting tissue inferiorly and thereby placing the penetrating bundle at risk. Such projections also readily identify the apical trabecular muscular defect which is too far from the aortic valve to permit insertion of an intra-ventricular conduit. In our experience, it is not always easy to distinguish the inlet ventricular septal defect, which is a long way from the aortic valve, from the anterior trabecular defect which is more appropriately sited, though it has been claimed that this is not difficult.<sup>39</sup> Identification of a straddling tricuspid valve is possible by angiocardiology,<sup>40</sup> but is much more easily achieved with sector scanning,<sup>41</sup> which also permits recognition of malattachment of the tricuspid valve to the rim of the ventricular septal defect. Subaortic stenosis, when severe, is easily recognised by the resultant pressure gradient, but angiocardiology may show infundibular subaortic stenosis which, though causing no obstruction preoperatively, may contribute to left ventricular aortic gradients postoperatively, unless it is relieved. Mitral valve anomalies must be assiduously sought for by the combination of pressure measurements, angiocardiology, and echocardiography. If the anatomy is unfavourable, other options for repair must be considered. These include a Mustard or Senning procedure, ventricular septal defect closure and left ventricular to pulmonary artery conduit,<sup>42 43</sup> or the concept of biventricular conduits.<sup>43</sup>

We thank Mr K Ross, Mr J Munroe, Mr D N Ross, and Mr M Yacoub for supplying us with the homograft valves, and Sister Siebert from the homograft department, Southampton Western Hospital.

*Note:* Fig. 1 to 6 have been reproduced with kind permission of the publishers from Stark J. The Rastelli operation. In: *Operative surgery, cardiothoracic surgery*. London: Butterworths, 1978: 130-5.

#### References

- 1 Keith JD, Rowe RD, Vlad P. *Heart disease in infancy and childhood*. New York: MacMillan, 1978.

- 2 Liebman J, Cullum L, Belloc NB. Natural history of transposition of the great arteries. Anatomy and birth and death characteristics. *Circulation* 1969; **40**: 237-62.
- 3 Van Praagh R. Anatomic types of left ventricular outflow tract obstruction in transposition of the great arteries (abstract). *Eur J Cardiol* 1978; **8**: 102.
- 4 Daicoff GR, Schiebler GL, Elliot LP, et al. Surgical repair of complete transposition of the great arteries with pulmonary stenosis. *Ann Thorac Surg* 1969; **7**: 529-38.
- 5 Danielson GK, Mair DD, Ongley PA, Wallace RB, McGoon DC. Repair of transposition of the great arteries by transposition of venous return. *J Thorac Cardiovasc Surg* 1971; **61**: 96-103.
- 6 Breckenridge IM, Stark J, Bonham-Carter RE, Oelert H, Graham GR, Waterston DJ. Mustard's operation for transposition of the great arteries (review of 200 cases). *Lancet* 1972; **i**: 1140-9.
- 7 Rastelli GC, Ongley PA, Davis GD, Kirklin JW. Surgical repair for pulmonary valve atresia with coronary—pulmonary artery fistula: report of a case. *Mayo Clin Proc* 1965; **40**: 521-7.
- 8 Arai R, Tsuyki Y, Nogi M, et al. Experimental study on bypass between the right ventricle and pulmonary artery, left ventricle and pulmonary artery and left ventricle and aorta by means of homograft with valve. *Bull Heart Inst Jap* 1965; **9**: 49-54.
- 9 Ross DN, Somerville J. Correction of pulmonary atresia with a homograft aortic valve. *Lancet* 1966; **ii**: 1446-7.
- 10 Rastelli GC. A new approach to "anatomic" repair of transposition of the great arteries. *Mayo Clin Proc* 1969; **44**: 1-12.
- 11 Daenen W, de Leval M, Stark J. Transposition of great arteries, ventricular septal defect, and left ventricular outflow tract obstruction. Results of 23 Rastelli operations (abstract). *Br Heart J* 1976; **38**: 878.
- 12 Stark J. Rastelli operation. In: Anderson RH, Shinebourne EA, eds. *Paediatric cardiology* 1977. Edinburgh and London: Churchill Livingstone, 1978: 540-7.
- 13 Jynge P, Hearse DJ, Braimbridge MV. Myocardial protection during ischemic cardiac arrest. A possible hazard with calcium-free cardioplegic infusates. *J Thorac Cardiovasc Surg* 1977; **73**: 848-55.
- 14 Jacobs T, de Leval M, Stark J. False aneurysm of the right ventricle after Rastelli's operation for transposition of the great arteries, ventricular septal defect and pulmonary stenosis. *J Thorac Cardiovasc Surg* 1974; **67**: 543-6.
- 15 Marcelletti C, Mair DD, McGoon DC, Wallace RB, Danielson GK. The Rastelli operation for transposition of the great arteries. Early and late results. *J Thorac Cardiovasc Surg* 1976; **72**: 427-34.
- 16 Norwood WI, Freed MD, Rocchini AP, Bernhard WF, Castaneda AR. Experience with valved conduits for repair of congenital cardiac lesions. *Ann Thorac Surg* 1977; **24**: 223-32.
- 17 Shrivastava S, Tadavarthy SM, Fukuda T, Edwards JE. Anatomic causes of pulmonary stenosis in complete transposition. *Circulation* 1976; **54**: 154-9.
- 18 Imamura E, Morikawa T, Tatsuno K, Okamoto K, Yasuharu I, Konno S. Conduit repairs of transposition complexes—a report of 14 cases. *J Thorac Cardiovasc Surg* 1977; **73**: 570-7.
- 19 Silove ED, Taylor JFN. Angiographic and anatomical features of subvalvar left ventricular outflow obstruction in transposition of the great arteries. The possible role of the anterior mitral valve leaflet. *Pediatr Radiol* 1973; **1**: 87-91.
- 20 Vidne BA, Subramanian S, Wagner HR. Aneurysm of the membranous ventricular septum in transposition of the great arteries. *Circulation* 1976; **53**: 157-61.
- 21 Van Gils FAW, Moolaert AJ, Oppenheimer-Dekker A, Wenink AEG. Transposition of the great arteries with ventricular septal defect and pulmonary stenosis. *Br Heart J* 1978; **40**: 494-9.
- 22 Anderson KR, McGoon DC, Lie JT. Vulnerability of coronary arteries in surgery for transposition of the great arteries. *J Thorac Cardiovasc Surg* 1978; **76**: 135-9.
- 23 Idriss FS, DeLeon SY, Nikaidoh H, et al. Resection of left ventricular outflow obstruction in d-transposition of the great arteries. *J Thorac Cardiovasc Surg* 1977; **74**: 343-51.
- 24 Oelert H, Laprell H, Piepenbrock S, Luhmer I, Kallfelz HC, Borst HG. Emergency and non-emergency intraatrial correction for transposition of the great arteries in 43 infants. *Thoraxchir Vask Chir* 1977; **25**: 305-13.
- 25 Tynan M, Aberdeen E, Stark J. Tricuspid incompetence after the Mustard operation for transposition of the great arteries. *Circulation* 1972; **45**, suppl I: 111-115.
- 26 Graham TP Jr, Atwood GF, Boucek RJ Jr, Boerth RC, Bender HW Jr. Abnormalities of right ventricular function following Mustard's operation for transposition of the great arteries. *Circulation* 1975; **52**: 678-84.
- 27 Merin G, McGoon DC. Reoperation after insertion of aortic homograft as a right ventricular outflow tract. *Ann Thorac Surg* 1973; **16**: 122-6.
- 28 Park SC, Neches WH, Lenox CC, Zuberbuhler JR, Bahnson HT. Massive calcification and obstruction in a homograft after the Rastelli procedure for transposition of great arteries. *Am J Cardiol* 1973; **32**: 860-4.
- 29 Rocchini AP, Rosenthal A, Keane JF, Castaneda AR, Nadas AS. Hemodynamics after surgical repair with right ventricle to pulmonary artery conduit. *Circulation* 1976; **54**: 951-6.
- 30 Bowman FO Jr, Hancock WD, Malm JR. A valve-containing Dacron prosthesis. Its use in restoring pulmonary artery-right ventricular continuity. *Arch Surg* 1973; **107**: 724-8.
- 31 Moore CH, Martelli V, Ross DN. Reconstruction of right ventricular outflow tract with a valved conduit in 75 cases of congenital heart disease. *J Thorac Cardiovasc Surg* 1976; **71**: 11-9.



- 32 Radley-Smith R, Ahmed M, Yacoub M. Late results of aortic homograft reconstruction of the right ventricular outflow tract in infants and children. *Thoraxchir Vask Chir* 1975; **23**: 455-9.
- 33 Barratt-Boyes BG. Long-term follow-up of aortic valvar grafts. *Br Heart J* 1971; **33**: 60-5.
- 34 Bailey WW, Kirklin JW, Barger LM Jr, Pacifico AD, Kouchoukos NT. Late results with synthetic valve external conduits from venous ventricle to pulmonary arteries. *Circulation* 1977; **56**, suppl II: 73-9.
- 35 West PN, Hartmann AF Jr, Weldon CS. Long-term function of aortic homografts as the right ventricular outflow tract. *Circulation* 1977; **56**, suppl II: 66-72.
- 36 Heck HA, Scheiken RM, Lauer RM, Doty DB. Conduit repair for complex congenital heart disease—late follow-up. *J Thorac Cardiovasc Surg* 1978; **75**: 806-14.
- 37 Puyau FA and Burko H. The tilted left anterior oblique position in the study of congenital cardiac anomalies. *Radiology* 1966; **87**: 1069-73.
- 38 Elliot LP, Barger LM, Jr, Bream PR, Soto B, Curry GC. Axial cineangiography in congenital heart disease. Section II. Specific lesions. *Circulation* 1977; **56**: 1084-93.
- 39 Soto B, Becker AE, Moulart AJ, Lie JT, Anderson RH. Classification of ventricular septal defects. *Br Heart J* 1980; **43**: 332-43.
- 40 Pacifico AD, Soto B, Barger LM Jr. Surgical treatment of straddling tricuspid valves. *Circulation* 1979; **60**: 655-64.
- 41 Aziz KU, Paul MH, Muster AJ, Idriss FS. Positional abnormalities of atrioventricular valves in transposition of the great arteries including double outlet right ventricle, atrioventricular valve straddling and malattachment. *Am J Cardiol* 1979; **44**: 1135-45.
- 42 Singh AK, Stark J, Taylor JFN. Left ventricle to pulmonary artery conduit in treatment of transposition of great arteries, restrictive ventricular septal defect, and acquired pulmonary atresia. *Br Heart J* 1972; **38**: 1213-6.
- 43 McGoon DC. Left ventricular and biventricular extracardiac conduits. *J Thorac Cardiovasc Surg* 1976; **72**: 7-14.

Requests for reprints to Dr J Stark, Thoracic Unit, The Hospital for Sick Children, Great Ormond Street, London WC1N 3JH.