

Two chambered left ventricle

Three new varieties

L M GERLIS*, J B PARTRIDGE, G I FIDDLER, G WILLIAMS, O SCOTT

From the Departments of Pathology, Radiology, and Paediatric Cardiology, Killingbeck Hospital, Leeds

SUMMARY A short review of two chambered left ventricle is given, and this rare condition is briefly compared and contrasted with the more common condition involving the right ventricle. Three cases are described, each of which presents a new variety of subdivision of the left ventricle; in two of these the condition was first shown by angiocardiology. The first case had left heart hypoplasia with dysplastic stenosis of the mitral and aortic valves and severe endocardial fibroelastosis of the main left ventricular cavity. The second case also showed dysplasia of the left sided valves with pronounced endocardial fibroelastosis, and in addition there was a congenital malformation of the left lung. The third case showed a bizarre ventricular subdivision without other congenital malformations.

The role of the intertrabecular myocardial sinusoids in the pathogenesis of some types of two chambered ventricle is discussed and this is considered to have been of significance in the first two cases. The third case possibly represented an intramyocardial aneurysm of obscure aetiology.

Subdivision of the left ventricular cavity is a rare cardiac anomaly; various types have been described and tentative classifications have been proposed.^{1 2} Distinction has been made between congenital ventricular aneurysms and diverticula. Aneurysms caused by congenital myocardial weakness have been separated from those caused by myocardial damage; diverticula have been subdivided according to whether they are muscular or fibrous, apical or basal, calcified or uncalcified.

Previously reported cases appear to fall into one of four types which are illustrated diagrammatically in Fig. 1.

(A) A thin-walled aneurysm or diverticulum, usually apical, which may result from bulging of an unusually weak portion of myocardium, especially in a region in which there is often distinct local reduction in wall thickness,^{1 3} or may be secondary to myocardial damage and subsequent stretching; this may result from anomalous origin of a coronary artery from the pulmonary artery. Other conditions which have been listed as possible causes of left ventricular aneurysm² include myocardial infarct, syphilis, tuberculosis, rheumatic fever, mycotic infection,

arteritides such as polyarteritis nodosa, Loeffler's parietal endocarditis, and trauma. Two instances of right ventricular diverticulum in childhood resulting from inflammatory myocardial disease have been described.^{4 5}

- (B) A thin-walled subvalvar or basal bulging presenting in the atrioventricular groove with the internal opening at the junction of the ventricular muscle with the atrioventricular ring and presumably resulting from congenital weakness or defect at this point. Examples have been described in the left ventricle^{2 6} and also in the right ventricle.⁷
- (C) A congenital tubular muscular diverticulum extending from the apex of the left ventricle has been described as part of a syndrome of congenital defects which may include congenital intracardiac malformation, midline supra-umbilical abdominal wall defects, lower sternal defects, anterior and diaphragmatic pericardial defects and cardiac malrotation, possibly with dextroposition.⁸⁻¹⁰
- (D) This variety presents as a thin walled, superficial, or "epicardial" blood filled cyst which may be situated anywhere in the ventricle wall. It may be multiloculated or of honeycomb appearance and is lined internally by endothelium with a variable amount of underlying elastic tissue. It com-

* L M G is supported by the National Heart Research Fund.
Received for publication 19 February 1981

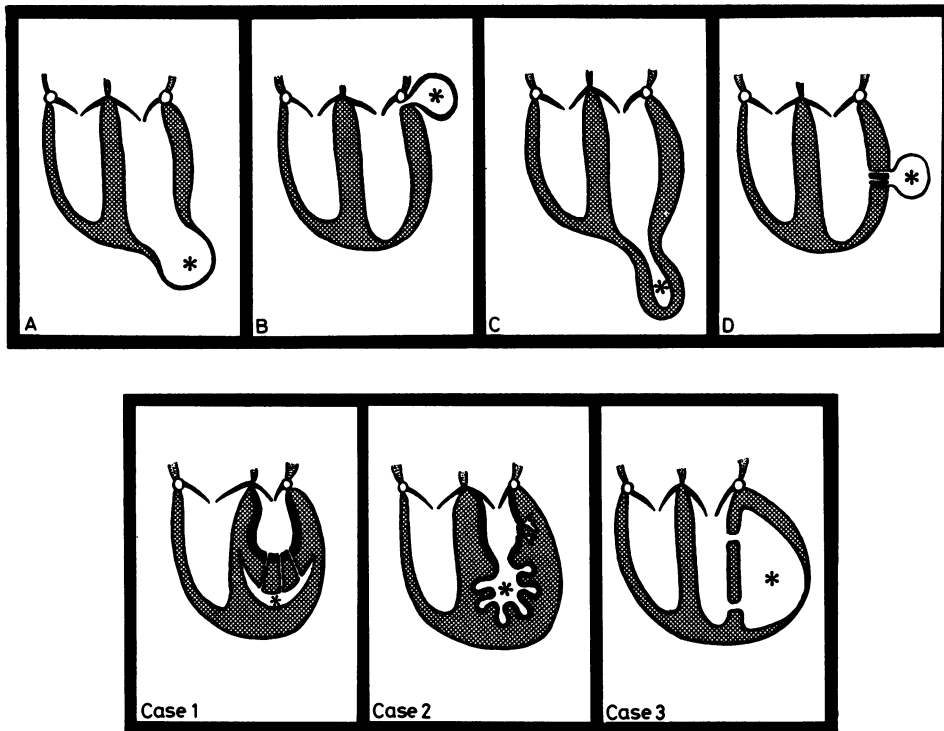


Fig. 1 Diagrammatic representation of the various types of two chambered left ventricle. A–D = previously reported types as detailed in the text. Cases 1, 2 and 3 illustrate the three new varieties. In all cases the ventricles are represented as in vertical section in the coronal plane. The thickened line in cases 1 and 2 indicates endocardial thickening. In all diagrams the "extra" left ventricular chamber is marked with an asterisk.

municates with the ventricular cavity by one or more narrow channels which open into the intratrabecular spaces and there may also be anastomotic communications with the adjacent coronary arteries. This condition is rare; examples have been reported in association with the left ventricle in a man of 62 years¹¹ and in a male infant of 2 weeks¹² and also, opening into the right ventricle, in a female child of 14 months.¹³ The underlying lesion has been considered to be an abnormal persistence of the embryological communication between the myocardial intratrabecular spaces and the coronary vasculature which normally becomes reduced to capillary dimensions except in the inner myocardial zone where some intratrabecular vessels retain communication with the ventricular cavity as the Thebesian vessels.

A unique variant of this type of subdivided ventricle has been described by Quero-Jiménez *et al.*^{14 15} in a case of tricuspid atresia with absent pulmonary valve in which there was asymmetrical septal hypertrophy with myocardial

fibre disarray and multiple endothelial lined clefts communicating with the right ventricular cavity; one of these was large enough to be considered as a third ventricular cavity or as a subdivision of the *right* ventricle.

The three cases now described are varieties of two chambered left ventricle which do not fall into any of the above categories and do not appear to have been previously described. In two of these the condition was demonstrated angiographically during life.

Case reports

CASE 1 MALE CAUCASIAN (age 1 day)

This was the first baby of a 27-year-old mother who had previously had a prosthetic valve replacement for severe congenital aortic stenosis and was on warfarin and heparin treatment throughout pregnancy. The infant was cyanosed from birth and had a praecordial systolic murmur. He was referred to the cardiac unit at 8 hours of age; single crystal M-mode echocardiography suggested congenital mitral stenosis and

angiocardiology showed a large persistent ductus arteriosus with a right-to-left shunt and patent foramen ovale. The left atrial angiogram was unusual. Once contrast medium passed through the mitral valve into the left ventricle it defined a smooth walled, non-contractile chamber, and contrast medium subsequently entered a small functioning left ventricular chamber through multiple orifices between the smooth walled chamber and the left ventricle proper (Fig. 2). The right ventricle was normal; the pulmonary venous return was normal. The heart was surgically explored under bypass to exclude cor triatriatum or congenital mitral stenosis. There was found to be a persistent ductus arteriosus, aortic hypoplasia, and left ventricular endocardial fibroelastosis. No radical corrective procedures were feasible and the child did not survive surgery.

Necropsy showed no lesions apart from the cardiac abnormalities. The heart was small and globular, the apex was to the left, and there was normal situs solitus morphology of the chambers with atrioventricular and ventriculoarterial concordance. The systemic and

pulmonary veins were normal. The right side of the heart was normal apart from moderate hypertrophy of the ventricle which had a bulging septum and a 7 mm thick free wall. The foramen ovale had been sutured and a widely patent 5 mm diameter ductus arteriosus had been ligated. The main left atrial cavity was rather small, approximately 15 mm diameter and the appendix was disproportionately enlarged, $25 \times 12 \times 8$ mm. The left atrioventricular valve was a miniature, hypoplastic but persistent structure with tiny chordae tendineae and no true papillary muscles.

The left ventricle consisted of two portions. The proximal or basal portion was a small cavity, 10 mm long by 7 mm diameter, lined by a pearly white dense zone of endocardial fibroelastosis, 2 mm thick, which was smooth apart from scattered minute pits up to 1 mm diameter. This cavity communicated with the left atrium and with the normally situated aorta. The outer muscular portion of the wall was 7 mm thick but was incomplete because of surgical and post-mortem examinations. The distal or apical half of the ventricle was composed of an apparently solid mass of muscle approximately 17 mm long, 20 mm wide, and 15 mm thick. On close examination, however, this was found to contain embedded in the anterior aspect, a cleft which was up to 10 mm wide, but not more than 2 mm deep in the fixed state. Part of this cavity was missing but it appeared to have been of crescentic form on the anterior aspect of the ventricle, concave upwards, and with the anterior extremity approaching the upper-mid portion of the anterior wall of the left ventricle. No definite inlet or outlet was found and it was presumed that there had been a to-and-fro connection with the upper or proximal portion of the left ventricular cavity through one or more myocardial sinusoids via the endocardial pits (Fig. 1 and 4A). The aortic valve was hypoplastic and dysplastic comprising three irregular nodular and rigid fragments with a narrowed orifice 2.5 mm in diameter. The ascending aorta was 4 mm in diameter, and there was slight preductal aortic isthmus stenosis to 2 mm.

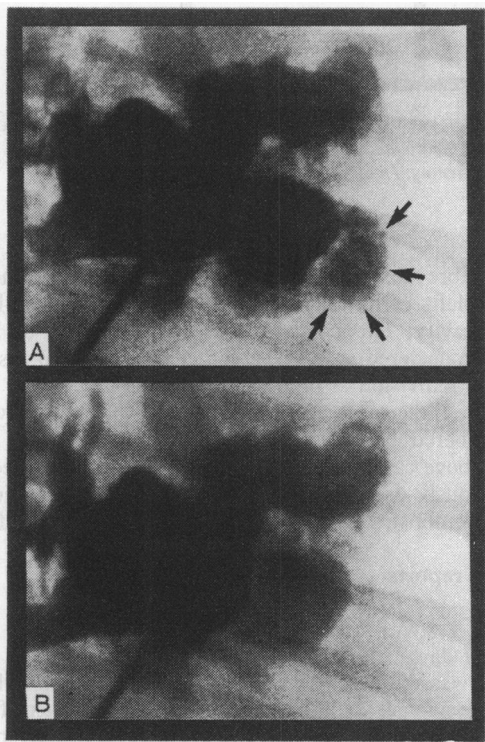


Fig. 2 Angiocardiograms of case 1. (A) Diastolic phase showing the accessory left ventricular chamber, indicated by arrows. (B) Systolic phase showing emptying of the accessory chamber and the non-contracting nature of the proximal left ventricular chamber.

CASE 2 FEMALE CAUCASIAN

(age 3 months)

This was the second child of a 37-year-old thyrotoxic mother; there was no relevant family history. There was some neonatal polycythaemia (haematocrit 68%), prolonged jaundice, and slow feeding. At 1 month there was poor feeding and low weight gain associated with tachypnoea. A pansystolic cardiac murmur was heard at the lower left sternal edge. Chest x-ray film at that time showed a globular heart but without increased pulmonary vascularity. The electrocardiogram showed right axis deviation. The clinical condition improved on digitalis.

At 7 weeks of age she was seen at the paediatric cardiac clinic. The clinical findings were confirmed and the electrocardiogram showed right ventricular hypertrophy. Radiologically the heart was of normal size with an uptilted apex; the lung fields were of normal vascularity. This was considered possibly to be a case of pulmonary stenosis as well as a ventricular septal defect.

When 3 months old she developed a severe chest infection and required artificial ventilation and it was felt necessary to assess the cardiac condition in more detail. Cardiac catheterisation showed poor function of both ventricles, and angiography showed a large persistent ductus arteriosus with a right-to-left shunt and a bizarre appearance of the left ventricle; the apical portion was functioning and distended while the basal portion showed a grossly thickened but non-functioning myocardium (Fig. 3). The child

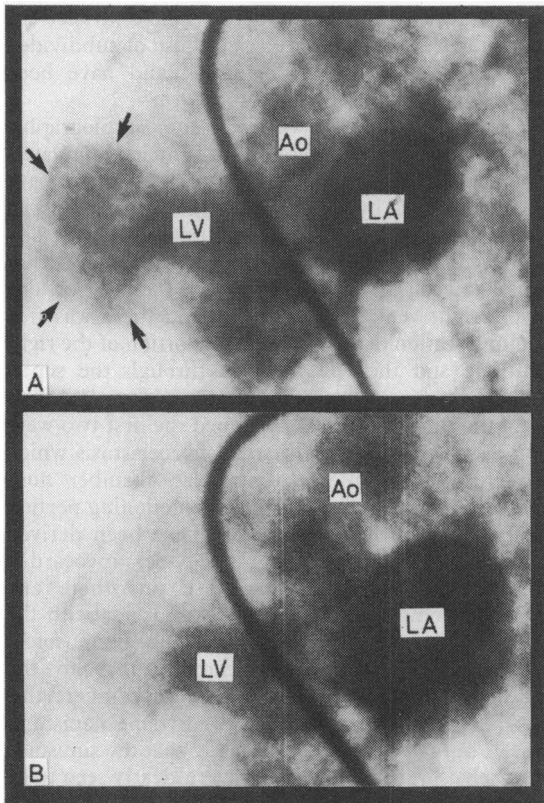


Fig. 3 Angiocardiograms of case 2. Follow through from pulmonary artery injection. (A) Diastolic phase showing the accessory left ventricular chamber, indicated by arrows. (B) Systolic phase showing emptying of the accessory chamber and the non-contracting nature of the proximal left ventricular chamber. LV, left ventricle; LA, left atrium; Ao, aorta.

died on the evening after the investigation while still on the ventilator.

Necropsy showed abnormalities of the cardio-respiratory organs only. The lungs showed severe congenital emphysema of the left lower lobe and collapse, oedema, and congestion of the other lobes. The heart was broad, the apex was normally directed to the left, and the general configuration was that of normal situs solitus morphology with atrioventricular and ventriculoarterial concordance. The systemic and pulmonary veins were normal. The right side of the heart was normal, the atrial septum was closed, and the right ventricular wall was 6 mm thick. The left atrium was of normal size and the endocardium was smoothly thickened, white, and opaque. The mitral valve was small and the chordae tendineae were short and were inserted directly into the ventricular wall in the absence of true papillary muscles.

The left ventricle was remarkable; the wall was thickened and the cavity was subdivided into two portions. In the fixed specimen the upper or basal portion was the larger, 13 mm long and 10 mm diameter, and the hypertrophied free muscular wall was 12 mm thick. This portion was lined by a smooth thickened pearly white endocardium with some small pits; the appearances were typically those of endocardial fibroelastosis and it was obvious that this would have prohibited any expansion or contraction. In the posterior wall there were prominent enlarged branching sinusoids lined by thickened endocardium (Fig. 1). This non-functional proximal portion of the ventricular cavity received the inlet flow from the left atrium and opened into the normally situated aorta. The lower distal or apical portion of the cavity was 8 mm in diameter and the wall was 5 mm thick. The endocardial lining was only slightly thickened, but presented a very corrugated appearance and this had clearly permitted functional expansion and contraction. The two portions of the left ventricle were separated by a moderately constricting "waist" 5 mm in diameter (Fig. 4B). The aortic orifice was adequate; the aortic valve was bicuspid and slightly thickened and irregular.

The ductus arteriosus was patent (lumen 2.5 to 4 mm diameter) and there was slight preductal aortic isthmus stenosis.

CASE 3 FEMALE CAUCASIAN (age 2 hours)

This child of a healthy 27-year-old mother was delivered by caesarian section because of hydramnios. Prenatal ultrasound scanning had shown gross enlargement of the fetal heart. On delivery she was grossly hydropic and 220 ml fluid was removed from the abdominal cavity. She was artificially ventilated and given digitalis and diuretics but she died shortly

after birth. Investigations showed haemoglobin 13.1 g/100 ml, blood leucocytes 14 000 per mm³, normal serum urea and electrolytes, serum calcium 2.66 mg/100 ml, and gross hypoproteinaemia (total protein 21 g/l, serum albumen 13 g/l). Chromosome analysis, rubella, herpes, and cytomegalovirus titres and amino acid chromatography were all normal.

Necropsy showed generalised oedema, but the only anatomical abnormality was found in the heart which was grossly enlarged, globular, and of almost cystic appearance, 50 × 35 × 40 mm diameter. The systemic and pulmonary veins were normal; the atria were of normal situs solitus morphology and communicated through a 5 mm diameter patent foramen ovale. The atrioventricular valves were normal and there was atrioventricular concordance. The right ventricle was of normal morphology and opened into a normally situated, but slightly dilated pulmonary artery, 7 mm in diameter.

The left ventricle was bizarre and was almost completely divided into two portions, which were side by side. The medial compartment was the smaller and was adjacent to the normal interventricular septum; it received the inlet flow from the left atrium via the mitral valve and opened into the normally situated aorta and therefore corresponded to the main left ventricular cavity. The larger lateral compartment included most of the free lateral wall of the ventricle and the apex and appeared to be an almost aneurysmal sac 30 mm in diameter. The wall of the left ventricle was up to 8 mm thick but in most of the lateral portion it was considerably attenuated and in the apical region it was of paper-thinness. The two portions of the left ventricular cavity communicated through two openings, each 5 mm in diameter, one at the base posteriorly behind a distorted flattened papillary muscle and the other at the apex. The muscular pseudo-septum between these two components of the left ventricle was continuous with the muscle of the free wall and it included the lateral papillary muscle; the medial papillary muscle was not defined. The lateral cavity had no direct communication with the atrium or with any vessels and appeared to be an aneurysmal diverticulum (Fig. 1 and 4C and D). The ascending aorta was 5 mm in diameter, the valve was normal, and the coronary arteries, though narrow, had normal origins and distribution. There was a 4 mm diameter patent ductus arteriosus with a moderate preductal stenosis of the aortic isthmus to 2 mm in diameter. The aortic arch and its branches were otherwise normal. The endocardium was not thickened.

Sections of the left ventricular wall showed slight pericardial thickening with normal coronary arteries and veins and no evidence of inflammatory infiltration. The myocardium showed some atrophy of

the muscle fibres with some separation and patchy replacement fibrosis. There were small areas of micro-nodular fibrosis, mainly in the inner zone, but separated from the endocardium by a narrow band of normal muscle and devoid of any changes suggestive of past or present inflammation. The thinned-out apical area showed a slightly thickened visceral pericardium, a narrow layer of small myocardial fibres, and a normal endocardium. There were very occasional minute areas of dystrophic calcification.

Discussion

Subdivision of the left ventricle is a rare condition compared with subdivision of the right ventricle; this is probably because the right ventricle is normally partially divided into inlet and outlet portions by the muscular ridge of the crista supraventricularis and the trabecula septomarginalis. Abnormalities of the various muscle bands in this region are the most frequent cause of two chambered right ventricle,¹⁶⁻²⁰ but some cases of similar type to those of subdivided left ventricle have been described and have been referred to.^{4 5 7 13-15}

Confusion may arise when the angiocardigraphic findings of a two chambered right ventricle simulate a two chambered left ventricle; two such cases have been described by Beitzke and his colleagues,²¹ in cases with double outlet right ventricle, subdivided by a muscular band and associated with ventricular septal defects; the openings between the two portions of the right ventricle were small and there was free communication between the distal portion of the right ventricle and the left ventricle through the septal defect, which accounted for the spurious appearances.

Of the three new cases described the first two were both associated with endocardial fibroelastosis which rendered the main left ventricular chamber non-contractile, and in both cases the functioning portion of the left ventricle appeared to have been derived from expansion of the intratrabecular myocardial sinusoids though in neither case was there any apparent communication of these sinusoids with the coronary arteries. It is possible that the sinusoidal dilatation was adaptive or compensatory to the rigidity of the main left ventricular chamber; this appears to have been a major causative mechanism in case 1, but it was apparent in case 2 that the sinusoids themselves were abnormal and were clearly seen to be grossly enlarged and were involved in the endocardial fibroelastosis even within the wall of the proximal portion of the left ventricle (Fig. 4). Abnormality of the myocardial intratrabecular sinusoids has been described in association with left ventricular endocardial fibroelastosis in cases of congenital aortic stenosis.^{14 22} Septal sinusoid enlargement and

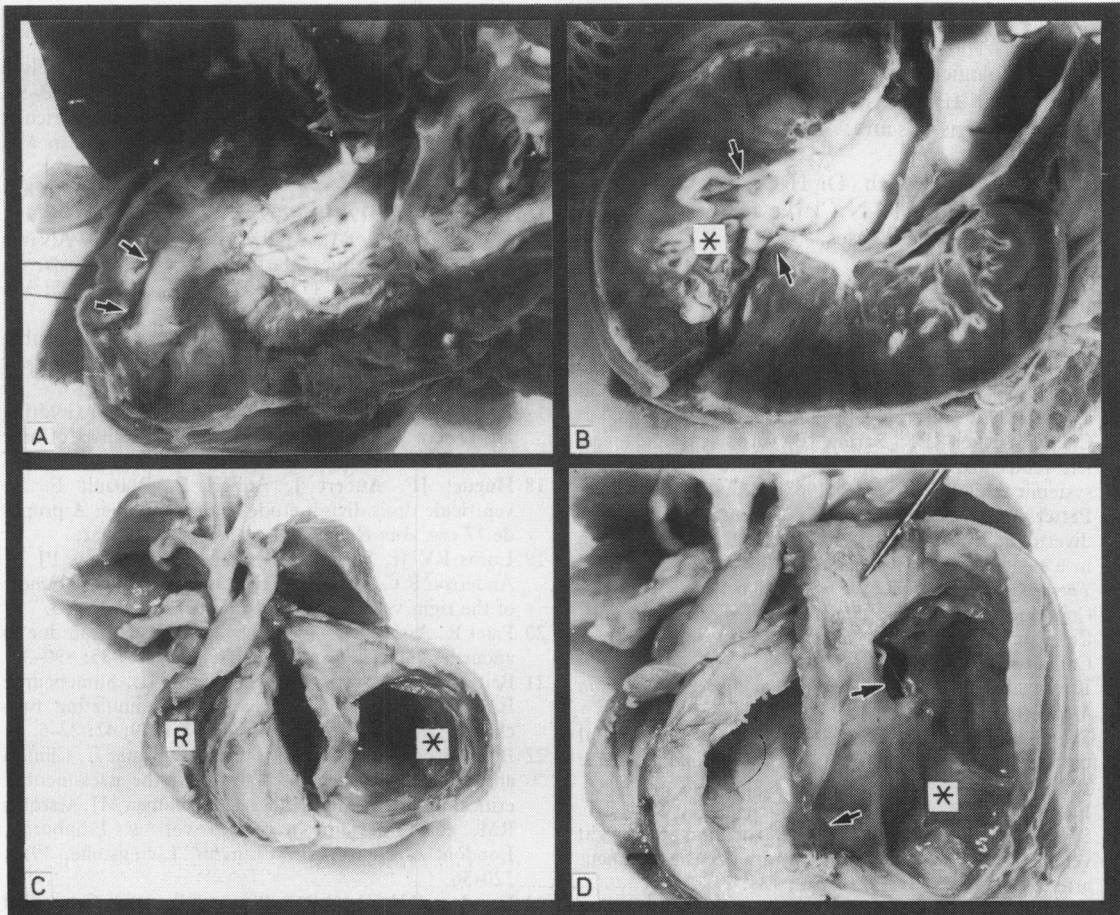


Fig. 4 (A) Case 1. The left side of the heart has been opened in the sagittal plane and viewed from the left side. The upper portion of the left ventricle is lined by a greatly thickened white endocardium in which there are small pit-like openings. The cleft part of the distal chamber lies within the apical muscle mass and is indicated by arrows. (B) Case 2. Section and orientation as for Fig. A. The proximal left ventricular cavity is lined by thickened endocardium and the distal cavity is marked by an asterisk; the "waist" between them is indicated by arrows. Prominent abnormal intramyocardial sinusoids are seen on the right side below the mitral valve. (C) Case 3. Anterior view of the heart showing the appearance of "three ventricles". The right ventricle (R) has been opened vertically and the anterior wall of the left ventricle has been removed; the distal or lateral left ventricular cavity is marked with an asterisk. (D) Case 3. View of the lateral cavity of the left ventricle showing the medial wall in which the two openings into the medial cavity are indicated by arrows. Attachment of mitral valve chordae tendineae is seen at the upper orifice.

communication with the right ventricular cavity has been described in two cases of congenital tricuspid atresia with absence of the pulmonary valve²³; these were not associated with endocardial fibroelastosis and are similar to the case described by Quero Jiménez *et al.*¹⁵ and referred to above, in which the degree of sinusoid enlargement was such that it was regarded as an additional (right) ventricle.

In all of these reported cases the sinusoid enlargement was associated with ventricular outflow obstruction and in the left sided cases endocardial fibroelastosis was a constant additional feature. In

case 2, however, there was no significant aortic stenosis though the valve was bicuspid and deformed. It is therefore considered probable that a primary maldevelopment of the myocardial intratrabecular sinusoids is the primary underlying anomaly in some varieties of two chambered ventricle and that haemodynamic factors may be contributory in some cases.

Case 3 presented an entirely different situation; the presence of "lateral" myocardial wall on both sides of the lateral compartment of the left ventricle, with atrophic, fibrotic, and calcific changes in the apical

region, indicate that this is an aneurysmal cavity not of the lateral wall, but *within* the lateral wall. There was no histological evidence of involvement of the intratrabecular sinusoids, and the aetiology of the condition remains obscure.

We thank Dr J B Lynch, Dr H G Kohler, Dr M G Hamilton, and Dr P C N Clarke for permission to publish details of these cases.

References

- 1 Gueron M, Hirsch M, Opschitzer I, Mogel P. Left ventricular diverticulum and mitral incompetence in asymptomatic children. *Circulation* 1976; **53**: 181–6.
- 2 Chesler Tucker RBK, Barlow JB. Subvalvular and apical left ventricular aneurysms in the Bantu as a source of systemic emboli. *Circulation* 1967; **35**: 1156–62.
- 3 Pettersson G, Bergström T. A case of ruptured diverticulum of the left ventricle and hemopericardium in a neonate, treated successfully by surgery. *Scand J Thorac Cardiovasc Surg* 1969; **3**: 203–6.
- 4 Copeland J, Higgins C, Hayden W, Stinson EB. Congenital diverticulum of the right ventricle. *J Thorac Cardiovasc Surg* 1975; **70**: 536–8.
- 5 Kavanagh-Gray D. Right ventricular diverticulum. *Can Med Assoc J* 1971; **105**: 1055–6.
- 6 Swyer AJ, Mauss IH, Rosenblatt P. Congenital diverticulosis of left ventricle. *Am J Dis Child* 1950; **79**: 111–4.
- 7 Farnsworth PB, Lefkowitz M, Shehadi W, Chan TT. Spontaneous rupture of fibrous diverticulum of the right ventricle. Occurrence in an infant with persistent truncus arteriosus. *Am J Dis Child* 1972; **123**: 248–50.
- 8 Cantrell JR, Haller JA, Ravitch MM. A syndrome of congenital defects involving the abdominal wall, sternum, diaphragm, pericardium, and heart. *Surg Gynecol Obstet* 1958; **107**: 602–14.
- 9 Edgett JW, Nelson WP, Hall RJ, Fishback ME, Jahnke EJ. Diverticulum of the heart. Part of the syndrome of congenital cardiac and midline thoracic and abdominal defects. *Am J Cardiol* 1969; **24**: 580–3.
- 10 Lovitt WV Jr, Lutz S Jr. Embryological aneurysm of the myocardial vessels. *Arch Pathol* 1954; **57**: 163–7.
- 11 Wagner ML, Singleton EB, Leachman RD. Congenital left ventricular diverticulum. *AJR* 1974; **122**: 137–45.
- 12 Patterson EL, Spink MS. Congenital epicardial cyst. *J Pathol Bacteriol* 1958; **76**: 601–4.
- 13 Grant RT. An unusual anomaly of the coronary vessels in the malformed heart of a child. *Heart* 1926; **13**: 273–83.
- 14 Quero-Jiménez M, Casanova Gomez M. Left ventricular outflow tract obstruction pathology. In: Godman MJ, Marquis RM, eds. *Paediatric cardiology*, vol. 2. Edinburgh, London, & New York: Churchill Livingstone, 1979; 196–209.
- 15 Quero-Jiménez M, Maître Azcárate MJ, Alvarez Bejarono H, Vázquez Martul E. Tricuspid atresia. An anatomical study of 17 cases. *Eur J Cardiol* 1975; **3/4**: 337–348.
- 16 Gale GE, Heinmann KW, Barlow JB. Double chambered right ventricle. A report of 5 cases. *Br Heart J* 1969; **31**: 291–8.
- 17 Hartmann AF Jr, Tsifutis AA, Arvidsson H, Goldring D. The two chambered right ventricle. Report of nine cases. *Circulation* 1962; **26**: 279–87.
- 18 Huguet JF, Aubert J, Aubert F, Rouault F. Le ventricule droit divisé; étude angiographique. A propos de 17 cas. *Ann Radiol (Paris)* 1979; **22**: 445–52.
- 19 Lucas RV Jr, Varco RL, Lillehei CW, Adams PJ Jr, Anderson R C, Edwards J E. Anomalous muscle bundle of the right ventricle. *Circulation* 1972; **25**: 443–55.
- 20 Patel R, Astley R. Right ventricular obstruction due to anomalous muscle bands. *Br Heart J* 1973; **35**: 890–3.
- 21 Beitzke A, Anderson RH, Wilkinson JL, Shinebourne EA. Two-chambered right ventricle; simulating two-chambered left ventricle. *Br Heart J* 1979; **42**: 22–6.
- 22 Buhlmeier K, Simon B, Morcellin R, Sauer U. Clinical angiographic and functional studies in the assessment of critical valvular aortic stenosis. In: Godman MJ, Marquis RM, eds. *Paediatric cardiology* vol. 2. Edinburgh, London, & New York: Churchill Livingstone, 1979; 220–36.
- 23 Freedom RM, Patel RG, Bloom KR, et al. Congenital absence of the pulmonary valve associated with imperforate membrane type of tricuspid atresia, right ventricular tensor apparatus and intact ventricular septum; a curious development complex. *Eur J Cardiol* 1979; **10**: 171–96.

Request for reprints to Dr L M Gerlis, Cardiac Research Unit, Killingbeck Hospital, Leeds LS14 6UQ.