

# Coronary thrombosis in pathogenesis of acute myocardial infarction

## *Histopathological study of coronary arteries in 108 necropsied cases using serial section<sup>1,2</sup>*

TOSHINOBU HORIE, MORIE SEKIGUCHI, AND KOSHICHIRO HIROSAWA

*From the Department of Cardiology, Heart Institute Japan, Tokyo Women's Medical College, 10 Kawada-cho, Shinjuku-ku, Tokyo, Japan*

**SUMMARY** An extensive histopathological study was carried out on the hearts of 108 patients with electrocardiographically proven acute myocardial infarction dying after admission to a coronary care unit. The occluded or the narrowest segments of the coronary arteries were examined at intervals of 100  $\mu$  using serial sections. Serial sectioning is important in such a study because the pathology of the lumen can vary considerably within a 2 to 3 mm segment. A high incidence (80.3%) of thrombus formation corresponding to the site of infarction was observed. These thrombi occluded the vessel lumen, were usually found proximally in the coronary arteries, and were associated with a ruptured atheromatous plaque in 90.8 per cent of cases. It is postulated that an increase of intraplaque pressure resulting from a honeycomb-like accumulation of foam cells, cholesterol clefts, and blood infiltration through the injured endothelial cells is the cause of rupture of the atheromatous plaque. This rupture into the vessel lumen may precede, and be responsible for, formation of thrombus and the onset of acute myocardial infarction.

The relation between coronary thrombosis and atherosclerosis in the pathogenesis of acute myocardial infarction is of great importance. Classically, infarction is presumed to follow thrombosis at the site of an atheromatous plaque which is causing severe stenosis of one of the main coronary arteries or their branches. However, coronary thrombi are not always found (Brest *et al.*, 1974; Eliot *et al.*, 1974; Khan and Haywood, 1974; Arnett and Roberts, 1976), or the ratio of coronary thrombi to acute myocardial infarction is very low (Branwood and Montgomery, 1956; Ehrlich and Shinohara, 1964; Hashimoto *et al.*, 1969; Otsu, 1970; Roberts and Buja, 1972; Baroldi *et al.*, 1974; Baroldi, 1976).

Furthermore, Branwood and Montgomery (1956) reported that many occluding thrombi appear to be of more recent origin than their related infarcts and suggested that they might develop in some cases of established recent myocardial infarction as a terminal event. This is supported by Baroldi *et al.* (1974), and Baroldi (1976) who reported that in some patients with acute infarction, stenosis of the coronary lumen was already 70 per cent or more at the site of the thrombus, which, therefore, did not decrease the coronary flow to the myocardium. Thus many have concluded that coronary thrombosis is probably a secondary event (Branwood and Montgomery, 1956; Ehrlich and Shinohara, 1964; Roberts and Buja, 1972; Baroldi *et al.*, 1974; Baroldi, 1976).

In our view, the explanation for differing theories of the pathogenesis of acute myocardial infarction lies in variations of technique and in the selection of case material, and we, therefore, examined the coronary arteries in necropsied hearts where death occurred at the acute stage of the infarction, and used the method of serial histopathological section.

<sup>1</sup>Presented in part at the 4th International Symposium on Atherosclerosis, Tokyo, Japan, 28 August 1976.

<sup>2</sup>Supported by grants from the Japanese Ministry of Education in 1975.

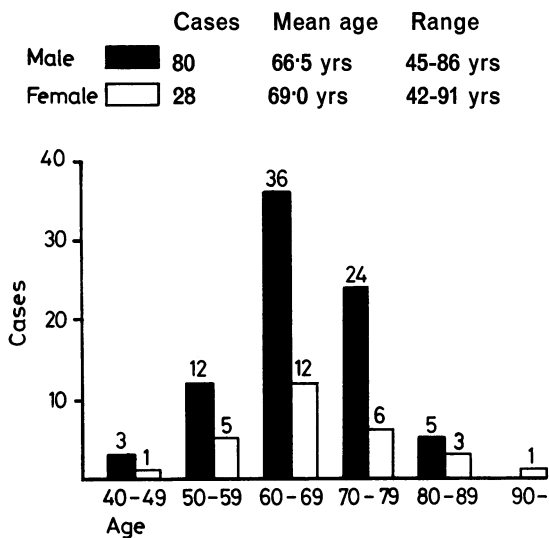


Fig. 1 Sex and age distribution of 108 necropsied cases of acute myocardial infarction.

### Subjects and methods

This study was performed on the hearts of 108 patients who had been admitted to the coronary care unit at the Heart Institute of Japan, Tokyo Women's Medical College, between 1 January 1967 and 30 January 1975. These patients had chest pain diagnosed as acute myocardial infarction clinically, by electrocardiogram, and by laboratory data; and necropsy which was performed at the Second Department of Pathology, disclosed coagulation necrosis of the myocardium in every case. The time interval between the onset of symptoms and death was ascertained accurately in all. The distribution of age and sex is shown in Fig. 1. Cases of sudden death without myocardial necrosis at necropsy were excluded from the study. The hearts weighed from 275 to 750 g, the mean being 436 g. After formalin fixation, each heart was cut into slices 1 cm thick, embedded in paraffin, and transversely sectioned (Fig. 2) in order to determine the site of the infarcted area.

Each coronary artery and its branches were carefully cut transversely into segments at 3 mm intervals along its entire course. Decalcification, where necessary, was performed by immersion in 5 per cent formic acid solution for 48 hours first. The segments were inspected with a stereoscopic microscope and diagrammatically sketched. After this, each was dehydrated with alcohol, cleared with xylene, embedded in paraffin, and sectioned.

When occlusion was present, both the occluded

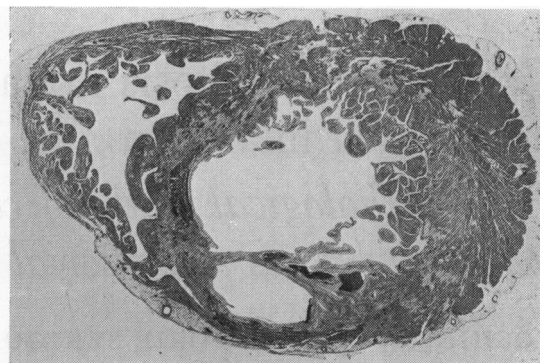


Fig. 2 Large histological section containing both ventricles of the heart. Antero-septal myocardial infarction is clearly seen. (Masson's trichrome stain.  $\times 0.5$ .)

segments of the coronary artery and the segments 3 mm proximal and distal to them were sectioned transversely at intervals of 100  $\mu$ .

In cases where a thrombus was not detected, coronary segments showing the most severe stenoses were examined by serial section in this manner. All sections were stained with haematoxylin and eosin, Masson's trichrome, elastic van Gieson, periodic acid methenamine silver (PAM) (Yajima, 1959), and phosphotungstic acid-haematoxylin (PTAH). Histopathological findings of the myocardium were assessed using Mallory's standard criteria (Mallory *et al.*, 1939). Fresh occluding coronary thrombi were selectively examined, but mural and organised thrombi were also studied for purposes of comparison.

### Results

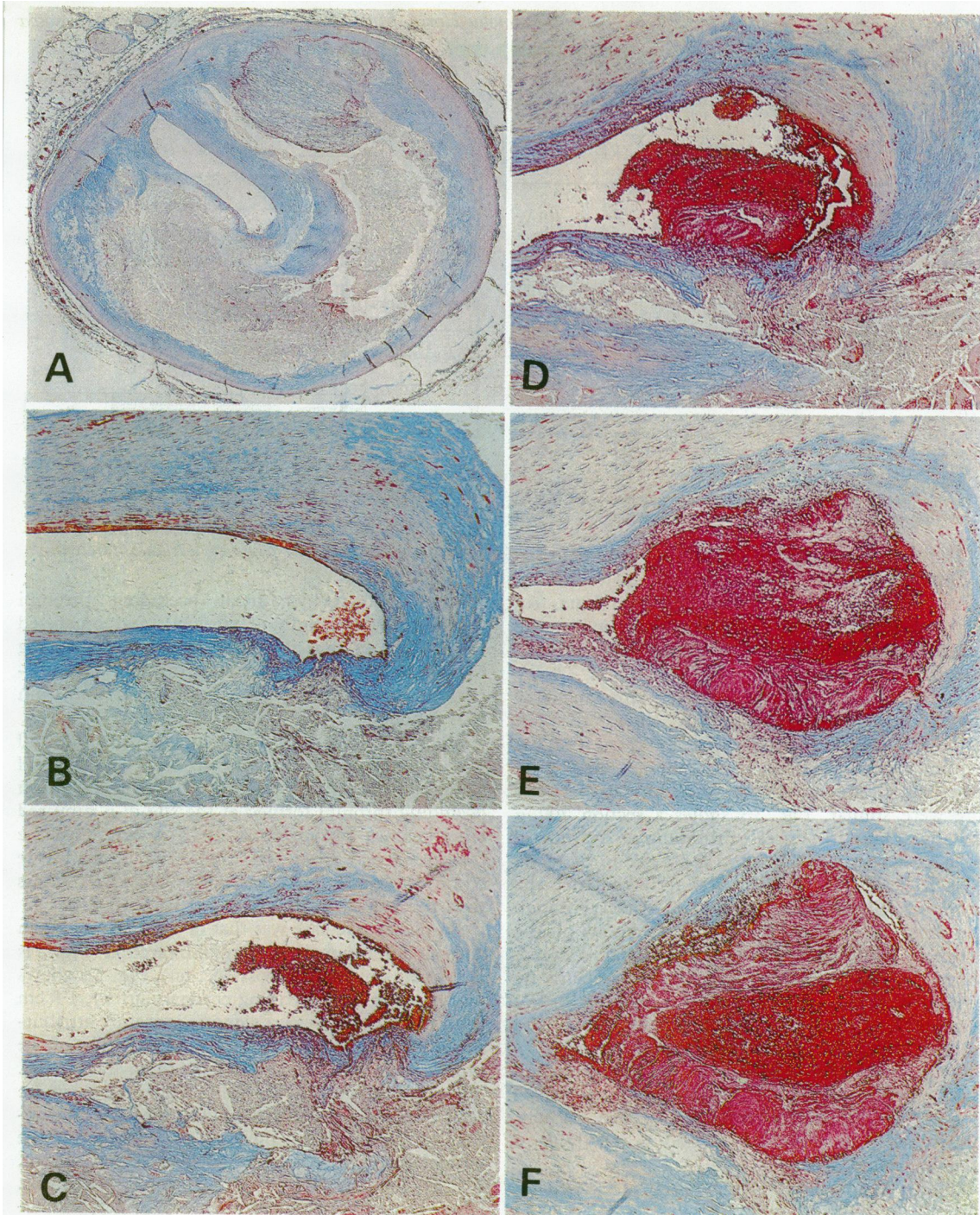
#### SITE AND AGE OF INFARCTION

The relation between the age of the myocardial infarction and the location of the infarcted areas is shown in Table 1.

#### CORONARY THROMBI

A fresh and occluding coronary thrombus was found in 70 cases, 6 of them having 2 thrombi. In the left coronary artery, many thrombi were sited within the first 3 cm of its course, but in the right, the distribution was more scattered. Occluding thrombi were usually about 1 cm in length, but 14 of them were 3 mm or less. In 4 instances, the occluding mass was a bolus of atheromatous debris extruded from an ulcerated atherosclerotic plaque. Mural thrombi were recognised in 6 cases and organised thrombi in 17; in 15 others, no thrombus at all was found.





**Fig. 3** Six sections of the left anterior descending coronary artery of a patient who died 2 days after an attack of acute myocardial infarction. (Masson's trichrome stain, A:  $\times 20$ ; B-F:  $\times 60$ ) (A) (1.5 cm from the ostium) Severe luminal stenosis caused by atheromatous deposition. No evidence of luminal thrombus. (B) (200  $\mu$  distally) A thinned area of intimal collagen fibres faces the lumen. (C) (400  $\mu$  distally) The group of red and white cells is larger. (D) (700  $\mu$  distally) A thrombus has been formed at the site of the thinned intimal collagen fibres. (E) (1000  $\mu$  distally) The multilayered structure of the thrombus is clearly evident. (F) (1600  $\mu$  distally) Complete blockage of the lumen by the thrombus.

Table 1 Relation between age of myocardial infarction and location of infarcted area

Location of infarcted area	Age of infarction			Total
	Fresh*	Fresh + Old†	Old‡	
Anterior	1	1	0	2
Anteroseptal	17	15	8	40
Anteroseptal and lateral	10	5	4	19
Anterolateral	1	2	0	3
Lateral	0	2	1	3
Posterolateral	2	3	3	8
Posterolateral and septal	4	0	1	5
Posteroseptal	9	7	4	20
Posterior	1	1	0	2
Anteroseptal and posterior	2	2	1	5
Anteroseptal and posterolateral	0	0	1	1
Total	47	38	23	108

\*Microscopical changes such as coagulation necrosis in muscle fibres with or without polymorphonuclear cell infiltration are found. Granulation tissue is either not present or a narrow zone at periphery of infarct.

†Combination of 'fresh' and 'old'.

‡Granulation tissue extends throughout the infarcted area and no fresh changes are found on microscopical examination.

In 14 instances, though thrombi were not detected by the stereoscopic microscope, occlusive lesions were found by the serial section technique. An illustrative case shows how lesions of importance may be concealed within a paraffin-embedded block as small as 2 to 3 mm.

A 68-year-old man died 2 days after an acute myocardial infarction. Fig. 3A shows the left anterior descending coronary artery 1.5 cm from the ostium. Severe stenosis of the lumen caused by atheroma is present. Further sections at the same site were similar. Fig. 3B shows a section 200  $\mu$  distally. There is an area of thinning of the intimal collagen close to the lumen, and a group of blood cells is nearby. Fig. 3C is 200  $\mu$  further on; the group of cells is larger. Infiltration of cells through the thinned collagen into the atheromatous plaque is seen. Fig. 3D is 300  $\mu$  more distal. Here, a thrombus has been formed at the same site. Its structure is not uniform; it is multilayered, and composed of plasma surrounded by fibrin and cellular elements. This multilayered structure is more evident in Fig. 3E, another 300  $\mu$  beyond, and Fig. 3F, 600  $\mu$  distal to 3E, shows complete occlusion of the lumen by thrombus. These findings suggest that thrombus is formed gradually in a stepwise manner.

Fig. 4 shows the relation between coronary thrombi and the duration of survival after acute myocardial infarction. Thrombi were found in 16 of 18 patients (88.9%) dying within 24 hours, in 57 of 71 patients (80.3%) dying within 2 weeks, in 8 of 14 patients (57.1%) dying between 2 weeks and 1 month, and in 5 of 23 patients (27.1%) dying after 1 month.

Duration of survival Cases %

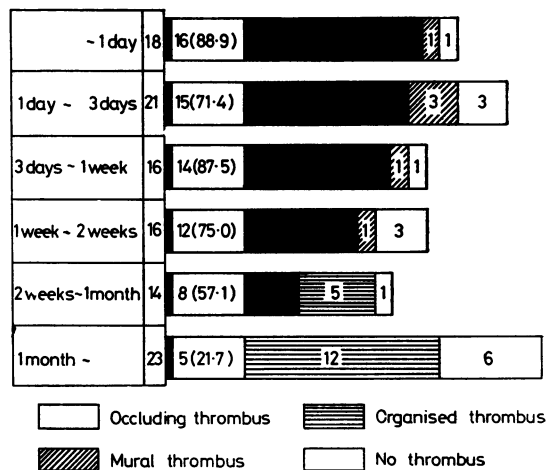


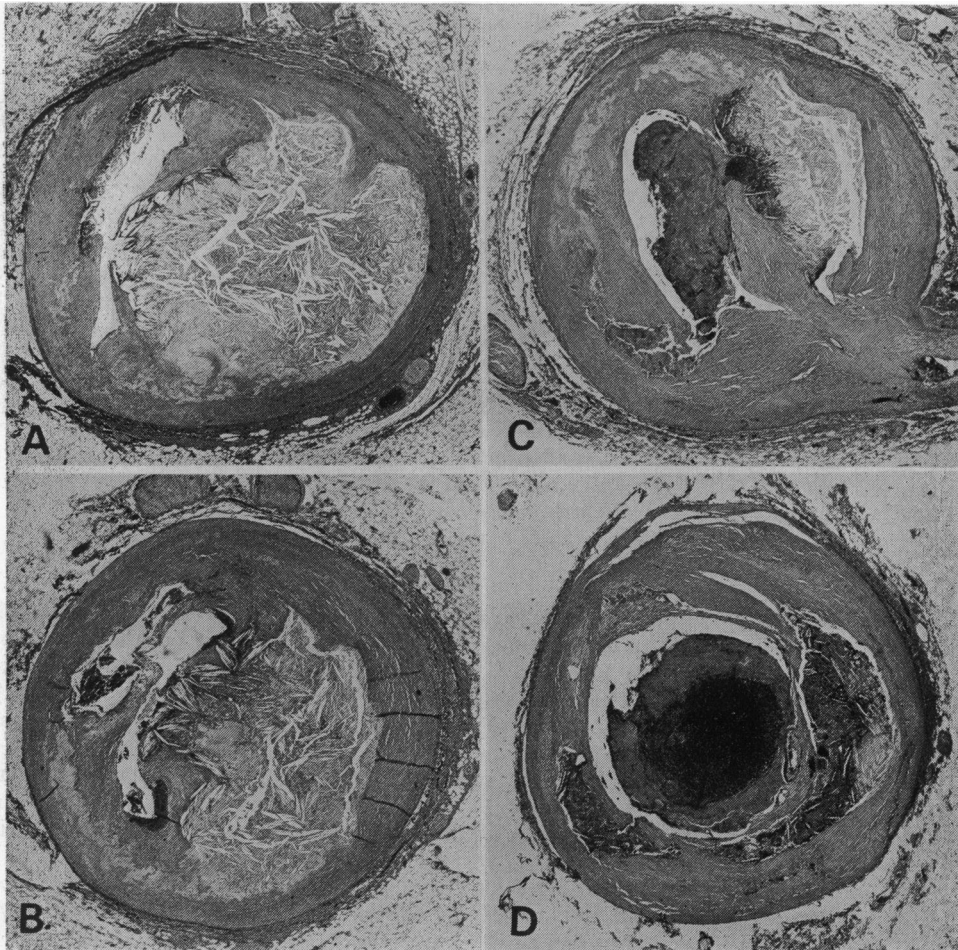
Fig. 4 Relation between coronary thrombi and the duration of survival after acute myocardial infarction.

The incidence of fresh occluding thrombi decreased with length of survival, and organised thrombi were found more often in patients surviving over 1 month. Fresh occluding thrombi were discovered in 2 cases in which death occurred within 5 or 6 hours.

Though calcification of the coronary arterial wall was unrelated to thrombosis, other histological changes were. In 69 of the 76 instances, fresh occluding thrombi formed at the site of a ruptured atheromatous plaque (90.8%). The length of the fracture varied from 100  $\mu$  to 1300  $\mu$ , while the width, which in most cases was considerably less than the length, varied from 30  $\mu$  to 1000  $\mu$ .

An illustrative case was that of a 56-year-old man with an anteroseptal myocardial infarction (Fig. 2 is in fact his ventricular cross-section). Fig. 5A shows his left anterior descending coronary artery, 1.8 cm from the ostium. Severe stenosis is mainly attributable to an atheromatous plaque. Destruction of the intimal collagen fibre layer seems to have occurred. The ruptured ends of the wall of the plaque can be seen directed towards the lumen. There is infiltration of blood and deposition of fibrin onto the intimal collagen. No endothelial cells are present. Fig. 5B shows a section 300  $\mu$  distal to that in 5A. Here, cholesterol clefts are seen, lying perpendicularly to the lumen. In addition, the deposit of fibrin in the atheromatous plaque has increased. Fig. 5C shows a section 1.2 mm more distal. The atheromatous plaque is smaller, but though the lumen is wider, the deposition of fibrin in the plaque is much greater, and a thrombus has formed at the site of





**Fig. 5** Four sections of the left anterior descending coronary artery of a patient who died of anteroseptal myocardial infarction. (Masson's trichrome stain,  $\times 20$ .) (A) (1.8 cm from the ostium) The ruptured ends of the walls of the abscess can be seen directed towards the lumen. (B) (300  $\mu$  distally) Cholesterol clefts lying perpendicular to the coronary lumen. (C) (1500  $\mu$  distally) A thrombus has formed at the site of the ruptured atheromatous plaque. (D) The thrombus can be recognised easily in this section.

The 'intraplaque haemorrhage' is mild and localised mainly near the lumen (A). However, it is larger in more distal segments (B, C) and occupies most of the plaque in (D).

the rupture. In Fig. 5D, 2.2 mm beyond, the lumen is again larger, and the deposition of fibrin yet further increased. The thrombus in this section could be easily recognised by the naked eye.

**Table 2** Severity of stenosis at site of ruptured atheromatous plaque

Severity of stenosis	0-25%	25-50%	50-75%	75-100%	Total
Cases	1	3	14	51	69
%	1.5	4.3	20.3	73.9	100

In 51 of the 69 cases in which a ruptured atheromatous plaque was present, the severity of the stenosis of the vessel lumen was 75 per cent or more (Table 2).

Histopathological examination of coronary thrombi showed erythrocytes and leucocytes in fibrin nets in all thrombosed segments. At the site of ruptured atheromatous plaques, coronary thrombi containing cholesterol crystals, foam cells, and fractured intimal collagen fibres were found.

Portions of atheromatous plaque which would probably have ruptured in the near future were also

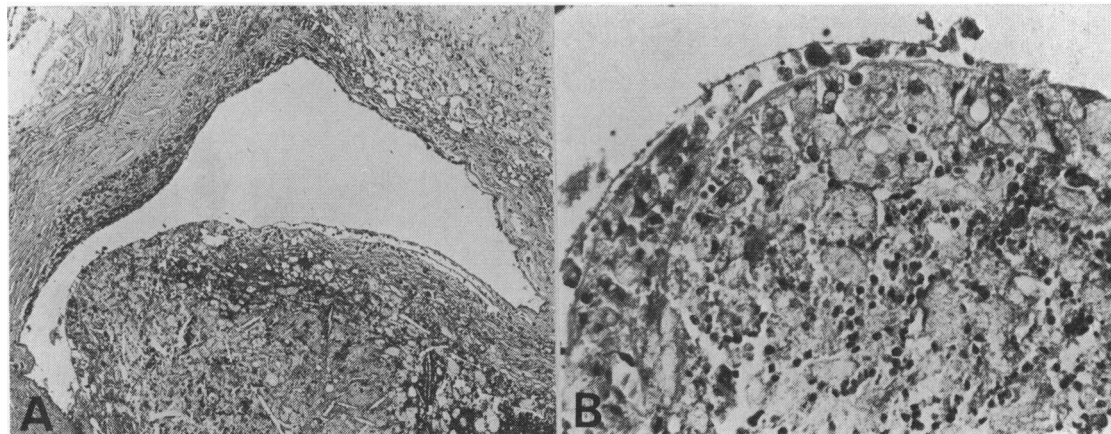


Fig. 6 The area of the atheromatous plaque which would have probably ruptured in the near future. (Masson's trichrome stain, A:  $\times 60$ ; B:  $\times 250$ ) Here, no endothelial cells are found. The intimal collagen fibres are thin and irregular. Many foam cells are found near the lumen. Infiltration of blood cells into the plaque is also seen.

found (Fig. 6A, B). Here, the intimal collagen fibres had become thin and irregular and infiltration of blood cells from the lumen into the atheromatous plaque through the injured endothelial barrier was observed. A honeycomb-like accumulation of foam cells was seen.

### Discussion

#### (1) RELATION BETWEEN CORONARY THROMBUS AND ACUTE MYOCARDIAL INFARCTION

In the many published studies concerning the relation between coronary thrombosis and acute myocardial infarction, the various investigators have differed in their definition of myocardial infarction by size, ranging between 2.5 cm across (Chapman, 1968) and 4 cm (Sinapius, 1972a), and this has been determined by gross examination and only in some cases confirmed histopathologically. Additionally, in these studies the pathogenesis of coronary thrombus has not been fully entered into. By contrast, when it has, the extent of myocardial infarction has not been stated (Friedman and Van den Bovenkamp, 1966).

In Friedman's detailed study, for instance (Friedman and Van den Bovenkamp, 1966), 11 of the 40 cases died suddenly and it is not clear whether these patients were clinically diagnosed as having acute myocardial infarction. In our study, however, the diagnosis of infarction was secure, both clinically and pathologically. Indeed correlation of the clinical and pathological facts in each case is vital if the causal relations of atherosclerosis coronary thrombosis, and the onset of acute myocardial infarction are to be elucidated.

Chapman (1968, 1974) described 303 acute infarcts in 292 hearts and found a recently occlusive thrombus in an extramural branch of a coronary artery in association in 278 of them (91.4%). His definition of acute myocardial infarction was limited to 'well defined zones of necrosis, at least 2.5 cm in the greatest dimension and estimated to have occurred within one month of autopsy', and the extramural branches of the coronary arteries were examined by longitudinal incision.

Sinapius (1972a) found a coronary artery occluded by thrombosis in 184 of 206 cases of myocardial infarction (89.3%). This was present in 164 of 170 transmural infarcts of more than 4 cm diameter (96.5%) and in 20 of 36 infarcts smaller than this (55.6%). Thus, there appeared to be a higher incidence of thrombus formation in larger infarctions.

Branwood and Montgomery (1956), however, reported recent coronary thrombosis which was fully occlusive in only 13 of their 61 cases of recent infarcts (21.3%), and later, Montgomery (1959) was unable to find any occlusion in the extramural coronary arteries of 45 of 108 further cases (42%).

By contrast, Bouch and Montgomery (1970) then reported that in 100 consecutive patients dying from myocardial ischaemia, occluded coronary arteries were found in 88 (88%), and stated that this contradiction of previous results was largely attributable to alterations of technique. In addition, they believed that case selection might have played a part.

Spain and Bradess (1960) found fresh thrombi in 16 per cent of patients who survived less than 1 hour

after infarction, in 37 per cent of patients who survived from 1 to 24 hours, and in 57 per cent of patients who survived over 24 hours. Thus, they believed there to be a direct relation between the incidence of thrombi and the length of survival after the acute episode. Later, Spain *et al.* (1974) reported that 45 of 50 (90%) recent transmural infarcts having a clinical age of no more than 2 weeks were associated with recent coronary thrombi. He also pointed out that in most previous necropsy studies of patients with myocardial infarction, deaths from arrhythmias and pump failure had been classified together.

Hashimoto *et al.* (1969) found coronary thrombi in 31 of 100 Japanese cases of myocardial infarction. Seventeen of these were organised thrombi, while non-organised thrombi were found in only 14. The series consisted of 8 cases with fresh infarction, 66 cases with old infarction, and 26 cases with both fresh and old. Thus, a large proportion had old infarction.

Finally, Otsu (1970) reported on a survey which had been performed by the Japanese Pathological Society. In this study, coronary thrombi were found by gross examination in only 101 (29.9%) of 338 cases of myocardial infarction. The conclusion was that the incidence as well as the severity of coronary disease was considerably lower in Japanese and that advanced stenosis and thrombosis of the coronary arteries seemed to be encountered less in Japan than in Western countries; however our study shows that this is not the case.

In these reports, whenever serial section was not used or when many cases of old infarction were included in the series, the incidence of coronary thrombi was low, thus leading some to conclude that coronary thrombus was a consequence rather than a cause of acute myocardial infarction (Branwood and Montgomery, 1956; Ehrlich and Shinohara, 1964; Roberts and Buja, 1972; Baroldi *et al.*, 1974; Baroldi, 1976).

By comparison our study showed a high incidence of fresh occluding coronary thrombi in cases of acute myocardial infarction, and this was probably precisely for these two reasons. Examining coronary arteries at intervals of 100  $\mu$  using serial sections detected coronary thrombi in 14 cases and which had in our view, not been discovered by routine histological section. The pathology of the coronary arterial lumen is so variable, even within a 2 to 3 mm segment of the diseased vessel, that this is mandatory.

Secondly, fresh occluding thrombi were found more commonly in patients dying during the acute stage of infarction than in those surviving 1 month or more, and in the latter, many organised thrombi were present. Hence it is necessary to examine

diseased arteries in patients who die at the acute stage of infarction. Thus, we conclude that coronary thrombi are responsible for the onset of acute myocardial infarction in most instances.

#### PATHOGENESIS OF CORONARY THROMBOSIS

Paterson (1936, 1938) showed by serial section that intimal haemorrhage resulted from the rupture of capillaries which arose from the coronary lumen, and that this rupture was caused by high intracapillary pressure. However, Crawford (1961) believed that the intracapillary pressure did not become high enough to do this.

In 4 of 17 cases studied by Constantinides (1966), relatively minor haemorrhages were present which resulted from the rupture of intraplaque capillaries which were not connected to the lumen. Thus he concluded that such capillary bleeding was not directly responsible for the thrombosis that occurred in its area. He also reported that in all 17 cases, recent thrombi were attached to cracks in the atherosclerotic wall. The same findings were reported by Chapman (1968, 1974), Friedman and Van den Bovenkamp (1966), Friedman (1969), and Sinapius (1972a, b).

Friedman and Van den Bovenkamp (1966) and Friedman (1969) examined 40 thrombosed coronary artery segments and reported that in 39 of them (97.5%) the thrombus was in direct communication with a pre-existing intramural atheromatous abscess.

Our work supports Friedman's (1966, 1969), because in 69 of 76 cases (90.8%) we found a direct communication between the thrombus and the atheromatous plaque, whereas capillary rupture at the site of thrombosis was not observed.

We believe that so-called 'plaque haemorrhages' are formed by an entry of blood from the lumen of the vessel. Examination of the ruptured zone of intimal collagen by serial section disclosed that 'plaque haemorrhage' in the proximal part of a diseased coronary artery was mild and localised principally near its lumen; distally it was larger and occupied most of the plaque.

Fig. 6A and B depict a segment of a coronary artery within 3 cm of the ostium, in which the intima would probably have ruptured in the near future. In this section, no endothelial cells are found and intimal collagen fibres have become thin and irregular. Many foam cells are present near the lumen. Infiltration of blood into the plaque is also to be seen.

In our study the location of most ruptured atheromatous plaques seemed to be restricted to the first 3 cm of the left coronary artery. In addition, this site showed both the highest incidence of

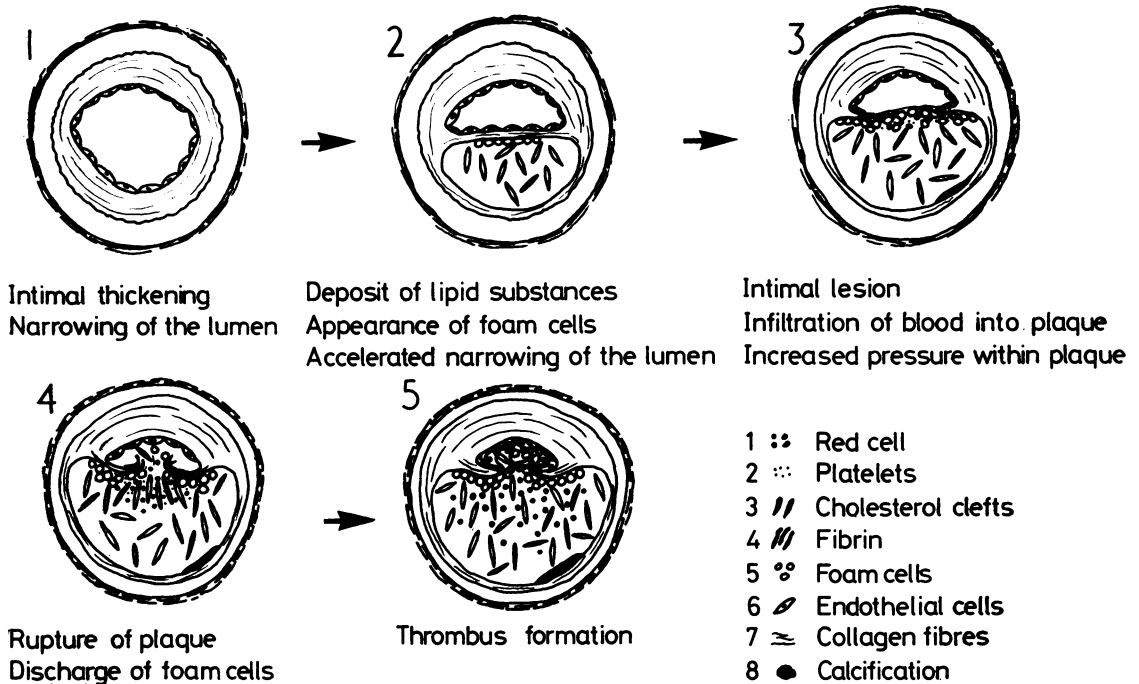


Fig. 7 Pathogenesis of coronary thrombosis.

occlusive lesions (as also reported by Montenegro and Eggen, 1968) and of coronary thrombi. Furthermore, the most severe coronary stenoses were found here in most of the cases we examined.

Fig. 7 sets out a suggested course of events in the pathogenesis of coronary thrombosis in acute myocardial infarction. The narrowing of the lumen caused by the intimal thickening increases with age and is accelerated by the deposition of lipid substances from the blood and the gradual appearance and accumulation of cholesterol crystals and foam cells. The intimal collagen fibres nearest the lumen become thin and irregular. Constituents of the blood then infiltrate into the atheromatous plaque through the injured endothelial barrier. This, together with the honeycomb-like accumulation of foam cells and cholesterol clefts, increases the intraplaque pressure, causing rupture of the atheromatous plaque. When this mechanical fracture has occurred, platelets are exposed and attached to the collagen. Once absorbed onto the collagen, the platelets swell and release the nucleotide, adenosine diphosphate, which has the property of causing further platelet adherence (Hovig, 1963; Johnson, 1965; Deykin, 1967). When the endothelial barrier is broken, tissue thromboplastin is also released

(Deykin, 1967). Thus, under the influence of yet another coagulation factor, fibrin is formed and an occluding thrombus gradually results.

We conclude that thrombus formation and the rupture of the atheromatous plaque are intimately connected, and speculate that fracture of the intimal collagen fibres between the lumen and the plaque may precede and be responsible for the formation of the thrombus and the onset of acute myocardial infarction. Clinically, this may account for preinfarction angina, the pain occurring at the time of the rupture of the atheromatous plaque. This view is supported by the following evidence from our study.

- (1) In 2 patients who died suddenly after a coronary attack, we found a ruptured atheromatous plaque, but no thrombus. As these patients showed severe stenosis with recanalisation in 2 of the 3 main coronary arteries, the rupture of the plaque caused significant occlusion of the remaining coronary artery (Horie *et al.*, 1978).
- (2) Fresh occluding thrombi had already been formed in 2 patients who died within 5 or 6 hours of the onset of acute myocardial infarction.



- (3) Coronary thrombi containing plaque components such as foam cells, cholesterol clefts, and fractured intimal collagen fibres, were detected (Horie *et al.*, 1977).
- (4) In 69 of 76 thrombosed segments (90.8%), direct communication between the thrombus and the atheromatous plaque was found.

The authors thank Professor Akira Kajita, for his advice in the course of this study, and the pathology staff for technical assistance.

#### References

- Arnett, E. N., and Roberts, W. C. (1976). Acute myocardial infarction and angiographically normal coronary arteries: an unproven combination. *Circulation*, **53**, 395-400.
- Baroldi, G. (1976). Coronary thrombosis: facts and beliefs. *American Heart Journal*, **91**, 683-688.
- Baroldi, G., Radice, F., Schmid, G., and Leone, A. (1974). Morphology of acute myocardial infarction in relation to coronary thrombosis. *American Heart Journal*, **87**, 65-75.
- Bouch, D. C., and Montgomery, G. L. (1970). Cardiac lesions in fatal cases of recent myocardial ischaemia from a coronary care unit. *British Heart Journal*, **32**, 795-803.
- Branwood, A. W., and Montgomery, G. L. (1956). Observations on the morbid anatomy of coronary artery disease. *Scottish Medical Journal*, **1**, 367-375.
- Brest, A. N., Wiener, L., Kasparian, H., Duca, P., and Rafter, J. J. (1974). Myocardial infarction without obstructive coronary artery disease. *American Heart Journal*, **88**, 219-224.
- Chapman, I. (1968). Relationship of recent coronary artery occlusion and acute myocardial infarction. *Journal of the Mount Sinai Hospital*, **35**, 149-154.
- Chapman, I. (1974). The cause-effect relationship between recent coronary artery occlusion and acute myocardial infarction. *American Heart Journal*, **87**, 267-271.
- Constantinides, P. (1966). Plaque fissures in human coronary thrombosis. *Journal of Atherosclerosis Research*, **6**, 1-17.
- Crawford, T. (1961). Morphological aspects in the pathogenesis of atherosclerosis. *Journal of Atherosclerosis Research*, **1**, 3-25.
- Deykin, D. (1967). Thrombogenesis. *New England Journal of Medicine*, **276**, 622-628.
- Ehrlich, J. C., and Shinohara, Y. (1964). Low incidence of coronary thrombosis in myocardial infarction: a restudy by serial block technique. *Archives of Pathology*, **78**, 432-445.
- Eliot, R. S., Baroldi, G., and Leone, A. (1974). Necropsy studies in myocardial infarction with minimal or no coronary luminal reduction due to atherosclerosis. *Circulation*, **49**, 1127-1131.
- Friedman, M. (1969). *Pathogenesis of Coronary Artery Disease*. McGraw-Hill, New York.
- Friedman, M., and Van den Bovenkamp, G. J. (1966). The pathogenesis of coronary thrombus. *American Journal of Pathology*, **48**, 19-44.
- Hashimoto, M., Ishihara, M., and Ueda, I. (1969). Pathology of the heart in cases of myocardial infarction and coronary atherosclerosis. (In Japanese.) *Japanese Journal of Clinical and Experimental Medicine*, **46**, 2676-2687.
- Horie, T., Sekiguchi, M., and Hirotsawa, K. (1977). Relationship between acute myocardial infarction and coronary thrombosis. (In Japanese.) *Respiration and Circulation*, **25**, 681-689.
- Horie, T., Sekiguchi, M., and Hirotsawa, K. (1978). Relationship between myocardial infarction and preinfarction angina: a histopathological study of coronary arteries in two sudden death cases employing serial section. *American Heart Journal*, **95**, 81-88.
- Hovig, T. (1963). Release of a platelet-aggregating substance (adenosine diphosphate) from rabbit blood platelets induced by saline extract of tendon. *Thrombosis et Diathesis Haemorrhagica*, **9**, 264-278.
- Johnson, A. J. (1965). Recent advances in experimental thrombogenesis. *Federation Proceedings*, **24**, 827-834.
- Khan, A. H., and Haywood, L. J. (1974). Myocardial infarction in nine patients with radiographically patent coronary arteries. *New England Journal of Medicine*, **291**, 427-431.
- Mallory, G. K., White, P. D., and Salcedo-Salgar, J. (1939). Speed of healing of myocardial infarction: a study of pathologic anatomy in 72 cases. *American Heart Journal*, **18**, 647-671.
- Montenegro, M. R., and Eggen, D. A. (1968). Topography of atherosclerosis in the coronary arteries. *Laboratory Investigation*, **18**, 586-593.
- Montgomery, G. L. (1959). Problems in the pathology of coronary artery disease. *Lectures on the Scientific Basis of Medicine*, **7**, 162-181.
- Otsu, S. (1970). A statistical study on myocardial infarction and coronary sclerosis in autopsy materials in Japan. *Acta Pathologica Japonica*, **20**, 1-35.
- Paterson, J. C. (1936). Vascularization and hemorrhage of the intima of arteriosclerotic coronary arteries. *Archives of Pathology*, **22**, 313-324.
- Paterson, J. C. (1938). Capillary rupture with intimal hemorrhage as a causative factor in coronary thrombosis. *Archives of Pathology*, **25**, 474-487.
- Roberts, W. C., and Buja, L. M. (1972). The frequency and significance of coronary arterial thrombi and other observations in fatal acute myocardial infarction: a study of 107 necropsy patients. *American Journal of Medicine*, **52**, 425-443.
- Sinapius, D. (1972a). Beziehungen zwischen Koronarthrombosen und Myokardinfarkten. *Deutsche medizinische Wochenschrift*, **97**, 443-448.
- Sinapius, D. (1972b). Zur Morphologie verschliessender Koronarthromben. *Deutsche medizinische Wochenschrift*, **97**, 544-551.
- Spain, D. M., and Bradess, V. A. (1960). The relationship of coronary thrombosis to atherosclerosis and ischemic heart disease: a necropsy study covering a period of 25 years. *American Journal of the Medical Sciences*, **240**, 701-710.
- Spain, D. M., Chandler, A. B., Chapman, I., Erhardt, L. R., Roberts, W. C., Schwartz, C. J., Sinapius, D., Sherry, S., Ness, P. N., and Simon, T. L. (1974). Coronary thrombosis in myocardial infarction: report of a workshop on the role of coronary thrombosis in the pathogenesis of acute myocardial infarction. *American Journal of Cardiology*, **34**, 823-833.
- Yajima, G. (1959). *New Silver Impregnation: New Method of Histological Study*, pp. 132-136. (In Japanese.) Ishiyaku, Tokyo.

Requests for reprints to Dr Toshinobu Horie, Department of Cardiology, Heart Institute Japan, Tokyo Women's Medical College, 10 Kawada-cho, Shinjuku-ku, Tokyo, Japan.