

Atrio-His bundle tracts

Claude Brechenmacher¹

From the Cardiac Histology Laboratory, Boucicaut Hospital, Paris; and the Cardiac Histology Laboratory of the Medical A. Clinic, Strasbourg, France

The atrio-His bundle tracts are very rare; only two have been found in 687 hearts studied histologically. These tracts have a similar appearance to those of the atrioventricular bundle and form a complete bypass of the atrioventricular node. In their presence the electrocardiogram may show a short or normal PR interval. They may be responsible for some cases of very rapid ventricular response to supraventricular arrhythmias.

The atrial tracts, which skirt the right convex aspect of the atrioventricular node and extend down to the entrance of the tricuspid valve, are present in all normal hearts; they have intrigued histologists for almost 100 years (Paladino, 1876). Kistin (1949) observed that in one heart, part of these tracts of Paladino penetrated the right lateral border of the atrioventricular node, but it was James (1961) who noted their existence in all hearts. Since they penetrate the right lateral surface of the atrioventricular node, occasionally low down, they may be considered to constitute a bypass of its upper part, i.e. an incomplete bypass of the atrioventricular node. As seen in one of his diagrams, but not in the text, James (1961) thought that the atrial tracts could sometimes likewise penetrate the atrioventricular bundle.

Subjects and methods

Six hundred and eighty-seven hearts were studied by the histological technique of Lenègre and Chevalier (1951). These hearts principally came from patients with heart disease, most of whom had ventricular conduction disturbances as well. From a single block sections were made in the frontal plane through the interatrial and interventricular septum; these were 8 μ thick, cut from behind forwards and stained with a haematoxylin-eosin-safran. Initially 1 section out of 20 was examined, though in areas of interest, 1 of 10 or of 5, or if appropriate, every single section was scrutinized.

Results

Of all the hearts studied, atrio-His bundle tracts were found in only two. The first case has been

reported in detail elsewhere (Brechenmacher *et al.*, 1974). In this case the tracts originate in the interatrial septum and descend vertically, skirting the right lateral surface of the atrioventricular node, to penetrate the first part of the atrioventricular bundle at the point where the tracts of the latter were already parallel and where the atrioventricular bundle was beginning to penetrate the central fibrous body.

In the second case, not previously published, the atrio-His bundle tracts likewise descend vertically from the interatrial septum and skirt the right lateral surface of the atrioventricular node. Unlike the preceding case, the atrio-His bundle tracts penetrate the lower part of the atrioventricular bundle at the site of its branching. The cells which form these tracts are long, rectangular, and have the same appearance as those of the atrioventricular bundle (Fig. 1), but are, however, approximately perpendicular to it. Its distribution is indicated diagrammatically in Fig. 2.

Discussion

It is interesting to compare the histological findings with the electrocardiographic appearances. In the first case (Brechenmacher *et al.*, 1974) the PR interval was rather short (0.12 s) and the QRS complex was narrow (0.08 s) (Clerc, Levy, and Cristesco, 1938); the patient died from supraventricular tachycardia with rapid ventricular response. The present patient had also suffered from paroxysmal tachycardia. In this case the electrocardiogram showed a longer PR interval (0.16 s) and incomplete left bundle-branch block with a QRS duration of 0.12 s and a QRS axis of -10° ; a subsequent recording showed transient lengthening of the PR interval to 0.22 s. This patient died suddenly 4

Received 10 October 1974.

¹Present address: Service de Cardiologie (R. Voegtlin), Centre Hospitalier Régional, 67000 Strasbourg, France.

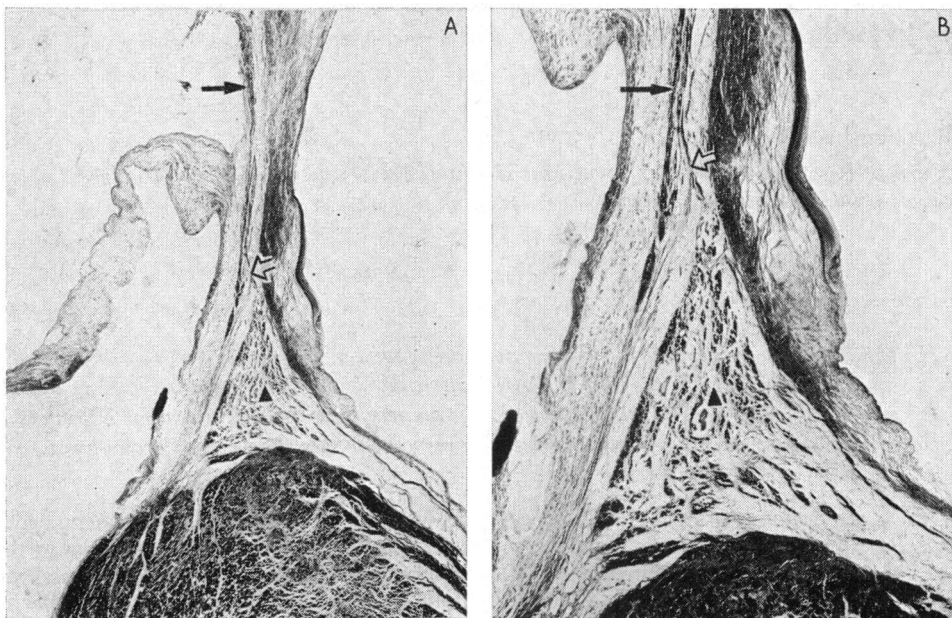


FIG. 1 A) Frontal plane section through the septum. At the top is the interatrial septum, and below is the interventricular septum. The tricuspid valve is seen extending to the left of the photomicrograph. The solid arrow indicates the atrio-His bundle tracts descending from the atrium and approaching the His bundle. The open arrow indicates some tracts entering the His bundle. The triangle indicates the branching part of the His bundle. At the lower right are some tracts of the left bundle-branch which originate from the His bundle. (Haematoxylin-eosin-safran. $\times 10.5$.) B) A higher magnification of the same section. The signs indicate the same structures as in A. ($\times 23$.)

days later at the age of 63, probably as a result of aortic stenosis. In this instance, histological examination showed considerable fibrosis in the anterior and posterior parts of the left bundle-branch and to a lesser extent in the lower part of the right bundle-branch.

This correlation of histology with the electrocardiogram shows that, when atrio-His bundle tracts are present, a short PR interval may be recorded on the electrocardiogram but that a normal or long PR interval may also occur. In this second case two hypotheses may be formulated. Either 1) the A-H fibres were not functional: supporting this hypothesis is our observation that distinctly fewer A-H fibres were present in this case than in the case with the short PR interval; or 2) possibly a short PH interval was compensated by a

long HV interval: this explanation is suggested by the presence of lesions at the level of the two bundle-branches. Only with a recording of His bundle activity would it have been possible to distinguish between the two hypotheses.

Unlike atrionodal tracts, which exist in all hearts and which have already been described (James, 1961), atrio-His bundle tracts are very rare; we have only found 2 examples in 687 hearts that we have studied. These tracts have the same histological appearances as those of the atrioventricular bundle; as in this latter case, conduction may be rapid. Whereas the atrionodal tracts described by James form a *partial* bypass of the atrioventricular node, the atrio-His bundle tracts described here form a *complete* bypass. This probably explains why rapid atrial arrhythmias can be

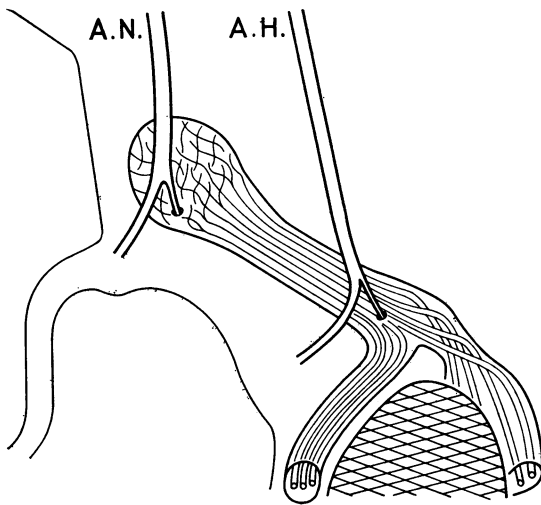


FIG. 2 A schematic drawing of the atrioventricular node, His bundle, and bundle-branches. The atrioventricular node is shown to be composed of interwoven cells while the fibres of the His bundle are parallel. The ventricular myocardium is represented by cross-hatching. A.N. indicates the atrionodal tracts described by James (1961). Some of them enter the atrioventricular node, and in some cases its lower part. Most of these tracts approach the insertion of the tricuspid valve, shown at the left of the drawing. A.H. indicates the atrio-His bundle tracts described in the text. Some of these tracts enter the His bundle.

transmitted to the ventricles by these atrio-His bundle tracts, as happened in the first patient, causing death.

We acknowledge the help of Dr. Dennis Krikler, of Dr. Jean Laham, and of Dr. Noël Paraiso.

References

- Brechenmacher, C., Laham, J., Iris, L., Gerbeaux, A., and Lenègre, J. (1974). Étude histologique des voies anormales de conduction dans un syndrome de Wolff-Parkinson-White et dans un syndrome de Lown-Ganong-Levine. *Archives des Maladies du Coeur et des Vaisseaux*, **67**, 507.
- Clerc, A., Levy, R., and Cristesco, C. (1938). A propos du raccourcissement permanent de l'espace PR de l'électrocardiogramme sans déformation du complexe ventriculaire. *Archives des Maladies du Coeur et des Vaisseaux*, **31**, 569.
- James, T. N. (1961). Morphology of the human atrioventricular node, with remarks pertinent to its electrophysiology. *American Heart Journal*, **62**, 756.
- Kistin, A. D. (1949). Observations on the anatomy of the question of atrioventricular bundle (bundle of His) and the question of other muscular atrioventricular connections in normal human hearts. *American Heart Journal*, **37**, 849.
- Lenègre, J., and Chevalier, H. (1951). Note technique préliminaire concernant l'étude histologique de la cloison du coeur. *Archives des Maladies du Coeur et des Vaisseaux*, **44**, 512.
- Paladino, G. (1876). Contribuzione all' anatomia, istologia e fisiologia del cuore. *Movimento, Napoli*, **8**, 428.

Requests for reprints to Dr. Claude Brechenmacher, Service de Cardiologie, Centre Hospitalier Régional, 67000 Strasbourg, France.