

# Coarctation of aorta with right aortic arch

## *Report of surgical correction in 2 cases: one with associated anomalous origin of left circumflex coronary artery from the right pulmonary artery*

M. Honey, J. C. R. Lincoln, M. P. Osborne,<sup>1</sup> and D. P. de Bono<sup>2</sup>  
*From the Departments of Cardiology and Surgery, Brompton Hospital, London*

*Two patients with right aortic arch, anomalous left subclavian artery, and coarctation of the aorta, have had operations for the relief of coarctation, successful in one but only partially successful in the other: in one case, a 'dacron' patch was inserted into the narrowed segment, but a mild recurrence of coarctation was found a year later; in the other, the proximal segment of the anomalous left subclavian artery was used for the repair, with complete relief of the coarctation, both immediately and at late follow-up.*

*The first case had multiple associated congenital abnormalities, including anomalous origin of the left circumflex coronary artery from the right pulmonary artery, which was also corrected surgically: this anomaly has only been recorded once hitherto. The second had facial haemangiomas and a small ventricular septal defect.*

*Four previously reported cases of coarctation and right arch are reviewed. These 6 cases are considered in the light of current views on the development and classification of aortic arch anomalies.*

The occurrence of coarctation in patients with right aortic arch is extremely rare: hitherto only 4 cases have been recorded. We have seen 2 further cases; in both of these, an attempt was made to correct the coarctation surgically.

### Case reports

#### Case 1

A 13-year-old Arab boy from Libya was referred for treatment of coarctation of the aorta. He complained of fatigue and effort dyspnoea but his disability was slight. There was no dysphagia or stridor.

On examination, he was undersized. There was no cyanosis or clubbing. The left arm pulses were reduced; the blood pressure in the right arm was 190/130 mmHg (25.3/17.3 kPa) and in the left arm 110/70 mmHg (14.6/9.3 kPa). The carotid pulses were forceful and equal; both femoral pulses were grossly reduced and delayed. The cardiac impulse suggested left ventricular hypertrophy; there was a basal ejection systolic murmur

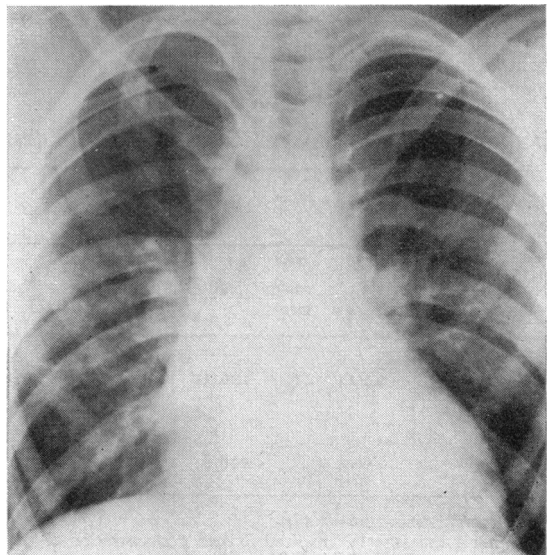


FIG. 1 Case 1. Chest x-ray.

Received 7 April 1975.

<sup>1</sup>Present address: Hemel Hempstead General Hospital, Herts.

<sup>2</sup>Present address: Addenbrooke's Hospital, Cambridge.

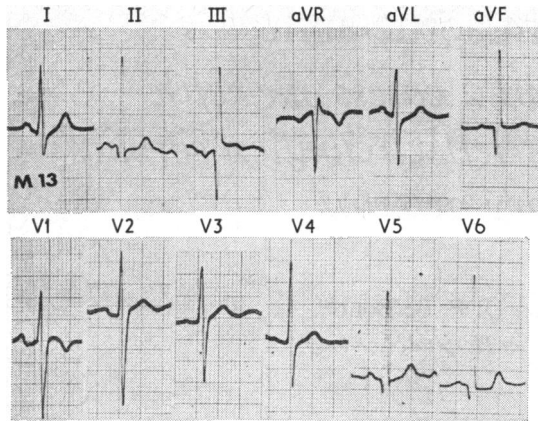


FIG. 2 Case 1. *Electrocardiogram.*

(grade 2–3/6) but no diastolic or continuous murmur; the heart sounds were normal and there was no ejection sound. A systolic murmur was also heard between the scapulae.

The *chest radiograph* (Fig. 1) showed slight cardiac enlargement, absence of the aortic knuckle, and possible pulmonary plethora. There were congenital abnormalities of the right ribs, with fusion of the posterior ends of the 3rd and 4th and of the 7th and 8th ribs, and there was a 'butterfly' deformity of the 12th dorsal vertebra. There was no rib notching on either side. The *electrocardiogram* (Fig. 2) showed a variable frontal plane P wave axis ( $+10^\circ$  and  $-35^\circ$  on different occasions); there was left ventricular hypertrophy by voltage criteria but no ST or T wave abnormality; prominent Q waves were seen in leads III and aVF. Routine urinalysis was normal; blood urea was 6.1 mmol/l (37 mg/100 ml), and serum creatinine 61.9  $\mu\text{mol/l}$  (0.7 mg/100 ml).

Intravenous pyelogram showed a normal left kidney, and no excretion on the right side. Chromosome studies gave normal results.

**Cardiac catheterization** (Table 1) Right heart pressures were normal, but there was a small left-to-right shunt at pulmonary artery level (flow ratio 1.2:1). An arterial catheter introduced from the right brachial artery entered the aortic arch and passed downwards through the coarctation, but was then manoeuvred into the ascending aorta and left ventricle. A second arterial catheter, introduced by right femoral arteriotomy, entered the left subclavian artery from below.

**Angiocardiography** (Fig. 3) *Arch aortogram.* Injection into the ascending aorta showed a right-sided aortic arch and descending aorta. The left common carotid artery, right common carotid artery, and right subclavian artery arose in turn from the arch; there was a moderately severe coarctation 2 cm in length just distal to the origin of the right subclavian artery (Fig. 3a). There was a very large and tortuous left main and anterior descending coronary artery, with later opacification of a vessel entering the pulmonary artery (Fig. 3b). Late films showed retrograde filling of the left subclavian artery from the left vertebral artery and thyrocervical trunk (Fig. 3c). The aortogram also showed a bicuspid aortic valve with minimal aortic regurgitation.

*Selective coronary arteriograms* showed a small but normal right coronary artery. The left coronary artery gave rise to a large anterior descending artery with diagonal and septal branches, anastomosing with distal circumflex branches; there was then retrograde filling of the main trunk of the circumflex artery, and puffs of contrast were seen to enter the posterior aspect of the right pulmonary artery.

*Abdominal aortogram* showed a normal left renal artery supplying a normal but large left kidney. No right renal artery was seen.

TABLE 1 *Preoperative cardiac catheterization data*

Case No., age, and sex	Pressures (mmHg)*				Oxygen saturation (per cent)							Flows l/min per m <sup>2</sup> BSA			
	RA mean	PA s/d	PA wedge mean	LV s/d	Asc. aorta s/d	Desc. aorta s/d	R. subcl. vein	SVC	RA	RV	PA	Aorta	Sys- temic ( $\dot{Q}_S$ )	Pul- monary ( $\dot{Q}_P$ )	$\dot{Q}_P/\dot{Q}_S$
Case 1															
13 yr M	3	24/14	11	176/12	180/100	120/95		64	67	66	71	97	3.2	3.8	1.2
Case 2†															
1 yr															
10 mth															
M	2	25/13		106/8	106/54		92	81	77	84	84	98	6.2	9.2	1.5

\* Reference zero: mid-thorax.

† General anaesthesia. Inspired oxygen concentration 25 per cent.

Abbreviations: RA, right atrium; PA, pulmonary artery; LV, left ventricle; RV, right ventricle; SVC, superior vena cava; s, d, ed, systolic, diastolic, end-diastolic.

Conversion factor from Traditional Units to SI units: 1 mmHg  $\approx$  0.133 kPa.

**Preoperative diagnosis** Coarctation of aorta with right aortic arch. Anomalous origin of left subclavian artery from descending aorta; mirror-image arrangement of other brachiocephalic trunks. Anomalous origin of left circumflex coronary artery from right pulmonary artery. Bicuspid aortic valve. Congenital absence of right kidney. Congenital deformities of right ribs and of the 12th dorsal vertebra.

**Operation** (1 May 1973) The chest was opened by a left lateral thoracotomy. The oesophagus was situated to the left of the descending aorta; there was post-stenotic dilatation of the aorta, from which arose the left subclavian artery; a left-sided ligamentum arteriosum connected the descending aorta to the left pulmonary artery. Retraction of the oesophagus revealed the coarcted segment 3 cm in length between the origins of the right and left subclavian arteries. This was exposed, and after cross-clamping the aorta proximally and distally, the coarcted segment was opened longitudinally. An onlay patch of woven 'dacron' was sewn on to the opened segment (Fig. 4A). Resection and end-to-end anastomosis was not feasible because the proximal limit of the coarctation lay in the right side of the mediastinum. The ligamentum was divided. A left superior vena cava was also noted.

**Postoperative course** Systemic hypertension required treatment initially with trimetaphan camsylate (Arfonad) infusion and intermittent intravenous chlorpromazine, and later with oral methyldopa. After the repair procedure the left leg pulses were normal, but in the right leg no pulse was palpable below the femoral. This was attributed to thrombosis at the site of preoperative femoral arteriotomy. After exploration and thrombectomy, an arterial catheter was passed retrogradely across the previously coarcted segment; no gradient was demonstrated and angiography confirmed successful relief of coarctation; a small false aneurysm was seen at the distal end of the repair (Fig. 3d). Subsequently all lower limb pulses were normal. Blood pressure averaged 140/90 mmHg (18.6/12.0 kPa).

He remained well, but was readmitted a year later for correction of the coronary artery anomaly. He was found to have signs of recurrence of coarctation. The femoral pulses were reduced and delayed. The right arm blood pressure was 170/100 mmHg (22.6/13.3 kPa), but in the left arm the pulses were reduced and blood pressure was 100/80 mmHg (13.3/10.6 kPa).

**Arch aortogram** (Fig. 3e) confirmed that there was now significant narrowing at the site of the repair. This was associated with a gradient of 45 mmHg (6.0 kPa) between the arch and descending aorta.

It was not thought feasible to repeat the onlay graft procedure; correction by insertion of a tube graft from ascending to descending aorta was considered as an alternative method of treatment, but this further extensive surgery was thought to be unjustified.

**Second operation** (5 July 1974) The heart was exposed through a median sternotomy. The anterior descending coronary artery was tortuous, but the circumflex artery was inaccessible. On routine cardiopulmonary

bypass, the pulmonary trunk was opened in its long axis, and the orifice of the anomalous circumflex coronary artery was seen in the posterior wall of the first centimetre of the right pulmonary artery. This opening was closed by direct suture.

**Postoperative course** He made an uninterrupted recovery. The signs of coarctation remain. Electrocardiogram 5 days after operation showed slight pericardial ST elevation but no change in QRS pattern. Later tracings showed widespread postoperative T wave inversion, but these changes had disappeared completely within 3 months.

## Case 2

An English boy aged 22 months was found to have a cardiac murmur on routine medical examination in infancy. His growth and development were normal, and there were no symptoms; there was no dysphagia or dyspnoea.

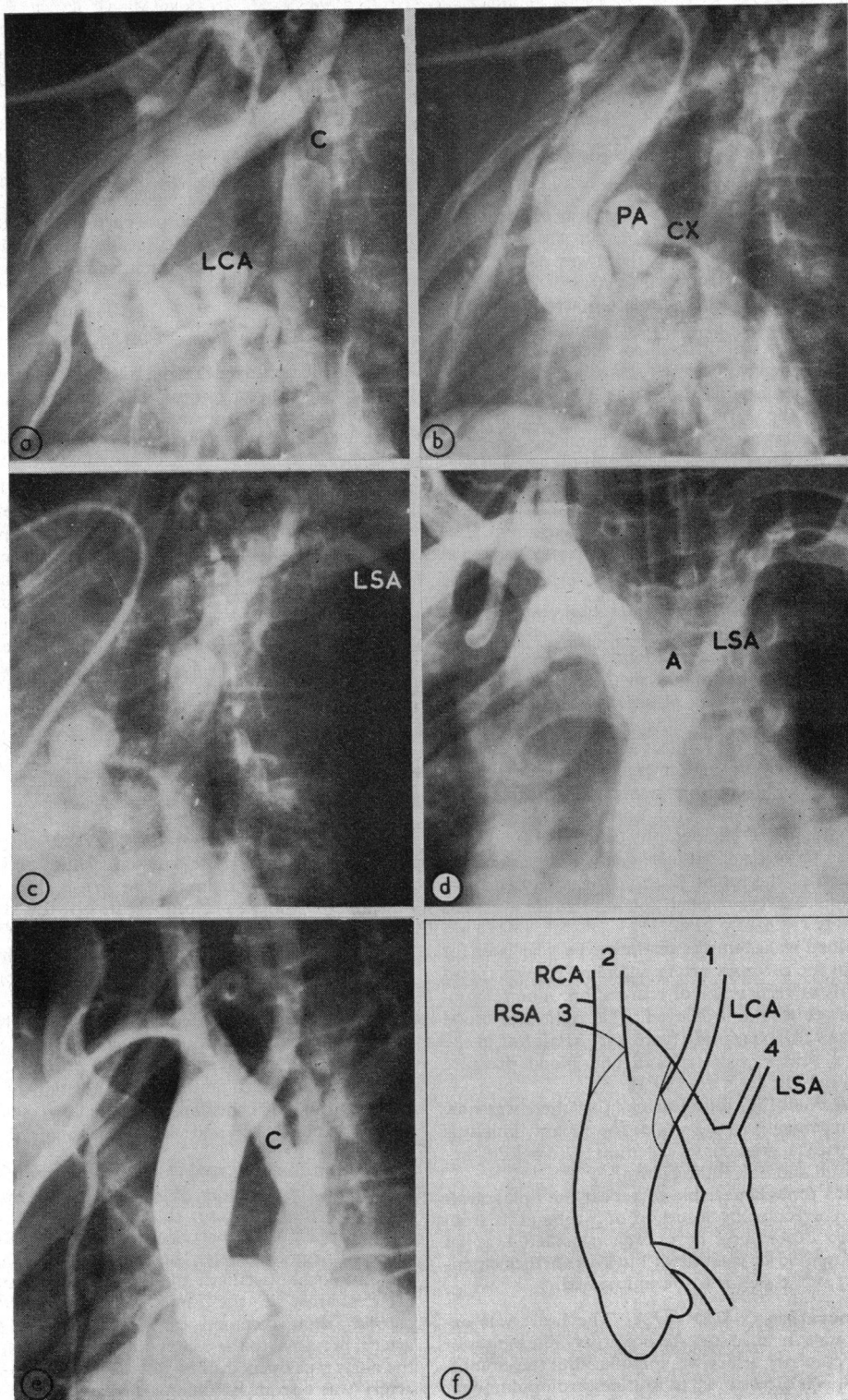
On examination he appeared healthy, and height and weight were normal for age. He had a large haemangioma on the right cheek and right side of the neck, and smaller ones on the lips and chin. The left arm pulses were reduced; the blood pressure was 160 mmHg (21.3 kPa) in the right arm and 80 mmHg (10.6 kPa) in the left arm by the Doppler shift method (Elseed, Shinebourne, and Joseph, 1973). The femoral pulses were weak and delayed. The heart was not enlarged; there was a pansystolic murmur (grade 4/6) at the left border of the sternum.

The chest radiograph showed moderate cardiac enlargement and pulmonary plethora; the main pulmonary trunk was prominent and the aortic knuckle invisible. The electrocardiogram was normal for age.

**Cardiac catheterization** (Table 1) Right heart pressures were normal. A left-to-right shunt at ventricular level was shown, with flow ratio 1.5:1. A right subclavian vein sample was 92 per cent saturated; this finding was attributed to the large haemangioma. An arterial catheter was passed retrogradely from the right brachial artery to the aortic arch and left ventricle, but the coarctation was not traversed.

**Left ventricular cineangiogram** in the left anterior oblique position showed a small infracristal ventricular septal defect and a short coarctation proximal to the left subclavian artery. The abnormal position of the aorta and origin of the other brachiocephalic vessels were not clearly demonstrated and were not recognized.

**Operation** (20 July 1973) The chest was opened by a left lateral thoracotomy. The anatomical findings were similar to the first case: there was a right aortic arch with aberrant left subclavian artery arising distal to the coarcted segment; a left ligamentum arteriosum completed a loose vascular ring. The other brachiocephalic arteries arose in the same order, viz. left common carotid, right common carotid, and right subclavian artery, proximal to the coarctation. After cross-clamping, the aorta was opened in its long axis; the left subclavian artery was also incised along its long axis and laid into



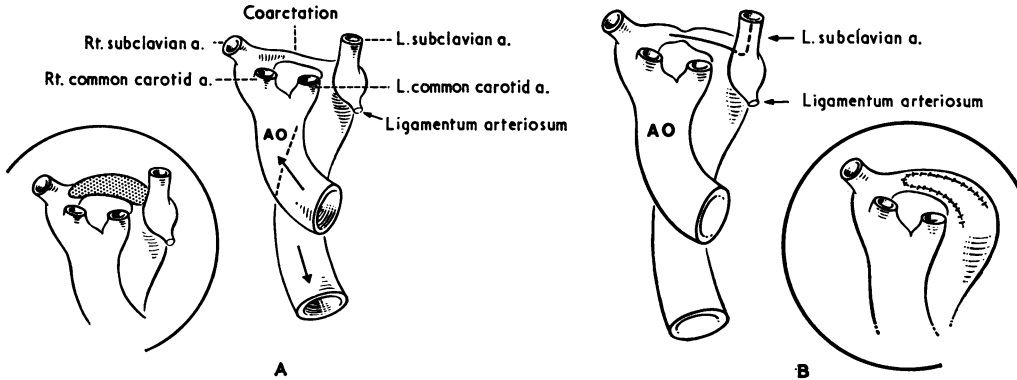


FIG. 4 A) Case 1: repair using 'dacron' patch; B) Case 2: repair using proximal segment of anomalous left subclavian artery.

the coarcted segment to achieve an angioplastic repair (Fig. 4B). The left subclavian artery was divided and ligated distally, as also was the ligamentum.

**Postoperative course** His postoperative progress was entirely uneventful.

He remains well one year after operation. The blood pressure in the right arm is 120/70 mmHg (16.0/9.3 kPa), and in the right leg 110/70 mmHg (14.6/9.3 kPa), but in the left arm 70 mmHg (10.6 kPa). The ventricular septal defect murmur is unchanged.

### Discussion

#### Right aortic arch: developmental considerations and classification

Stewart, Kincaid, and Edwards (1964) have proposed a classification of aortic arch anomalies. Their group III consists of patients with right aortic arch, and they subdivide this group according to the mode of origin of the brachiocephalic trunks. This may be the mirror-image of normal so that left innominate, right common carotid, and right subclavian arteries arise in turn from the aortic arch (Type IIIA); the left subclavian artery may be aberrant, arising from the descending aorta, with left common carotid, right common carotid, and right subclavian

arteries arising in turn from the arch (Type IIIB); finally, the left subclavian artery may have no direct origin from the aorta (Type IIIC). Each type of right aortic arch may be associated with a left-sided ductus (subgroup 1), a right-sided ductus (subgroup 2), or bilateral ductus (subgroup 3). Blake and Manion (1962) in an analysis of 41 cases classify aortic arch anomalies in relation to abnormal sites of involution of the primitive aortic arch system. Involution of the left and persistence of the right dorsal aortic root give rise to Type IIIA of Stewart *et al.* (1974) with mirror-image branching. Involution of the left fourth arch and persistence of the left and right dorsal aortic roots give rise to Type IIIB with anomalous origin of left subclavian artery. Involution of the left ventral aortic root gives rise to a situation not recognized by Stewart *et al.* (1964) in which there is anomalous origin of a left innominate artery from the descending aorta.

The primitive aortic arch system is illustrated digrammatically in Fig. 5A. The sites at which involution occurs to produce the observed patterns of branching in the normal subject and in patients with a right aortic arch are shown. The resulting postnatal right arch patterns are shown in Fig. 5C and D, with the normal for comparison in Fig. 5B.

FIG. 3 Case 1. Aortograms. a) Early preoperative aortogram shows coarctation (C) and dilated and tortuous left coronary artery (LCA); b) Later preoperative aortogram shows anomalous left circumflex artery (CX) entering pulmonary artery (PA); c) Later preoperative aortogram shows late opacification of anomalous left subclavian artery (LSA); d) Early postoperative aortogram shows relief of coarctation and false aneurysm (A), with early opacification of anomalous left subclavian artery (LSA); e) Late postoperative aortogram shows reduction in aortic lumen at site of coarctation repair (C); f) Line drawing of Fig. 3e illustrating successive origin of brachiocephalic trunks (LCA left carotid, RCA right carotid, RSA right subclavian, LSA left subclavian).

TABLE 2 Coarctation and right aortic arch: anatomical features and associated lesions in 6 cases

Authors	Age and sex	Type of right arch	Pattern of branching		Ductus or ligamentum (vascular ring + or -)	Upper descending aorta	Operation
			Proximal to coarctation	Distal to coarctation			
Felson and Palayew (1963)	Child	'Posterior'* Anomalous LCCA and LSA	R. innom. A	LCCA LSA	Not stated	Not stated	Yes (no details)
Stewart, Kincaid, and Edwards (1964)	16 yr M	Anomalous left subclavian artery (IIIB <sub>1</sub> )	LCCA, RCCA, RSA	LSA	Left ductus (+)	Unknown	Yes (‘difficult’; no details)
Grossman and Jacoby (1969)	14 yr F	Anomalous left subclavian artery (IIIB)	LCCA, RCCA, RSA	LSA	Unknown	Right	Not attempted
Price and Schieken (1974)	13 yr F	Mirror-image (IIIA)	L. innom. A, — RCCA, RSA†	—	Not stated	Right	Successful resection and end-to-end anastomosis
Case 1	13 yr M	Anomalous left subclavian artery (IIIB <sub>1</sub> )	LCCA, RCCA, RSA	LSA	Left ligamentum (+)	Right	Partially successful (onlay graft) repair
Case 2	1 yr 10 mth M	Anomalous left subclavian artery (IIIB <sub>1</sub> )	LCCA, RCCA, RSA	LSA	Left ligamentum (+)	Left	Successful repair (angioplastic)

\* Type of aortic arch abnormality not classifiable by the scheme of Stewart, *et al* (1964).

† Right subclavian artery arising at site of coarctation (case of Price and Schieken).

Abbreviations: LCCA, RCCA: left and right common carotid arteries; LSA, RSA: left and right subclavian arteries; SVC: superior vena cava.

The coexistence of a right arch and anomalous left subclavian artery passing behind the oesophagus with left-sided ductus or ligamentum results in the formation of a type of vascular ring, usually but not always a loose one (Stewart *et al.*, 1964; Lincoln *et al.*, 1969). It is noteworthy that in almost all cases, the mirror-image type of branching of a right arch is associated with cyanotic congenital heart disease, commonly Fallot's tetralogy or persistent truncus arteriosus; on the other hand, in group IIIB of Stewart *et al.* (1964), with right arch and aberrant left subclavian artery, intracardiac anomalies are unusual and coincidental.

#### Right aortic arch and coarctation

The association of right aortic arch with coarctation is very unusual. Four cases have been reported (Felson and Palayew, 1963; Stewart *et al.*, 1964; Grossman and Jacoby, 1969; Price and Schieken, 1974) in addition to the 2 described here (Table 2).

Our 2 cases, the case of Stewart *et al.* (1964), and that of Grossman and Jacoby (1969) appear to be

identical, in possessing right aortic arch, anomalous left subclavian artery arising from the descending aorta distal to the coarctation, and left common carotid, right common carotid, and right subclavian arteries arising in that order from the arch (Type IIIB). This situation is the mirror-image of coarctation of a normal left arch, with anomalous *right* subclavian artery. Grossman and Jacoby present their case as a 'unique anatomical variation', though it appears to differ in no way from the case of Stewart *et al.* (1964). In Felson and Palayew's case (1963) not only was the left subclavian artery aberrant but the left common carotid artery also arose distal to the coarctation: on embryological grounds one would expect these vessels to arise together as an aberrant left innominate artery (Blake and Manion, 1962), but this is neither stated nor denied. In the case reported by Price and Schieken (1974) the pattern of branching was the mirror-image of normal (Type IIIA) and was unusual in being unassociated with cyanotic congenital heart disease.

Associated lesions	
Cardiovascular	Other systems
None (?)	Not stated
Not stated (? none)	Not stated (? none)
None	None
Aortic valve stenosis (operation)	Turner's syndrome
Anomalous origin of left circumflex coronary artery (operation), bicuspid aortic valve, bilateral SVC	Absent right kidney, skeletal anomalies
Ventricular septal defect	Facial haemangiomas

A left ductus or ligamentum was recognized in 3 of the cases; this resulted in the formation of a loose asymptomatic vascular ring. In the other 3 cases, it was either unknown or not stated on which side the ductus or ligamentum was situated. In our Case 1 and in 2 others, the upper descending aorta is right-sided, but in Case 2, the right arch, having passed behind the oesophagus, continues as a left-sided descending aorta; as a result the appearance at left thoracotomy differed so that in Case 1 the descending aorta was concealed by the oesophagus whereas the converse was true in Case 2.

We cannot suggest any plausible mechanism to account for the site of coarctation in these cases. This is neither juxtaductal coarctation nor the isthmal narrowing not uncommonly seen in left-to-right shunt situations (Rudolph, Heymann, and Spitznas, 1972; Shinebourne and Elseed, 1974), but partial involution of the terminal segment of the primitive right dorsal aortic root, distal to the origin of the seventh dorsal intersegmental artery (which gives rise to the right subclavian artery). This has

resulted in the appearance of a coarcted segment distal to the origin of the right subclavian artery in all cases, and in 5 of the 6 cases proximal to an aberrant left subclavian artery (and left common carotid artery in the case of Felson and Palayew, 1963).

#### Associated lesions

In 1 case certainly and probably in 2 others there was no associated cardiovascular lesion. One who had Turner's syndrome with characteristic chromosomal abnormality had aortic valve stenosis of sufficient severity to require surgical relief (Price and Schieken, 1974). Our Case 1 has a bicuspid aortic valve, bilateral superior vena cava with variable P wave axis on the electrocardiogram, and an unusual congenital coronary arterial anomaly. He also has minor skeletal anomalies, and congenital absence of the right kidney. Our Case 2 has a small ventricular septal defect. None of the cases had any form of conotruncal abnormality.

#### Surgical treatment

Surgical correction of coarctation was clearly indicated in both our cases, in the second of whom the presence of a right arch was unsuspected before operation. Because of the difficult access to the proximal end of the coarcted segment of the posterior aortic arch, resection with end-to-end anastomosis was not technically feasible. In both cases, the coarcted segment was opened longitudinally and its internal diameter increased, in 1 case with a 'dacron' onlay graft, and in the other by using the proximal portion of the aberrant left subclavian artery for the same purpose. When Case 1 was re-examined a year after operation it was clear that coarctation had recurred and this was confirmed by pressure measurements and aortography; it was thought that any further attempt to correct the coarctation would be a difficult and hazardous procedure. In Case 2, normal femoral pulses and normal right arm and lower limb blood pressure 13 months after operation confirm the adequacy of the repair procedure.

Unfortunately no details of the operation are given in 2 of the other cases (Felson and Palayew, 1963; Stewart *et al.*, 1964), but in Price and Schieken's case (1974) resection and end-to-end anastomosis were successfully accomplished in a different anatomical situation. In the sixth case (Grossman and Jacoby, 1969), surgical repair was not attempted, as this was thought to pose technically insuperable problems.

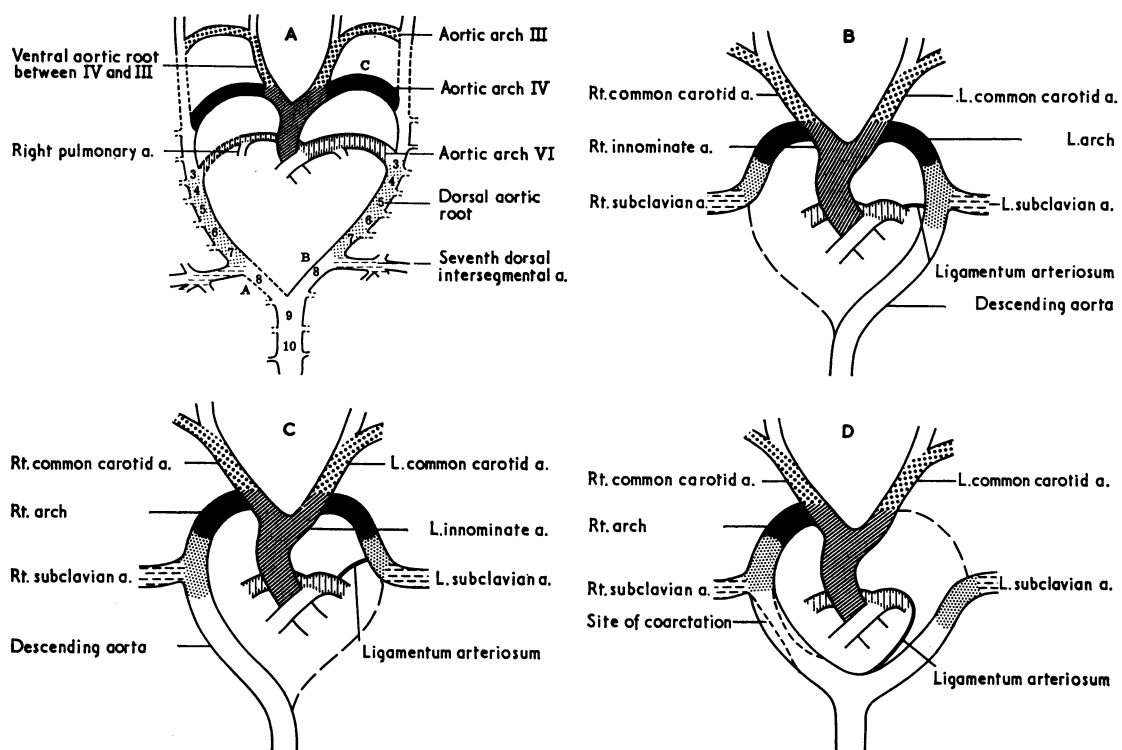


FIG. 5 A) Primitive aortic arch system. Involution at A (right dorsal aortic root) results in left aortic arch and normal origin of major branches. Involution at B results in right arch with 'mirror-image' branching pattern. Involution at C results in right arch with anomalous origin of left subclavian artery; hypoplasia at A produces coarctation between right and left subclavian arteries. B) Development of normal pattern. Differential growth produces a shift in relative positions of ductus (or ligamentum) and left subclavian artery. C) Development of right arch with successive origin of left innominate, right carotid, and right subclavian arteries. D) Development of right arch with anomalous left subclavian artery. Hypoplasia of dorsal aortic root distal to right seventh dorsal intersegmental artery (subclavian artery) results in coarctation at this site.

#### Anomalous origin of left circumflex coronary artery

We have been able to find only one published report of anomalous origin of the circumflex branch of the left coronary artery from the pulmonary artery, in a patient in whom the anterior descending artery arose from the right artery (Effler *et al.*, 1967: Case 7). In the Bland-Garland-White syndrome, the main left coronary artery arises from the pulmonary artery, and one artery (the right) arises from the aorta. This syndrome has been the subject of several reviews, but no reference is made to any other patient in whom the left anterior descending or circumflex artery alone arises from the pulmonary artery. The published reports on congenital coronary arterial fistula contain several cases in which

there is a fistula into the pulmonary artery or one of its main branches. It is presumed, but not always stated explicitly, that there are normal proximal right, left anterior descending, and circumflex arteries. Possibly cases of anomalous origin of the left circumflex coronary artery may have masqueraded as coronary fistulae terminating in the pulmonary artery.

Our Case 1 had a small but normal right coronary artery. The left coronary artery had no circumflex branch but continued in the anterior interventricular groove, giving rise to normally situated but large diagonal and septal branches, from which drainage occurred into the circumflex territory, and thence into a single large vessel entering the right pulmonary artery. This lesion constituted a low pres-



sure run-off from the coronary circuit and gave rise to a small but measurable left-to-right shunt. There was no clinical or electrocardiographic evidence of impaired myocardial perfusion, but it was thought rational to correct the anomaly either by dividing the anomalous circumflex artery or by reimplanting it into the aortic root. The anomalous vessel was closed from within the pulmonary artery and, as would be expected, this procedure was well tolerated. The case of Effler *et al.* (1967) was also treated by division of the anomalous circumflex artery at its pulmonary arterial end (D. B. Effler, 1974, personal communication).

### References

- Blake, H. A., and Manion, W. C. (1962). Thoracic arterial arch anomalies. *Circulation*, **26**, 251.
- Effler, D. B., Sheldon, W. C., Turner, J. J., and Groves, L. K. (1967). Coronary arteriovenous fistulae: diagnosis and surgical management. *Surgery*, **61**, 41.
- Elseed, A. M., Shinebourne, E. A., and Joseph, M. C. (1973). Assessment of techniques for measurement of blood pressure in infants and children. *Archives of Disease in Childhood*, **48**, 932.
- Felson, B., and Palayew, M. J. (1963). The two types of right aortic arch. *Radiology*, **81**, 745.
- Grossman, M., and Jacoby, W. J. (1969). Right aortic arch and coarctation of the aorta. *Diseases of the Chest*, **56**, 158.
- Lincoln, J. C. R., Deverall, P. B., Stark, J., Aberdeen, E., and Waterston, D. J. (1969). Vascular anomalies compressing the oesophagus and trachea. *Thorax*, **24**, 295.
- Price, H. L., and Schieken, R. M. (1974). Right aortic arch with coarctation of the aorta. *Chest*, **65**, 110.
- Rudolph, A. M., Heymann, M. A., and Spitznas, U. (1972). Hemodynamic considerations in the development of narrowing of the aorta. *American Journal of Cardiology*, **30**, 514.
- Shinebourne, E. A., and Elseed, A. M. (1974). Relation between fetal flow patterns, coarctation of the aorta, and pulmonary blood flow. *British Heart Journal*, **36**, 492.
- Stewart, J. R., Kincaid, O. W., and Edwards, J. E. (1964). *An Atlas of Vascular Rings and Related Malformations of the Aortic Arch System*. Charles C. Thomas, Springfield, Illinois.

Requests for reprints to Dr. Michael Honey, Brompton Hospital, Fulham Road, London SW3 6HP.