

Verapamil inhibits scar formation after peripheral nerve repair *in vivo*

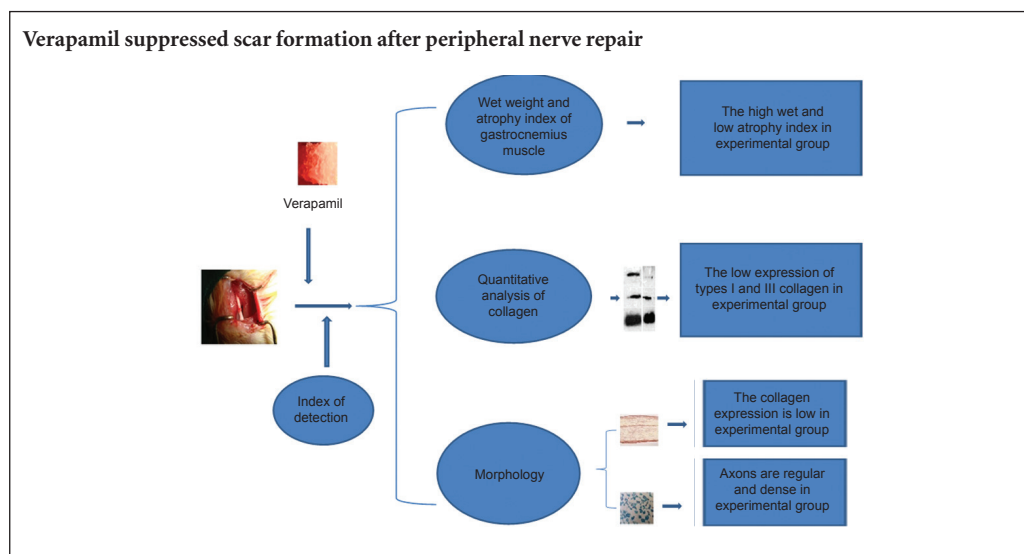
A-chao Han¹, Jing-xiu Deng², Qi-shun Huang^{1,*}, Huai-yuan Zheng¹, Pan Zhou¹, Zhi-wei Liu¹, Zhen-bing Chen¹

¹ Department of Hand Surgery, Union Hospital, Tongji Medical College, Huazhong University of Science and Technology, Wuhan, Hubei Province, China
² 457 Hospital of PLA, Wuhan, Hubei Province, China

How to cite this article: Han AC, Deng JX, Huang QS, Zheng HY, Zhou P, Liu ZW, Chen ZB (2016) Verapamil inhibits scar formation after peripheral nerve repair *in vivo*. *Neural Regen Res* 11(3):508-511.

Funding: This research was supported by the Natural Science Foundation of Hubei Province of China, No. 2011CDB392.

Graphical Abstract



*Correspondence to:
Qi-shun Huang, M.D.,
hqswh@hotmail.com.

orcid:
0000-0003-2429-4894
(Qi-shun Huang)

doi: 10.4103/1673-5374.179075
<http://www.nrronline.org/>

Accepted: 2015-11-18

Abstract

The calcium channel blocker, verapamil, has been shown to reduce scar formation by inhibiting fibroblast adhesion and proliferation *in vitro*. It was not clear whether topical application of verapamil after surgical repair of the nerve *in vivo* could inhibit the formation of excessive scar tissue. In this study, the right sciatic nerve of adult Sprague-Dawley rats was transected and sutured with No. 10-0 suture. The stoma was wrapped with gelfoam soaked with verapamil solution for 4 weeks. Compared with the control group (stoma wrapped with gelfoam soaked with physiological saline), the verapamil application inhibited the secretion of extracellular matrix from fibroblasts *in vivo*, suppressed type I and III collagen secretion and increased the total number of axons and the number of myelinated axons. These findings suggest that verapamil could reduce the formation of scar tissue and promote axon growth after peripheral nerve repair.

Key Words: nerve regeneration; nerve injury; verapamil; scar; sciatic nerve; type I collagen; type III collagen; neural regeneration

Introduction

During peripheral nerve repair, fibroblasts proliferate and release extracellular matrix, mainly as collagen, which forms scar tissue at the injury site. Excessive scar tissue at the cut ends of axons hinders axonal regeneration, affects peripheral nerve regeneration and nerve conduction (Ngeow, 2010). Several studies have confirmed that inhibiting the inflammatory reaction and fibroblast proliferation could noticeably suppress scar growth surrounding the site of injury (de Luca et al., 2014; Gong et al., 2014; Grinsell and Keating, 2014).

The calcium channel blocker, verapamil, has been shown

to inhibit *in vitro* cultured fibroblast adhesion and proliferation (Lundborg, 2000), contribute to extracellular matrix degradation and reduce scar formation (Terenghi et al., 2011). Whether topical application of verapamil after nerve repair *in vivo* could inhibit the formation of excessive scar tissue and promote nerve regeneration remains unclear. Thus, we sought to verify the inhibitory effect of verapamil on scar formation after peripheral nerve repair in *in vivo* tests.

Materials and Methods

Ethical approval

The experiments were approved by the Animal Ethics Com-

mittee of Huazhong University of Science and Technology of China. The animal studies were performed in accordance with the National Institutes of Health Guide for the Care and Use of Laboratory Animals. Precautions were taken to minimize suffering and the number of animals used in each experiment.

Animals

Sixty specific-pathogen-free male Sprague-Dawley rats aged 3–5 months and weighing 180–200 g were provided by the Experimental Animal Center, Tongji Medical College, Huazhong University of Science and Technology of China [animal license No. SCXK (E) 2008-0004]. All rats were housed at 18–25°C and at a relative humidity of 50%. The rats were equally and randomly assigned to experimental and control groups.

Sciatic nerve injury and treatment with verapamil

The rats were intraperitoneally anesthetized with 1% sodium pentobarbital (50 mg/kg). The four limbs were fixed in the prone position. After shaving, a longitudinal incision was made on the dorsal side of the right lower limb to expose the biceps femoris. The biceps femoris was bluntly dissociated to expose the sciatic nerve. The superior segment

of the sciatic nerve was transected, and then an epineurial neurorrhaphy was carried out with No. 10-0 Prolene suture. The stoma was wrapped with gelfoam soaked in 200 μM verapamil solution (Approval No. GYZZ H23020293; Heilongjiang Duoduo Pharmaceutical Co., Ltd., Jiamusi, China), forming a tube around the repair. The wrapped stoma was placed under the biceps femoris. The biceps femoris was sutured with absorbable suture and the skin was sutured with silk sutures. After disinfecting, the wound was dressed (Yang et al., 2006). In the control group, the stoma was wrapped with gelfoam soaked in physiological saline. After regaining consciousness, all rats were fed with benzylpenicillin sodium solution (North China Pharmaceutical Co., Ltd., Shijiazhuang, Hebei Province, China).

Wet weight and atrophy index of the gastrocnemius muscle

Four weeks after injury, the rats were decapitated. The skin of the posterior leg on the injury side was cut open to expose the gastrocnemius muscle. The gastrocnemius muscle was completely dissociated by breaking from the Achilles tendon.

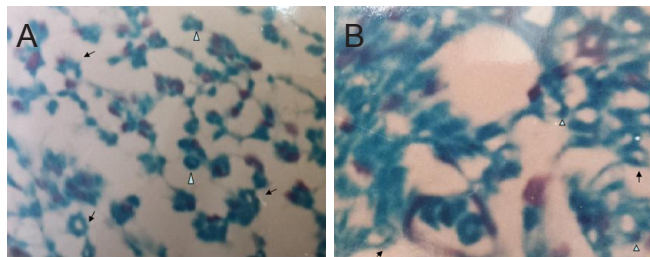


Figure 1 Verapamil effects on the morphology of axons in rats with sciatic nerve injury (toluidine blue staining, × 100). (A) Axons were regular and dense in the experimental group; (B) axons were disordered and irregular; collagen was visible in the control group. Arrows show axons; triangles show Schwann cells.

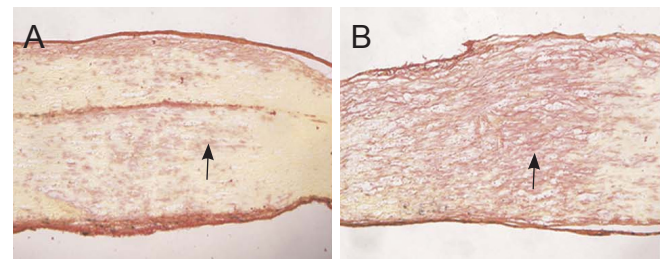


Figure 2 Verapamil effects on collagen deposition at the injury site in rats with sciatic nerve injury (Van Gieson staining, × 40). After sciatic nerve injury, the broken end was intervened with verapamil solution in the experimental group, with physiological saline in the control group. (A) Experimental group: less collagen was observed in the nerve stem and below the epineurium. (B) Control group: the epineurium was plump; collagen deposition was more within the nerve stem. Arrows present collagen deposition.

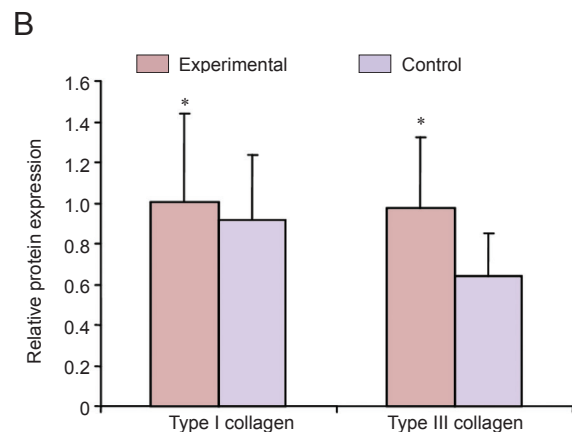
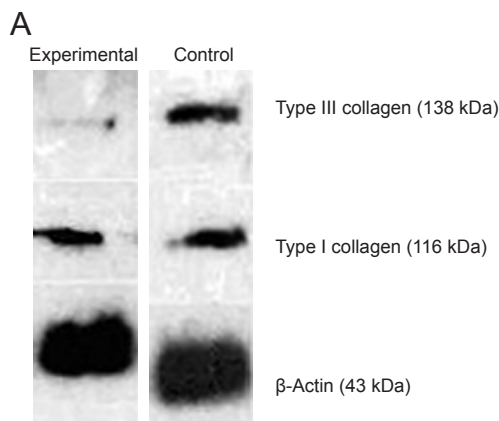


Figure 3 Verapamil effects on the expression of types I and III collagen at the injury site in rats with sciatic nerve injury (western blot assay). The expression of types I and III collagen was presented by the ratio of optical density of types I and III collagen to β-actin. After sciatic nerve injury, the broken end was intervened with verapamil solution in the experimental group, with physiological saline in the control group. The data are expressed as the mean ± SD, with 10 rats in each group. Two-sample *t*-test was used to compare the data between two groups. **P* < 0.05, vs. control group.

Table 1 Effects of verapamil on gastrocnemius muscle morphology in rats with sciatic nerve injury

Group	Wet weight of gastrocnemius muscle (g)	Atrophy index
Experimental	8.876±1.433 [*]	0.64±0.16 [*]
Control	6.852±1.204	0.42±0.19

After sciatic nerve injury, the broken end was intervened with verapamil solution in the experimental group, with physiological saline in the control group. Gastrocnemius muscle atrophy index = wet weight of gastrocnemius muscle/body weight. The data are expressed as the mean ± SD, with 30 rats in each group. Two-sample *t*-test was used to compare the data between two groups. **P* < 0.05, vs. control group.

Blood was removed with filter paper. Sample weight was weighed with a analytical balance (Keep Apex, Wuxi, Jiangsu Province, China). Gastrocnemius muscle atrophy index was calculated as the wet weight of gastrocnemius muscle/body weight.

Sample collection

Four weeks after injury, the rats were decapitated. After removal of gastrocnemius muscle, the sciatic nerve was exposed. Taking the suture site as the center, 1.5 cm of sciatic nerve was obtained, dehydrated through a graded alcohol series, cleared with xylene, embedded in paraffin and sliced into 4-μm-thick sections. The sections were dried at 50°C for further use.

Toluidine blue staining for axons and myelinated nerve fibers

All nerve sections were dewaxed, hydrated, fixed in 4% paraformaldehyde for 1 hour, washed once or twice with phosphate buffered saline (PBS), treated with preheated 0.5% toluidine blue (Shanghai Enzyme-linked Biotechnology Co., Ltd., Shanghai, China), stained in a water bath at 55°C for 20 minutes, washed three times with distilled water, and placed in 0.15% ethanol and HCl for 3 seconds. The samples were dehydrated with 90% ethanol, counter-stained with 0.25% eosin for 5 seconds, decolorized with 95% ethanol, dehydrated, cleared with xylene, mounted, and observed with a light microscope (Precise, Beijing, China). The number of myelinated nerve fibers was counted at 200× magnification with HPLAS-1000 high-resolution color pathological image analysis system (China Daheng Group, Inc. Beijing Image Vision Technology Branch, Beijing, China).

Van Gieson staining for morphology of collagen

Nerve sections were dewaxed, hydrated, stained with Weigert's iron hematoxylin for 20 minutes, washed with running water, differentiated with 95% ethanol, and washed with distilled water for 10 minutes. The samples were stained with Van Gieson's solution for 1 minute, washed, differentiated with 95% ethanol, dehydrated with absolute alcohol, cleared with xylene, and mounted. Collagen deposition was observed with a light microscope.

Table 2 Verapamil effects on the number of axons in the sciatic nerve of rats with sciatic nerve injury

Group	Total number of axons	Number of myelinated axons
Experimental	207.5±11.2 [*]	97.6±10.2 [*]
Control	125.6±12.0	67.6±9.1

After sciatic nerve injury, the broken end was intervened with verapamil solution in the experimental group, with physiological saline in the control group. The data are expressed as the mean ± SD, with 20 rats in each group. Two-sample *t*-test was used to compare the data between two groups. **P* < 0.05, vs. control group.

Western blot assay for types I and III collagen expression

Each sciatic nerve sample was homogenized and total protein was extracted. Protein concentrations were measured. Ten samples of each group underwent electrophoresis, and then transferred onto the polyvinylidene fluoride membrane. Membranes were blocked with 5% skimmed milk, incubated with rabbit anti-rat type I collagen monoclonal antibody (1:200; Abcam, Cambridge, UK) and rabbit anti-rat type III collagen monoclonal antibody (1:400; Abcam) in a wet box overnight at 4°C, followed by 0.5 hours at room temperature. Then they were incubated with CY3 goat anti-rabbit secondary antibody (1:200; Abcam) in the dark for 1 hour at room temperature, and visualized with X-ray. Optical densities of types I and III collagen were analyzed with Image-Pro Plus 5.0.2.9 software (Media Cybernetics, Bethesda, MD, USA). Results were presented by the ratio of optical density of collagen to β-actin.

Statistical analysis

The data are expressed as the mean ± SD and analyzed with SPSS 13.0 software (SPSS, Chicago, IL, USA). Two-sample *t*-test was used to compare the data between two groups. A value of *P* < 0.05 was considered statistically significant.

Results

Verapamil alleviated the injury of gastrocnemius muscle in rats with sciatic nerve injury

Compared with the control group, wet weight of gastrocnemius muscle was higher, and the atrophy index was larger in the experimental group (*P* < 0.05; **Table 1**).

Verapamil improved the morphology of axons in the sciatic nerve of rats with sciatic nerve injury

Toluidine blue staining results reveal that at 4 weeks after injury, the total number of axons and the number of myelinated axons were higher in the experimental group than in the control group (*P* < 0.05; **Figure 1, Table 2**).

Verapamil effects on collagen fiber morphology at the site of injury in rats with sciatic nerve injury

Van Gieson staining results demonstrate that at 4 weeks after injury, proliferation of newborn capillaries, accumulation of fibroblasts and scar tissue formation were observed at the

injury site. Collagen deposition was less at the injury sites in the experimental group than in the control group (Figure 2).

Verapamil inhibited the expression of types I and III collagen at the site of injury in rats with sciatic nerve injury

Western blot assay results show that four weeks after injury, compared with the control group, the expression of types I and III collagen at the site of injury was lower in the experimental group than in the control group ($P < 0.05$; Figure 3).

Discussion

After peripheral nerve injury, fibrin exudation was induced by proinflammatory cytokines. Fibroblasts accumulated, divided, and secreted extracellular matrix (mainly types I and III collagen) around the injury site. Lee and Ping (1990) first reported the effect of calcium channel blockers in the reduction of scar formation. Doong et al. (1996) found that intracellular calcium concentration first increased and then decreased after treatment with verapamil, which inhibited the functions of various Ca^{2+} -mediated cells. Iannetti et al. (2009) identified that calcium channel blockers inhibited fibroblast growth possibly by suppressing the protein kinase C pathway.

Calcium channel blockers can prevent the flow of calcium into fibroblasts, depolymerize actin, destroy the cytoskeleton, induce spherical change in fibroblasts, block the movement of vesicles during protein synthesis, cause collagen precursor to gather in cells and inhibit the secretion of collagen. On the one hand, calcium channel blockers reduce the biological activity of cells by inhibiting signal transduction inside and outside fibroblasts. On the other hand, calcium channel blockers suppress synthesis and secretion of collagen and extracellular matrix by changing fibroblast morphology and ultrastructure, reduce tissue adhesion and scar formation. Types I and III collagen and mRNA levels were higher in scar tissue than in skin. Verapamil has an inhibitory effect on types I and III collagen and mRNA synthesis. Inhibiting mRNA at the genetic level is the main pathway by which calcium channel blockers inhibit collagen synthesis (Huang et al., 2014).

Roth et al. (1996) considered that calcium channel blockers not only suppressed extracellular matrix secretion, but also promoted extracellular matrix degradation. Several studies have confirmed that collagen synthesis was reduced and collagenase secretion was increased when fibroblasts became more spherical (Baccai and Kocsis, 2000; Özgenel, 2003; Gordon et al., 2009). Calcium channel blockers can induce spherical changes in fibroblasts. After this effect is activated, even if the drug is removed, the synthesis and secretion of collagenase still remained. Spherical changes induced synthesis and secretion of collagenase are probably associated with gene expression and regulation.

In summary, topical verapamil application reduces the formation of types I and III collagen in the sciatic nerve at the site of injury and, after epineurial repair, diminishes the formation of scar tissue and indirectly promotes axon growth. Whether verapamil impacts anti-tensile force and anti-tensile strength during the healing of nerves requires

further investigation.

Author contributions: *ACH performed the experiments and provided data. QSH obtained funding, conceived and designed the study. HYZ and JXD participated in statistical analysis. ZWL wrote the paper. PZ was in charge of manuscript authorization and proofreading. ZBC served as a principle investigator. All authors approved the final version of the paper.*

Conflicts of interest: *None declared.*

Plagiarism check: *This paper was screened twice using Cross-Check to verify originality before publication.*

Peer review: *This paper was double-blinded and stringently reviewed by international expert reviewers.*

References

- Baccai ML, Kocsis JD (2000) Voltage-gated calcium currents in axotomized adult rat cutaneous afferent neurons. *J Neurophysiol* 83:2227-2238.
- de Luca AC, Lacour SP, Raffoul W, di Summa PG (2014) Extracellular matrix components in peripheral nerve repair: how to affect neural cellular response and nerve regeneration? *Neural Regen Res* 9:1943-1948.
- Doong H, Dissanayake S, Gowrishankar TR, LaBarbera MC, Lee RC (1996) The 1996 Lindberg Award. Calcium antagonists alter cell shape and induce procollagenase synthesis in keloid and normal human dermal fibroblasts. *J Burn Care Rehabil* 17:497-514.
- Gong LL, Zhu Y, Xu X, Li HQ, Guo WM, Zhao Q, Yao DB (2014) The effects of claudin 14 during early Wallerian degeneration after sciatic nerve injury. *Neural Regen Res* 9:2151-2158.
- Gordon T, Chan KM, Sulaiman OA, Udina E, Amirjani N, Brushart TM (2009) Accelerating axon growth to overcome limitations in functional recovery after peripheral nerve injury. *Neurosurgery* 65:A132-144.
- Grinsell D, Keating CP (2014) Peripheral nerve reconstruction after injury: a review of clinical and experimental therapies. *Biomed Res Int* 2014:698256.
- Huang X, Fan R, Lu Y, Yu C, Xu X, Zhang X, Liu P, Yan S, Chen C, Wang L (2014) Regulatory effect of AMP-activated protein kinase on pulmonary hypertension induced by chronic hypoxia in rats: in vivo and in vitro studies. *Mol Biol Rep* 41:4031-4041.
- Iannetti P, Parisi P, Spalice A, Ruggieri M, Zara F (2009) Addition of verapamil in the treatment of severe myoclonic epilepsy in infancy. *Epilepsy Res* 85:89-95.
- Lee RC, Ping JA (1990) Calcium antagonists retard extracellular matrix production in connective tissue equivalent. *J Surg Res* 49:463-466.
- Lundborg G (2000) A 25-year perspective of peripheral nerve surgery: evolving neuroscientific concepts and clinical significance. *J Hand Surg Am* 25:391-414.
- Ngeow WC (2010) Scar less: a review of methods of scar reduction at sites of peripheral nerve repair. *Oral Surg Oral Med Oral Pathol Oral Radiol Endod* 109:357-366.
- Özgenel GY (2003) Effects of hyaluronic acid on peripheral nerve scarring and regeneration in rats. *Microsurgery* 23:575-581.
- Roth M, Eickelberg O, Kohler E, Erne P, Block LH (1996) Ca^{2+} channel blockers modulate metabolism of collagens within the extracellular matrix. *Proc Natl Acad Sci U S A* 93:5478-5482.
- Terenghi G, Hart A, Wiberg M (2011) The nerve injury and the dying neurons: diagnosis and prevention. *J Hand Surg Eur Vol* 36:730-734.
- Yang F, Zhang JR, Wen YF, Yang LM, Huang QB (2006) Synergistic effect of verapamil and nerve growth factor on promoting sciatic nerve regeneration in rats. *Zhongguo Zuzhi Gongcheng Yanjiu yu Linchuang Kangfu* 13:7231-7235.
- Yegiyants S, Dayicioglu D, Kardashian G, Panthaki ZJ (2010) Traumatic peripheral nerve injury: a wartime review. *J Craniofac Surg* 21:998-1001.

Copiedited by Dawes EA, Pack M, Yu J, Qiu Y, Li CH, Song LP, Zhao M