

# Endocardial cushion defects

## *An anatomical study of 54 specimens*

M. Ugarte, F. Enríquez de Salamanca, and M. Quero

*From Servicio de Cardiología, Clínica 'Puerta de Hierro'; Departamento de Medicina Interna, Ciudad Sanitaria 1° de Octubre; and Servicio de Cardiología Pediátrica, Clínica Infantil 'La Paz', Madrid, Spain*

*An anatomical study of 54 specimens with endocardial cushion defect is described. The material was divided into two groups, according to the morphology and attachments of the anterior component of the anteroseptal mitral leaflet.*

*We suggest that there is no divided or undivided anterior common leaflet. There are always two anterior leaflets, a mitral and a tricuspid one, separated by a commissure; depending on the degree of straddling of the mitral component over the interventricular septum, this will protrude into the interventricular septum or into the anterior papillary muscle of the right ventricle. Thus, the commissure separating the mitral and the tricuspid components will lie over the interventricular septum or will be quite separate in the right ventricle. In the latter case the straddling mitral component gives the false appearance of an undivided anterior common leaflet.*

*The septal tricuspid leaflet was found to be underdeveloped or absent but we were not able to find any clefts or divisions in it. We suggest that this leaflet derives solely from the division of the posteroinferior endocardial cushion into two halves, right and left. The left half later becomes the posterior component of the normal anteroseptal mitral leaflet.*

*Associated anomalies are also reviewed.*

Endocardial cushion defects form a wide spectrum of anomalies (Campbell and Missen, 1957; Kiely *et al.*, 1958; Neufeld *et al.*, 1961; Al Omeri *et al.*, 1965), ranging from the isolated left axis deviation of the QRS (Sumner *et al.*, 1967) to the so-called persistent common atrioventricular canal in its complete form.

The endocardial cushions are responsible for the development of the posterior smooth septum (Wakai and Edwards, 1956, 1958; Van Mierop *et al.*, 1962; Goor, Edwards, and Lillehei, 1970a; Goor *et al.*, 1970b), the membranous septum (Campbell and Missen, 1957; Van Mierop *et al.*, 1962; Odgers, 1938), the anteroseptal mitral leaflet (Grant, 1962), the septal and posterior tricuspid leaflets (Al Omeri *et al.*, 1965; Van Mierop, 1969; Grant, 1962), and indirectly for the correct anatomical distribution of the conduction system (Feldt, DuShane, and Titus, 1970). The part they play in the development of the anterior tricuspid leaflet

and the posterior ventricular wall has not been clearly explained.

Stimulated by recent papers (Goor, Lillehei, and Edwards, 1968; Tenckhoff and Stamm, 1973; Blieden *et al.*, 1974), we examined our necropsy material with special reference to the anatomy of the atrioventricular valves, their relation to the interventricular septum, and the haemodynamic, angiographic, and surgical implications.

### **Patients and methods**

A study was made of 54 necropsy specimens from the anatomical collection of the Clínica Infantil 'La Paz', Madrid, which showed endocardial cushion defect. Cases with important dominance of a ventricle and/or total or partial absence of the subvalvular apparatus in the underdeveloped ventricle were excluded (single ventricle and related anomalies).

We accept the embryological origin of the atrioventricular valves as shown in Fig. 1.

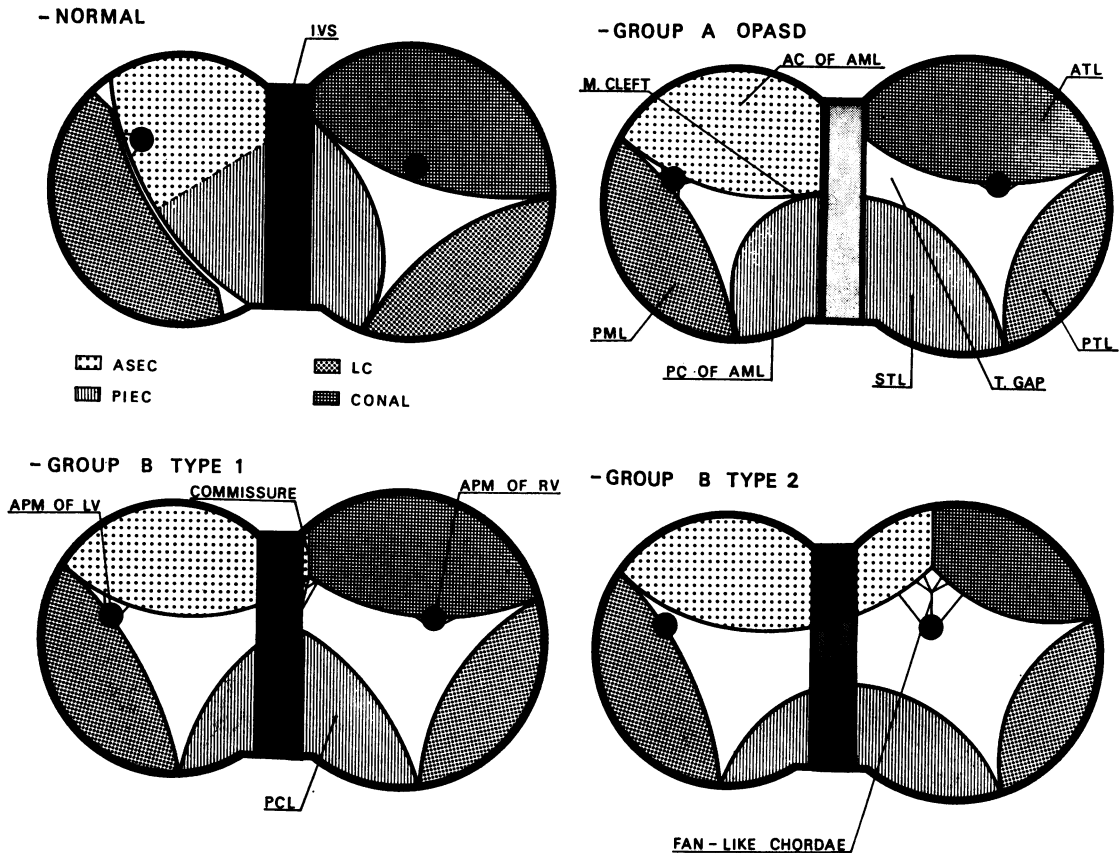


FIG. 1 Diagrammatic representation of anatomical components of atrioventricular valves in normal heart and in different types of endocardial cushion defect.

Upper left: normal heart. Anterosuperior endocardial cushion (ASEC) converts wholly into anterior component of anteroseptal mitral leaflet (AC of AML). Posteroinferior endocardial cushion (PIEC) converts into posterior component of anteroseptal mitral leaflet (PC of AML) and septal tricuspid leaflet (STL). Posterior mitral leaflet (PML) and posterior tricuspid leaflet (PTL) are developed from left and right lateral cushions (LC), respectively. Anterior tricuspid leaflet (ATL) is considered to be of conal origin.

Upper right: Group A: ostium primum atrial septal defect (OPASD). Existence of fibrous continuity between AC of AML and PC of AML, though cleft is present between them (M. cleft). STL is smaller than usual and there is gap (T. gap) between it and ATL, where normal anterior tricuspid commissure should be.

Lower left: Group B: type 1. AC of AML joins ATL forming commissure which is attached by short chordae tendineae to crest of interventricular septum (IVS). Medially-located fissure tending to divide posterior common leaflet (PCL) into two halves.

Lower right: Group B: type 2. Commissure between AC of AML and ATL is inserted into anterior papillary muscle of right ventricle (APM of RV) and is located more to right than in cases of type 1 because of straddling of AC of AML over IVS towards right ventricle and to smaller-sized ATL. APM of RV in these cases may be located more medially than usual.

In all three types of endocardial cushion defects anterior papillary muscle of left ventricle (APM of LV) is usually laterally displaced with respect to normal heart.

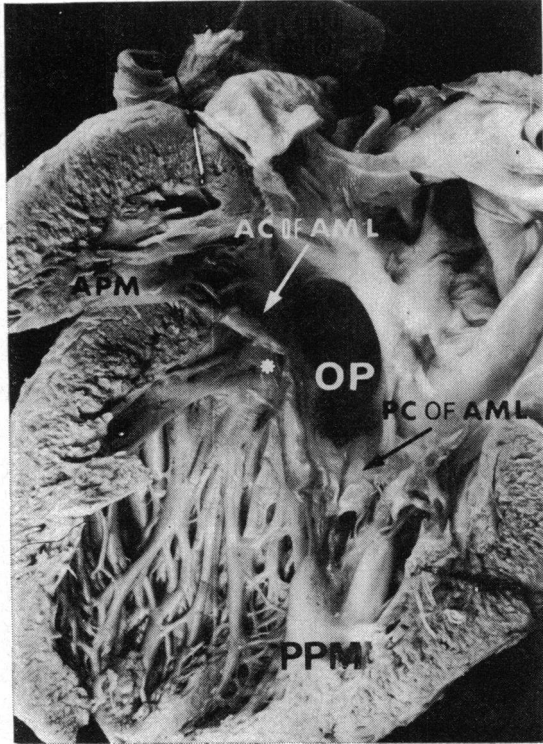


FIG. 2 Left ventricular view of group A case. Ostium primum (OP) and cleft (\*) between anterior (AC of AML) and posterior (PC of AML) components of anteroseptal mitral leaflet. Upward displacement of anterior papillary muscle (APM) and increased mass of posterior group of papillary muscles (PPM).

The following elements have been examined in the atrioventricular valves.

**(A) Anterior component of anteroseptal mitral leaflet**

**(B) Posterior common leaflet**

This represents the incomplete development of the posteroinferior endocardial cushion and its subsequent failure to divide into the posterior component of the anteroseptal mitral leaflet and the septal tricuspid leaflet, where this exists (Van Mierop, 1969; Grant, 1962).

**(C) Left and right lateral leaflets**

The left lateral leaflet later becomes the posterior mitral leaflet in cases of ostium primum atrial septal defect and in normal hearts, while the right one becomes the posterior tricuspid leaflet (Al Omeri *et al.*, 1965; Van Mierop, 1969).

**(D) Anterior tricuspid leaflet**

This is generally thought to be partially or totally of conal origin (Odgers, 1938; Al Omeri *et al.*, 1965; Van Mierop, 1969; Tenckhoff and Stamm, 1973).

Previously reported criteria (Lam *et al.*, 1970; Ranganathan *et al.*, 1970; Silver *et al.*, 1971) for the identification of the commissures in normal hearts were used.

Our material has been classified as follows.

**Group A (7 cases)**

This group includes those specimens showing two well-differentiated atrioventricular valves with fibrous continuity between the anterosuperior endocardial cushion and the posteroinferior endocardial cushion, or, in other words, between the anterior and posterior components of the anteroseptal mitral leaflet. Those are the cases usually known as

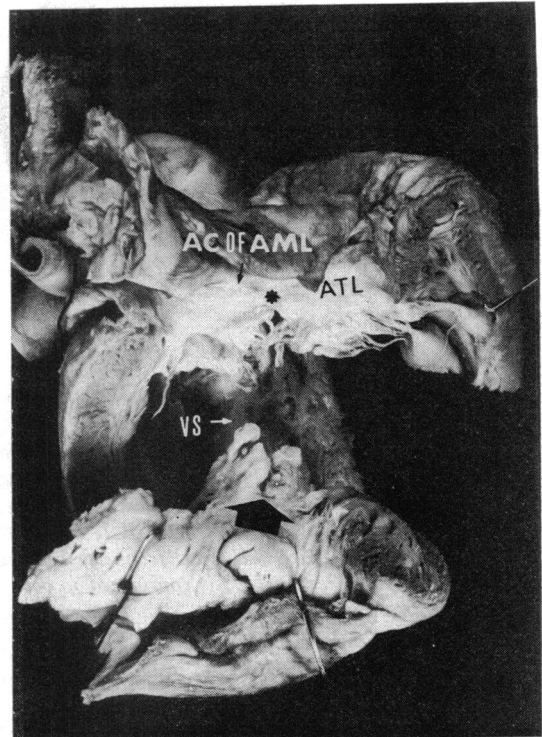


FIG. 3 Group B type 1 case, viewed from above. Commissure (\*) between anterior component of anteroseptal mitral leaflet (AC of AML) and anterior tricuspid leaflet (ATL) is inserted by means of short chordae tendineae into top rim of interventricular septum (VS). Fissure (arrow) in posterior common leaflet (PCL) divides it into two halves of roughly similar size.

ostium primum atrial septal defect (Fig. 1, upper right, and Fig. 2), and we include here the partial and transitional forms of Wakai and Edwards (1956, 1958).

### Group B (47 cases)

This group includes those specimens showing discontinuity between the anterosuperior endocardial cushion and the posteroinferior endocardial cushion, being the so-called persistent common atrioventricular canal in the complete form of Wakai and Edwards. This group consists of two types.

**Type 1** (26 cases) Here the anterior component of the anterior mitral leaflet attaches on its medial side to the interventricular septum and is not connected to the anterior papillary muscle of the right ventricle (Fig. 1, lower left, and Fig. 3).

**Type 2** (21 cases) Here the anterior component of the anteroseptal mitral leaflet straddles the interventricular septum and inserts into the anterior papillary muscle of the right ventricle (Fig. 1, lower right, and Fig. 4).

We analysed the insertions of the anterior and posterior leaflets into the interventricular septum and the nature of these insertions when found. We also dealt with the ventricular septal defects under

the leaflets, the presence of redundant valvular tissue, the number, position, and size of the papillary muscles, and the presence of accessory valvular orifices, identified as such by the presence of chordae tendineae inserted into the annulus of the orifice.

An analysis of the atrial septum was included. The septum primum was considered to be intact when at its anterosuperior and posteroinferior limits, it joined the base of the atrioventricular valves and there was no important defect above an imaginary line joining both limits.

The anatomy of the interventricular septum was studied according to recent papers by Goor *et al.* (1970a, b).

We tried to recognize the septal and moderator bands whenever it was possible to do so with reasonable certainty.

The out-flow/in-flow tract ratio was measured (Goor *et al.*, 1968; Tenckhoff *et al.*, 1973; Blieden *et al.*, 1974). Atrial straddling of the interventricular septum (Tenckhoff and Stamm, 1973; Yokoyama *et al.*, 1973) and ventricular dominances (Bharati and Lev, 1973) were also investigated.

The associated anomalies were recorded, and special attention paid to those of truncoconal nature.

## Results

### Atrioventricular valves

In 45 cases of group B a commissure was identified between the anterior component of the anteroseptal mitral leaflet and the anteroseptal tricuspid leaflet.

This commissure does not exist in normal hearts, since in these the anteroseptal tricuspid leaflet, at its medial commissure, joins the septal tricuspid leaflet. In two other group B type 2 cases this commissure was not identified in one case, because of deterioration of the region and, in the other, because of hypoplasia of the anteroseptal tricuspid leaflet. In one group B type 1 case and three group B type 2 cases there was partial fusion of the anterior component of the anteroseptal mitral leaflet and the anteroseptal tricuspid leaflet; a clear fusion line was identified. In group A the anterior component of the anteroseptal mitral leaflet, instead of being connected to the anteroseptal tricuspid leaflet, joined the posterior component of the anteroseptal mitral leaflet, derived from the posteroinferior endocardial cushion. A cleft between the two components was always present (Fig. 2).

A ventricular septal defect under the anterior component of the anteroseptal mitral leaflet and the posterior common leaflet has been frequently found in every group (Table 1), even in group A. A

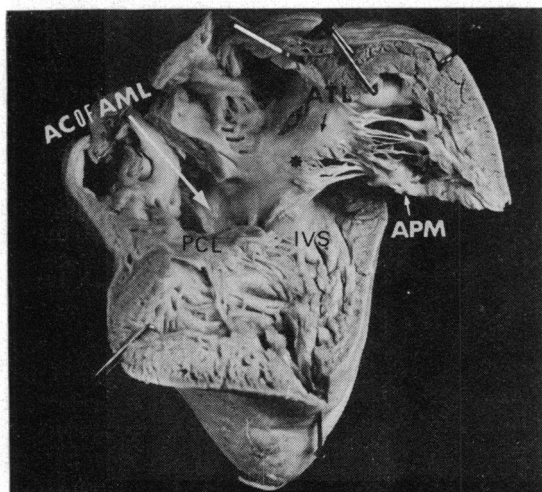


FIG. 4 Right ventricular view of group B type 2 case. Commissure (\*) between straddling anterior component of anteroseptal mitral leaflet (AC of AML) and anterior tricuspid leaflet (ATL) is displaced far towards right, being clearly contained in right ventricle and anchored by means of 'fan-like' chordae to anterior papillary muscle (APM). PCL=posterior common leaflet. IVS=interventricular septum.

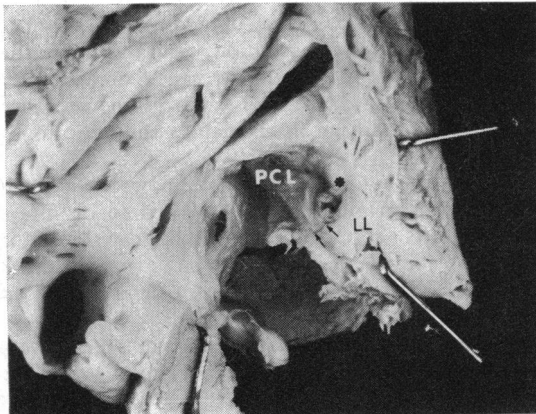


FIG. 5 Left atrial view of group B type 2 case showing accessory atrioventricular orifice (\*). Fusion line (arrows) between posterior common leaflet (PCL) and left lateral leaflet (LL).

medially-located fissure in the posterior common leaflet was present in 17 cases (36%) in group B (Fig. 3), partially dividing this leaflet into right and left halves. This fissure was more common in group B type 1 cases (42%). Redundant valvular tissue has also been frequently encountered in this leaflet.

Twenty-four accessory valvular orifices were found in our material, evenly distributed in all groups. All but a few were on the fusion line of two valvular leaflets, usually between the lateral and the posterior, sometimes between the lateral and the anterior, and even, on occasion, between the anterior mitral and tricuspid leaflets. Usually the fusion line was easily recognizable (Fig. 5).

### Papillary muscles

Position anomalies of the papillary muscles were encountered mainly in the left ventricle, and usually consisted of a lateralization and upwards displacement of both papillary muscles. This anomaly occurred in all cases of group A and in 27 group B cases, and was more frequent in type 1 of group B

TABLE 1 Number and location of ventricular septal defects

Group	VSD under AC of AML	VSD under PC of AML
A	2 (29%)	1 (14%)
B-1	23 (88%)	19 (73%)
B-2	21 (100%)	16 (76%)

VSD, ventricular septal defect; AC of AML, anterior component of anteroseptal mitral leaflet; PC of AML, posterior component of anteroseptal mitral leaflet.

(17 cases, 65%) than in type 2 (group B) (10 cases, 48%). In 6 cases (29%) of type 2 (group B) a medial displacement of the anterior papillary muscle of the right ventricle was seen.

The papillary muscle of the conus was absent in 19 cases (91%) of type 2 (group B). By contrast, this structure was found to exist in 31 cases (94%) of the remaining specimens not included in type 2 (group B).

One case in group A showed parachute atrioventricular valve in both ventricles; the overall incidence of parachute atrioventricular valves in our material was 9.3 per cent. Accessory papillary muscles were often found, usually lateral and in some cases were large.

### Atrial septum

After careful evaluation, the septum primum was considered intact in 5 cases (71%) of group A, 16 cases (62%) of type 1 (group B) and in 11 cases (52%) of type 2 (group B). An ostium secundum atrial septal defect was present in 48 per cent of all

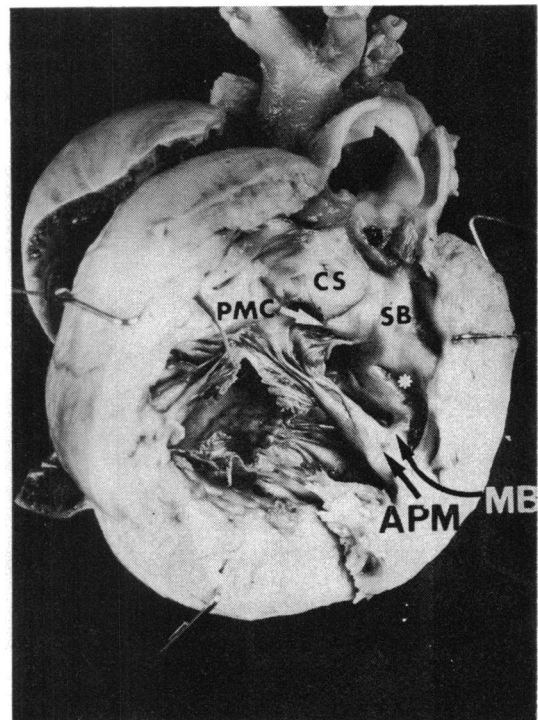


FIG. 6 Right ventricular view of group B type 1 case. Bifid nature (\*) of inferior extremity of septal band (SB). CS=conal septum. MB=moderator band. PMC=papillary muscle of conus. APM=anterior papillary muscle of right ventricle.

TABLE 2 Percentage of deficiency of left ventricular posterior wall according to out-flow/in-flow tract ratio

Group	Per cent deficiency ( $\pm$ SD)
A	24.7 $\pm$ 7.7
B-1	27.9 $\pm$ 8.8
B-2	23.6 $\pm$ 8.1

cases. Five cases of type 1 (group B), and another five of type 2 (group B) presented a single atrium. No instance of single atrium was found in group A.

### Interventricular septum

Membranous septum was deficient or absent in every case in group B, whereas it was present in all the cases in group A. Anterior smooth septum was deficient in 9 cases (19%) of group B, there being no difference between types 1 and 2. No case among those studied showed a defect in the trabeculated septum. Posterior smooth septum was naturally deficient in all cases.

### Septal and moderator bands

It was not possible to recognize the septal band in one case of group A, 8 cases (31%) of type 1 (group B), and 5 cases (24%) of type 2 (group B). In addition, 3 cases of group A, 9 cases of type 1 (group B), and 7 cases of type 2 (group B) showed a bifid inferior division of the septal band. The anterior division pointed towards the apex of the right ventricle and the posterior one formed the moderator band (Fig. 6).

### Out-flow/in-flow tract ratio in left ventricle

The posterior wall of the left ventricle was in all cases undersized. The degree of underdevelopment of the left ventricular posterior wall was similar in all groups (Table 2).

### Atrial straddling and ventricular dominances

In one case in group A, 11 cases of type 1 (group B) and 10 cases of type 2 (group B) the right atrium straddled the interventricular septum and the atrial

TABLE 3 Major associated anomalies

Type	TGV	PAA	TF	IPS	Asplenia
Group B, 1	2	1	1	1	2
Group B, 2	—	1	3	—	—

TGV, transposition of great vessels; PAA, pulmonary artery atresia; TF, tetralogy of Fallot; IPS, infundibular pulmonary stenosis.

Note: Only Group B is shown, as there was no instance of major associated anomalies in group A.

septum lay to the left, leaving a smaller than normal left atrium in those cases.

A right or left ventricular dominance was encountered in some cases. There was no instance of left ventricular dominance in group A, the right ventricle being dominant in 4 cases in this group. In group B ventricular dominances were evenly distributed.

### Associated malformations

Major associated anomalies are described in detail in Table 3. Truncocoanal malformations were found only in group B, occurring as frequently in type 1 as in type 2. There were no associated major malformations.

There was a high incidence of persistent ductus arteriosus in all groups. Minor associated anomalies included one case of coarctation of the aorta, 7 cases of aortic arch anomalies, and 8 cases of persistent left superior vena cava draining either to the coronary sinus (7 cases) or to the left atrium (1 case). In addition, one case of type 1 (group B) showed a partial anomalous pulmonary venous drainage.

Four cases in group A, 9 cases of type 1 (group B), and 6 cases of type 2 (group B) showed no associated malformation.

### Discussion

Endocardial cushion defects have, in the past, been classified in a variety of ways (Campbell and Missen, 1957; Wakai and Edwards, 1956, 1958; Rastelli, Kirklin, and Titus, 1966; Rastelli *et al.*,

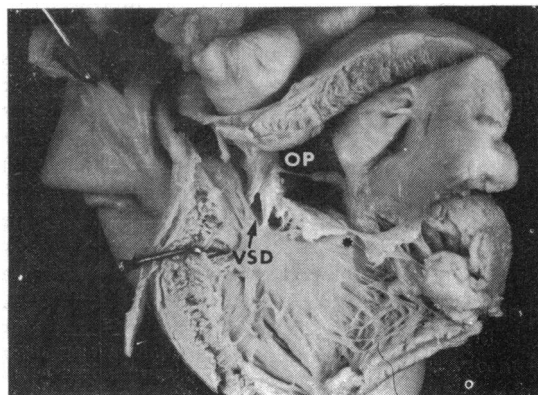


FIG. 7 Left ventricular view of group A case. Anterior component of anterosseptal mitral leaflet (AC of AML) is attached to crest of interventricular septum by short chordae tendineae which leave multiple ventricular septal defects (VSD) between them. OP=ostium primum; (\*)=cleft of the anterosseptal mitral leaflet.

1968; Quero *et al.*, 1974) in accordance with the various criteria applied. Classifications have usually been based upon the morphology and attachments of the so-called anterior common leaflet, though the anatomically less anomalous cases (ostium primum atrial septal defect) have always been considered separately. The most widely accepted classification is that proposed by Rastelli and co-workers (1966, 1968); some aspects of it, however, have recently been questioned (Tenckhoff and Stamm, 1973; Quero *et al.*, 1974), especially type II. Thus, endocardial cushion defects are at present divided into two types—always with the exception of ostium primum atrial septal defect—according to the presence or absence of attachments between the so-called anterior common leaflet and the interventricular septum.

A review of our necropsy material according to the embryological scheme previously outlined in this paper showed that in group B cases the valvular apparatus was always composed of two elements on its anterior side—a left or mitral one and a right or tricuspid one, separated by a commissure. The component situated to the right of the commissure is always an anterosseptal tricuspid leaflet whose size may vary. The component situated to the left of the commissure—the mitral component—may insert on its medial side into the anterior papillary muscle of the right ventricle (group B, type 2 cases) or into the interventricular septum (group B, type 1 cases), while on its lateral side it always inserts into the anterior papillary muscle of the left ventricle.

Early in the life of the embryo the anterosuperior endocardial cushion is found straddling the interventricular septum; it later rotates and shifts towards the left ventricle to become the anterior component of the anterosseptal mitral leaflet (Grant, 1962) and fuses to its posterior component developed from the posteroinferior endocardial cushion. If the anterior component of the anterosseptal mitral leaflet is displaced towards the left ventricle, as in the normal heart, but is only partially fused to the posterior component, a cleft in the anterosseptal mitral leaflet will result (group A, ostium primum atrial septal defect). If the anterior component of the anterosseptal mitral leaflet is shifted towards the left ventricle but has not fused to the posterior component, its medial side will insert into the crest of the interventricular septum and the commissure separating it from the anterosseptal tricuspid leaflet will necessarily be located over the interventricular septum (group B type 1). If the anterior component of the anterosseptal mitral leaflet is not shifted towards the left ventricle nor has fused to the posterior component developed

from the posteroinferior endocardial cushion, it will insert on its medial side into the anterior papillary muscle of the right ventricle, thus giving the false appearance of an anterior common leaflet. Nevertheless careful inspection will reveal that, to the right of this anterior component, and separated from it by a commissure, there exists an anterosseptal tricuspid leaflet, however small. In such cases this commissure will be located in the right ventricle (group B type 2).

The underdevelopment of the anterosseptal tricuspid leaflet in some of these cases may be the result of the fact that, since the anterosuperior endocardial cushion is abnormally located, the anterosseptal tricuspid leaflet cannot so easily develop from the dextrodorsal conus swelling and a lesser amount of endocardial tissue of conal origin is able to reach the atrioventricular ring.

In some of our cases of type 2 (group B) it seemed at first sight that there was no anterosseptal tricuspid leaflet. It did, however, exist, and was located in its normal place, though on the anterior side of the mitral component that straddled the interventricular septum, and was hidden by it. It seems that an anterosseptal tricuspid leaflet had developed from the dextrodorsal conus swelling, even though ousted from its normal location by the abnormally sited anterosuperior endocardial cushion. The final result was something like a double or overlapping leaflet in the anterior tricuspid region.

Thus, we consider that the concept of a divided or undivided anterior common leaflet (Rastelli *et al.*, 1966, 1968) must be re-examined and that we should think in terms of an anterior component of the mitral leaflet attached to the interventricular septum or a straddling anterior component of the anterosseptal mitral leaflet anchored to the anterior papillary muscle of the right ventricle. The division usually described in the anterior common leaflet is a commissure between the anterior component of the anterosseptal mitral leaflet, originally the anterosuperior endocardial cushion, and an anterior tricuspid component of conal origin. In support of this we adduce the presence of 'fan-like' chordae, previously reported as commissure markers in normal hearts (Lam *et al.*, 1970; Ranganathan *et al.*, 1970; Silver *et al.*, 1971), which we found in the majority of our type 2 (group B) cases (Fig. 4).

A fissured posterior common leaflet (Fig. 3) is found more frequently in type 1 (group B) cases than in type 2 (group B), and, in our opinion, indicates a more advanced stage of development, since such fissures are the first indication of the posterior common leaflet dividing to produce the posterior component of the anterosseptal mitral leaflet and the septal tricuspid leaflet.

A cleft septal tricuspid leaflet was not found in our study, a fact that seems to favour the idea that it is developed from the posteroinferior endocardial cushion and does not have a dual origin, as some authors have suggested (Wakai and Edwards, 1956, 1958; Kiely *et al.*, 1958; Al Omeri *et al.*, 1965; Tenckhoff and Stamm, 1973).

The presence of significant ventricular septal defects under the anterior and posterior leaflets in cases of group A (Fig. 7), and the fact that the posterior smooth septum is consistently deficient (Goor *et al.*, 1968), in our opinion qualifies these cases where they occur to be included under the general heading of persistent common atrioventricular canal. In our classification we include them as 'cases with fibrous continuity between both endocardial cushions', and we consider them as a group which shows the same basic malformation.

The very frequent presence of significant ventricular septal defects under both anterior and posterior leaflets in group B cases, even in those attaching medially to the interventricular septum, needs further emphasis. These ventricular septal defects allow shunts to occur, and are difficult to identify, since at present there are no satisfactory haemodynamic or angiocardiographic criteria by which they may be identified (Baron *et al.*, 1964; Wakai, Swan, and Wood, 1956; Cornell, 1965; Rastelli, Kirklín, and Kincaid, 1967; Somerville and Jefferson, 1968; Gotsman, Beck, and Schrire, 1968). Furthermore, they may prevent successful conservative surgery if residual shunts are present (Vanetti and Daumet, 1975).

The accessory valvular orifices, as previously reported (Campbell and Missen, 1957), were mainly located at the fusion line of two leaflets; in many of them the cicatricial fusion line was clearly visible (Fig. 5).

Anomalies of papillary muscles have been described previously (Al Omeri *et al.*, 1965; Tenckhoff and Stamm, 1973; Bharati and Lev, 1973). There are three striking features about the cases studied: firstly, in the left ventricle, the papillary muscles tended to lateralize and fuse, which perhaps explains the high incidence of parachute atrioventricular valves in this malformation. Secondly, the frequent medial deviation of the anterior papillary muscle of the right ventricle in type 2 (group B) cases (Rastelli *et al.*, 1966, 1968) may be because this muscle is connected to a valvular component from the left ventricle. Thirdly, the high percentage of positional anomalies of the papillary muscles of the left ventricle in group A cases (100% in our material) could prevent normal functioning of the mitral valve after conservative surgery (Frater, 1965; Somerville, 1966).

The septum primum could be considered intact in a great percentage of cases. This leads us to believe, with other authors (Wakai *et al.*, 1956; Wakai and Edwards, 1958; Kiely *et al.*, 1958; Baron *et al.*, 1964; Al Omeri *et al.*, 1965; Frater, 1965; Quero *et al.*, 1974) that the septum primum plays no part in the complex of malformations, and that the ostium primum atrial septal defect is actually a result of insufficient upwards growth of the endocardial cushions. Moreover, some cases have been reported (Neufeld *et al.*, 1961; Goor *et al.*, 1968; Quero *et al.*, 1974) of endocardial cushion defects without ostium primum atrial septal defect in which the anomalies were limited to the atrioventricular valves and the interventricular septum.

Septal and moderator bands were difficult to recognize in a great number of cases. Also worthy of note is the frequency with which a bifid inferior division was present on the septal band (Fig. 6). This phenomenon needs further study, as the embryological origin of these structures is still not completely explained.

In agreement with results obtained by previous authors (Goor *et al.*, 1968; Tenckhoff and Stamm, 1973; Blieden *et al.*, 1974), we have consistently found a shortening of the posterior wall of the left ventricle, as measured by the out-flow/in-flow tract ratio in the left ventricle. In some of our cases, however, the electrocardiogram showed right axis deviation of the QRS even where a pronounced shortening of the left ventricular posterior wall occurred.

Deviation of the atrial septum was a common finding (Tenckhoff and Stamm, 1973; Yokoyama *et al.*, 1973); the right atrium straddled the interventricular septum, suggesting that in some cases cyanosis may coexist with normal pressures on the pulmonary trunk (Campbell and Missen, 1957; Tenckhoff and Stamm, 1973; Quero *et al.*, 1974).

Among associated malformations, the commonest was persistent ductus arteriosus; the poorer prognosis of any left-to-right shunt associated with persistent ductus arteriosus may explain the high incidence of this malformation in necropsy material.

Group A did not show the associated severe anomalies occurring in the rest of the specimens. Truncocoanal malformations were concentrated in group B, but occurred as frequently in type 1 as in type 2. This agrees only partially with the findings of previous authors (Rastelli *et al.*, 1966, 1968; Bharati and Lev, 1973; Tenckhoff and Stamm, 1973), a discrepancy which we have been unable to explain.

Consequently, we consider that endocardial cushion defects are a continuous spectrum of malformations the anatomy of which depends on the



horizon on which the growth of the posteroinferior endocardial cushion is stopped and the degree of displacement of the anterosuperior endocardial cushion towards the right ventricle. Further haemodynamic and angiocardiographic findings are needed to reach a precise preoperative diagnosis. The surgeon who operates upon an endocardial cushion defect must be prepared to cope with the different types of the malformation, and avoid any type of intervention that might worsen the haemodynamic status of the malformation (Frater, 1965; Somerville, 1966).

### References

- Al Omeri, M., Bishop, M., Oakley, C., Bentall, H. H., and Cleland, W. P. (1965). The mitral valve in endocardial cushion defects. *British Heart Journal*, **27**, 161.
- Baron, M. G., Wolf, B. S., Steinfeld, S., and Van Mierop, L. H. S. (1964). Endocardial cushion defects: specific diagnosis by angiocardiography. *American Journal of Cardiology*, **13**, 162.
- Bharati, S., and Lev, M. (1973). The spectrum of common atrioventricular orifice (canal). *American Heart Journal*, **86**, 553.
- Blieden, L. C., Randall, P. A., Castaneda, A. R., Lucas, R. V., Jr., and Edwards, J. E. (1974). The 'goose neck' of the endocardial cushion defect: anatomic basis. *Chest*, **65**, 13.
- Campbell, M., and Missen, G. A. K. (1957). Endocardial cushion defects: common atrio-ventricular canal and ostium primum. *British Heart Journal*, **19**, 403.
- Cornell, S. H. (1965). Angiocardiography in endocardial cushion defects. *Radiology*, **84**, 907.
- Feldt, R. H., DuShane, J. W., and Titus, J. L. (1970). The atrioventricular conduction system in persistent common atrioventricular canal defect: correlations with electrocardiogram. *Circulation*, **42**, 437.
- Frater, R. W. M. (1965). Persistent common atrioventricular canal: anatomy and function in relation to surgical repair. *Circulation*, **32**, 120.
- Goor, D., Lillehei, C. W., and Edwards, J. E. (1968). Further observations on the pathology of the atrioventricular canal malformation. *Archives of Surgery*, **97**, 954.
- Goor, D. A., Edwards, J. E., and Lillehei, C. W. (1970a). The development of the interventricular septum of the human heart; correlative morphogenetic study. *Chest*, **58**, 453.
- Goor, D. A., Lillehei, C. W., Rees, R., and Edwards, J. E. (1970b). Isolated ventricular septal defect. Developmental basis for various types and presentation of classification. *Chest*, **58**, 468.
- Gotsman, M. S., Beck, W., and Schrire, V. (1968). Left ventricular cine-angiocardiography in endocardial cushion defect. *British Heart Journal*, **30**, 182.
- Grant, R. P. (1962). The embryology of the ventricular flow pathways in man. *Circulation*, **25**, 756.
- Kiely, B., Adams, P., Jr., Anderson, R. C., and Lester, R. G. (1958). The ostium primum syndrome. *American Journal of Diseases of Children*, **96**, 381.
- Lam, J. H. C., Ranganathan, N., Wigle, E. D., and Silver, M. D. (1970). Morphology of the human mitral valve. I. Chordae tendineae: a new classification. *Circulation*, **41**, 449.
- Neufeld, H. N., Titus, J. L., DuShane, J. W., Burchell, H. B., and Edwards, J. E. (1961). Isolated ventricular septal defect of the persistent common atrioventricular canal type. *Circulation*, **23**, 685.
- Odgers, P. N. B. (1938). The development of the pars membranacea septi in the human heart. *Journal of Anatomy*, **72**, 247.
- Quero M., Ugarte, M., Enriquez de Salamanca, F., Calabró, R., and Pérez-Martínez, V. (1974). Risultati anatomici ed implicazioni embriologiche. *Settimana Medica*, **62**, 331.
- Ranganathan, N., Lam, J. H. C., Wigle, E. D., and Silver, M. D. (1970). Morphology of the human mitral valve. II. The valve leaflets. *Circulation*, **41**, 459.
- Rastelli, G. C., Kirklin, J. W., and Kincaid, O. W. (1967). Angiocardiography of persistent common atrioventricular canal. *Mayo Clinic Proceedings*, **42**, 200.
- Rastelli, G. C., Kirklin, J. W., and Titus, J. L. (1966). Anatomic observations on complete form of persistent common atrioventricular canal with special reference to atrioventricular valves. *Mayo Clinic Proceedings*, **41**, 296.
- Rastelli, G. C., Ongley, P. A., Kirklin, J. W., and McGoon, D. C. (1968). Surgical repair of the complete form of persistent common atrioventricular canal. *Journal of Thoracic and Cardiovascular Surgery*, **55**, 299.
- Silver, M. D., Lam, J. H. C., Ranganathan, N., and Wigle, E. D. (1971). Morphology of the human tricuspid valve. *Circulation*, **43**, 333.
- Somerville, J. (1966). Clinical assessment of the function of the mitral valve in atrioventricular defects related to the anatomy. *American Heart Journal*, **71**, 701.
- Somerville, J., and Jefferson, K. (1968). Left ventricular angiocardiography in atrioventricular defects. *British Heart Journal*, **30**, 446.
- Sumner, R. G., Phillips, J. H., Jacoby, W. J., Jr., and Tucker, D. H. (1967). Forme fruste of endocardial cushion defect. *American Journal of Medical Sciences*, **254**, 266.
- Tenckhoff, L., and Stamm, S. J. (1973). An analysis of 35 cases of the complete form of persistent common atrioventricular canal. *Circulation*, **48**, 416.
- Vanetti, A., and Daumet, P. (1975). Traitement chirurgicale des formes sévères du canal atrio-ventriculaire. *Archives des Maladies du Cœur et des Vaisseaux*, **68**, 719.
- Van Mierop, L. H. S. (1969). Endocardial cushion defects. In *The Ciba Collection of Medical Illustrations*, Vol. 5: Heart, p. 139. By F. H. Netter. Ciba, New York.
- Van Mierop, L. H. S., Alley, R. D., Kausel, H. W., and Stranahan, A. (1962). The anatomy and embryology of endocardial cushion defects. *Journal of Thoracic and Cardiovascular Surgery*, **43**, 71.
- Wakai, C. S., and Edwards, J. E. (1956). Developmental and pathologic considerations in persistent common atrioventricular canal. *Proceedings of the Staff Meetings of the Mayo Clinic*, **31**, 487.
- Wakai, C. S., and Edwards, J. E. (1958). Pathologic study of persistent common atrioventricular canal. *American Heart Journal*, **56**, 779.
- Wakai, C. S., Swan, H. J. C., and Wood, E. H. (1956). Hemodynamic data and findings of diagnostic value in nine proved cases of persistent common atrioventricular canal. *Proceedings of the Staff Meetings of the Mayo Clinic*, **31**, 500.
- Yokoyama, M., Ando, M., Takao, A., and Sakakibara, S. (1973). The location of the coronary sinus orifice in endocardial cushion defects. *American Heart Journal*, **85**, 302.

Requests for reprints to Dr. M. Ugarte, Servicio de Cardiología Pediátrica, Clínica Infantil 'La Paz', Madrid, Spain.